



# Role of $^{99m}\text{Tc}$ -Mebrofenin Hepatobiliary Scintigraphy in the Diagnosis of Post Cholecystectomy Syndrome

S. Durga Sowmya<sup>1</sup> Amit Gupta<sup>1</sup> Manishi L. Narayan<sup>2</sup> Udit Chauhan<sup>3</sup> Jaydeep Jain<sup>1</sup> Tanuj Singla<sup>1</sup>  
Jaine John Chennatt<sup>1</sup>

<sup>1</sup>Department of Surgery, All India Institute of Medical Sciences, Rishikesh, Uttarakhand, India

<sup>2</sup>Department of Nuclear Medicine, All India Institute of Medical Sciences, Rishikesh, Uttarakhand, India

<sup>3</sup>Department of Radiology, All India Institute of Medical Sciences, Rishikesh, Uttarakhand, India

Address for correspondence S. Durga Sowmya, MS, Department of Surgery, All India Institute of Medical Sciences, Rishikesh 249203, Uttarakhand, India (e-mail: durgasowmya17@gmail.com).

World J Nuclear Med 2022;21:231–235.

## Abstract

**Background** Huge variation in the prevalence of post cholecystectomy syndrome (PCS) is because PCS can include a wide variety of disorders that can be both related and unrelated to cholecystectomy. Hepatobiliary scintigraphy (HBS) is a noninvasive nuclear medicine scan that can evaluate a delay in the transit of bile from the hepatic hilum to the duodenum using a radiotracer  $^{99m}\text{Tc}$ -Mebrofenin that can be associated with a functional ampullary obstruction. The aim of this study was to assess the role of  $^{99m}\text{Tc}$ -Mebrofenin HBS in the detection of the cause of PCS among the patients undergoing cholecystectomy.

**Methods** Twenty-one patients who presented with PCS from September 2018 to February 2020 were included in the study. These patients were characterized based on history, examination, liver function test, and abdominal ultrasound. Sphincter of Oddi dysfunction (SOD) was diagnosed using the Rome 3 criteria and the Milwaukee classification. Magnetic resonance cholangiopancreatography (MRCP) and upper gastrointestinal endoscopy and biopsy were done when indicated, to establish the diagnosis. These patients were further subjected to  $^{99m}\text{Tc}$ -Mebrofenin HBS, and the findings were analyzed.

**Results** The most common symptom in PCS was biliary pain occurring in 85.7% of the patients. The average time of presentation since surgery was 1.9 years. The most common cause of PCS was SOD, occurring in 52.3% of the patients, followed by benign biliary stricture occurring in 23.8% of the patients. The mean bile duct (common bile duct) visualization time in patients with PCS was 25.2 minutes, the mean duodenal visualization time was 38.2 minutes, and the mean jejunal visualization time was 60.5 minutes. The mean bile duct to duodenum transit time was 12.7 minutes, while the mean bile duct to jejunum transit time was 30.1 minutes. HBS showed consistent findings with the final diagnosis made by other diagnostic modalities (clinical criteria/MRCP/intraoperative findings) in 80.9% of the patients.

**Conclusion**  $^{99m}\text{Tc}$ -Mebrofenin HBS has a significant role in the evaluation of PCS.

## Keywords

- ▶ hepatobiliary scintigraphy
- ▶ sphincter of Oddi dysfunction
- ▶ post cholecystectomy syndrome
- ▶ radiotracer
- ▶ bile duct
- ▶ dyspepsia

DOI <https://doi.org/10.1055/s-0042-1751038>.  
ISSN 1450-1147.

© 2022. World Association of Radiopharmaceutical and Molecular Therapy (WARMTH). All rights reserved.

This is an open access article published by Thieme under the terms of the Creative Commons Attribution-NonDerivative-NonCommercial-License, permitting copying and reproduction so long as the original work is given appropriate credit. Contents may not be used for commercial purposes, or adapted, remixed, transformed or built upon. (<https://creativecommons.org/licenses/by-nc-nd/4.0/>)

Thieme Medical and Scientific Publishers Pvt. Ltd., A-12, 2nd Floor, Sector 2, Noida-201301 UP, India

## Introduction

Post cholecystectomy syndrome (PCS) is defined as the persistence or recurrence of abdominal pain and/or dyspepsia post cholecystectomy. It has been observed in 5 to 47% of the patients post cholecystectomy.<sup>1</sup> The huge variation in the prevalence is because PCS can include a wide variety of disorders that can be both related and unrelated to cholecystectomy. The major cause for pain in PCS is an extrabiliary disorder like pancreatitis or gastroesophageal reflux disease.<sup>2</sup> PCS can also be caused by a biliary disorder such as retained or de novo bile duct stones, biliary strictures, biliary dyskinesia, or sphincter of Oddi dysfunction (SOD). Though the management of these various biliary disorders is known, there are no definitive guidelines on how to investigate a patient who presents with post cholecystectomy pain. Hence, further research into the diagnostic approach of PCS becomes indispensable. SOD is one of the important causes of PCS. The most important element in the diagnosis of SOD is the history of a biliary type of pain, which warrants further evaluation.

The gold standard investigation for the diagnosis of SOD is endoscopic retrograde cholangiopancreatography (ERCP) with endoscopic sphincter of Oddi manometry (ESOM).<sup>3</sup> Despite being gold standard, ERCP with ESOM carries a significant risk of morbidity. Pancreatitis is reported in 4 to 31% of the patients undergoing ERCP with ESOM.<sup>4</sup> It is also difficult to perform and needs expertise. Hence, it is not available in all health care facilities. Here comes the need for a relatively safe noninvasive diagnostic approach for SOD. Hepatobiliary scintigraphy (HBS) is a noninvasive nuclear medicine scan that can evaluate a delay in the transit of bile from the hepatic hilum to the duodenum using a radiocolloid tracer that can be associated with a functional ampullary obstruction.<sup>5</sup> HBS is considered safe because the use of <sup>99m</sup>Tc-Mebrofenin causes only a total body radiation exposure of 16 millirads/mCi or 0.0016 rads/mCi.<sup>6</sup> The incidence of adverse reactions for radiopharmaceuticals is also low.<sup>7</sup> It is also a less expensive alternative. This study aimed to ascertain the role of <sup>99m</sup>Tc-Mebrofenin HBS in PCS.

## Methods

This is a prospective observational study, conducted from September 2018 to February 2020. Twenty-one patients

who presented to the outpatient department with PCS during this period were included in the study. Patients who were incidentally diagnosed with carcinoma gall bladder on histopathological examination of the cholecystectomy specimen and pregnant females were excluded from the study. Institutional Ethics Committee approval (No.281/IEC/PGM2018) and informed consent from all patients were taken. Those patients who had a recurrence of symptoms (upper abdominal pain and dyspepsia) or those who had persistence of symptoms for more than 30 days post surgery were diagnosed with PCS. Those patients who presented with PCS were further characterized by history, clinical examination, liver function test, and abdominal ultrasound. SOD was diagnosed based on the Rome 3 criteria and the Milwaukee classification (►Table 1).<sup>8</sup> Magnetic resonance cholangiopancreatography (MRCP), upper gastrointestinal endoscopy, and biopsy were done when indicated, to establish the diagnosis and the cause of PCS. The patients who developed PCS underwent <sup>99m</sup>Tc-Mebrofenin HBS and its parameters were analyzed.

### <sup>99m</sup>Tc-Mebrofenin Hepatobiliary Scintigraphy


Imaging was done after 4 hours of fasting. For HBS, 4 to 5 millicurie of <sup>99m</sup>Tc-Mebrofenin was injected intravenously, while the patient was lying supine under Gamma camera (GE NMCT 670, single-photon emission computed tomography/computed tomography [SPECT/CT] system). Immediate perfusion images (2 seconds × 30 frames) followed by a sequential dynamic image (15 seconds × 240 frames in 128 × 128 matrix size with zoom factor 1) were acquired in anterior view. The delayed static image was acquired at 1 hour using 256 × 256 matrix size for 2-minute duration (►Fig. 1). The patients were allowed to take meal and postmeal static images were taken at 1.5 hours, 2 hours, 3 hours, and 4 hours using the same acquisition protocol. SPECT and low-dose correlative CT were performed wherever needed.

### Image Processing

Both dynamic and static images were analyzed qualitatively and quantitatively by the nuclear medicine team. Various parameters such as common bile duct (CBD) visualization time, duodenal visualization time (C-shaped tracer activity seen just after the arrival of tracer at CBD; ►Fig. 2A), jejunal visualization time (irregular focus of intraluminal tracer

**Table 1** Rome 3 criteria and the Milwaukee classification

Rome 3 criteria	The Milwaukee classification
<b>Functional biliary sphincter disorder:</b> <ol style="list-style-type: none"> <li>1. Biliary pain</li> <li>2. Elevated liver enzymes or dilated bile duct, but not both</li> <li>3. Absence of bile duct stones or other structural abnormalities</li> </ol> <b>Supportive criteria:</b> <ol style="list-style-type: none"> <li>1. Normal amylase/lipase</li> <li>2. Abnormal sphincter of Oddi manometry</li> <li>3. Hepatobiliary scintigraphy.</li> </ol>	<b>Sphincter of Oddi dysfunction (SOD) 1:</b> <ol style="list-style-type: none"> <li>1. Biliary type of pain and elevated liver or pancreatic bioenzymes</li> <li>2. Dilated bile duct or pancreatic duct</li> </ol> <b>SOD 2:</b> <ol style="list-style-type: none"> <li>1. Biliary type of pain and elevated liver or pancreatic bioenzymes</li> <li>2. Dilated bile duct or pancreatic duct</li> </ol> <b>SOD 3:</b> <ol style="list-style-type: none"> <li>3. Biliary type of pain only</li> </ol>



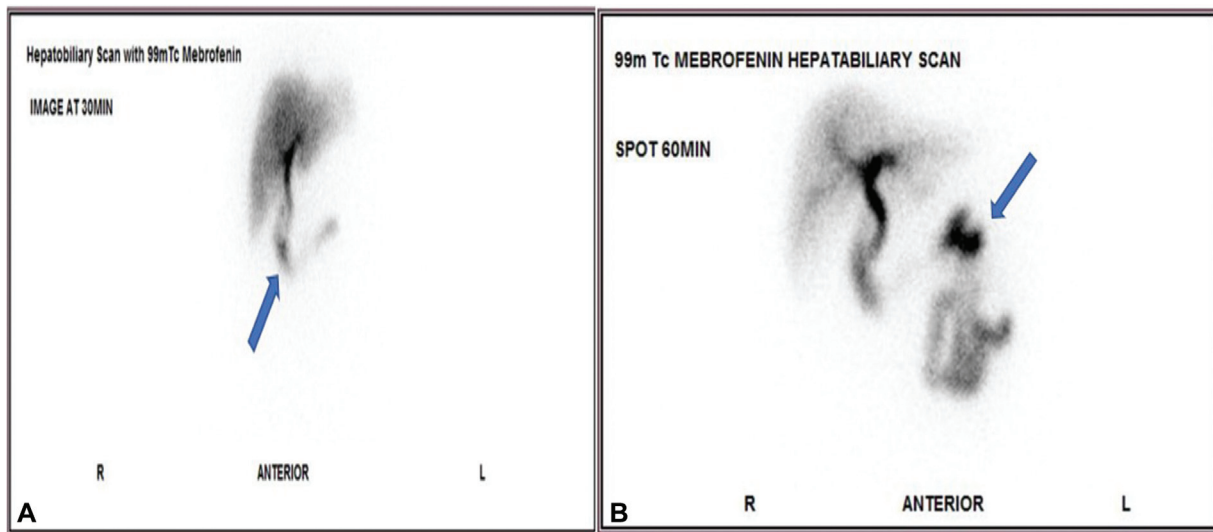
**Fig. 1** <sup>99m</sup>Tc-Mebrofenin hepatobiliary scintigraphy image: One minute frame dynamic image showing common bile duct visualization time at 19 minutes, duodenal visualization at 25 minutes, jejunal visualization time at 34 minutes with a biliointestinal (bile duct to the duodenum) transit time of 6 minutes, and a bile duct to the jejunum transit time of 15 minutes in a patient diagnosed with sphincter of Oddi dysfunction.

activity in the periumbilical region, right or left quadrant immediately after the arrival of tracer in duodenum; **→Fig. 2B**), biliointestinal (bile duct to duodenum) transit time, and bile duct to jejunum transit time were noted.

**Statistical Analysis**

The data were tabulated in an Excel Sheet and analyzed with SPSS v. 23.0 (Armonk, New York: IBM Corp). Descriptive

statistics was elaborated in the form of mean/standard deviation and median/interquartile range for continuous variables, and frequency and percentage for categorical variables. Shapiro–Wilk normality test was applied to the continuous variables. Nonparametric Kruskal–Wallis test was used to compare the HBS parameters with the three subgroups of PCS. Taking confidence interval as 95%,  $p < 0.05$  was taken as statistically significant.



**Fig. 2** (A) Duodenal visualization time: C-shaped tracer activity seen just after the arrival of tracer at common bile duct (blue arrow). (B) Jejunal visualization time: irregular focus of intraluminal tracer activity seen in the periumbilical region (blue arrow), right or left quadrant immediately after arrival of tracer in the duodenum.

## Results

The mean age of the patients included in the study was  $44.1 \pm 15.0$  years. The clinical profile of all the PCS patients is summarized in ► **Table 2**. The mean CBD visualization time of the 21 patients with PCS was  $25.2 \pm 38.2$  minutes ranging between 9 and 180 minutes. The mean intestinal visualization time (duodenum) was  $38.2 \pm 49.2$  minutes ranging between 12 and 240 minutes. The mean jejunum visualization time was  $60.1 \pm 65.2$  minutes ranging between 14 and 300 minutes. The mean biliointestinal (duodenal) transit time was  $12.7 \pm 13.2$  minutes, ranging between 2 and 60 minutes. The mean biliointestinal (jejunal) transit time was  $30.1 \pm 27.6$  minutes, ranging between 4 and 120 minutes. Three patients (14.2%) had duodenogastric reflux on HBS. With the other modalities of investigation, 11 patients (52.3%) had features suggestive of SOD, 5 patients (23.8%) had a benign biliary stricture (BBS), 2 patients (9.5%) had bile leak (cystic duct stump blow out), 1 patient (4.8%) had *Helicobacter pylori* gastritis, 1 patient (4.8%) had a remnant gall bladder with calculi, and 1 patient (4.8%) had choledocholithiasis. The findings in HBS were consistent with the final diagnosis made by other diagnostic modalities, in 17 patients (81%). The 21 patients were divided into 3 subgroups based on the final diagnosis as patients with SOD, other biliary causes, and nonbiliary causes.

The mean duodenal visualization time of the SOD group was  $21.0 \pm 7.6$  minutes, that of the other biliary (bile duct injury and stones) group was  $64.6 \pm 71.8$  minutes, and that of the nonbiliary group was 15 minutes. There was a significant difference between the three subgroups in diagnosis in terms of duodenal visualization time in minutes ( $p = 0.014$ ). The mean jejunal visualization time in the SOD group was  $36.3 \pm 20.8$  minutes, that in the other biliary (bile duct injury and stones) group was  $97.8 \pm 90.4$  minutes, and that in the other biliary group was 20 minutes. There was a significant difference between the three subgroups in terms of jejunal visualization time ( $p = 0.033$ ).

**Table 2** Clinical profile of the patients with post cholecystectomy syndrome

Mean age in years	$44.1 \pm 15.0$ (range: 23–80)
Male:female ratio	2:19
Mean body mass index in kg/m <sup>2</sup>	$24.0 \pm 4.2$ (range: 17.9–32.5)
Most common symptom	Pain
Severity of pain: Numeric Rating Scale	$4.9 \pm 1.4$ (range: 3–7)
Duration of symptoms (in months)	$3.3 \pm 3.4$ (range: 0.5–12)
Alkaline phosphatase (ALP) IU/L	$292.1 \pm 352.1$ (range: 68–1,650)
Raised ALP	12 (57.1%)
Dilated bile duct	3 (14.3%)
Time since surgery (years)	$1.9 \pm 2.9$ (range: 0.16–12)

## Discussion

In this study, it was observed that the jejunal visualization time (mean = 60.1 minutes) was more delayed in the patients with PCS than the duodenal visualization time (mean = 38.2 minutes) in this study. The mean biliointestinal (bilioduodenal) transit time in patients with PCS in the present study was  $12.7 \pm 13.3$  minutes. Corazziari et al<sup>9</sup> reported a mean biliointestinal (bilioduodenal) transit time of  $12.5 \pm 2.2$  minutes in patients with post cholecystectomy pain and a mean biliointestinal (bilioduodenal) transit time of  $6.7 \pm 2.6$  minutes in asymptomatic controls, thus showing an obvious delay in the PCS patients. The bile duct to the jejunum transit time (mean = 30.1 minutes) was also markedly increased compared with the bile duct to the duodenum transit time (mean = 12.7 minutes) in the patients with PCS.

Normally, not much delay is seen for the arrival of tracer into the duodenum or jejunum from the CBD. But in the current study, we have noticed a difference between the bile duct to duodenum transit time and the bile duct to jejunum transit time. This is possibly due to the high sensitivity of radionuclide scans (HBS) to detect the passage of minute quantities of radioactive bile in the intestine. Hence, minute quantities of radiotracer could be seen passing down slowly in the duodenum, much earlier than the bile flow to jejunal loops, in patients with biliary tract obstruction or SOD. Both transit times, including CBD to duodenum and CBD to jejunum, were significantly delayed in our study population.

Various other pharmacological interventions have been proposed in the past for confirming the diagnosis of SOD, including morphine intervention.<sup>10</sup> But opioids are associated with intolerable pain and have been reported to incite pancreatitis. Certain exogenous agents relax the Sphincter of Oddi, reducing its pressure and resistance.<sup>11</sup> This includes calcium-channel blockers, tricyclic antidepressants, botox, glyceryl trinitrate, and somatostatin. The use of these agents has also reported to indirectly diagnose SOD in various studies. In patients with SOD, HBS will show the reflux of bile into the bile ducts, which is well appreciated after the cessation of cholecystokinin injection as reported by Sostre et al<sup>12</sup> In the present study, intervention with cholecystokinin could not be performed due to nonavailability. Hence bile reflux could not be appreciated in patients suspected with SOD. But it was observed that 8 out of the 11 patients with suspected SOD (72.7%) showed CBD prominence with/or retention and slow drainage via the bile duct thus giving significant results even in the absence of any cholecystokinin and opioid intervention. Interestingly, two patients with PCS showed intermittent pooling of tracer at the cystic duct stump raising the suspicion of SOD, of which one patient was diagnosed with SOD II based on the clinical criteria (Rome's criteria and Milwaukee classification). It was seen that <sup>99m</sup>Tc-Mebrofenin HBS showed consistent findings in patients of PCS due to other biliary causes such as BBS, bile leak, choledocholithiasis, and remnant gall bladder with calculi, which were confirmed with MRCP. HBS showed an extrahepatic biliary obstruction in all the five patients of BBS confirmed by MRCP and intraoperative findings. It also

showed ascending cholangitis in four of the nine patients with biliary obstruction/bile leak. In both the patients with bile leak, HBS showed tracer leak and subhepatic collection.

## Conclusion

Therefore, in this study, <sup>99m</sup>Tc-Mebrofenin HBS demonstrates both structural and functional abnormalities making it an efficient diagnostic tool in the evaluation of the patients with the PCS. The bile duct to jejunum transit time was more representative, and correlated well with the biliointestinal transit abnormalities than the bile duct to duodenal transit time, making it an important parameter to be analyzed in the evaluation of PCS.

## Limitation

Diagnosis of SOD was made based on Rome 3 criteria and Milwaukee classification in this study. Sphincter of Oddi manometry, the gold standard investigation for SOD, could not be performed due to nonavailability at our institute. Hence the diagnostic accuracy of HBS could not be defined.

### Funding

None.

### Conflict of Interest

None declared.

## References

- 1 Bisgaard T, Rosenberg J, Kehlet H. From acute to chronic pain after laparoscopic cholecystectomy: a prospective follow-up analysis. *Scand J Gastroenterol* 2005;40(11):1358–1364
- 2 Girometti R, Brondani G, Cereser L, et al. Post-cholecystectomy syndrome: spectrum of biliary findings at magnetic resonance cholangiopancreatography. *Br J Radiol* 2010;83(988):351–361
- 3 Bistriz L, Bain VG. Sphincter of Oddi dysfunction: managing the patient with chronic biliary pain. *World J Gastroenterol* 2006;12(24):3793–3802
- 4 Fogel EL, Eversman D, Jamidar P, Sherman S, Lehman GA. Sphincter of Oddi dysfunction: pancreaticobiliary sphincterotomy with pancreatic stent placement has a lower rate of pancreatitis than biliary sphincterotomy alone. *Endoscopy* 2002;34(04):280–285
- 5 Ziessman HA. Hepatobiliary scintigraphy in 2014. *J Nucl Med* 2014;55(06):967–975
- 6 Krishnamurthy GT, Krishnamurthy S. Imaging agents. In: Krishnamurthy GT, Krishnamurthy S, eds. *Nuclear Hepatology: A Textbook of Hepatobiliary Diseases*. 2nd edition. New York, NY: Springer; 2009:65
- 7 Silberstein EB, Ryan J. Pharmacopeia Committee of the Society of Nuclear Medicine. Prevalence of adverse reactions in nuclear medicine. *J Nucl Med* 1996;37(01):185–192
- 8 Morgan AK, Adams BD. Biliary dyskinesia and Sphincter of Oddi dysfunction. In: Yeo J Charles, ed. *Shackleford's Surgery of the Alimentary Tract*. 8th edition. Philadelphia, PA: Elsevier; 2019: 1294–1299
- 9 Corazziari E, Cicala M, Habib FI, et al. Hepatoduodenal bile transit in cholecystectomized subjects. Relationship with sphincter of Oddi function and diagnostic value. *Dig Dis Sci* 1994;39(09): 1985–1993
- 10 Krishnamurthy S, Krishnamurthy GT. Cholecystokinin and morphine pharmacological intervention during <sup>99m</sup>Tc-HIDA cholecystigraphy: a rational approach. *Semin Nucl Med* 1996;26(01): 16–24
- 11 Afghani E, Lo SK, Covington PS, Cash BD, Pandol SJ. Sphincter of Oddi function and risk factors for dysfunction. *Front Nutr* 2017; 4:1
- 12 Sostre S, Kallou AN, Spiegler EJ, Camargo EE, Wagner HN Jr. A noninvasive test of sphincter of Oddi dysfunction in postcholecystectomy patients: the scintigraphic score. *J Nucl Med* 1992;33(06):1216–1222