

A Rod-Sparing Retinopathy in Bardet-Biedl Syndrome

Cynthia S. Chiu^a Dimosthenis Mantopoulos^{b, c} Simmons Lessell^c
Dean M. Cestari^c

^aDepartment of Ophthalmology, University of California San Francisco, San Francisco, Calif., ^bDepartment of Ophthalmology and Visual Science, Havener Eye Institute, The Ohio State University, Columbus, Ohio, and ^cNeuro-Ophthalmology Service, Massachusetts Eye and Ear Infirmary, Harvard Medical School, Boston, Mass., USA

Key Words

Bardet-Biedl syndrome · Rod-sparing · Polydactyly · Retinitis Pigmentosa · Electroretinography

Abstract

Bardet-Biedl syndrome is a continuum of disorders characterized by systemic and ocular findings. Retinal abnormalities typically present as diffuse photoreceptor degeneration. Here, we report a novel case that suggests a rod-sparing variant of Bardet-Biedl syndrome.

© 2015 S. Karger AG, Basel

Introduction

Bardet-Biedl syndrome is a continuum of systemic manifestations that include obesity, polydactyly, hypogonadism and mental retardation [1]. The ocular examination can reveal different types and severity of pigmentary retinal dystrophy (including retinitis pigmentosa sine pigmento, retinitis punctata albescens or even typical retinitis pigmentosa) [2] as well as a combined rod-cone dystrophy characterized by global photoreceptor malfunction. However, we have identified an unusual variant of Bardet-Biedl syndrome where the retinopathy is cone selective.

Case Report

A 17-year-old Armenian boy was referred to the Neuro-Ophthalmology Service at the Massachusetts Eye & Ear Infirmary after failing 2 recent vision screenings. Except for poor vision, both an optometrist and an ophthalmologist had found his eye examination to be 'normal', but neither could improve his vision with refraction. The patient did not have fluctuation of the vision consistent with nyctalopia or hemeralopia, while, according to his mother, he had always been 'nearsighted', but could read books if he held them close to his face.

The patient's birth history was unremarkable. His medical history was notable for hypercholesterolemia, the surgical removal of a sixth toe bilaterally and the repositioning of an undescended testicle. There was no pertinent family or ocular history. He had mild mental retardation and was enrolled in a special education curriculum at his local high school.

The physical examination revealed an obese adolescent with mild psychomotor retardation. Visual acuity could not be improved beyond 16/100 OU, and the patient exhibited a profound bilateral dyschromatopsia. He could only read the control plates on the Ishihara tests and made numerous errors along the deutan axis on the Farnsworth D-15 dichotomous color blindness test. A slit-lamp examination and a tonometry were unremarkable. A dilated funduscopy (fig. 1a, b) revealed a normal appearance of his optic nerves. There was pigment mottling in the central macula bilaterally. He was noted to have white-without-pressure temporally in both eyes. Goldmann perimetry revealed bilateral central scotoma to the I4e test object, spanning a 10-degree radius from the center of vision (fig. 1c, d).

Electroretinography (ERG) revealed normal dim and bright scotopic amplitudes as well as normal implicit times. However, the bright photopic response was unrecordable, and the 30-Hz flicker stimulus was severely reduced and delayed bilaterally. The remainder of his neuro-ophthalmic evaluation, including head and orbital CT, was unremarkable. Analysis of these findings suggested a cone-specific degeneration (fig. 2a–d). Repeat ERG 4 years after initial testing showed a bilateral cone dysfunction (fig. 2e–h). Genetic testing was not performed.

Discussion

Bardet-Biedl syndrome is a genetic disorder with variable expressivity and a wide range of clinical variability observed both within and between families. The main clinical features include polydactyly, truncal obesity, mental retardation, hypogonadism and renal dysfunction. Classically, these patients present with childhood-onset visual loss that is preceded by nyctalopia secondary to a rod-cone dystrophy. Our patient had Bardet-Biedl syndrome with a rod-sparing, photoreceptor dystrophy. Bardet-Biedl syndrome has previously been described as a rod-cone, cone-rod, choroidal or global retinal dystrophy [3]. It has also been reported that patients with difficult to classify early photoreceptor dysfunction eventually progress to a classic stage of rod degeneration [4]. However, the ERG recordings of our patient, 4 years apart, consistently demonstrated isolated cone dysfunction. Thus, we believe that this patient demonstrates a rare cone-selective variant of Bardet-Biedl syndrome.

References

- 1 Riise R, Andreasson S, Borgstrom MK, Wright AF, Tommerup N, et al: Intrafamilial variation of the phenotype in Bardet-Biedl syndrome. *Br J Ophthalmol* 1997;81:378–385.
- 2 Beales PL, Elcioglu N, Woolf AS, Parker D, Flinter FA: New criteria for improved diagnosis of Bardet-Biedl syndrome: results of a population survey. *J Med Genet* 1999;36:437–446.
- 3 Riise R, Andreasson S, Tornqvist K: Full-field electroretinograms in individuals with the Laurence-Mood-Bardet-Biedl syndrome. *Acta Ophthalmol Scand* 1996;74:618–620.
- 4 Azari AA, Aleman TS, Cideciyan AV, Schwartz SB, Windsor EA, et al: Retinal disease expression in Bardet-Biedl syndrome-1 (BBS1) is a spectrum from maculopathy to retina-wide degeneration. *Invest Ophthalmol Vis Sci* 2006;47:5004–5010.

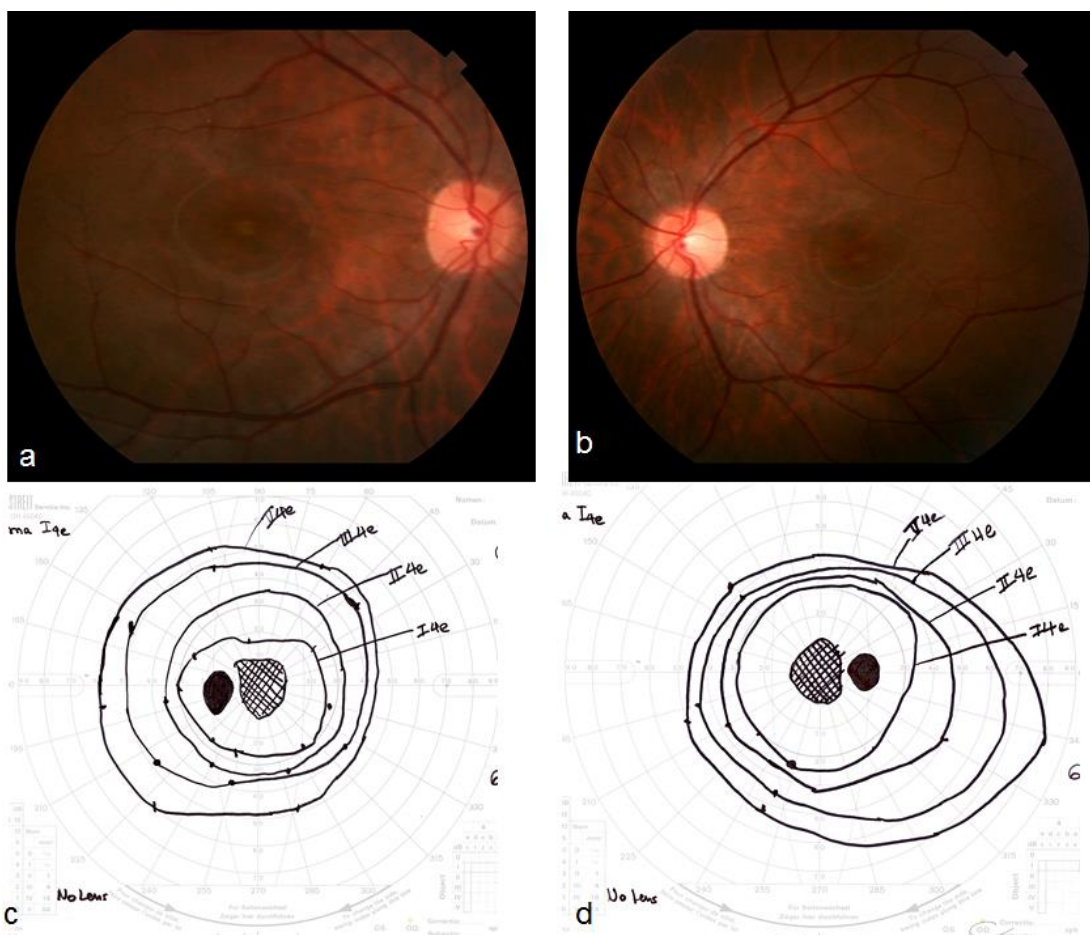


Fig. 1. Fundus photos of both eyes showing optic nerves with a normal appearance, and pigment mottling in the macula in the right (a) and the left eye (b). Goldmann visual fields documented bilateral central scotoma to the I4e test isopter, spanning a 10-degree radius from the center of vision both in the left (c) and the right eye (d).

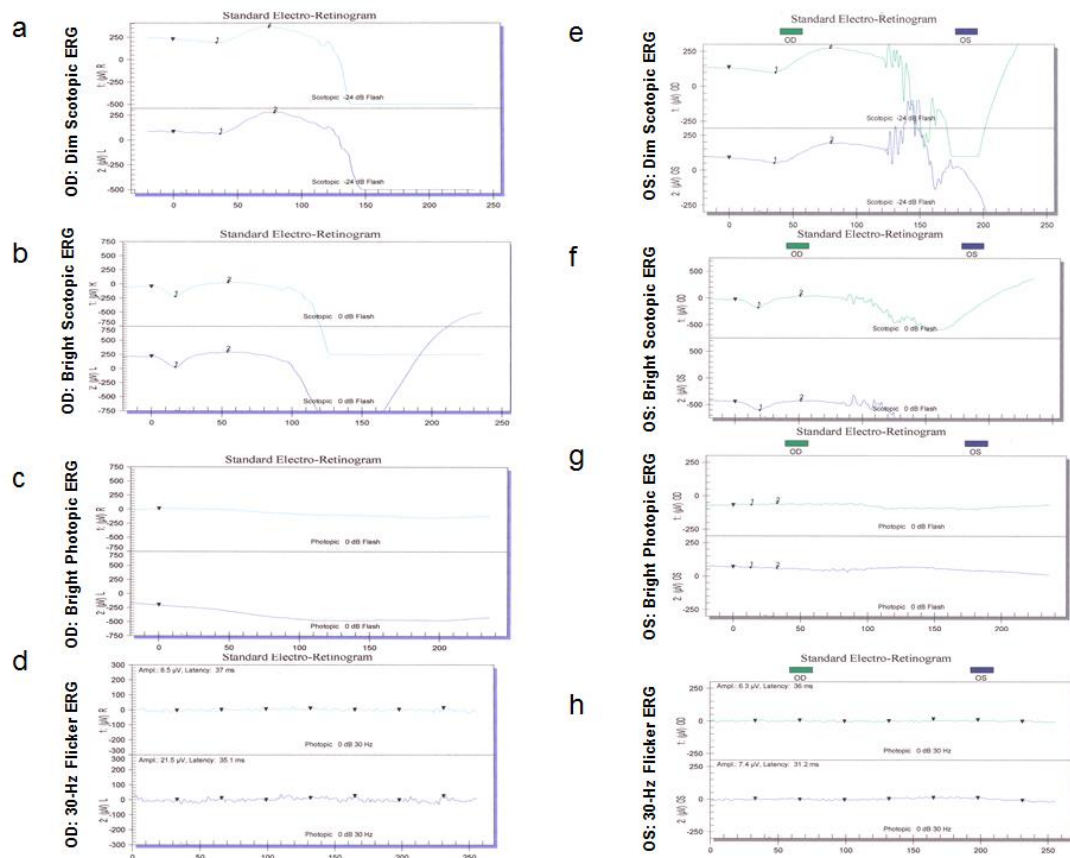


Fig. 2. ERG recordings. A Ganzfeld stimulator, with bright flash intensity calibrated to 2.12 cd s/m², was used. The flash duration was 10 ms. The band pass of the amplifiers was set at 0.3–300 Hz. A 24-dB neutral density filter over a strobe lamp was presented as a dim white flash stimulus. The background of the Ganzfeld dome was then illuminated at 39 cd/m². Using the same background illumination, the bright flash was presented at 30 Hz and then sweeps were averaged. Dim scotopic (**a**, **e**) and bright scotopic (**b**, **f**) were normal, while bright photopic was unrecordable (**c**, **g**) and 30-Hz flicker showed reduced and delayed tracings (**d**, **h**), both upon first presentation as well as 4 years later (**a–h**).