

Activator protein-1 (AP-1) signalling in human atherosclerosis: results of a systematic evaluation and intervention study

C. Arnoud MEIJER¹, Pum A. A. LE HAEN¹, Rogier A. VAN DIJK, Mitsuhsa HIRA, Jaap F. HAMMING, J. Hajo VAN BOCKEL and Jan H. LINDEMAN

Department of Vascular Surgery, Leiden University Medical Center, Leiden, PO Box 9600, 2300 RC Leiden, The Netherlands

A B S T R A C T

Animal studies implicate the AP-1 (activator protein-1) pro-inflammatory pathway as a promising target in the treatment of atherosclerotic disease. It is, however, unclear whether these observations apply to human atherosclerosis. Therefore we evaluated the profile of AP-1 activation through histological analysis and tested the potential benefit of AP-1 inhibition in a clinical trial. AP-1 activation was quantified by phospho-c-Jun nuclear translocation (immunohistochemistry) on a biobank of aortic wall samples from organ donors. The effect of AP-1 inhibition on vascular parameters was tested through a double blind placebo-controlled cross-over study of 28 days doxycycline or placebo in patients with symptomatic peripheral artery disease. Vascular function was assessed by brachial dilation as well as by plasma samples analysed for hs-CRP (high-sensitivity C-reactive protein), IL-6 (interleukin-6), IL-8, ICAM-1 (intercellular adhesion molecule-1), vWF (von Willebrand factor), MCP-1 (monocyte chemoattractant protein-1), PAI-1 (plasminogen activator inhibitor-1) and fibrinogen. Histological evaluation of human atherosclerosis showed minimal AP-1 activation in non-diseased arterial wall (i.e. vessel wall without any signs of atherosclerotic disease). A gradual increase of AP-1 activation was found in non-progressive and progressive phases of atherosclerosis respectively ($P < 0.044$). No significant difference was found between progressive and vulnerable lesions. The expression of phospho-c-Jun diminished as the lesion stabilized ($P < 0.016$) and does not significantly differ from the normal aortic wall ($P < 0.33$). Evaluation of the doxycycline intervention only revealed a borderline-significant reduction of circulating hs-CRP levels ($-0.51 \mu\text{g/ml}$, $P = 0.05$) and did not affect any of the other markers of systemic inflammation and vascular function. Our studies do not characterize AP-1 as a therapeutic target for progressive human atherosclerotic disease.

INTRODUCTION

Atherosclerosis is a lipid-driven disorder with a strong inflammatory component. The efficacy of lipid-lowering interventions to reduce incident atherosclerotic disease has been firmly established, yet its success rate remains

limited to an approximate 30% reduction in clinical events [1]. Hence, the need for complementary strategies beyond that of lipid lowering is widely acknowledged.

Inflammation is a key factor in the progression and complications of atherosclerotic disease. Consequently, strategies aimed at the 'central hub' of inflammation have

Key words: activator protein 1 (AP-1), atherosclerosis, clinical trial, doxycycline, inflammation.

Abbreviations: AAA, abdominal aortic aneurysm; AP-1, activator protein-1; CVD, cardiovascular disease; HDL, high-density lipoprotein; hs-CRP, high-sensitivity C-reactive protein; ICAM-1, intercellular adhesion molecule-1; IL, interleukin; MCP-1, monocyte chemoattractant protein-1; NTG, nitroglycerine; PAI-1, plasminogen activator inhibitor-1; PAD, peripheral arterial disease; SMC, smooth muscle cell; vWF, von Willebrand factor.

¹ These authors contributed equally to this paper.

Correspondence: Dr Jan H.N. Lindeman (email lindeman@lumc.nl).

been brought forward as a reasonable target in limiting vascular inflammation [2]. *In vitro* and animal studies implicate the common inflammatory transcription factor AP-1 (activator protein-1) as a critical correlate in the initiation and progression of vascular dysfunction, and atherogenesis. Hence, AP-1 inhibition has been proposed as an attractive target to prevent progression of atherosclerosis [3–6].

However, as the available literature on the role of the AP-1 pathways in human atherosclerosis is limited, we decided to explore the possible role of AP-1 in atherosclerotic disease. To that end, we first performed a systematic histological evaluation of AP-1 activation in the successive stages of atherosclerotic disease. This evaluation showed abundant AP-1 activation throughout all stages of atherosclerosis. We next performed a clinical study to test whether quenching of AP-1 activation improves vascular function. The tetracycline analogue doxycycline has been shown to have a direct inhibitory effect on the activation of JNK1 (c-Jun N-terminal kinase 1) and JNK2, two key members of the AP-1 pathway [7]. These *in vitro* findings were corroborated in a clinical study that showed that a 2-week doxycycline intervention in patients with an AAA (abdominal aortic aneurysm) quenches aortic wall AP-1 activation [8].

Hence it was reasoned that doxycycline provides a means of evaluating a possible role of AP-1 in human atherosclerosis. We therefore tested whether doxycycline improves vascular function in high-risk patients (patients with peripheral artery disease) in a double-blind placebo-controlled cross-over trial.

MATERIALS AND METHODS

AP-1 activation

All sample collection and handling were performed in accordance with the guidelines of the Medical and Ethical Committee in Leiden, The Netherlands and the code of conduct of the Dutch Federation of Biomedical Scientific Societies (<http://www.federa.org/?s=1&m=82&p=0&v=4#827>).

A systematic analysis of AP-1 activation (phospho-c-Jun) was performed on material from a large biobank of aortic patches that were removed along with the kidney during kidney explanation from heart-beating, brain-dead multiple organ donors. All donors met the criteria set by The Eurotransplant Foundation. The patches were divided into 5 μm paraffin-embedded sections. The stage of atherosclerosis for each section was classified according to the modified classification of the American Heart Association proposed by Virmani et al. [9] (Table 1). All analyses were performed on the dominant lesion in the tissue section, i.e. the section showing the most advanced grade of atherosclerosis. Details of the first 260 cases in this bank have been published previously [12].

In order to achieve balanced study groups, we consecutively selected pre-classified samples for each stage (Table 1) from the tissue bank. The sections were stained for the identification of activated AP-1 (phospho-c-Jun, nuclear translocation using the anti-phospho-c-Jun clone KM-1; Cell Signaling, 1:800 overnight). Conjugated biotinylated anti-mouse IgG was used as a secondary antibody. Sections were developed with Nova Red (Vector Laboratories). Corroboration with the downstream marker PAI-1 (plasminogen activator inhibitor-1) was performed with an in-house rabbit polyclonal antibody that recognizes both the free and complex form [10,11]. Conjugated biotinylated anti-rabbit anti-IgG (1:1000 dilution, Amersham Biosciences) was used as secondary antibody. Sections were counterstained with Mayer's haematoxylin. Stained sections were histologically analysed for positive nuclear signalling and classified according to intensity. The degree of AP-1 activity was assessed semi-quantitatively within the atherosclerotic lesion: – (absent), +/– (<10% of component area stained positively), + (10–50%) and ++ (>50%). Intimal, medial and adventitial layers were analysed separately. Particular interest was paid to the various cell types present in the atherosclerotic lesion [i.e. endothelial cells, monocytes/macrophages and SMCs (smooth muscle cells)].

An atherosclerotic lesion was defined as the area between the endothelium and internal elastic lamina over a distance of 1 mm. In the presence of a necrotic core, the distance was expanded by another 500 μm on both sides of the necrotic core to include the adjacent shoulder region [12].

Intervention study

An open crossover double-blind placebo-controlled trial was used to evaluate the effect of doxycycline therapy on vascular functioning (Dutch Trial Registry NTR1389 <http://www.trialregister.nl/trialreg/admin/rctview.asp?TC=1389>). As current medical strategies focus on high-risk patients, we recruited patients with symptomatic PAD (peripheral arterial disease) from the outpatient department of vascular surgery. PAD patients were chosen for their condition, which is associated with a high risk for CVD (cardiovascular disease) [13,14]. PAD was confirmed by a history of intermittent claudication and an ankle-brachial pressure index <0.9. Patients with a history of lower extremity revascularization or endarterectomy, with diabetes mellitus or known hypersensitivity for tetracycline derivatives, or treated with antibiotics or immunosuppressive agents were excluded from participation in the study. In order to exclude potential effects of different kinds or doses of cholesterol-lowering agents all subjects were switched to, or started with, simvastatin (40 mg/day) at least 4 weeks prior to the start of study medication. All subjects participated in two sessions and both received treatments of 28 days of

Table 1 Qualitative phospho-c-Jun expression in endothelial cells, SMCs and monocytes/macrophages within the intimal atherosclerotic lesions

Lesions are classified according the modified American Heart Association classification by Virmani et al. [8]. * $P < 0.041$ and ** $P < 0.009$ between the groups, as determined by ANOVA. —, no expression of phospho-c-Jun; +/—, 0–10%; +, 10–50%; ++, >50%.

Morphological description	n	Phospho-c-Jun expression			
		Cell type . . .	Endothelial cells	SMCs*	Monocytes/macrophages**
Normal aorta	10		+ / —	+ / —	—
Non-atherosclerotic lesions					
Adaptive intimal thickening	10		+ / —	+	—
Intimal xanthoma	10		+ / —	+	+
Progressive atherosclerotic lesions					
Pathological intimal thickening	10		+ / —	++	+
Early fibroatheroma	10		+	+	+ / —
Late fibroatheroma	10		+	+	+ / —
Vulnerable atherosclerotic lesions					
Thin cap fibroatheroma	10		+	++	+
Plaque rupture	8		+	+	+
Stabilized atherosclerotic lesions					
Healed ruptures	10		+ / —	+	+
Fibrotic calcified plaque	10		+ / —	+	+ / —

doxycycline (100 mg/day) ($t_{1/2} = 15\text{--}23$ h) or placebo in a cross-over design. Dosing was separated by a washout period of 28 days.

Informed consent was obtained from each patient. Randomization was performed by the Leiden University Medical Center pharmacy.

Brachial flow-mediated dilation

Endothelial function was evaluated through flow-mediated vasodilation of the brachial artery, an established test that assesses the vasodilatory response to transient ischaemia. Endothelium independent vasodilation of the brachial artery was assessed through the artery's vasodilatory response to NTG (nitroglycerine) [15]. Flow- and NTG-mediated vasodilations were measured on each visit.

After overnight fasting, patients were examined in the supine position after 15 min of rest in a quiet room at room temperature. Patients refrained from vasoactive drugs, coffee and tea for at least 8 h prior to testing. The right brachial artery was visualized in longitudinal sections above the elbow, by high-resolution ultrasound using a 10 MHz linear probe on an Aloka 5500 SSD machine. Reactive hyperaemia was triggered by inflating a pneumatic tourniquet distal to the brachial artery to 50 mmHg above the systolic pressure for 5 min and dilation of the vessel was evaluated 1 min after releasing the tourniquet. The diameter of the brachial artery was measured in triplicate at the R-wave of the ECG, at the interface of the intima and media of the anterior and posterior wall. The brachial artery was allowed to return to its resting state for at least 15 min. Endothelium-

independent vasodilation was studied by brachial artery diameter changes 4 min after administering 400 μg of NTG sublingual. The inter- and intra-observer variability for the measurement of the diameter of brachial artery was <0.1 mm. Flow-mediated vasodilation and NTG-mediated vasodilation were defined as the percentage increase in artery diameter during dilation.

Endothelium and inflammation

Fasting blood samples were taken from the patients' left arm (non-study arm) just after evaluating vascular reactivity. Samples were centrifuged at 2000 g at 4°C for 20 min and the obtained plasma was removed and subsequently recentrifuged at 12 000 g for 10 min. Plasma was stored at -80°C until analysis. Glucose, insulin, hs-CRP (high-sensitivity C-reactive protein), TAG (triacylglycerol), HDL (high-density lipoprotein)-cholesterol and total cholesterol concentrations were determined in one batch at the certified clinical laboratory of the Leiden University Medical Center. The plasma concentration of LDL (low-density lipoprotein)-cholesterol was obtained using Friedewald estimation. The plasma concentration of vWF (von Willebrand factor), ICAM-1 (intercellular adhesion molecule-1), PAI-1, MCP-1 (monocyte chemoattractant protein-1), IL (interleukin)-6, IL-8, hs-CRP and fibrinogen were obtained using ELISA [an in-house ELISA using a rabbit anti-human vWF (A0082; Dako) and an HRP (horseradish peroxidase)-conjugated rabbit anti-human VWF antibody (P0226; Dako), an R&D Systems human ICAM-1 ELISA (DY720), an in-house ELISA using a PAI-1 coating monoclonal antibody 3-3b conjugate, an R&D Systems human MCP-1 ELISA (DY279), a

Sanquin PeliKine-compact human IL-6 ELISA (M1916), a Sanquin PeliKine-compact human IL-8 ELISA (M1918) and an in-house ELISA using a fibrinogen coating α -XDP conjugate]. hs-CRP was measured on a cobas c system (04628918; Roche Diagnostics). vWF was calibrated against a pool of human plasma (available from Sanquin). All other calibrating solutions were supplied within the kit. Samples were diluted to maintain plasma concentration well within the accuracy boundaries of the kits. All samples were analysed in duplicate. The reproducibility and accuracy of the ELISA tests were within the limits of the standard kit.

Statistical analysis

Mean levels of AP-1 expression in the immunohistochemical analysis were compared with the one-way ANOVA. Differences between the groups were assessed by Fisher's LSD (least significant difference) analysis. $P < 0.05$ was considered statistically significant.

Power calculation for the crossover study was based on data published in [7,14]. A group size of 12 patients allowed for a discriminating power of more than 95 % for a 20 % difference in arterial dilation [17] and reduction of pro-inflammatory cytokines [8] between placebo and therapeutic treatment. The normality of different variables was tested. Wilcoxon signed ranks test was used if normal distribution of the data was not applicable (see Table 3). Statistical significance was defined as a two-sided $P < 0.05$. Data in the Figures are presented as means (S.D.) in Table 2 or as medians (25th and 75th percentiles) in Table 3). All statistical analyses were performed using SPSS for Windows, version 17.0.

RESULTS

Immunohistochemistry

AP-1 activation (phospho-c-Jun nuclear translocation) was evaluated in 98 human aortic wall samples that cover the full spectrum of atherosclerotic disease (Table 1). Minimum activation of AP-1 was found in the normal aortic wall. In these samples, nuclear staining was mainly limited to the endothelial cells (Table 1 and Figure 1). A gradual increase of AP-1 activation was found in non-progressive and progressive phases of atherosclerosis respectively ($P < 0.33$ and $P < 0.044$ respectively; Figure 2), with involvement of macrophages and SMCs (Table 1 and Figure 1). No further significant increase was found in the vulnerable lesion types ($P < 0.48$; Figure 2). In advanced lesions (i.e. progressive and vulnerable phases), activated cells were distributed throughout the vascular wall with a particular strong nuclear staining of macrophages and SMCs (Table 1 and Figure 1). A notable sharp reduction in AP-1 activation was found in the stabilized lesion types, i.e. healed ruptures and fibrotic calcified plaques ($P = 0.016$;

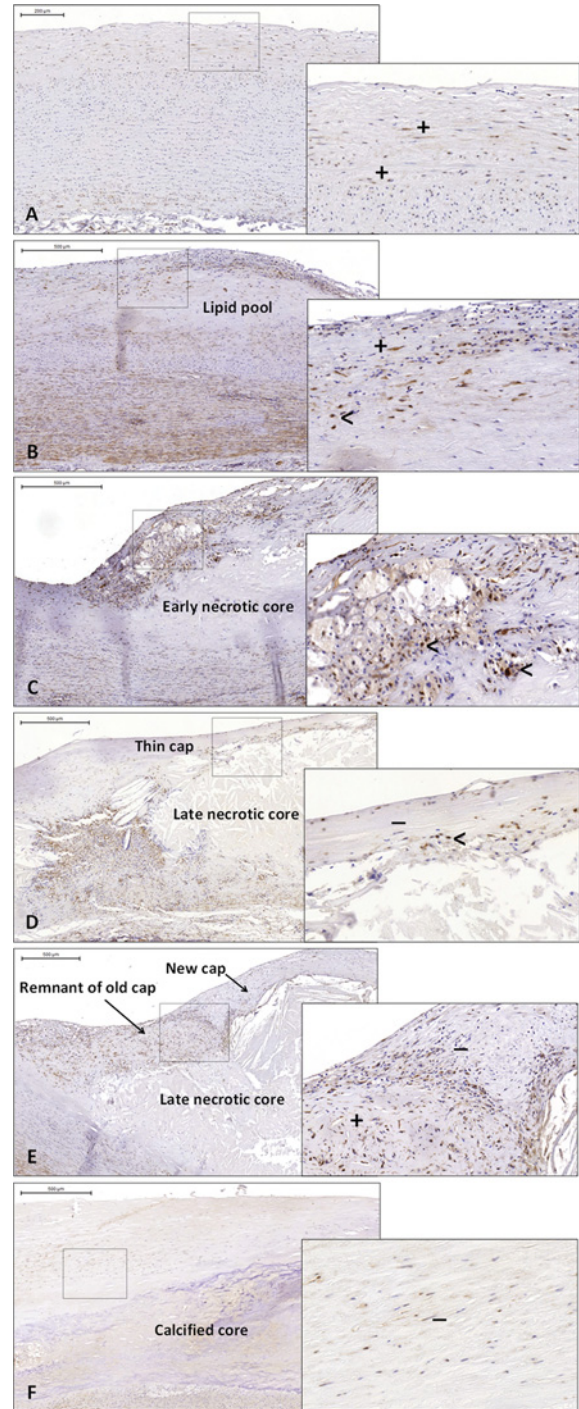


Figure 1 Phospho-c-Jun expression during the evolution of human atherosclerosis

The intima within the normal aortic wall and in aortas containing adaptive intimal thickening showed minimal expression of phospho-c-Jun in the nuclei of the vascular SMC (A). There was a higher amount of phospho-c-Jun expression in the infiltrating SMCs and monocytes surrounding the lipid pools in pathological intimal thickening (B). In early fibroatheromata almost 50 % of the monocytes and macrophages stained positive for phospho-c-Jun (C). In the thin cap fibroatheroma, the vulnerable phase in atherosclerosis, the very few SMCs that were found within the fibrous cap lacked phospho-c-Jun expression (D). In the fibrous cap of

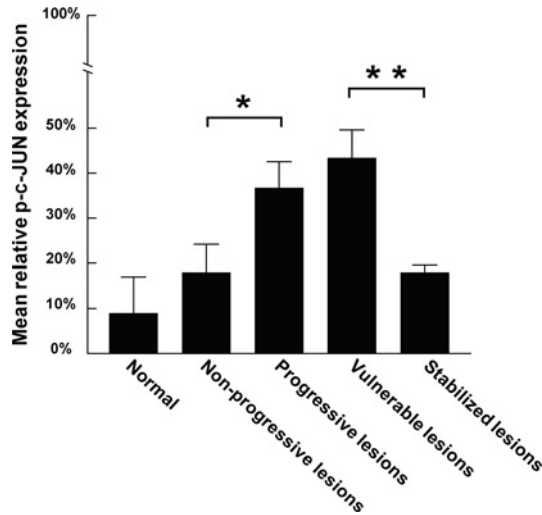


Figure 2 Phospho-c-Jun expression within the various atherosclerotic lesions

There was minimal phospho-c-Jun (p-c-JUN) expression within the endothelial cells and SMCs of the normal aortic wall. This expression increased gradually during the development of atherosclerosis. Activation of phospho-c-Jun increased significantly from non-progressive to progressive lesions (* $P < 0.044$). No significant difference was found between progressive and vulnerable lesions ($P < 0.48$). The expression of phospho-c-Jun diminished as the lesion stabilized (** $P < 0.016$) and did not significantly differ from the normal aortic wall ($P < 0.33$). Values are means \pm S.E.M. For the detailed qualification scale, see the Materials and methods section.

Figures 1 and 2). AP-1-regulated PAI-1 gene expression showed a distribution parallel to the activated AP-1 expression, with a significant increase in the progressive lesions ($P < 0.002$; Figure 3).

Doxycycline intervention

A total of 15 patients were enrolled in the study. One patient experienced photosensitivity reaction and withdrew from the study. No other adverse events occurred. Two subjects were lost to follow up for reasons that were not study related. The mean age of the participants was 67 ± 8 years and 82% were male. All characteristics were assessed just prior to the start of the study (Table 2). Evaluation of systemic markers of inflammation (hs-CRP, IL-6, IL-8 and fibrinogen) only revealed a borderline significant decrease in plasma hs-CRP concentration after doxycycline treatment ($-0.51 \mu\text{g/ml}$, $P = 0.050$; Table 3). Endothelial cell activation markers (ICAM, vWF and PAI-1) were not influenced by the treatment (Table 3).

healed atherosclerotic ruptures was a remarkable difference in phospho-c-Jun expression between the SMCs in the remnants of the old cap and the newly formed cap (E). Fibrotic calcified lesions were mostly acellular and minimally expressed phospho-c-Jun (F). +, phospho-c-Jun-positive SMC; -, phospho-c-Jun-negative SMC; <, phospho-c-Jun-positive monocyte or macrophage.

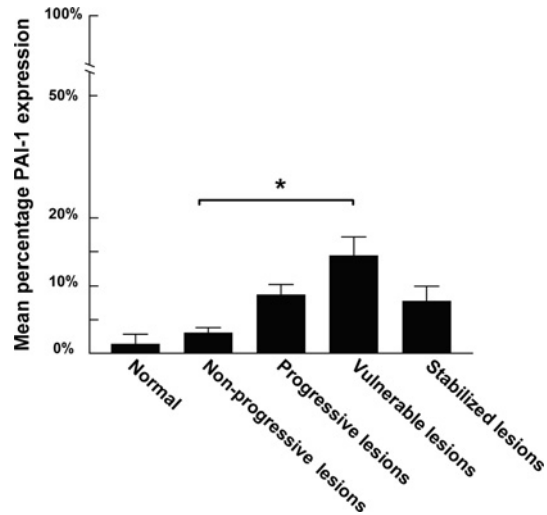


Figure 3 PAI expression within the observed lesion in relation to the atherosclerotic stage

There is a significant increase in PAI expression when atherosclerosis evolves from a non-progressive lesion into a vulnerable lesion (* $P < 0.002$). Values are means \pm S.E.M. For the detailed qualification scale and an overview of the various atherosclerotic clusters, see the Materials and methods section.

Table 2 Patient characteristics

Values are means (S.D.), $n = 12$. BMI, body mass index; DM, diabetes mellitus; TAG, triacylglycerol.

Characteristic	
Age (years)	67 (8)
Male gender	82%
BMI (kg/m^2)	25.0 (5.0)
Smoking (%)	100
DM (%)	0.0
Total cholesterol (mmol/l)	4.37 (0.85)
TAG (mmol/l)	1.62 (1.62)
HDL (mmol/l)	1.26 (0.50)
Glucose (mmol/l)	5.95 (0.54)
Brachial artery diameter (mm)	3.8 (0.6)

In addition to the circulating inflammatory and endothelial cell activation markers, we also assessed flow-mediated vasodilation as a functional test of endothelial function. Flow-mediated vasodilation (baseline value, 13.2%) and NTG-mediated vasodilation (baseline value, 11.3%) were not influenced by doxycycline treatment [-5.9% (-14.9 to 3.9), $P = 0.10$; and -5.4% (-16.4 to 0.7), $P = 0.18$; values are medians (25th to 75th percentiles)] (Table 3).

DISCUSSION

Modulation of chronic vascular inflammation is now considered the most promising complementary strategy for the prevention of incident CVD. Typically, this

Table 3 Markers of inflammation and vascular function

Values are medians (25th–75th percentile), $n = 12$. Doxycycline – placebo represents the difference between the doxycycline treatment and the placebo treatment. $P < 0.05$ for doxycycline–placebo. ND, non-detectable; concentration below the detection limit of the assay (<20 pg/ml).

Parameter	Baseline	Doxycycline – placebo	<i>P</i>
Circulating markers			
hs-CRP ($\mu\text{g/ml}$)	2.21 (1.28–5.20)	– 0.51 (– 6.46 to 0.04)*	0.05
Fibrinogen (mg/ml)	5.38 (3.89–6.23)	– 1.12 (– 0.53 to 3.00)	0.18
IL-6 (pg/ml)	1.80 (0.92–2.03)	– 0.11 (– 1.38 to 2.54)*	0.33
IL-8 (pg/ml)	4.28 (3.24–7.74)	0.68 (– 1.38 to 2.54)	0.53
MCP-1 (pg/ml)	ND	–	–
ICAM-1 (102 ng/ml)	1.88 (1.37–2.17)	– 0.13 (– 0.36 to 0.34)	0.35
vWF (% HPP)	149.6 (114.3–164.5)	– 16.8 (– 58.9 to 27.6)	0.58
PAI-1 (ng/ml)	34.4 (26.2–49.7)	4.6 (– 20.5 to 46.1)	0.58
Dilation			
Flow-mediated (%)	13.2 (6.9–16.4)	– 5.9 (– 14.1 to 3.9)	0.10
NTG-mediated (%)	11.3 (8.8–25.1)	– 5.4 (– 16.4 to 0.7)	0.18

*Exclusion of a patient in the placebo arm with elevated levels of hs-CRP and IL-6 due to infection.

strategy will focus on patients with clinical or subclinical atherosclerosis, i.e. those with progressive atherosclerotic lesions. On the basis of animal studies, the AP-1 pro-inflammatory pathway has been implicated in the initiation and progression of atherosclerotic disease. Up-regulation of AP-1 in rabbits increased with age-related vascular SMC proliferation [18,19] and in rats AP-1 mediated AngII (angiotensin II)-induced inflammation [20]. Additionally, it has been shown that AP-1 deficiency protects against the development of atherosclerosis in hypercholesterolemic mice [5]. In humans, AP-1 was activated in progressive and unstable atherosclerotic plaques and proposed as a switch for inflammatory tissue response and repair [21,22].

Consequently, these studies imply AP-1 as a reasonable target for complementary therapeutic strategies, but its potential role in human atherosclerosis remains unclear.

Our histological analysis shows a gradual increase in the activation of the AP-1 system during the development of atherosclerotic disease, from normal up to progressive atherosclerotic lesions. Remarkably, further transition from progressive to vulnerable lesion types is not associated with significant increase of AP-1 activation. This ‘plateau phase’ of activation clearly diminishes in the fibrotic calcified stabilized plaques. The extent of activation of the AP-1 system is paralleled by a shift in activated cell types, from mainly endothelial cells in normal tissue to predominantly vascular SMCs in advanced atherosclerotic lesions. Accordingly, these observations suggest that AP-1 activation is an early event in human atherosclerotic disease and that it is not prominently involved in further progression of the disease (advanced atherosclerosis and its complications).

In order to further test or refute a possible role of AP-1 activation in the perpetuation of advanced

atherosclerosis, we performed an intervention study with doxycycline in a group of patients with PAD. The presence of PAD identifies patients with systemic atherosclerosis at a high risk of cardiovascular events, as reflected by general endothelial dysfunction and a high incidence of myocardial infarction and stroke [13,14]. This endothelial impairment is related to the severity of the circulatory failure in the affected limb and with increased plasma markers of inflammation [23], and is a potentially reversible manifestation of progressive vascular disease [24,25]. Flow- and NTG-mediated vasodilation of the brachial artery are especially suitable to detect changes in endothelial functioning and have been reported as a widely used research tool and a marker of cardiovascular atherosclerosis [13,26,27].

Independent of their antibiotic properties, doxycycline and other members of the tetracycline family of antibiotics have been recognized as potent anti-inflammatory and immunomodulating agents [28–31]. Sub-antimicrobial doses of doxycycline are now registered for the treatment of active periodontitis and rosacea [32,33]. *In vitro* studies have shown that the effects are (in part) related to an effect on the AP-1 inflammatory pathway. In fact, doxycycline appeared equally effective as the established AP-1 inhibitor SP600125 [7].

Doxycycline is safe and has an excellent tissue penetration [34,35], making it a suitable candidate for clinical studies. We previously studied the effects of 2 weeks of perioperative doxycycline treatment on vascular inflammation in AAA, and found that doxycycline has a profound but selective effect on vascular inflammation, as indicated by a clear reduction in aortic wall IL-6 and IL-8 levels, and a respective 75 % and 96 % reduction in aortic wall neutrophil and cytotoxic T-cell content. Further evaluation showed that this effect

is mediated by a selective reduction in AP-1 activation (measured by phospho-c-Jun) [8]. Baseline AP-1 (non-phosphorylated c-Jun) levels were not influenced by doxycycline treatment. As such these clinical findings corroborate the *in vitro* findings of Kim et al. [7], and we thus hypothesized that doxycycline provides a means of modulating AP-1 activation in atherosclerosis.

Despite the clear effects in aneurysmal disease, we did not observe any effect on each of the markers studied in the atherosclerotic patients. It is unlikely that failure of the intervention reflects a pharmacokinetic limitation. Our studies in AAA show that a brief period of 2 weeks (i.e. one half of the treatment period in this study) suffices for a profound effect. In these studies, we also observed that the effect was already maximal at doses as low as 50 mg. A more likely explanation for the failure of doxycycline in our patients are the profound differences in the inflammatory footprint between aneurysmal disease and atherosclerotic disease, with AP-1 being prominently involved in aneurysmal disease, but to a much lesser extent in advanced atherosclerotic disease [36]. We cannot fully exclude that the negative findings are based on a type II statistical error; however, the study was powered on results from a previous positive study [8]. As of the consistent negative findings for all markers studied and the cross-over design, it is in our opinion unlikely that a larger study would have significantly different results. The study does not support a major role for AP-1 in the initiation and progression of atherosclerosis.

Our results do not exclude that AP-1 inhibition has a beneficial effects in the earliest phases (initiation phase) of the disease. However, given the fact that manifest atherosclerotic disease is present in more than 75 % of male population between 20 and 30 years of age [37], such a treatment should typically be initiated before the age of 20 years, and be maintained throughout the rest of life. We consider such a strategy unrealistic.

Our findings do not exclude a role of AP-1 in complications of atherosclerotic disease such as plaque rupture. It has been suggested before that doxycycline decreases the risk of acute coronary syndromes [38]. Thrombo-occlusive events usually occur in the vulnerable stages of the atherosclerotic process, including plaque rupture and erosion. Plaque rupture is an acute event with inflammatory characteristics distinctive from progressive lesions. Given the presumably acute nature of this process, this will be typically missed in our cross-sectional sample collection.

In conclusion, the response to inhibition of the activated AP-1 system is largely missing in the advanced stages of human atherosclerosis. The results of our intervention seemingly contrast with animal studies, in which AP-1 deficiency in hypercholesterolaemic mice ultimately prevented atherosclerosis. These results, however, apply to the initiation of the atherosclerotic process, whereas human atherosclerotic disease reflects

the advanced (i.e. progressive and vulnerable) stages. This is in line with our systematic evaluation of AP-1 activation in the successive atherosclerotic stages showing that AP-1 activation occurs early in the process and is not related to advanced atherosclerosis and complications. The mere presence of AP-1 in progressive human atherosclerotic tissue is not an indication of the extent of the disease process.

AUTHOR CONTRIBUTION

Arnoud Meijer and Jan Lindeman performed the data analyses and drafted the paper. Pum le Haen and Jan Lindeman designed the clinical study. Arnoud Meijer and Pum le Haen executed the clinical study, which was supervised by Jaap Hamming and Hajo van Bockel. Mitsuhsa Hira performed the laboratory experiments, which were supervised and analysed by Rogier van Dijk. All authors read and approved the final paper.

FUNDING

This study was supported, in part, by The Netherlands Organization for Health Research and Development (ZonMw) [grant number 9510.0108].

REFERENCES

- 1 Ford, I., Murray, H., Packard, C. J., Shepherd, J., Macfarlane, P. W. and Cobbe, S. M. (2007) Long-term follow-up of the West of Scotland Coronary Prevention Study. *N. Engl. J. Med.* **357**, 1477–1486
- 2 De Caterina, R., Massaro, M., Scoditti, E. and Annunziata Carluccio, M. (2010) Pharmacological modulation of vascular inflammation in atherothrombosis. *Ann. N.Y. Acad. Sci.* **1207**, 23–31
- 3 Wang, J., An, F. S., Zhang, W., Gong, L., Wei, S. J., Qin, W. D., Wang, X. P., Zhao, Y. X., Zhang, Y., Zhang, C. and Zhang, M. X. (2011) Inhibition of c-Jun N-terminal kinase attenuates low shear stress-induced atherogenesis in apolipoprotein E-deficient mice. *Mol. Med.* **17**, 990–999
- 4 Muslin, A. J. (2008) MAPK signalling in cardiovascular health and disease: molecular mechanisms and therapeutic targets. *Clin. Sci.* **115**, 203–218
- 5 Osto, E., Matter, C. M., Kouroedov, A., Malinski, T., Bachtschmid, M., Camici, G. G., Kilic, U., Stallmach, T., Boren, J., Iliceto, S. et al. (2008) c-Jun N-terminal kinase 2 deficiency protects against hypercholesterolemia-induced endothelial dysfunction and oxidative stress. *Circulation* **118**, 2073–2080
- 6 Manning, M. W., Cassis, L. A. and Daugherty, A. (2003) Differential effects of doxycycline, a broad-spectrum matrix metalloproteinase inhibitor, on angiotensin II-induced atherosclerosis and abdominal aortic aneurysms. *Arterioscler. Thromb. Vasc. Biol.* **23**, 483–488
- 7 Kim, H. S., Luo, L., Pflugfelder, S. C. and Li, D. Q. (2005) Doxycycline inhibits TGF- β 1-induced MMP-9 via Smad and MAPK pathways in human corneal epithelial cells. *Invest. Ophthalmol. Visual Sci.* **46**, 840–848
- 8 Lindeman, J. H., Abdul-Hussien, H., van Bockel, J. H., Wolterbeek, R. and Kleemann, R. (2009) Clinical trial of doxycycline for matrix metalloproteinase-9 inhibition in patients with an abdominal aneurysm: doxycycline selectively depletes aortic wall neutrophils and cytotoxic T cells. *Circulation* **119**, 2209–2216

- 9 Virmani, R., Kolodgie, F. D., Burke, A. P., Farb, A. and Schwartz, S. M. (2000) Lessons from sudden coronary death: a comprehensive morphological classification scheme for atherosclerotic lesions. *Arterioscler. Thromb. Vasc. Biol.* **20**, 1262–1275
- 10 Keeton, M. R., Curriden, S. A., van Zonneveld, A. J. and Loskutoff, D. J. (1991) Identification of regulatory sequences in the type 1 plasminogen activator inhibitor gene responsive to transforming growth factor β . *J. Biol. Chem.* **266**, 23048–23052
- 11 Lindeman, J. H. N., Pijl, H., Toet, K., Eilers, P. H. C., van Ramshorst, B. and Buijs, M. M. (2007) Human visceral adipose tissue and the plasminogen activator inhibitor type 1. *Int. J. Obes.* **31**, 1671–1679
- 12 van Dijk, R. A., Virmani, R., von der Thüsen, J. H., Schaapheerder, A. F. and Lindeman, J. H. (2010) The natural history of aortic atherosclerosis: a systematic histopathological evaluation of the peri-renal region. *Atherosclerosis* **210**, 100–106
- 13 Criqui, M. H., Langer, R. D., Fronek, A., Feigelson, H. S., Klauber, M. R., McCann, T. J. and Browner, D. (1992) Mortality over a period of 10 years in patients with peripheral arterial disease. *N. Engl. J. Med.* **326**, 381–386
- 14 Gokce, N., Keaney, Jr, J. F., Hunter, L. M., Watkins, M. T., Nedeljkovic, Z. S., Menzoian, J. O. and Vita, J. A. (2003) Predictive value of noninvasively determined endothelial dysfunction for long-term cardiovascular events in patients with peripheral vascular disease. *J. Am. Coll. Cardiol.* **41**, 1769–1775
- 15 Akamatsu, D., Sato, A., Goto, H., Watanabe, T., Hashimoto, M., Shimizu, T., Sugawara, H., Sato, H., Nakano, Y., Miura, T. et al. (2010) Nitroglycerin-mediated vasodilation of the brachial artery may predict long-term cardiovascular events irrespective of the presence of atherosclerotic disease. *J. Atheroscler. Thromb.* **17**, 1266–1274
- 16 Hukshorn, C. J., Lindeman, J. H., Toet, K. H., Saris, W. H., Eilers, P. H., Westerterp-Plantenga, M. S. and Kooistra, T. (2004) Leptin and the proinflammatory state associated with human obesity. *J. Clin. Endocrinol. Metab.* **89**, 1773–1778
- 17 Cheetham, C., O'Driscoll, G., Stanton, K., Taylor, R. and Green, D. (2001) Losartan, an angiotensin type I receptor antagonist, improves conduit vessel endothelial function in Type II diabetes. *Clin. Sci.* **100**, 13–17
- 18 Metzler, B., Hu, Y., Dietrich, H. and Xu, Q. (2000) Increased expression and activation of stress-activated protein kinases/c-Jun NH₂-terminal protein kinases in atherosclerotic lesions coincide with p53. *Am. J. Pathol.* **165**, 1875–1886
- 19 Rivard, A., Principe, N. and Andrés, V. (2000) Age-dependent increase in c-fos activity and cyclin A expression in vascular smooth muscle cells. A potential link between aging, smooth muscle cell proliferation and atherosclerosis. *Cardiovasc. Res.* **45**, 1026–1034
- 20 Chen, Y. and Currie, R. W. (2005) Heat shock treatment suppresses angiotensin II-induced SP-1 and AP-1 and stimulates Oct-1 DNA-binding activity in heart. *Inflamm. Res.* **54**, 338–343
- 21 Chen, F., Eriksson, P., Hansson, G. K., Herzfeld, I., Klein, M., Hansson, L. O. and Valen, G. (2005) Expression of matrix metalloproteinase 9 and its regulators in the unstable coronary atherosclerotic plaque. *Int. J. Mol. Med.* **15**, 57–65
- 22 Hansson, G. K. and Hermansson, A. (2011) The immune system in atherosclerosis. *Nat. Immunol.* **12**, 204–212
- 23 Brevetti, G., Silvestro, A., Di Giacomo, S., Bucur, R., Di Donato, A., Schiano, V. and Scopacasa, F. (2003) Endothelial dysfunction in peripheral arterial disease is related to increase in plasma markers of inflammation and severity of peripheral circulatory impairment but not to classic risk factors and atherosclerotic burden. *J. Vasc. Surg.* **38**, 374–379
- 24 Arcaro, G., Zenere, B. M., Saggiani, F., Zenti, M. G., Monauni, T., Lechi, A., Muggeo, M. and Bonadonna, R. C. (1999) ACE inhibitors improve endothelial function in type 1 diabetic patients with normal arterial pressure and microalbuminuria. *Diabetes Care* **22**, 1536–1542
- 25 Taneva, E., Borucki, K., Wiens, L., Makarova, R., Schmidt-Lucke, C., Luley, C. and Westphal, S. (2006) Early effects on endothelial function of atorvastatin 40 mg twice daily and its withdrawal. *Am. J. Cardiol.* **97**, 1002–1006
- 26 Barth, J. D. (2002) An update on carotid ultrasound measurements of intima-media thickness. *Am. J. Cardiol.* **89**, 32B–39B
- 27 Faulx, M. D., Wright, A. T. and Hoit, B. D. (2003) Detection of endothelial dysfunction with brachial artery ultrasound scanning. *Am. Heart J.* **145**, 943–951
- 28 Ryan, M. E., Ramamurthy, S. and Golub, L. M. (1996) Matrix metalloproteinases and their inhibition in periodontal treatment. *Curr. Opin. Periodontol.* **3**, 85–96
- 29 Bendeck, M. P., Conte, M., Zhang, M., Nili, N., Strauss, B. H. and Farwell, S. M. (2002) Doxycycline modulates smooth muscle cell growth, migration, and matrix remodeling after arterial injury. *Am. J. Pathol.* **160**, 1089–1095
- 30 Soory, M. (2007) Periodontal diseases and rheumatoid arthritis: a coincident model for therapeutic intervention? *Curr. Drug Metab.* **8**, 750–757
- 31 Sapadin, A. N. and Fleischmajer, R. (2006) Tetracyclines: nonantibiotic properties and their clinical implications. *J. Am. Acad. Dermatol.* **54**, 258–265
- 32 Caton, J. and Ryan, M. E. (2011) Clinical studies on the management of periodontal diseases utilizing subantimicrobial dose doxycycline (SDD). *Pharmacol. Res.* **63**, 114–120
- 33 McKeage, K. and Deeks, E. D. (2010) Doxycycline 40 mg capsules (30 mg immediate-release/10 mg delayed-release beads): anti-inflammatory dose in rosacea. *Am. J. Clin. Dermatol.* **11**, 217–222
- 34 Smith, K. and Leyden, J. J. (2005) Safety of doxycycline and minocycline: a systematic review. *Clin. Ther.* **27**, 1329–1342
- 35 Axisa, B., Loftus, I. M., Naylor, A. R., Goodall, S., Jones, L., Bell, P. R. and Thompson, M. M. (2002) Prospective, randomized, double-blind trial investigating the effect of doxycycline on matrix metalloproteinase expression within atherosclerotic carotid plaques. *Stroke* **33**, 2858–2864
- 36 Lindeman, J. H., Abdul-Hussien, H., Schaapheerder, A. F., Van Bockel, J. H., Von der Thüsen, J. H., Roelen, D. L. and Kleemann, R. (2008) Enhanced expression and activation of pro-inflammatory transcription factors distinguish aneurysmal from atherosclerotic aorta: IL-6- and IL-8-dominated inflammatory responses prevail in the human aneurysm. *Clin. Sci.* **114**, 687–697
- 37 Joseph, A., Ackerman, D., Talley, J. D., Johnstone, J. and Kupersmith, J. (1993) Manifestations of coronary atherosclerosis in young trauma victims. An autopsy study. *J. Am. Coll. Cardiol.* **22**, 459–467
- 38 Kardara, M., Papazafropoulou, A., Katsakiori, P., Petropoulos, C. and Jelastopulu, E. (2006) Protective effect of doxycycline use on coronary artery disease? *J. Infect.* **52**, 243–246

Received 5 May 2011 / 7 November 2011; accepted 17 November 2011

Published as Immediate Publication 17 November 2011, doi:10.1042/CS20110234