



Review article

Macular thickness analysis for glaucoma diagnosis and management



Divakar Gupta, Sanjay Asrani*

Department of Ophthalmology, Duke University Eye Center, Durham, NC, USA

ARTICLE INFO

Article history:

Received 25 December 2015

Received in revised form

15 January 2016

Accepted 18 January 2016

Available online 28 February 2016

Keywords:

optical coherence tomography

macular thickness

retinal nerve fiber layer

glaucoma

ABSTRACT

There is increasing literature regarding the role of macular imaging by optical coherence tomography (OCT) in glaucoma care. Spectral domain OCT (SD-OCT) has allowed for high resolution imaging of the total macula and macular segments. With the use of asymmetry analysis, macular thickness is a measurement that can be used for the detection and progression of glaucoma. Some artifacts seen on retinal nerve fiber layer (rNFL) scans may be overcome by macular SD-OCT imaging. Also, nonglaucomatous optic neuropathies may be more easily identified on macular thickness plots than rNFL scans. Special populations, such as children or myopes, may also have improved glaucoma surveillance using macular SD-OCT. In this review we explore the advantages and pitfalls of macular OCT in glaucoma care and offer an approach on how to use macular thickness scans in clinical practice.

Copyright © 2016, The Ophthalmologic Society of Taiwan. Published by Elsevier Taiwan LLC. This is an open access article under the CC BY-NC-ND license (<http://creativecommons.org/licenses/by-nc-nd/4.0/>).

1. Introduction

Glaucoma is a progressive, asymptomatic optic neuropathy resulting in characteristic structural damage and associated visual field loss. In addition to ophthalmoscopy, optic nerve imaging and perimetry are used to aid in the diagnosis and surveillance of glaucoma. Automated perimetry, however, lacks the resolution to detect early glaucomatous damage as greater than 35% of the retinal ganglion cells can be lost before any visual field defects are detected.¹ This observation, that structural changes precede detectable functional deficits, has led to an increased interest in imaging technology.

To date, imaging modalities have analyzed the structure of the optic nerve head (scanning laser ophthalmoscopy) and measured retinal nerve fiber layer thickness (scanning laser polarimetry and optical coherence tomography) to aid in glaucoma diagnosis. In this review, we explore the role of macular thickness by spectral domain–optical coherence tomography (SD–OCT) in glaucoma.

2. Why macular thickness?

Retinal ganglion cells (RGCs) are the cells that die in glaucoma. RGC axons make up the retinal nerve fiber layer (rNFL) and exit the eye through the optic nerve. Progression of glaucomatous optic neuropathy can be seen by increased optic nerve cupping or peripapillary rNFL losses on SD–OCT. Within ~5mm or 16° of the fovea > 50% of RGC bodies reside.² Cell bodies are stacked up to six layers thick.² Thus, small losses of ganglion cell bodies (which along with the rNFL constitutes > 30% of the retinal thickness) are detectable by analyzing total retinal thickness. Total macular thickness is a surrogate measure of tissue thickness loss due to glaucoma in the absence of other macular pathology (which might affect other layers of the retina).

Changes in total macular thickness loss in glaucoma thus reflect the loss of the rNFL, ganglion cell bodies, and the inner plexiform layer (IPL)—tissues that are lost in glaucoma. Total macular thickness (internal limiting membrane to retinal pigment epithelium) is easily and accurately measured by optical reflective devices such as the OCT due to the high level of reflectivity from these two boundary regions of the retina. Earliest measurements of the retinal thickness were performed by the Retinal Thickness Analyzer (Talia Technologies, Neve Ilan, Israel) and subsequently by time domain OCT (Stratus, Carl Zeiss AG, Heidenheim, Germany).^{3–6} The Stratus OCT measured the central 6 mm × 6 mm perifoveal area by acquiring data from six radial line scans intersecting at the fovea and created a map of macular thickness which interpolated the data in between the lines. This strategy of interpolation of data with sparse measurements in a large retinal region did not prove to be

Conflicts of interest: Dr. Gupta has no relevant financial interests, activities, relationships, or affiliations to disclose. Dr. Asrani receives lecture honoraria from Heidelberg Engineering, Inc.

* Corresponding author. Department of Ophthalmology, Duke Eye Center, 2351 Erwin Road, DUMC 3802, Durham, NC 27710, USA.

E-mail address: Sanjay.Asrani@duke.edu (S. Asrani).

<http://dx.doi.org/10.1016/j.tjo.2016.01.003>

2211-5056/Copyright © 2016, The Ophthalmologic Society of Taiwan. Published by Elsevier Taiwan LLC. This is an open access article under the CC BY-NC-ND license (<http://creativecommons.org/licenses/by-nc-nd/4.0/>).

useful in the diagnosis and management of glaucoma compared with the peripapillary RNFL measurements.⁶ Subsequently, SD-OCT permitted the measurements of larger areas of the retina with higher acquisition speed. This provided the ability of measuring retinal thickness with greater concentration of data points, and much less interpolation of data, thus providing a more reliable retinal (macular) thickness map. Different software strategies by different instrument makers are used for this such as a raster of lines or a grid of lines across the macular region.

Recently, software advancements have allowed the automated segmentation of the inner layers of the retina such as rNFL + RGC + IPL, collectively termed as the GCC (Ganglion cell complex). Such a strategy could be very useful in eyes with co-existing pathologies such as diabetic macular edema or age related macular degeneration, in which the total macular thickness is affected but the inner layer thickness changes due to glaucoma can be measured separately.

Various instruments measure different segmented layers such as RGCs + IPL or rNFL + RGC + IPL. Instruments such as the Cirrus (Carl Zeiss AG), RTVue (Optovue Inc., Fremont, CA, USA) and Topcon 3D OCT-2000 (Topcon Medical Systems, Oakland, NJ, USA) measure approximately the central 4–6 mm of the perifoveal area whereas instruments such as the Spectralis (Heidelberg Engineering, Heidelberg, Germany) and RS-3000 Nidek (Nidek Inc., Fremont, CA, USA) measure 9–10 mm of the perifoveal area.

Macular thickness is a highly reproducible measurement on SD-OCT with intravisit and intervisit coefficients of variation of < 1%.^{7–9} Segmented layers, such as ganglion cell-IPL (GC IPL), also show good reproducibility.⁸ High reproducibility thus allows for easier detection of glaucomatous progression.

2.1. Correlations between rNFL thickness, visual fields, and macular thickness

Macular thickness has been shown to correlate both with optic nerve cupping and peripapillary rNFL thickness in glaucoma.^{10,11} Macula thickness losses in glaucomatous eyes have correlated with estimated RGC count and Humphrey Visual Field (HVF) parameters in both glaucomatous and normal eyes.^{4,10,12–14} Peripapillary rNFL scans images a ring of tissue around the optic nerve, whereas, imaging the macula allows for quantification of total macula thickness. This permits the mapping of macula thickness, and thus RGCs, to the visual field for comparison.¹⁵

The traditional 24-2 or 30-2 visual field has relatively few spots dedicated to the macular region and visual field deficits in this area require a greater numbers of ganglion cell loss as compared with the more peripheral retina represented in the visual field.¹⁶ Small losses of macular thickness are thus not detectable on visual field testing, enhancing the potential for detecting early glaucoma using this modality.^{2,17}

3. How to use macular thickness

3.1. Glaucoma diagnosis

Pattern recognition of arcuate losses on macular thickness maps permits early detection of disease. Ganglion cell losses in the perifoveal area are not isolated. They are accompanied by loss of the ganglion cells along the arcuate track of the rNFL extending to the optic nerve (Figure 1).¹⁸

3.2. Glaucoma progression

Continued glaucomatous progression is detected by worsening of existing visual field defects or by development of new visual field

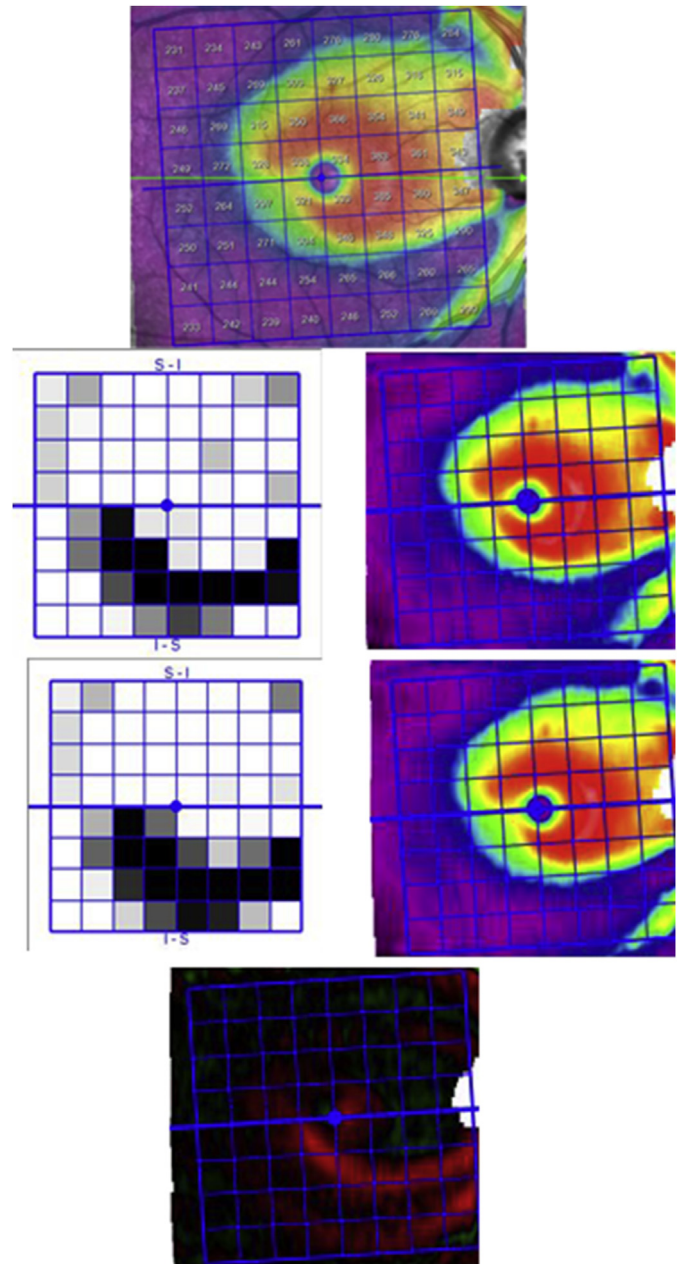


Figure 1. Glaucomatous progression on macular SD-OCT scans. A macular thickness map of the right eye (top) with arcuate thickness loss (inferior) is shown followed by macular thickness maps and superior–inferior hemifield asymmetry plots at two separate visits (middle). The bottom figure is a macula progression (change) map highlighting arcuate retinal thickness losses (red) in the inferior macula between the two patient visits.

losses. Progression detection on macular thickness maps is similarly performed by comparison plots between maps at different time points. Glaucomatous losses are detectable by their arcuate shape in the subtraction maps (Figure 1).

3.3. Asymmetry of macular thickness

Glaucoma is typically a bilateral disease, but frequently asymmetric. A hallmark of glaucoma is that visual field defects respect the horizontal midline, affecting superior or inferior visual field differentially. Visual field deficits are also commonly asymmetric between the two eyes at the time of diagnosis.¹⁹ Structurally,

asymmetry in optic nerve cup-to-disc ratios is also considered concerning for glaucoma. These concepts form the basis for the use of SD-OCT macular thickness maps that compare both intrascan asymmetry (between the superior and inferior macula) and inter-eye asymmetry (between the 2 eyes).^{20,21} As no normative database is yet available for total macular thickness, using internal patient controls to detect asymmetry is a powerful tool. This strategy may be limited in patients with end-stage symmetric disease or with coexisting macular pathology (epiretinal membranes, diabetic macular edema, and macular degeneration).

3.4. Ganglion cell segments

Use of macular RGC + IPL (GCIPL) thickness for glaucoma diagnosis has shown to yield results similar to peripapillary rNFL thickness.²² Macular layer (GCIPL) asymmetry has also been shown to be effective in the diagnosis of early glaucoma.^{23–25} Macular losses of the GCIPL have shown to be correlated with visual field defects.²⁴ Macular GCIPL may also perform better than rNFL in advanced disease.²⁶ Other strategies using macular thickness include measuring extramacular ganglion cell complex thickness or using the ratio of ganglion cell complex to total macular thickness.^{27,28}

4. Artifacts

Artifacts on SD-OCT are common and many of their causes are shared between scans of the peripapillary rNFL and macula.²⁹ Artifacts may result from operator/machine errors as well as coexisting pathologies. Poor signal strength, improper centration, or segmentation errors can lead to artificial increase or decrease in measured thickness. Epiretinal membrane or vitreous adherence can artificially increase the thickness of the rNFL or macula by causing improper identification of the internal limiting membrane. Anterior–posterior vitreous traction, or retinal microcyst formation in rapidly advancing glaucoma may also confound measurements.^{29,30} Inflammatory eye disease (iritis or uveitis) may cause edematous thickening of the macula and rNFL that could also mask retinal ganglion cell loss.³¹

There are some artifacts of SD-OCT rNFL scans that are less prominent on macular scans. For example, nonglaucomatous optic nerve damage or release of vitreous traction may show up as segmental or diffuse rNFL loss making it difficult to detect glaucomatous damage. However, on macular scans arcuate-shaped retinal loss, which is more specific for glaucomatous damage, would allow better detection of glaucomatous damage. In cases of vitreous traction in the peripapillary region (evolving posterior vitreous detachment), the macular thickness may still be a reliable test as it may not be influenced by vitreous traction.

Finally, some pathologies affect macular scans greater than rNFL scans. Macular edema, focal epiretinal membranes, macular degeneration, or atrophy may make macular scans difficult to interpret or use to monitor for glaucomatous progression. The utility of using only unaffected layers/segments, rather than total macula thickness, in cases of coexisting retinal pathologies is not known.

Macular thickness maps may also be helpful in making the diagnosis of nonglaucomatous optic neuropathies.³² Typical patterns of loss such as those seen in hemianopia or in ischemic optic neuropathies are easily detectable on the macular thickness map (Figures 2 and 3).

5. Special populations

The use of SD-OCT in children is attractive as they may be unable to perform reliable visual fields. Macular thickness

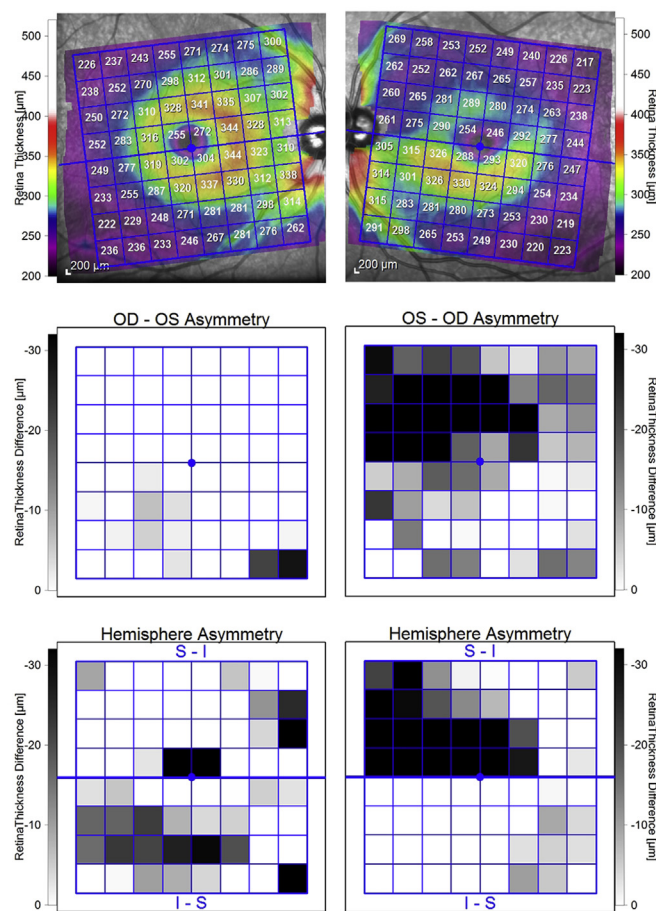


Figure 2. Nonglaucomatous macular thickness loss from nonarteritic ischemic optic neuropathy. Macular thickness plots of the right and left eye are shown. In the middle row right–left (OD-OS and OS-OD) asymmetry plots are shown and in the bottom row superior–inferior hemifield asymmetry plots are shown. These represent both intereye and intrascan differences. Note the losses (seen in black) in the superior macula of the left eye and the relative preservation of macular thickness in the inferior left eye and superior/inferior macula of the right eye. These losses represent altitudinal loss from nonarteritic ischemic optic neuropathy.

measurements have been shown to be lower in children with glaucoma and mirrored the performance of peripapillary rNFL.³³

Myopes present several challenges as they may have nonprogressive visual field changes due to a tilted optic nerve, optic nerve coloboma, or posterior pole staphyloma.³⁴ In addition, peripapillary atrophy, retinal schisis, and vitreous traction results in unreliable rNFL measurements. Macular thickness maps in such eyes have been shown to be useful in glaucoma detection and management.³⁵ Longer axial length is correlated with macular thinning, specifically thinning of the nuclear layers of the macula.³⁶ Macular scans may help in these cases because RGCs are thickest in the macula and progressive disease can still be detected.

6. Conclusion

Macular thickness measurements are an excellent adjuvant modality in glaucoma diagnosis complementing SD-OCT rNFL, perimetry, and optic nerve head examination. They aid in the ability to confirm changes seen on other modalities, and can overcome some of the shortcomings of optic nerve assessment and rNFL measurements. The use of macular scans marks a transition in how structural damage is measured in glaucoma—originally the optic nerve head cup was assessed, then the peripapillary rNFL, and now

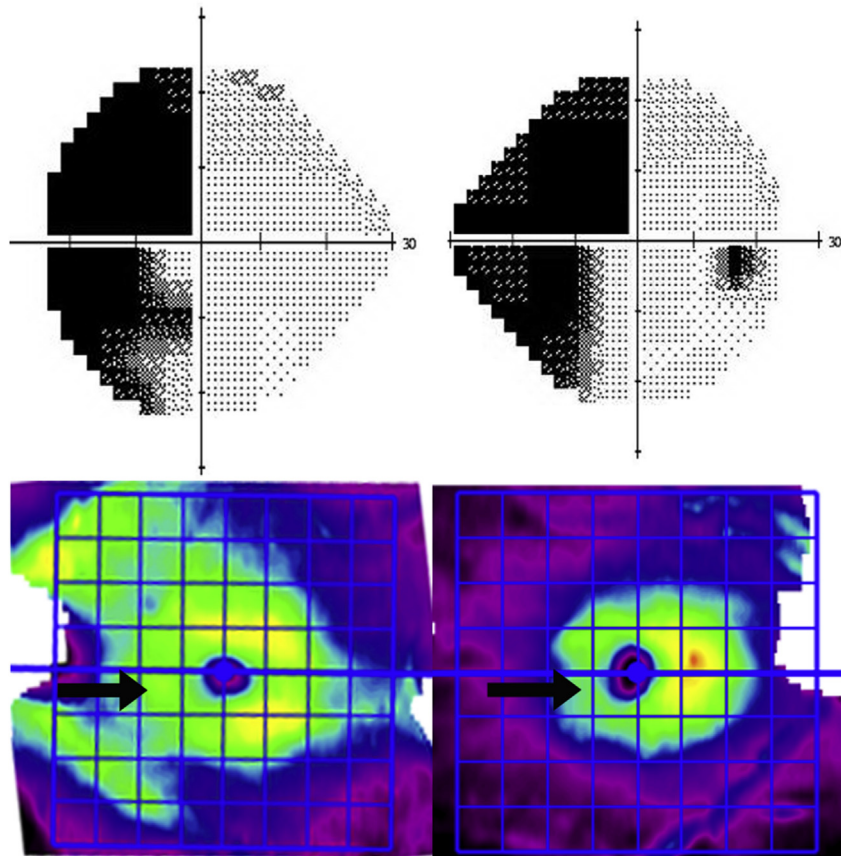


Figure 3. Retrograde loss of macular thickness in a patient with a cerebrovascular accident. A left homonymous hemianopia is shown by visual field testing. Loss of nasal left eye macular thickness and temporal right eye macular thickness is seen below on the macular thickness plots (black arrows). Note these losses respect the vertical (and not horizontal) axis of the fovea. Also the temporal left eye macula and nasal right eye macula are still preserved (seen as yellow on the macular thickness plots).

the macula. There are instances where macular scans and macular segment analysis may be erroneous due to operator/machine factors or other coexisting retinal pathology. More studies are needed to optimize the role of macular SD-OCT in glaucoma care.

References

- Kerrigan-Baumrind LA, Quigley HA, Pease ME, Kerrigan DF, Mitchell RS. Number of ganglion cells in glaucoma eyes compared with threshold visual field tests in the same persons. *Invest Ophthalmol Vis Sci.* 2000;41:741–748.
- Curcio CA, Allen KA. Topography of ganglion cells in human retina. *J Comp Neurol.* 1990;300:5–25.
- Asrani S, Zeimer R, Goldberg MF, Zou S. Application of rapid scanning retinal thickness analysis in retinal diseases. *Ophthalmology.* 1997;104:1145–1151.
- Zeimer R, Asrani S, Zou S, Quigley H, Jampel H. Quantitative detection of glaucomatous damage at the posterior pole by retinal thickness mapping. A pilot study. *Ophthalmology.* 1998;105:224–231.
- Zeimer R, Shahidi M, Mori M, Zou S, Asrani S. A new method for rapid mapping of the retinal thickness at the posterior pole. *Invest Ophthalmol Vis Sci.* 1996;37:1994–2001.
- Guedes V, Schuman JS, Hertzmark E, Wollstein G, Correnti A, Mancini R, et al. Optical coherence tomography measurement of macular and nerve fiber layer thickness in normal and glaucomatous human eyes. *Ophthalmology.* 2003;110:177–189.
- Ghasia FF, El-Dairi M, Freedman SF, Rajani A, Asrani S. Reproducibility of spectral-domain optical coherence tomography measurements in adult and pediatric glaucoma. *J Glaucoma.* 2015;24:55–63.
- Kim KE, Yoo BW, Jeoung JW, Park KH. Long-term reproducibility of macular ganglion cell analysis in clinically stable glaucoma patients. *Invest Ophthalmol Vis Sci.* 2015.
- Ng DS, Gupta P, Tham YC, Peck CF, Wong TY, Ikram MK, et al. Repeatability of perimacular ganglion cell complex analysis with spectral-domain optical coherence tomography. *J Ophthalmol.* 2015;2015:605940.
- Asrani S, Challa P, Herndon L, Lee P, Stinnett S, Allingham RR. Correlation among retinal thickness, optic disc, and visual field in glaucoma patients and suspects: a pilot study. *J Glaucoma.* 2003;12:119–128.
- Oli A, Joshi D. Can ganglion cell complex assessment on cirrus HD OCT aid in detection of early glaucoma? *Saudi J Ophthalmol.* 2015;29:201–204.
- Mathers K, Rosdahl JA, Asrani S. Correlation of macular thickness with visual fields in glaucoma patients and suspects. *J Glaucoma.* 2014;23:e98–e104.
- Zhang C, Tatham AJ, Weinreb RN, Zangwill LM, Yang Z, Zhang JZ, et al. Relationship between ganglion cell layer thickness and estimated retinal ganglion cell counts in the glaucomatous macula. *Ophthalmology.* 2014;121:2371–2379.
- Araie M, Saito H, Tomidokoro A, Murata H, Iwase A. Relationship between macular inner retinal layer thickness and corresponding retinal sensitivity in normal eyes. *Invest Ophthalmol Vis Sci.* 2014;55:7199–7205.
- Hood DC, Raza AS. Method for comparing visual field defects to local RNFL and RGC damage seen on frequency domain OCT in patients with glaucoma. *Biomed Opt Express.* 2011;2:1097–1105.
- Garway-Heath DF, Caprioli J, Fitzke FW, Hitchings RA. Scaling the hill of vision: the physiological relationship between light sensitivity and ganglion cell numbers. *Invest Ophthalmol Vis Sci.* 2000;41:1774–1782.
- Wang DL, Raza AS, de Moraes CG, Chen M, Alhadeff P, Jarukatsetphorn R, et al. Central glaucomatous damage of the macula can be overlooked by conventional OCT retinal nerve fiber layer thickness analyses. *Transl Vis Sci Technol.* 2015;4:4.
- Asrani SG, Singh IP. Three-dimensional nature of retinal nerve fiber layer defects. *J Glaucoma.* 2010;19:592–597.
- Poinoosawmy D, Fontana L, Wu JX, Bunce CV, Hitchings RA. Frequency of asymmetric visual field defects in normal-tension and high-tension glaucoma. *Ophthalmology.* 1998;105:988–991.
- Asrani S, Rosdahl JA, Allingham RR. Novel software strategy for glaucoma diagnosis: asymmetry analysis of retinal thickness. *Arch Ophthalmol.* 2011;129:1205–1211.
- Um TW, Sung KR, Wollstein G, Yun SC, Na JH, Schuman JS. Asymmetry in hemifield macular thickness as an early indicator of glaucomatous change. *Invest Ophthalmol Vis Sci.* 2012;53:1139–1144.
- Mwanza JC, Durbin MK, Budenz DL, Sayyad FE, Chang RT, Neelakantan A, et al. Glaucoma diagnostic accuracy of ganglion cell-inner plexiform layer thickness: comparison with nerve fiber layer and optic nerve head. *Ophthalmology.* 2012;119:1151–1158.
- Hwang YH, Ahn SI, Ko SJ. Diagnostic ability of macular ganglion cell asymmetry for glaucoma. *Clin Experiment Ophthalmol.* 2015;43:720–726.

24. Jeong JS, Kang MG, Kim CY, Kim NR. Pattern of macular ganglion cell-inner plexiform layer defect generated by spectral-domain OCT in glaucoma patients and normal subjects. *J Glaucoma*. 2015;24:583–590.
25. Kim YK, Yoo BW, Kim HC, Park KH. Automated detection of hemifield difference across horizontal raphe on ganglion cell-inner plexiform layer thickness map. *Ophthalmology*. 2015;122:2252–2260.
26. Kim KE, Park KH, Jeoung JW, Kim SH, Kim DM. Severity-dependent association between ganglion cell inner plexiform layer thickness and macular mean sensitivity in open-angle glaucoma. *Acta Ophthalmol*. 2014;92:e650–e656.
27. Morooka S, Hangai M, Nukada M, Nakano N, Takayama K, Kimura Y, et al. Wide three-dimensional macular ganglion cell complex imaging with spectral-domain optical coherence tomography in glaucoma. *Invest Ophthalmol Vis Sci*. 2012;53:4805–4812.
28. Kita Y, Kita R, Takeyama A, Takagi S, Nishimura C, Tomita G. Ability of optical coherence tomography-determined ganglion cell complex thickness to total retinal thickness ratio to diagnose glaucoma. *J Glaucoma*. 2013;22:757–762.
29. Asrani S, Essaid L, Alder BD, Santiago-Turla C. Artifacts in spectral-domain optical coherence tomography measurements in glaucoma. *JAMA Ophthalmol*. 2014;132:396–402.
30. Wen JC, Freedman SF, El-Dairi MA, Asrani S. Microcystic macular changes in primary open-angle glaucoma. *J Glaucoma*. 2014.
31. Moore DB, Jaffe GJ, Asrani S. Retinal nerve fiber layer thickness measurements: uveitis, a major confounding factor. *Ophthalmology*. 2015;122:511–517.
32. Rosdahl JA, Asrani S. Glaucoma masqueraders: diagnosis by spectral domain optical coherence tomography. *Saudi J Ophthalmol*. 2012;26:433–440.
33. Hess DB, Asrani SG, Bhide MG, Enyedi LB, Stinnett SS, Freedman SF. Macular and retinal nerve fiber layer analysis of normal and glaucomatous eyes in children using optical coherence tomography. *Am J Ophthalmol*. 2005;139:509–517.
34. Doshi A, Kreidl KO, Lombardi L, Sakamoto DK, Singh K. Nonprogressive glaucomatous cupping and visual field abnormalities in young Chinese males. *Ophthalmology*. 2007;114:472–479.
35. Nakanishi H, Akagi T, Hangai M, Kimura Y, Suda K, Kumagai KK, et al. Sensitivity and specificity for detecting early glaucoma in eyes with high myopia from normative database of macular ganglion cell complex thickness obtained from normal nonmyopic or highly myopic Asian eyes. *Graefes Arch Clin Exp Ophthalmol*. 2015;253:1143–1152.
36. Szigeti A, Tátrai E, Varga BE, Szamosi A, DeBuc DC, Nagy ZZ, et al. The effect of axial length on the thickness of intraretinal layers of the macula. *PLoS ONE*. 2015;10:e0142383.