

Small-Bore Needle Arthroscopic Extensor Carpi Radialis Brevis Release Results in Improved Outcomes at One Year Postoperatively



Wyatt Daniel Vander Voort, M.D., Maarouf Saad, M.D., David Falgout, M.D., Theodore A. Blaine, M.D., and Hafiz F. Kassam, M.D.

Purpose: To evaluate outcomes of patients who underwent small-bore needle arthroscopic extensor carpi radialis brevis (ECRB) release for the management of recalcitrant lateral epicondylitis. **Methods:** Patients who underwent elbow evaluation and ECRB release using a small-bore needle arthroscopy system were included in this study. Thirteen patients were included. Quick Disabilities of the Arm Shoulder and Hand and Single Assessment Numerical Evaluation scores, as well as overall satisfaction scores, were collected. A 2-tailed paired *t*-test was conducted to assess the statistical significance of the differences observed between preoperative and 1-year postoperative scores with significance set at $P < .05$. **Results:** There was a statistically significant improvement in both outcome measures ($P < .001$) and a 92.3% satisfaction rate with no significant complications at a minimum 1-year follow-up. **Conclusions:** Patients with recalcitrant lateral epicondylitis treated with ECRB release using needle arthroscopy demonstrated significantly improved Quick Disabilities of the Arm Shoulder and Hand and Single Assessment Numerical Evaluation scores postoperatively, without complications. **Level of Evidence:** IV, retrospective case series.

Studies report improved clinical outcomes as well as expedited return to work following arthroscopic approaches to extensor carpi radialis brevis (ECRB) release. A retrospective comparative study completed by Peart et al.¹ showed a statistically significant decrease in time to return to work in patients treated arthroscopically. One prospective, randomized control trial showed that patients managed with minimally invasive

techniques returned to work on average 3 weeks earlier than those who underwent open debridement.² In addition, there were greater rates of patient satisfaction, Disability of Arm, Shoulder, and Hand (DASH) scores, and improved ability to return to sporting activities in this group.²

Elbow arthroscopy has provided a means for ECRB tendon debridement that spares an open approach to the elbow. This technique allows for adequate visualization of the ECRB tendon at its origin on the lateral epicondyle of the humerus with the additional benefit of visualizing and addressing intra-articular pathologies simultaneously. The operation can be performed with the patient in the prone, lateral, or supine position, and neurovascular structures are protected by injecting saline solution into the joint, thereby displacing these structures from future portal sites. A proximal–medial portal is initially established and is then used for visualization. The superior lateral working portal is then created under direct visualization and allows for the introduction of a motorized shaver or ablator to perform the ECRB tendon release.^{3,4} More recently, needle arthroscopy (NA) has gained traction as a diagnostic and therapeutic tool with the proposed benefits of minimizing disruption to soft tissues and risk to neurovascular structures. Within the elbow, the smaller

From the UC Davis Medical Center, Sacramento, California (W.D.V.V., M.S.); Hoag Orthopedic Institute, Irvine, California (D.F., H.F.K.); and Hospital for Surgery, New York, New York (T.A.B.), U.S.A.

The authors report the following potential conflicts of interest or sources of funding: T.A.B. reports personal fees and other from Catalyst, Zimmer Biomet, and Stryker, outside the submitted work. H.F.K. reports personal fees from DePuy Synthes and Catalyst OrthoScience other from Zimmer Biomet, and personal fees from Smith & Nephew, outside the submitted work. Full ICMJE author disclosure forms are available for this article online, as supplementary material.

Received May 2, 2021; revised manuscript received October 22, 2022; accepted November 8, 2022.

Address correspondence to Hafiz F. Kassam, M.D., 22 Corporate Plaza, Newport Beach, CA 92670. E-mail: hafizkassam@gmail.com

© 2022 THE AUTHORS. Published by Elsevier Inc. on behalf of the Arthroscopy Association of North America. This is an open access article under the CC BY-NC-ND license (<http://creativecommons.org/licenses/by-nc-nd/4.0/>). 2666-061X/22553

<https://doi.org/10.1016/j.asmr.2022.11.007>

camera size (2 mm) and weight of the tools allow for a minimally invasive and percutaneous approach, thereby potentially minimizing the risk of damage to adjacent neurovascular structures including the median, median antebrachial cutaneous, ulnar, and radial nerves as well the brachial artery. In addition, the inflow sheath results in decreased arthroscopic fluid use, which may reduce postoperative swelling and pain and lead to improved short-term recovery and patient satisfaction. Less fluid use also results in less overall soft-tissue extravasation. Excessive soft-tissue swelling due to arthroscopy fluid is a common limiting factor to the time many surgeons will allot for arthroscopy, and the decreased fluid use in NA, theoretically, increases the maximum time allowance for these technically difficult cases.⁵ This study aimed to evaluate outcomes of patients who underwent small-bore nano arthroscopic ECRB release for the management of recalcitrant lateral epicondylitis. We hypothesized that this treatment method would result in good postoperative outcomes and high patient satisfaction.

Methods

Study Design

Patients who underwent NA with ECRB between January 2019 and June 2020 were identified. Local institutional review board approval was obtained. Inclusion criteria included a clinical diagnosis of lateral epicondylitis with refractory pain for greater than 6 months despite nonoperative measures including activity modification, oral nonsteroidal anti-inflammatories, at least 6 weeks of formal therapy, and bracing, as well as availability for the final 1-year follow-up. Quick Disabilities of the Arm Shoulder and Hand (qDASH) scores and Single Assessment Numerical Evaluation (SANE) scores were collected preoperatively and 1-year postoperatively. Patients also were asked if they were satisfied with their decision to proceed with surgery and their responses were collected. Demographic information was collected through the electronic medical record.

Surgical Technique

Patient Positioning, Equipment, and Setup

The patient may be positioned in the lateral decubitus or prone position. The authors recommend the lateral decubitus position with the patient leaning slightly forward to allow intraoperative elbow flexion. An arm holder supports the proximal humerus, allowing the elbow to rest at approximately 90°. A tourniquet is applied but not always inflated.

The NA set (NanoScope; Arthrex Inc., Naples, FL) includes a zero-degree arthroscope with power cord, monitor, and sharp and blunt trochars with corresponding sheaths including inflow portals. Assorted

instruments, including a retractable probe and a 2.0-mm shaver, are also available (Fig 1). Using a sterile technique, the cords are attached, and the monitor can be relayed to overhead monitors in the operating room via a standard HDMI cable.

Anatomical Landmarks, Portal Locations, and Insufflation

The olecranon, medial epicondyle, lateral epicondyle, and ulnar nerve are identified and marked, as well as the following described portals (Fig 2). For access to the anterior elbow, a modified proximal anteromedial portal (mPAMP), proximal anterolateral portal (PALP), mid-anterolateral portal (MALP), and distal anterolateral portal (DALP) are used. The mPAMP is used as the primary viewing portal and is located 0.5 to 1 cm proximal to the medial epicondyle and immediately anterior to the intermuscular septum. This is a modification of the classic PAMP position, which is located 2 cm proximal to the medial epicondyle and anterior to the intermuscular septum. This modification allows for a better inline view of the entire joint and is necessary due to the zero-degree viewing angle of the NA camera. Despite moving the portal slightly more distal, the decreased size of the NA camera sheath (2 mm vs 4-5 mm) makes injury to the median antebrachial cutaneous nerve unlikely. The PALP functions as the inflow portal and is located 2 cm proximal to the lateral epicondyle and 1 cm anterior to the humerus. The MALP is the primary working portal and provides direct inline access to the joint. It is located 1 cm proximal and 1 cm anterior to the lateral epicondyle. The DALP is used as an accessory working portal and is located 1 to 2 cm distal and 1 cm anterior to the lateral epicondyle, just anterior to the radial head.

Access to the posterior elbow is achieved with a transtriceps portal (TTP), the posterolateral portal (PLP), and accessory posterolateral portal. The TTP is

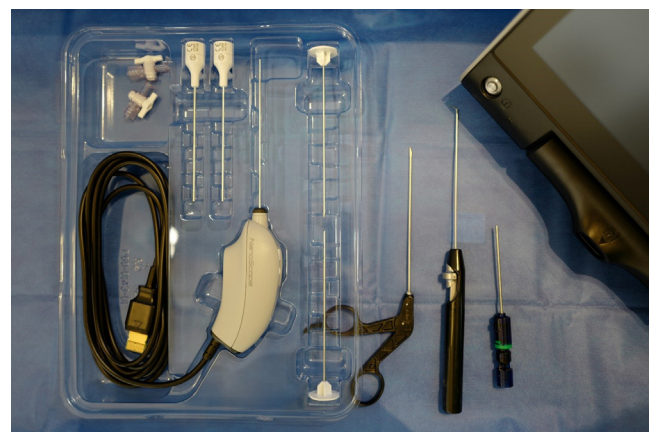
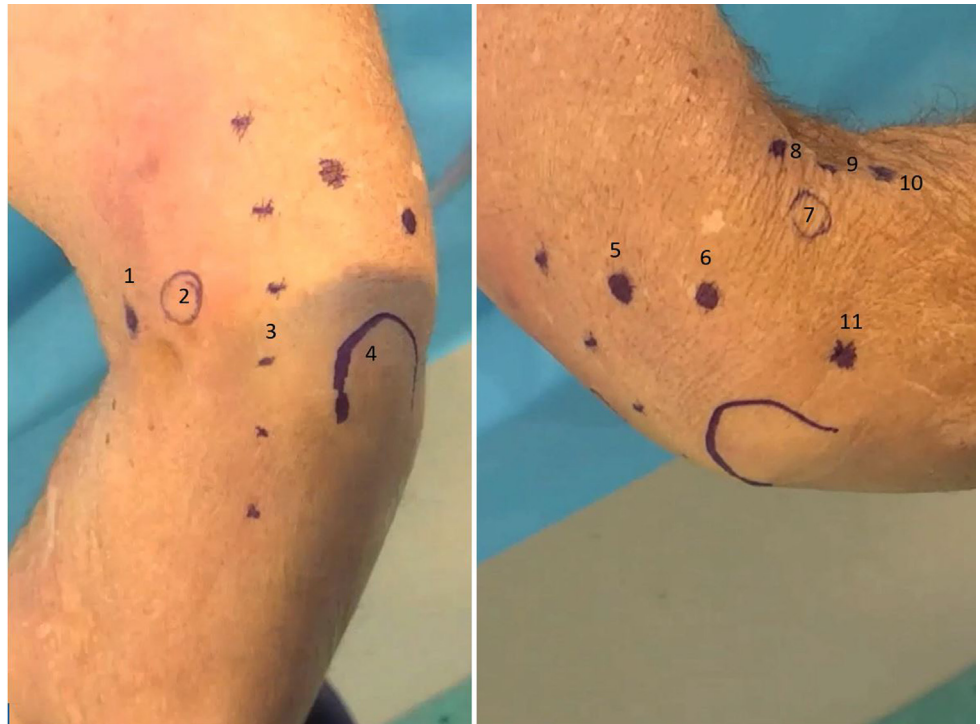

Fig 1. Setup of a Nano Arthroscopy Set (Arthrex, Naples, FL) with associated small joint instrumentation.

Fig 2. Left, Medial external view of a right elbow in the lateral decubitus position. 1 – modified proximal anteromedial portal (mPAMP), 2 – medial epicondyle, 3 – ulnar nerve, and 4 – olecranon. Right, Lateral external view of a right elbow in the lateral decubitus position. 5 – transtriceps portal (TTP), 6 – posterolateral portal (PLP), 7 – lateral epicondyle, 8 – proximal anterolateral portal (PALP), 9 – mid-anterolateral portal (MALP), 10 – distal anterolateral portal (DALP), and 11 – soft-spot portal.



the primary viewing portal and is located 3 cm proximal to the tip of the olecranon through the triceps tendon. The PLP is used as an inflow portal and is located 1.5 cm proximal to the olecranon and just lateral to the triceps tendon. The accessory posterolateral portal is a working portal and is located 0.5 to 1 cm proximal to the PLP depending on the angle of approach needed for instrumentation.

Insufflation is achieved through the “soft-spot” portal located at the center of a triangle connecting the olecranon tip, lateral epicondyle, and radial head. Before arthroscopy begins, approximately 15 to 20 mL of normal saline is injected with an 18-gauge spinal needle into the soft spot portal to achieve joint insufflation.

Anterior Compartment Arthroscopy

Diagnostic NA begins with the introduction of the needle arthroscope into the mPAMP. Using a NA sheath with sharp trochar, the sheath is introduced through the skin and into the joint space. The trochar is removed and the NA camera is inserted into the sheath. Upon insertion of the camera, the visualization should be possible as the result of previous insufflation. If necessary, inflow tubing can be attached to the camera sheath and the camera can be temporarily removed to assist in fluid delivery and visualization of the joint. Under direct visualization, a second sheath with sharp trochar is introduced into the joint through the PALP. The trochar is removed and inflow tubing is then

transferred to this sheath, creating a dedicated inflow port. This helps obtain excellent visualization of the joint and can help mitigate flow mismatch. It is important to realize visualization in NA relies more upon controlling flow through a dedicated inflow cannula than upon pump pressure and fluid volume. If required, the inflow sheath can also be used as an anterior capsule retractor.

Once the NA system is established, additional working portals can be made by using the NA sharp trochar (without a sheath). The diameter of the trochar allows for a wide enough percutaneous hole for dedicated NA instrumentation to pass through. The authors recommend the MALP as the primary working portal. The DALP can be created as an accessory working portal as required. Instrumentation can then be inserted, and arthroscopic treatment performed as indicated.

With this approach to the anterior compartment, the radial head and neck, radiocapitellar joint, coronoid fossa, coronoid, and anterior capsule can be easily visualized and accessed with working tools (Fig 3).

Extensor Carpi Radialis Brevis Release

Once the anterior compartment has been visualized, we proceed with the ECRB release. This is similar to traditional arthroscopic techniques. In severe cases, a distinct area of inflammation (Nirschl lesion) confluent with the lateral capsule can be identified. A small joint ablator is introduced through the working portal and

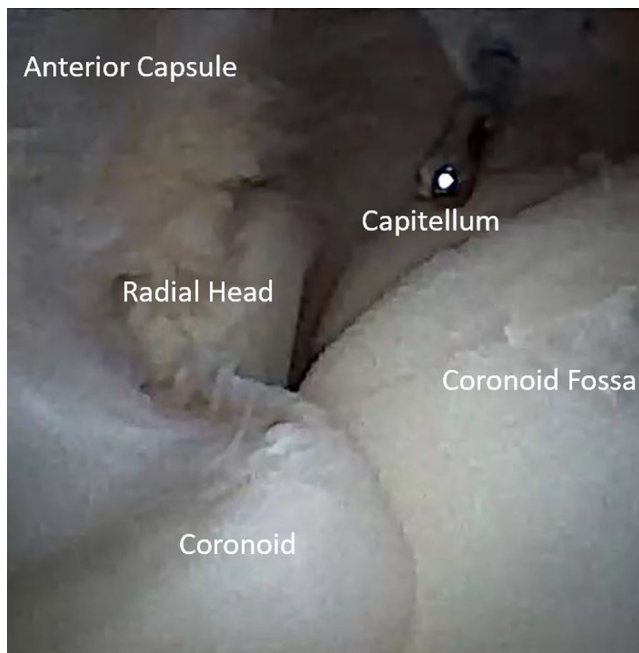


Fig 3. Arthroscopic view, right elbow, lateral decubitus position, from the modified proximal anteromedial portal (mPAMP), which allows direct in-line visualization of key structures. Similarly, the instrument placed through the mid-anterolateral portal (MALP) enables direct in-line access to key structures.

the capsule is released horizontally. Once the ECRB tendon is visualized, a small joint mechanical shaver is introduced to debride the tendon distal to its bony attachment in a triangular shape (Fig 4). The debridement is then carried proximally to the lateral epicondyle where the bony attachment is subsequently debrided as well. Care is taken to remain above the “equator” of the line bisecting the radio-capitellar joint to avoid iatrogenic injury to the lateral collateral ligament complex.

Posterior Compartment Arthroscopy

While not required for an isolated ECRB release, an evaluation of the posterior compartment can be performed to examine the joint completely. The authors recommend routine posterior joint space visualization in these cases as the posterolateral gutter can have concomitant pathology in recalcitrant tennis elbow. Through a standard posterior TTP, visualization of the olecranon tip, medial gutter, and lateral gutter can be easily obtained (Fig 5).

Closure and Postoperative Protocol

NA results in minimal soft-tissue swelling and disruption. The created percutaneous portals do not require sutures (Fig 6). A simple, compressive soft dressing is placed over the elbow after the procedure

and may be removed after 48 to 72 hours. Patients are encouraged to engage in immediate elbow range of motion and typically, non-narcotic medications are sufficient for postoperative pain control.

Statistical Analysis

A 2-tailed paired *t*-test was conducted to assess the statistical significance of the differences observed between preoperative and 1-year postoperative qDASH scores. An identical experiment was conducted to examine the second metric, SANE scores which also were obtained preoperatively and 1-year postoperatively. Significance was set at $P < .05$ for all tests.

Results

A total of 15 patients were identified. Two patients were lost to follow-up, so 13 patients were included in this study. Eight of the patients had received at least 1 corticosteroid injection.

qDASH and SANE Scores

Preoperative and 1-year postoperative qDASH and SANE scores can be viewed in Table 1. One-year postoperative qDASH scores were significantly lower than preoperative scores; $t(12) = 7.640$, $P < .001$. The average sample qDASH score improved by 27.1 points. At a 95% confidence level, we can infer that the average improvement in the population lies between 19.4 and 34.8 points. SANE scores also improved. One-

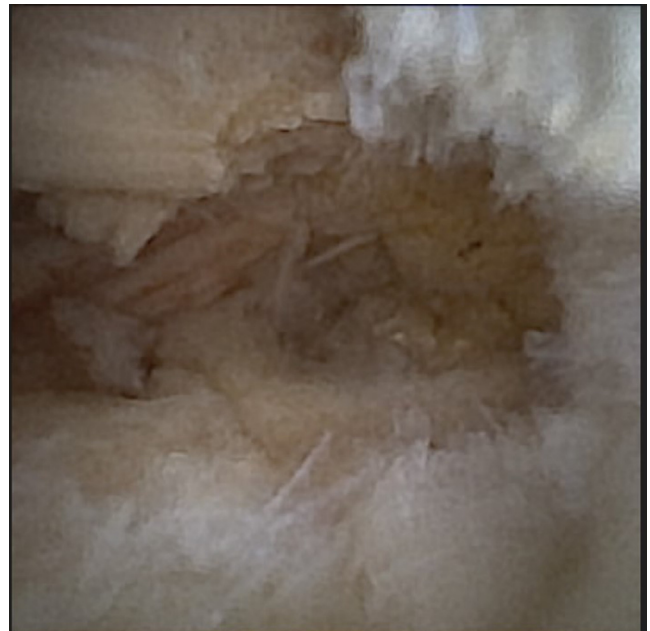


Fig 4. Arthroscopic view, right elbow, lateral decubitus position, from the modified proximal anteromedial portal (mPAMP) showing the excised capsule and completed resection of the affected extensor carpi radialis brevis tissue.



Fig 5. Arthroscopic view, right elbow, lateral decubitus position, from the transtriceps portal (TTP) visualizing the posterior compartment.

year postoperative SANE scores were significantly greater than preoperative scores; $t(12) = |6.657|$, $P < .001$. The average sample SANE score improved by 25 points. At a 95% confidence level, we can infer that the average improvement in the population lies between 16.8 and 33.2 points.

Satisfaction Rate

All but 1 patient (patient 10) reported that they were satisfied with the procedure at 1-year follow-up resulting in a 92.3% satisfaction rate. No major complications were noted postoperatively (infection, neurovascular injury, etc.), with 1 patient developing early stiffness that resolved completely at the final 1-year follow-up.

Discussion

In this study, small-bore nano arthroscopy for the treatment of lateral epicondylitis resulted in improved patient-reported outcomes at the 1-year postoperative time point. Lateral epicondylitis is a common condition encountered in general orthopaedic practice. Fortunately, most patients diagnosed with this condition will experience satisfactory improvement in their symptoms following conservative management. Patients who continue to experience recalcitrant pain following appropriate pharmacological treatment, physical therapy, and occasionally corticosteroid injections are indicated for operative intervention. At present, the options for operative intervention include open versus arthroscopic release of the ECRB tendon, which is effective in

providing a clinically relevant improvement in patient comfort and function post-operatively. Here we have provided an outline for an alternative intervention in the form of NA, a procedure with several potential advantages over the current treatment options. In addition, we have reported the outcomes of this procedure in a cohort of thirteen consecutive patients with appropriate operative indications and found that this group demonstrated both a statistically significant increase in their qDASH and SANE scores at 1-year postoperatively compared with their preoperative scores. We have also shown a 92.3% satisfaction rate.

Previous literature suggests that the minimal clinically important difference for the qDASH for lateral epicondylitis is 15.8.⁶ In the current study, the average improvement in qDASH scores was 27.1. In a retrospective study, López-Alameda et al.⁷ demonstrated no significant difference in qDASH score improvement between open and arthroscopically treated lateral epicondylitis (19.4 vs 19, respectively). Patel et al.⁸ found the mean baseline SANE score to be 41.0 ± 25.6 in patients with lateral epicondylitis. Although no studies reporting on pre- and postoperative SANE scores in lateral epicondylitis patients were identified, the minimal clinically important difference for the SANE for the upper extremity has been reported at 15.⁹ The present study demonstrated an average preoperative SANE score of 50.8 with an average improvement of 25.0. These findings show that in this cohort of appropriately selected patients, surgical intervention in the form of NA results in outcomes comparable with those achieved following the open or traditional arthroscopic release of the ECRB tendon in the treatment of lateral epicondylitis.

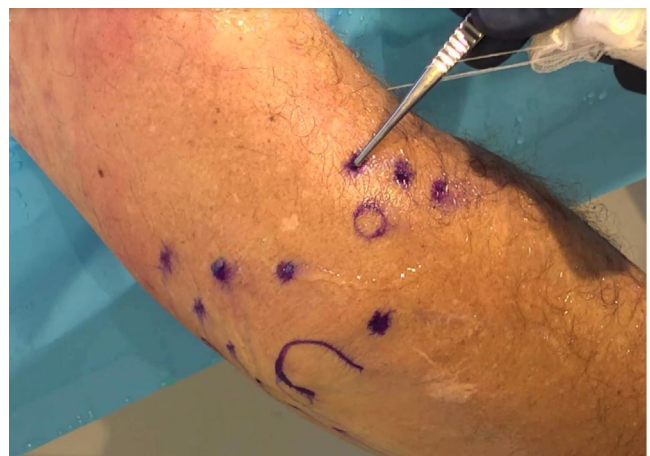

Fig 6. External view of a right elbow in the lateral decubitus position post arthroscopy, demonstrating minimal soft tissue disruption. Portals do not require sutures. A simple compressive soft dressing over the elbow for 48 to 72 hours is usually sufficient for postoperative wound care.

Table 1. Preoperative and 1-Year Postoperative qDASH and SANE Scores

Patient	qDASH Preoperative	qDASH Postoperative	qDASH Difference	SANE Preoperative	SANE Postoperative	SANE Difference
1	43.2	15.9	27.3	60	70	10
2	31.8	18.2	13.6	60	85	25
3	65.9	20.5	45.4	30	75	45
4	59.1	22.7	36.4	45	80	35
5	63.6	20.5	43.1	55	75	20
6	52.3	36.4	15.9	65	75	10
7	47.7	27.3	20.4	60	80	20
8	68.2	29.5	38.7	40	80	40
9	70.5	59.1	11.4	50	60	10
10	36.4	29.5	6.9	55	60	5
11	52.3	27.3	25	40	70	30
12	54.5	25	29.5	50	85	35
13	56.8	18.2	38.6	50	90	40
Average	54.0	26.9	27.1	50.8	75.8	25.0

qDASH, Quick Disabilities of the Arm Shoulder; SANE, Hand and Single Assessment Numerical Evaluation.

Limitations

Although the number of patients included in this study was limited, the improvement in scores postoperatively was large enough to be statistically significant. Another limitation of this study was that NA was performed in an operating room setting, limiting our ability to evaluate outcomes following in-office completion of this procedure.

In addition, there is a learning curve associated with performing nano-arthroscopy, particularly in the elbow, given the need for portal modifications, coping with the zero-degree viewing angle, and smaller instrumentation. It is possible that this may have had an effect on earlier patients in the cohort. This may be mitigated by the fact that the primary surgeon in this study began using elbow nano arthroscopy for diagnostic arthroscopy and gained experience with this before using it for arthroscopic ECRB release. In addition, the actual ECRB release portion of the procedure is purposefully very similar to traditional techniques. This would possibly minimize the learning curve associated with widespread adoption.

Conclusions

Patients with recalcitrant lateral epicondylitis treated with ECRB release using needle arthroscopy demonstrated significantly improved Quick Disabilities of the Arm Shoulder and Hand and Single Assessment Numerical Evaluation scores postoperatively without complications.

References

1. Peart RE, Strickler SS, Schweitzer KM Jr. Lateral epicondylitis: A comparative study of open and arthroscopic lateral release. *Am J Orthop (Belle Mead NJ)* 2004;33:565-567.
2. Dunkow PD, Jatti M, Muddu BN. A comparison of open and percutaneous techniques in the surgical treatment of tennis elbow. *J Bone Joint Surg Br* 2004;86:701-704.
3. Calfee RP, Patel A, DaSilva MF, Akelman E. Management of lateral epicondylitis: Current concepts. *J Am Acad Orthop Surg* 2008;16:19-29.
4. Baker CL Jr, Murphy KP, Gottlob CA, Curd DT. Arthroscopic classification and treatment of lateral epicondylitis: Two-year clinical results. *J Shoulder Elbow Surg* 2000;9:475-482.
5. Peters M, Gilmer B, Kassam HF. Diagnostic and therapeutic elbow arthroscopy using small-bore needle arthroscopy. *Arthrosc Tech* 2020;9:e1703-e1708.
6. Smith-Forbes EV, Howell DM, Willoughby J, Pitts DG, Uhl TL. Specificity of the minimal clinically important difference of the quick Disabilities of the Arm Shoulder and Hand (QDASH) for distal upper extremity conditions. *J Hand Ther* 2016;29:81-88.
7. López-Alameda S, Varillas-Delgado D, De Felipe-Gallego J, González-Granados MG, Hernández-Castillejo LE, García-de Lucas F. Arthroscopic surgery versus open surgery for lateral epicondylitis in an active work population: A comparative study. *J Shoulder Elbow Surg* 2022;31:984-990.
8. Patel MS, Kirsch JM, Gutman MJ, et al. Single assessment numeric evaluation correlates with American Shoulder and Elbow Surgeons score for common elbow pathology: A retrospective cohort study. *Am J Sports Med* 2021;49:2771-2777.
9. Furtado R, MacDermid J. Clinimetrics: Single assessment numeric evaluation. *J Physiother* 2019;65:111.