

# Evaluation the Relationship between Mandibular Molar Root Apices and Mandibular Canal among Residents of the Moscow Population using Cone-Beam Computed Tomography Technique

## Abstract

**Background:** The relationship between the inferior alveolar nerve and the root apices of the mandibular molars and premolars is of clinical importance. The aim of this study was to determine the relationship between the mandibular canal (MC) and the mandibular molar root apices using cone-beam computed tomography (CBCT) scanning among residents of the Moscow population. **Materials and Methods:** Three hundred CBCT scans for patients aged 20–70 years were analyzed. Patients were divided into three age groups: young group (20–44 years), middle-age group (45–59 years), and elderly group (60–70). The distance from the MC and the mandibular molar root apices was measured in each group in the coronal view of CBCT scans. Statistical analysis was set on  $P < 0.05$ . **Results:** The mean distance from the mesial root apices of the first, second, and third molars to the MC was 4.92, 2.85, and 2.24 mm, respectively. The distal root showed to be the closest root to the MC in multirouted teeth. The young age group showed smaller distances to MC than other age groups ( $P < 0.05$ ). Females showed smaller distances to MC in mandibular molars than males ( $P < 0.05$ ). **Conclusions:** The distance between the root apices and the MC has to be taken into consideration when performing surgical or endodontic procedures.

**Keywords:** Cone-beam computed tomography, inferior alveolar nerve, injuries, mandible, molar

## Introduction

The mandibular canal (MC) is an intraosseous duct, begins at the mandibular foramen on the medial surface of the mandibular ramus, curves downward and forward until it becomes horizontal below the apices of the mandibular molars, then it divides in the premolar area in two branches; the incisive canal which continues horizontally to the midline, and the mental canal, which turns upward and opens in the mental foramen. The inferior alveolar nerve (IAN), artery, and vein are located inside this canal.<sup>[1]</sup>

The relationship between the IAN and the root apices of the mandibular molars and premolars is of clinical importance, especially during complex surgical procedures, that involve interfering with the IAN, such as extraction of the mandibular third molar located close to MC which considered a risk factor of IAN injuries,<sup>[2]</sup> or surgical endodontic procedures in the posterior mandible.

These procedures could damage the IAN as a result of its proximity to root apices, and this damage can cause paresthesia or dysesthesia in the region of distribution of the nerve.<sup>[3,4]</sup> The IAN could also be affected during nonsurgical endodontic treatment by mechanical irritation like over instrumentation with endodontic files<sup>[5,6]</sup> or by chemical processes such extrusion of irritants<sup>[7]</sup> or root canal filling materials<sup>[8,9]</sup> or by increasing in temperature proximal to the IAN  $>10$  C.<sup>[10]</sup>

IAN damage occurs frequently between 0.5% and 8% during surgical or endodontic procedures in the posterior mandible.<sup>[11]</sup> For that, clinicians should pay attention to avoid any extrusion of root canal material close to IAN, and before undertaking any procedure that may damage the IAN, it is critical to identify the location of the IAN with respect to the surrounding structures to avoid any injury.<sup>[12]</sup>

A few studies have evaluated the relationship between the MC and the root

Svetlana Razumova,  
Anzhela Brago,  
Ammar Howijieh,  
Haydar Barakat,  
Yuliya Kozlova,  
Nikolay Razumov

Department of Propaedeutics  
of Dental Diseases, Medical  
Institute, Peoples' Friendship  
University of Russia (RUDN  
University), Moscow, Russia

Submitted : 08-Nov-2019  
Revised : 28-Feb-2020  
Accepted : 01-Oct-2020  
Published : 23-Mar-2022

### Address for correspondence:

Dr. Ammar Howijieh,  
117198, Miklukho-Maklaya  
Street, 6, Moscow, Russia.  
E-mail: amarhweje@gmail.com

### Access this article online

Website:  
www.contempclindent.org

DOI: 10.4103/ccd.ccd\_388\_19

### Quick Response Code:



This is an open access journal, and articles are distributed under the terms of the Creative Commons Attribution-NonCommercial-ShareAlike 4.0 License, which allows others to remix, tweak, and build upon the work non-commercially, as long as appropriate credit is given and the new creations are licensed under the identical terms.

For reprints contact: WKHLRPMedknow\_reprints@wolterskluwer.com

**How to cite this article:** Razumova S, Brago A, Howijieh A, Barakat H, Kozlova Y, Razumov N. Evaluation the relationship between mandibular molar root apices and mandibular canal among residents of the moscow population using cone-beam computed tomography technique. *Contemp Clin Dent* 2022;13:3-8.

apices of mandibular teeth using periapical or panoramic radiographs.<sup>[13]</sup> Panoramic radiography is a routine preoperative examination in dentistry; it displays a full view of the dentition and the anatomical structures. However, it could not give an accurate confirmation of the relationship between the anatomical structures and the teeth because of the two-dimensional (2D) image.<sup>[14]</sup>

Recently, cone-beam computed tomographic (CBCT) technique allows to assess the distance between the MC and the mandibular molar root apices in 3D images with high accuracy and high reliability.<sup>[15,16]</sup> The aim of this study was to determine the distance between the MC and the root apices of mandibular molars among residents of the Moscow region.

## Materials and Methods

This cross-sectional study included patients (170 females and 130 males) from those attending the radiologic diagnostic center for CBCT images in Moscow in the period between October 2017 and May 2018. Written consent was signed by all patients. The study protocol was approved by the Ethics Committee in People's Friendship University of Russia (RUDN University).

Patient confidentiality was strictly respected and no personal information was divulged except the age and the sex, whereas patients were divided into three age groups: young age (20–44 years), middle age (45–59 years), and elderly (60–70 years).

CBCT scans were taken by a 3D eXam (Kavo, Biberach, Germany) with standard exposure settings (23 cm × 17 cm field of view, 0.3 mm voxel size, 110 kV, 1.6–20 s) and were analyzed by two endodontic examiners in a semi-dark room using I-CAT viewer software (version 10, Hatfield, England). Inclusion criteria were (1) patients aged 20–70 years and (2) permanent mandibular molars with no periapical lesions. Scans were excluded if a periapical lesion or root resorption was discovered. The mandibular molars were studied in three-plane (sagittal, axial, and coronal) slices. The shorter distance between the root apices and the MC was measured in mm from the closed point of the apices of both roots (distal and mesial roots) to the border of the MC in the coronal view. The contrast and brightness tools were used to enhance the measuring procedures.

IBM SPSS Statistics v 22.0 licensed package (IBM, Chicago, IL, USA) was used for statistical processing of the used data. The method of descriptive statistics (mean and standard deviation) was used for statistical processing of the received data. The comparison between the age groups was analyzed by one-way ANOVA test with  $P < 0.05$ . The comparison between males and females was done by independent  $t$ -test with  $P < 0.05$ .

## Results

Three hundred CBCT scans (170 females and 130 males) were analyzed and resulted in 396 mandibular first molars and 378 second molars and 125 third molars.

### Mandibular first molar

For the first molar, the younger group showed to have smaller distances to MC than other age groups ( $P < 0.05$ ). The mean distance for mesial root was 4.46 mm in the young group, 5.04 mm in the middle group, and 5.11 mm in the elderly group. For the distal root, the mean distance was 4.25, 4.59, and 4.69 mm for age groups, respectively [Table 1 and Figure 1].

### Mandibular second molar

The roots of the mandibular second molar were closer to MC than the first molar. The mean distance for the mesial root was 2.52, 3.01, and 3.05 mm in the young, middle, and elderly groups ( $P < 0.05$ ).

When comparing the distances on both right and left sides, no difference was observed in each group ( $P > 0.05$ ) [Table 2 and Figure 2a and b].

### Mandibular third molar

The mandibular third molar was observed to have one root in most cases. The mean distance for one-rooted third molar was 1.84, 2.02, and 2.05 mm in the young, middle, and elderly groups, respectively ( $P > 0.05$ ). The roots for this tooth had the closest distance to MC [Table 3 and Figure 2c].

When comparing the distance between the roots of mandibular molars and MC in males and females, it was observed that molar roots in females had a smaller distance to MC than in males ( $P < 0.05$ ) [Table 4 and Figure 3].

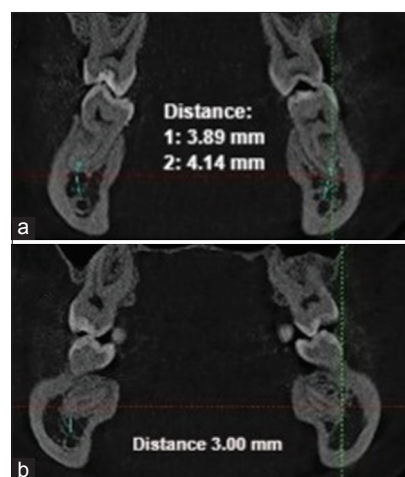


Figure 1: (a) The distance from mesial roots of mandibular first molar in both sides the right one 4.14 mm and the left 3.89 mm. (b) The distance from the distal root of the mandibular first molar on the right side and about 3.00 mm

**Table 1: The mean±standard deviation of the distance between mandibular first molar root apices and mandibular canal**

| Distance                          | Young group | Middle group | Elderly group | Total     | Test                       | P     |
|-----------------------------------|-------------|--------------|---------------|-----------|----------------------------|-------|
| Left                              |             |              |               |           |                            |       |
| M                                 | 4.45±2.32   | 5.08±2.70    | 5.11±2.61     | 4.81±2.81 | ANOVA                      | 0.04  |
| D                                 | 4.22±2.50   | 4.66±2.51    | 4.72±2.55     | 4.60±2.51 | ANOVA                      | 0.03  |
| Right                             |             |              |               |           |                            |       |
| M                                 | 4.50±2.40   | 5.01±2.80    | 5.15±2.18     | 4.91±2.62 | ANOVA                      | 0.04  |
| D                                 | 4.28±2.71   | 4.58±2.82    | 4.65±2.60     | 4.46±2.60 | ANOVA                      | 0.03  |
| Total                             |             |              |               |           |                            |       |
| M                                 | 4.46±2.41   | 5.04±2.73    | 5.11±2.60     | 4.92±2.71 | ANOVA                      | 0.04  |
| D                                 | 4.25±2.50   | 4.59±2.72    | 4.69±2.42     | 4.51±2.40 | ANOVA                      | 0.03  |
| Comparison between left and right |             |              |               |           | Independent <i>t</i> -test | >0.05 |

**Table 2: The mean±standard deviation of the distance between mandibular second molar root apices and mandibular canal**

| Distance                          | Young group | Middle group | Elderly group | Total     | Test                       | P     |
|-----------------------------------|-------------|--------------|---------------|-----------|----------------------------|-------|
| Left                              |             |              |               |           |                            |       |
| M                                 | 2.52±2.12   | 2.93±2.20    | 3.12±2.19     | 2.85±2.13 | ANOVA                      | 0.03  |
| D                                 | 2.41±1.85   | 2.82±2.20    | 2.85±2.33     | 2.64±2.10 | ANOVA                      | 0.03  |
| Right                             |             |              |               |           |                            |       |
| M                                 | 2.53±2.20   | 3.10±2.22    | 3.01±2.20     | 2.82±2.20 | ANOVA                      | 0.03  |
| D                                 | 2.35±1.97   | 2.81±2.10    | 2.85±2.11     | 2.65±2.03 | ANOVA                      | 0.02  |
| Total                             |             |              |               |           |                            |       |
| M                                 | 2.52±2.10   | 3.01±2.01    | 3.05±2.10     | 2.85±2.01 | ANOVA                      | 0.03  |
| D                                 | 2.38±1.92   | 2.82±2.14    | 2.85±2.21     | 2.64±2.05 | ANOVA                      | 0.04  |
| Comparison between left and right |             |              |               |           | Independent <i>t</i> -test | >0.05 |

**Table 3: The mean±standard deviation of the distance between mandibular third molar root apices and mandibular canal**

| Distance                          | Young group | Middle group | Elderly group | Total     | Test                       | P     |
|-----------------------------------|-------------|--------------|---------------|-----------|----------------------------|-------|
| Left                              |             |              |               |           |                            |       |
| M                                 | 2.15±1.92   | 2.29±2.01    | 2.31±1.98     | 2.22±1.98 | ANOVA                      | 0.04  |
| D                                 | 2.02±1.91   | 2.15±1.98    | 2.16±2.05     | 2.08±1.97 | ANOVA                      | 0.04  |
| I root                            | 1.85±1.65   | 2.05±1.87    | 2.06±1.96     | 1.95±1.85 | ANOVA                      | 0.02  |
| Right                             |             |              |               |           |                            |       |
| M                                 | 2.14±1.95   | 2.30±2.00    | 2.32±1.98     | 2.24±1.94 | ANOVA                      | 0.01  |
| D                                 | 2.01±1.72   | 2.16±1.91    | 2.18±1.95     | 2.06±1.91 | ANOVA                      | 0.04  |
| I root                            | 1.81±1.70   | 2.02±1.82    | 2.05±1.96     | 1.92±1.84 | ANOVA                      | 0.02  |
| Total                             |             |              |               |           |                            |       |
| M                                 | 2.15±1.91   | 2.29±2.00    | 2.31±1.99     | 2.24±1.92 | ANOVA                      | 0.03  |
| D                                 | 2.00±1.81   | 2.15±1.90    | 2.16±2.00     | 2.05±1.91 | ANOVA                      | 0.03  |
| I root                            | 1.84±1.63   | 2.02±1.86    | 2.05±1.96     | 1.94±1.88 | ANOVA                      | 0.54  |
| Comparison between left and right |             |              |               |           | Independent <i>t</i> -test | >0.05 |

## Discussion

IAN injuries are serious complications during surgical extraction of the mandibular third molar or during endodontic treatment in the posterior mandible, which is responsible for 8%–35% of reported iatrogenic nerve damage.<sup>[17,18]</sup> The risk factors of IAN damage in the literature are the clinicians' experience and age and sex of the patient, and the most important one is the anatomical

relationship between the root apices of mandibular molars and MC.<sup>[19]</sup> IAN damage could also be a result of accidental extrusion of sealer into the MC. In the literature, it was observed four possibilities of extrusion of endodontic sealer into the periapical region: (1) toward the MC, (2) drainage through lymphatic vessels, (3) systemic diffusion through a periapical vein, and (4) progression toward soft tissues between bone and mucosal membrane.<sup>[20]</sup>

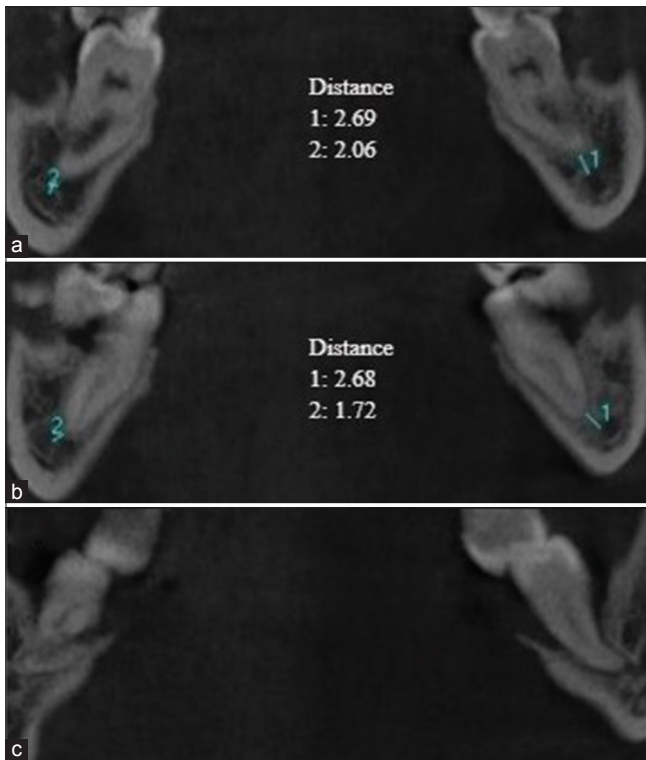


Figure 2: A coronal view of the second and third mandibular molar. (a) The distance from the mesial root of the second molar to the mandibular canal, (b) The distance from the distal root of the second molar to the mandibular canal, (c) the proximity of the third molar to the canal

The precise identification of the MC is so important for the planning of many dental procedures, and the knowledge of relationship between the MC and teeth roots is of clinical significance for clinicians,<sup>[21,22]</sup> and using the CBCT technique is considered the gold standard for judging this relation.

In 2018, a review was conducted to assess the IAN injuries due to endodontic treatment and resulted that IAN injuries after endodontic treatment require urgent management and suggested that early surgical removal of excess of endodontic materials near the nerve during 72 h allows the best recovery.<sup>[23]</sup>

To our knowledge, a few studies were conducted to assess the relationship between the MC and the root apices of the posterior mandible in different populations;<sup>[15,24]</sup> therefore, this study aimed to determine the relationship of the MC and the root apices of mandibular molars in different age groups using CBCT among residents of the Moscow population.

Various studies have been conducted to study the proximity of the MC and the root apices of mandibular molars. A study by Simonton *et al.* reported that females had significantly more vertical distance from the IAN to the mesial and distal roots.<sup>[25]</sup> Denio *et al.* used sectioning on 22 mandibles to evaluate the relationship of the MCs to root apices, finding that the mandibular second molar had

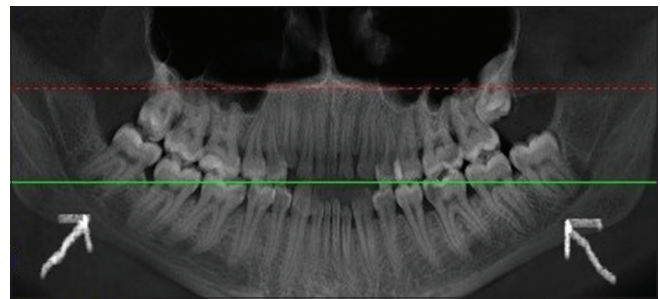


Figure 3: A panoramic view of a female, 23 years old, and it is observed the small distance between the mandibular molars and the mandibular canal

**Table 4: The mean±standard deviation of the distance between mandibular molar root apices and mandibular canal according to sex**

| Tooth                   | Root   | Male      | Female    | Test               | P     |
|-------------------------|--------|-----------|-----------|--------------------|-------|
| Mandibular first molar  | M      | 5.12±2.10 | 3.98±2.06 | Independent t-test | 0.001 |
|                         | D      | 4.67±2.13 | 3.64±2.10 | Independent t-test | 0.02  |
| Mandibular second molar | M      | 3.05±2.21 | 2.55±1.97 | Independent t-test | 0.04  |
|                         | D      | 2.75±2.04 | 2.20±1.90 | Independent t-test | 0.04  |
| Mandibular third molar  | M      | 2.29±2.01 | 1.95±1.83 | Independent t-test | 0.01  |
|                         | D      | 2.09±1.87 | 1.91±1.85 | Independent t-test | 0.03  |
|                         | 1 root | 2.03±1.96 | 1.90±1.87 | Independent t-test | 0.04  |

the closest distance to the canal.<sup>[26]</sup> Sato *et al.* studied the distance from root apices to the superior border of the MC using computed tomography images and panoramic radiographs and found that the root apices of the first and second molars were closer to the MC in females than in males. In addition, the average distance from the first molar mesial root was 1.06 mm and from the distal root was 0.99 mm.<sup>[13]</sup>

A study by Koivisto *et al.* used CBCT to determine the proximity of the MC to the tooth apex and found that the mandibular second molars were closed to the MC than other teeth, and younger patients were significantly closer to the MC than older patients.<sup>[16]</sup>

Another retrospective study among central Indians by Hiremath *et al.* resulted in that the average distance of IAN to the mesial root apex of the first molar was 1.46–13.23 mm for males and 0.93–8.03 mm for females, and for the second molar, the average distance was 1.31–14.71 mm for males and 0.00–6.91 for females.<sup>[24]</sup>

In a study by Bürklein *et al.* in the German population, 627 CBCT scans were analyzed and the results showed that the mean distance from the MC to the root apices of the first, second, and third molars was 4.9, 3.1, and 2.6 mm, respectively, and the distance was smaller in women compared to men and smaller in young patients.<sup>[15]</sup> Chong *et al.* found in their study that in 54.8% of the cases, the IAN lies ≤3 mm from the anatomic apex of the root.<sup>[27]</sup>

This study included 300 CBCT images and recorded 396 mandibular first molars, 378 second molars, and 125 third



molars and resulted that the mean distance from the root apices of the first, second, and third molars was higher in mesial roots of the first molars (4.92 mm) and smaller in the third molars (1.94 mm). The results also showed that distal roots of mandibular molars were closer to the MC than mesial roots in each age group; these results are agreement with other studies.<sup>[13,15]</sup>

Regarding the difference between the groups, the young group showed a smaller significant distance between the root apices and the MC than other age groups, and this is also incompatible to Bürklein *et al.*<sup>[15]</sup> and Koivisto *et al.*,<sup>[16]</sup> where the distance was increased with age. This result indicates that the facial skeletal growth may continue during late adolescence.

Regarding the distance between molar roots and MC in males and females, our results coincide with the results of Hiremath *et al.*<sup>[24]</sup> and Sato *et al.*,<sup>[13]</sup> in which females show a smaller distance to MC than males. The mean distance in distal roots in mandibular first, second, and third molars was 4.67, 2.75, and 2.09 mm in males, respectively, while in females, the mean distance was 3.64, 2.20, and 1.91 mm, respectively.

## Conclusions

Within the limits of this study, the distal roots of mandibular molars were closer to the MC than mesial roots. The young age group showed a smaller distance to MC than other age groups. This relationship between the MC and the root apices should be taken into consideration when performing surgical and endodontic procedures in the posterior mandible, and clinicians should be aware of the proximity of root apices to the MC to avoid any damage to the IAN. Using CBCT is an invasive technique and provides accurate 3D images for the anatomic structures and helps avoiding the IAN injuries.

## Declaration of patient consent

The authors certify that they have obtained all appropriate patient consent forms. In the form the patient(s) has/have given his/her/their consent for his/her/their images and other clinical information to be reported in the journal. The patients understand that their names and initials will not be published and due efforts will be made to conceal their identity, but anonymity cannot be guaranteed.

## Financial support and sponsorship

The publication has been prepared with the support of the "RUDN University Program 5-100."

## Conflicts of interest

There are no conflicts of interest.

## References

- Nortjé CJ, Farman AG, Grotepass FW. Variations in the normal anatomy of the inferior dental (mandibular) canal: A retrospective study of panoramic radiographs from 3612 routine dental patients. *Br J Oral Surg* 1977;15:55-63.
- Xu GZ, Yang C, Fan XD, Yu CQ, Cai XY, Wang Y, *et al.* Anatomic relationship between impacted third mandibular molar and the mandibular canal as the risk factor of inferior alveolar nerve injury. *Br J Oral Maxillofac Surg* 2013;51:e215-9.
- Robinson PP. Observations on the recovery of sensation following inferior alveolar nerve injuries. *Br J Oral Maxillofac Surg* 1988;26:177-89.
- Renton T, Yilmaz Z. Managing iatrogenic trigeminal nerve injury: A case series and review of the literature. *Int J Oral Maxillofac Surg* 2012;41:629-37.
- Mohammadi Z. Endodontics-related paresthesia of the mental and inferior alveolar nerves: An updated review. *J Can Dent Assoc* 2010;76:a117.
- Rowe AH. Damage to the inferior dental nerve during or following endodontic treatment. *Br Dent J* 1983;155:306-7.
- Becking AG. Complications in the use of sodium hypochlorite during endodontic treatment. Report of three cases. *Oral Surg Oral Med Oral Pathol* 1991;71:346-8.
- Scolozzi P, Lombardi T, Jaques B. Successful inferior alveolar nerve decompression for dysesthesia following endodontic treatment: Report of 4 cases treated by mandibular sagittal osteotomy. *Oral Surg Oral Med Oral Pathol Oral Radiol Endod* 2004;97:625-31.
- Poveda R, Bagán JV, Fernández JM, Sanchis JM. Mental nerve paresthesia associated with endodontic paste within the mandibular canal: Report of a case. *Oral Surg Oral Med Oral Pathol Oral Radiol Endod* 2006;102:e46-9.
- Escoda-Francoli J, Canalda-Sahli C, Soler A, Figueiredo R, Gay-Escoda C. Inferior alveolar nerve damage because of overextended endodontic material: A problem of sealer cement biocompatibility? *J Endod* 2007;33:1484-9.
- Ueda M, Nakamori K, Shiratori K, Igarashi T, Sasaki T, Anbo N, *et al.* Clinical significance of computed tomographic assessment and anatomic features of the inferior alveolar canal as risk factors for injury of the inferior alveolar nerve at third molar surgery. *J Oral Maxillofac Surg* 2012;70:514-20.
- Burstein J, Mastin C, Le B. Avoiding injury to the inferior alveolar nerve by routine use of intraoperative radiographs during implant placement. *J Oral Implantol* 2008;34:34-8.
- Sato I, Ueno R, Kawai T, Yosue T. Rare courses of the mandibular canal in the molar regions of the human mandible: A cadaveric study. *Okajimas Folia Anat Jpn* 2005;82:95-101.
- Nayak DS, Raghavan SA, Birur P, Gurudath S, Keerthi G. Determination of proximity of mandibular third molar to mandibular canal using panoramic radiography and cone-beam computed tomography. *J Indian Acad Oral Med Radiol* 2017;29:273-7.
- Bürklein S, Grund C, Schäfer E. Relationship between root apices and the mandibular canal: A cone-beam computed tomographic analysis in a German population. *J Endod* 2015;41:1696-700.
- Koivisto T, Chiona D, Milroy LL, McClanahan SB, Ahmad M, Bowles WR. Mandibular canal location: Cone-beam computed tomography examination. *J Endod* 2016;42:1018-21.
- Renton T, Yilmaz Z. Profiling of patients presenting with posttraumatic neuropathy of the trigeminal nerve. *J Orofac Pain* 2011;25:333-44.
- Libersa P, Savignat M, Tonnel A. Neurosensory disturbances of the inferior alveolar nerve: A retrospective study of complaints in a 10-year period. *J Oral Maxillofac Surg* 2007;65:1486-9.
- Sedaghatfar M, August MA, Dodson TB. Panoramic radiographic findings as predictors of inferior alveolar nerve

- exposure following third molar extraction. *J Oral Maxillofac Surg* 2005;63:3-7.
20. Alantar A, Tarragano H, Lefèvre B. Extrusion of endodontic filling material into the insertions of the mylohyoid muscle. A case report. *Oral Surg Oral Med Oral Pathol* 1994;78:646-9.
  21. Juodzbaly G, Wang HL, Sabalys G. Injury of the inferior alveolar nerve during implant placement: A literature review. *J Oral Maxillofac Res* 2011;2:e1.
  22. Kim TS, Caruso JM, Christensen H, Torabinejad M. A comparison of cone-beam computed tomography and direct measurement in the examination of the mandibular canal and adjacent structures. *J Endod* 2010;36:1191-4.
  23. Castro R, Guivarc'h M, Foletti JM, Catherine JH, Chossegros C, Guyot L. Endodontic-related inferior alveolar nerve injuries: A review and a therapeutic flow chart. *J Stomatol Oral Maxillofac Surg* 2018;119:412-8.
  24. Hiremath H, Agarwal R, Hiremath V, Phulambrikar T. Evaluation of proximity of mandibular molars and second premolar to inferior alveolar nerve canal among central Indians: A cone-beam computed tomographic retrospective study. *Indian J Dent Res* 2016;27:312-6.
  25. Simonton JD, Azevedo B, Schindler WG, Hargreaves KM. Age- and gender-related differences in the position of the inferior alveolar nerve by using cone beam computed tomography. *J Endod* 2009;35:944-9.
  26. Denio D, Torabinejad M, Bakland LK. Anatomical relationship of the mandibular canal to its surrounding structures in mature mandibles. *J Endod* 1992;18:161-5.
  27. Chong BS, Quinn A, Pawar RR, Makdissi J, Sidhu SK. The anatomical relationship between the roots of mandibular second molars and the inferior alveolar nerve. *Int Endod J* 2015;48:549-55.