

Laparoscopic Repair of Umbilical Hernias in Conjunction With Other Laparoscopic Procedures

George M. Eid, MD, Paul A. Thodiyil, MD, Joy Collins, MD, Gianluca Bonanomi, MD, Samer G. Mattar, MD, Steven J. Hughes, MD, Philip R. Schauer, MD, Mark Wilson, MD, PhD

ABSTRACT

Background: This study evaluates the feasibility of laparoscopic transfascial suture repair of umbilical hernias when combined with another laparoscopic procedure that potentially contaminates the peritoneal cavity.

Method: From August 1997 to November 2001, 32 patients underwent laparoscopic umbilical suture repair in association with another laparoscopic procedure. The repair was performed with the Carter-Thomason suture passer.

Results: Of the 32, 26 patients with more than 1-year follow-up were included in the study. The mean diameter of the umbilical hernia defect was 1.67 cm (range, 0.5 to 3). At a mean follow-up of 34 months (range, 12 to 60), there were only 2 recurrences (7.7%) both of which happened in patients with hernia defects larger than 2 cm in diameter. Apart from 2 wound infections, no other complications occurred.

Conclusion: Laparoscopic suture repair of umbilical hernias with the suture passer method is effective and durable even when combined with other laparoscopic procedures that potentially contaminate the peritoneal cavity with bile or enteric contents.

Key Words: Umbilical hernia, Laparoscopic technique, Combined operations.

INTRODUCTION

Open umbilical hernioplasty by primary closure of the fascial defects, considered the standard repair by most surgeons, is plagued by a high recurrence rate, particularly after suture repair (11%).¹ Synthetic mesh has a more favorable recurrence rate (1%), but may not be an appropriate option when combined with laparoscopic procedures that violate a biliary or enteric lumen. Laparoscopic transfascial suture repair of these defects, an approach that allows wider fascial closure, may offer an attractive alternative in these cases. This article reports our experience with laparoscopic umbilical hernia suture repair when combined with another laparoscopic procedure.

METHODS

Between August 1997 and November 2001, 32 patients underwent laparoscopic umbilical suture repair in association with another laparoscopic procedure. The procedures were performed by or under the direct supervision of a single attending surgeon. Of these, 26 patients had a follow-up period of more than 1 year and were selected as the study population. Thus, 6 patients were excluded due to a short follow-up. Data were collected retrospectively and included patient age, sex, concomitant laparoscopic procedure, number of previous repairs, size of fascial defect, and postoperative complications. Patients were evaluated for hernia recurrence and complications by the attending surgeon in the immediate postoperative period and 1 to 2 weeks postoperatively. Long-term surveillance for recurrence was performed by a surgeon every 3 months by physical examination. Data are presented as mean and range. Statistical analysis was performed with the Student *t* test for 2 variables. $P < 0.05$ was considered significant.

In the course of the primary operation, if incarcerated omentum was encountered, blunt dissection was performed to reduce it. A 2-mm stab incision was performed over the umbilicus to allow the insertion of the tip of the Carter-Thomason device. Using the device, and under direct vision, a nonabsorbable suture was introduced into the abdominal cavity on one side of the defect and retrieved back on the other side of the defect after once more passing the Carter-Thomason device, as shown in

Center for Minimally Invasive Surgery, University of Pittsburgh Medical Center, Pittsburgh, Pennsylvania, USA (Drs Collins, Thodiyil, Bonanomi, Schauer, Mattar).

Veteran Administration Pittsburgh Healthcare System, Pittsburgh, Pennsylvania, USA (Drs Eid, Wilson, Hughes).

Address reprint requests to: George M. Eid, MD, Suite 5500, 300 Halket Street, Pittsburgh, PA 15213, USA. Telephone: 412 641 3667, Fax: 412 641 7612, E-mail: eidgm@msx.upmc.edu

© 2006 by JSLs, Journal of the Society of Laparoendoscopic Surgeons. Published by the Society of Laparoendoscopic Surgeons, Inc.

Figure 1. At least 3 sutures were placed across the fascial defect and left untied (**Figure 2**). After all sutures were laid, the pneumoperitoneum pressure was released and the sutures were then tied. The suture knots were buried under the skin, and the incision was closed with a subcutaneous suture.

RESULTS

Patient and hernia characteristics are summarized in **Table 1**. Twenty-six patients had a follow-up of 1 year or longer. Sixteen were males (61%), and the mean age was 51 years (range, 30 to 85). The mean diameter of the hernia defects was 1.67 cm (range, 0.5 to 3). Thirty percent of all the patients were found to have hernias with incarcerated omentum, and 2 patients had recurrent umbilical hernias, both with defects larger than 2cm in diameter. None of the patients required conversion to open repair. The concomitant operations consisted of Nissen fundoplication,¹¹ cholecystectomy,⁹ gastrectomy,² small bowel resection² and splenectomy.² The average follow-up was 34 months (range, 12 to 60). Postoperative complications, which included wound cellulitis and hernia recurrence, are shown in **Table 2**.

DISCUSSION

Umbilical hernia is an acquired defect in over 90% of adults.² Such hernias are relatively common and most likely occur in the fifth and sixth decades of life.³ Many of these lesions remain undetected until discovered in the course of laparoscopic procedures. Nassar et al⁴ reported

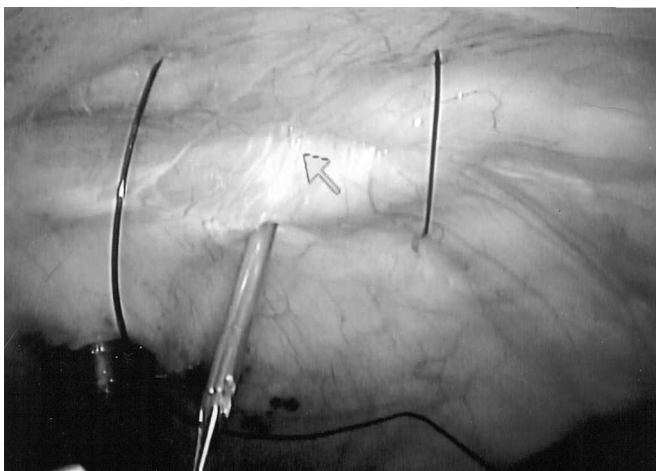


Figure 1. A Carter-Thomason device is used to introduce and then retrieve a nonabsorbable suture into the abdominal cavity on either side of the defect.

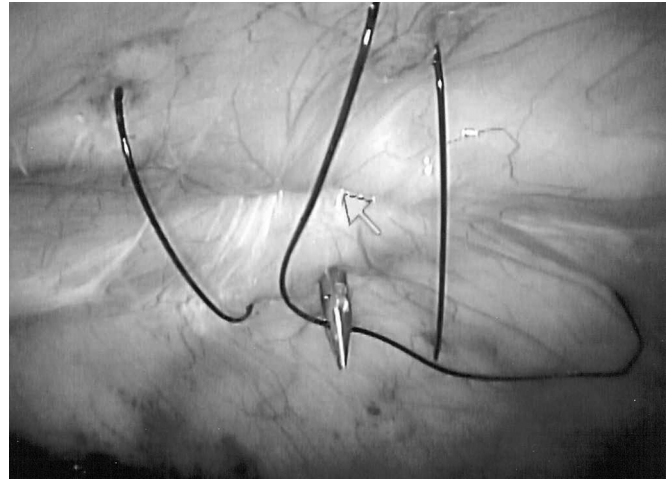


Figure 2. At least 3 sutures are placed across the fascial defect but only tied after release of the pneumoperitoneum.

Table 1.
Preoperative Characteristics of Patients

Mean age (years)	51 (range, 30 to 85)
Sex ratio (M:F)	16:10
Recurrent hernias	2 (7.7%)
Omental incarceration	8 (31%)
Hernia defect	
≥ 2 cm	8 (31%)
≤ 2 cm	18 (69%)

Table 2.
Complications in Patients Who Underwent Laparoscopic Umbilical Hernia Repair

Hernia Diameter	Recurrences	Wound Infection
<2 cm	0/18*	1/18 (5.6%)
>2 cm	2/8 (25%)*	1/8 (12.5%)
Totals	2/26 (7.7)	2/26 (7.7%)

*No statistical significance between the 2 groups of patients.

a 12% incidence of umbilical or paraumbilical defects in patients undergoing laparoscopic cholecystectomy.

Open umbilical herniorrhaphy with the suture technique has been widely used over the last century. Despite attempts to vary suturing techniques, primary repair of umbilical hernias has yielded unfavorable results with recurrence rates of 10% to 20%.^{1,5} These rates have been markedly reduced to 1% with the use of mesh to achieve

a tension-free repair.¹ However, the use of synthetic mesh for repair of umbilical hernias may not be appropriate when combined with another procedure that violates a biliary or enteric lumen, because of the potential risk of contamination and chronic wound infection.

The laparoscopic approach for umbilical hernia repair offers an advantage over the open technique. It allows for a wide fascial closure under direct vision and eliminates the need for anterior tissue dissection. These factors probably lead to a lower recurrence rate and complication rate. In our small series, the rate of recurrence (7.7%) was smaller when compared with that in previously published series on open techniques. Although not statistically significant, the recurrence rate was reduced to zero in patients who have defects smaller than 2 cm in diameter.

This technique, previously described by Carter⁶ for closure of trocar sites, is relatively easy to perform. Surgeons with basic laparoscopic skills should be able to implement this technique. The technique is no different from that involved in the closure of 10-mm port sites and adds no more than 5 minutes to 10 minutes to the procedure. Although postoperative pain was not formally studied, it was anecdotally only marginally greater than that from a normal 10-mm trocar closure site and did not affect hospital stay.

This 1-stage repair of the umbilical hernia has several advantages. With a reoperation rate of 7.7% (at 34 months), this saves on the cost of a second procedure in over 92% of patients. Furthermore, the material costs of a prosthetic mesh are considerably more than the costs of the suture material used in the technique described here. Despite the fact that the recurrence rate for defects over 2 cm was 25%, there would still be an argument for undertaking a primary suture closure of these larger defects in the presence of potential contamination. Given this increased recurrence rate when the fascial defect measures greater than 2 cm, we now typically include an underlay

of bio-absorbable mesh, in addition to suture closure, when repairing the larger hernia defects.

CONCLUSION

Laparoscopic umbilical repair with the suture passer method is effective and durable, even when combined with other laparoscopic procedures. Our experience demonstrates a lower recurrence and complication rate compared with the published data on the open approach in a similar clinical setting. Probably reflecting a type II error, the better outcomes achieved with umbilical hernia defects smaller than 2 cm in diameter did not achieve statistical significance. To adequately compare the proposed laparoscopic transfascial suture repair with the standard open suture closure, a prospective, randomized study is required.

References:

1. Arroyo A, Garcia P, Perez F, Andreu J, Candela F, Calpena R. Randomized clinical trial comparing suture and mesh repair of umbilical hernia in adults. *Br J Surg*. 2001;88:1321–1323.
2. Morgan WW, White JJ, Stambaugh S, Haller JA. Prophylactic umbilical hernia repair in childhood to prevent adult incarceration. *Surg Clin North Am*. 1970;50:839–845.
3. Harmel RP. Umbilical hernia. In: Nyhus LM, Condon RE, eds. *Hernia*. 3rd ed. Philadelphia, Pennsylvania: JB Lippincott, 1989; 347–352.
4. Nassar AH, Ashkar KA, Rashed AA, Abdulmoneum MG. Laparoscopic cholecystectomy and the umbilicus. *Br J Surg* 1997;84:630–633.
5. Celdran A, Bazire P, Garcia-Urena MA, Mariguam JL. Hernioplasty: A tension-free repair for umbilical hernia. *Br J Surg*. 1995;82:371–372.
6. Carter JE. A new technique of fascial closure for laparoscopic incisions. *J Laparoendoscopic Surg*. 1994;4:143–148.