

Intraocular Lens Calcification: Clinico-pathological Report of Two Cases and Literature Review

Mansour Rahimi¹, MD; Ali Azimi¹, MD; Masoud Hosseinzadeh², MD

¹Poostchi Eye Research Center, Department of Ophthalmology, Shiraz University of Medical Sciences, Shiraz, Iran

²Department of Pathology, School of Medicine, Shiraz University of Medical Sciences, Shiraz, Iran

Abstract

Purpose: We report the clinicopathological features and surgical outcomes of two cases of intraocular lens (IOL) calcification along with a review of the current literature.

Case Report: The first patient was a 53-year-old woman with diabetes mellitus (type 2) who underwent phacoemulsification with posterior chamber IOL insertion (PCIOL), and pars plana vitrectomy. Significant clouding of the IOL was first noted after 1.5 years, and the IOL was replaced with an Artisan lens. The second patient was a 22-year-old woman with Vogt-Koyanagi-Harada syndrome; she underwent a lensectomy, PCIOL, and pars plana vitrectomy. IOL opacification was first noted 4.5 years after the initial surgery and the IOL was extracted.

Conclusion: The calcification of each IOL was confirmed by a pathologist. Further studies are required to determine the primary causes and mechanisms of the calcification of biomaterials including IOLs.

Keywords: Calcification; Intraocular Lens; Pathology

J Ophthalmic Vis Res 2018; 13 (2): 195–199

INTRODUCTION

The frequency of implantation of intraocular lenses (IOLs) has increased, albeit each IOL type has associated complications.^[1] While modern cataract surgery and small incision methods have improved, the demand for foldable intraocular lens (FIOL) biomaterials has increased.^[2] Since the latter's introduction, cataract surgery has reduced astigmatism and increased the rehabilitation of the injured organ.

New generations of FIOLs are available in various designs that comprise various materials, including silicon,

hydrophobic acrylic, and hydrophilic acrylic (hydrogel). Hydrophilic acrylic lenses may reduce post-surgical inflammation due to improved biocompatibility with ocular tissues. Optical resolution and refractive stability during the patient's life are desirable IOL performance metrics.^[3-5]

The occurrence of opacity and the formation of deposits in these lenses after surgery are considered as fairly recent problems. Histological studies and structure of IOLs reveal that these opacities occur due to the formation of organic deposits on the IOL components or the presence of impurities in the polymer.^[6,7] Since their introduction in 1949, the biomaterials used for the fabrication of IOL have been constantly undergoing further development. Studies on IOLs have reported discrete cases of calcification, which are usually caused

Correspondence to:

Mansour Rahimi, MD. Department of Ophthalmology, Poostchi Eye Research Center, Shiraz University of Medical Sciences, Shiraz 71867, Iran.

E-mail: m.rahimi@msn.com

Received: 06-03-2016

Accepted: 19-07-2016

Access this article online

Quick Response Code:



Website:

www.jovr.org

DOI:

10.4103/jovr.jovr_36_16

This is an open access journal, and articles are distributed under the terms of the Creative Commons Attribution-NonCommercial-ShareAlike 4.0 License, which allows others to remix, tweak, and build upon the work non-commercially, as long as appropriate credit is given and the new creations are licensed under the identical terms.

For reprints contact: reprints@medknow.com

How to cite this article: Rahimi M, Azimi A, Hosseinzadeh M. Intraocular lens calcification: Clinico-pathological report of two cases and literature review. *J Ophthalmic Vis Res* 2018;13:195-9.

by either underlying or chronic diseases. Until 1999, these investigations reported more post-surgical cases of opacity and calcification of IOLs. In some cases, the lenses required removal and replacement due to various levels of vision loss or high intensity glare; while in others, delayed opacity due to calcification was reported after surgery. This opacity was either in the form of a deposit on the surface of optics or haptics or both surfaces of the IOL. In some cases, the deposit penetrated the IOL.^[5,7,8]

Most companies that produce IOLs have withdrawn their products from the market and incorporated numerous changes into new versions as they learned of problems.^[5] Nevertheless, different studies have mentioned various pathologic and clinical demonstrations of IOLs. The design of some IOLs results in a high probability of calcification, which was subsequently resolved in other designs. This case report reveals the role of the biomaterial and manufacturing processes of IOL in its opacity.^[3,9]

Most delayed opacity in IOLs occurs in hydrophilic acrylic IOLs. Nevertheless, some cases of IOL opacification have also been reported in silicon IOLs. Opacity can decrease visual acuity; therefore, clinical evaluation of the causes is important.^[3,4,8] In this study, we present the clinicopathological features and surgical treatment outcomes of two cases of IOL calcification, along with a literature review.

CASE REPORTS

Case 1

In 2009, a 53-year-old woman with type 2 diabetes mellitus (DM) underwent simultaneous cataract surgery, deep vitrectomy, and SF6 injection due to cataract and diabetic retinopathy and an epiretinal membrane in the left eye. A foldable IOL (Bausch & Lomb; New Jersey, USA) with a power of +21 diopters (D) was implanted in the capsular bag under general anesthesia. The patient had a history of DM, as well as rheumatoid arthritis and hypertension. During follow-up, the best corrected visual acuity (BCVA) of the affected eye improved to 8/10; no intraocular inflammation or increased intraocular pressure (IOP) was detected. IOL clouding was first noted in 2011, 1.5 years after an uneventful surgery and regular postoperative follow-ups. Clouding caused decreased vision; the patient's BCVA decreased to 6 m counting fingers [Figure 1]. Follow-up visits were planned to assess the potential decrease in visual acuity. Examination showed the progression of refractory cystoid macular edema (CME) and central retinal vein occlusion. The possibility of an IOL exchange and re-deep vitrectomy due to refractory CME were discussed with the patient. The IOL was exchanged with an artisan lens (+18 D). A postoperative follow-up examination after the exchange showed a clear IOL.

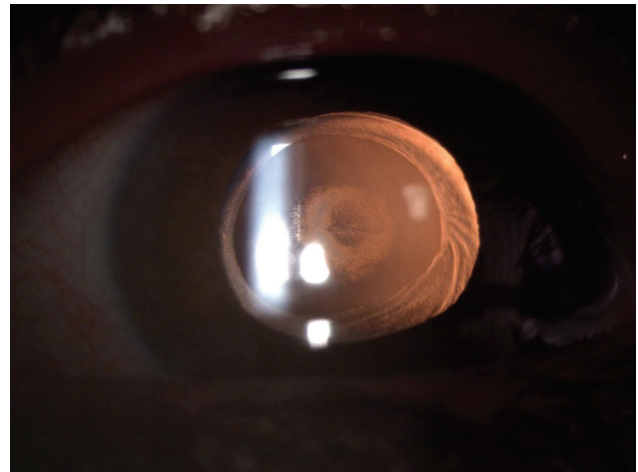


Figure 1. Clouding of the IOL, which causes decreased vision.

Case 2

In 2005, a 22-year-old woman with chronic intermediate uveitis due to Vogt-Koyanagi-Harada (VKH) syndrome underwent uneventful lensectomy, deep vitrectomy, and SF6 injection due to cataract, 360-degree peripheral anterior synechia (PAS), and posterior synechia (PS), in addition to uncontrolled intermediate uveitis in the right eye. A foldable IOL (BAUSCH & LOMB; serial number: 7917521273) with a power of +17.5 D with an A-constant of 118.5 was implanted in the capsular bag under general anesthesia. Four months later, shallow anterior chamber (AC) progressed and a pupillary membrane was detected. Therefore, AC reformation and a peripheral iridectomy (PI) were performed.

Opacification of the IOL was first noted in 2010, 4.5 years after the initial surgery [Figure 2]. At that time, the patient's visual acuity was 2 m counting fingers, and severe PS and PAS were detected. The IOL was extracted and viscogoniosynechiolysis was performed [Figure 3]. Two years later, the patient presented with uncontrolled glaucoma; she underwent transscleral cyclophotocoagulation in 2012.

In both cases, macroscopic examination of the explanted IOLs showed opacification of the inner surfaces. Paraffin blocks of each specimen were prepared, and H&E and Von Kossa staining was performed on 1- μ m sections. The slides were examined microscopically and revealed linear deposition of the round to oval course granular material [Figure 4]. The deposits varied in size and were separated from the surface of the lens by a clear zone. The Von Kossa stain revealed dense linear deposition of dark, calcium-containing deposits [Figure 5].

DISCUSSION

IOL opacification is not a new phenomenon. The incidence of opacity in Hydroview IOLs after surgery

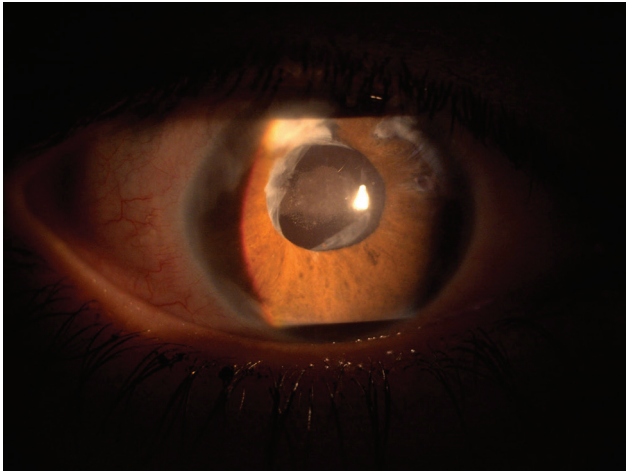


Figure 2. IOL calcification after surgery.

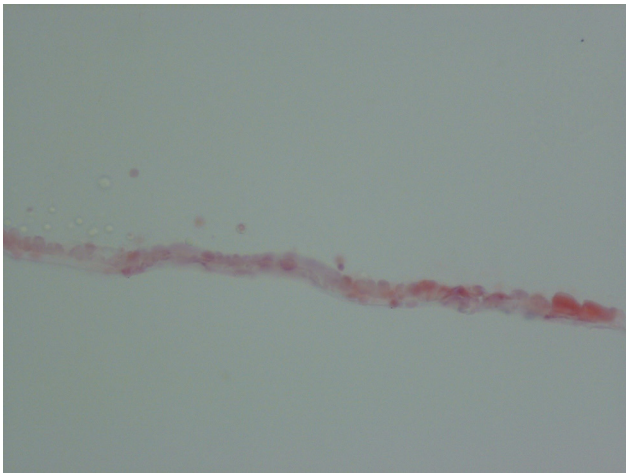


Figure 4. The slides were examined microscopically; linear deposition of round to oval coarse granular material was observed (H and E stain; $\times 100$ magnification).

was first reported in 1999 by Chang et al which attracted much attention.^[2,10]

This report describes the surgical outcomes and pathological findings of two patients with IOL opacification. This study describes the opacity that occurred in 2 IOLs fabricated by different companies of BAUSCH and LOMB. One patient suffered from poorly controlled DM, while the other patient was affected by inflammatory VKH. In both cases, the interval between IOL implantation and the occurrence of opacity was < 5 years. This interval concurs with many other ophthalmology studies.^[3-5] Opacity has been reported in PMMA, silicon, and foldable acrylic lenses. Studies demonstrate that changes in IOL materials result in blurred vision or glistening. Glistening is a result of thermal effects in the lens rather than structural changes.^[11-14] Vacuoles form within the lens due to excessive temperature, and water fills the vacuoles.

The adsorption of proteins to the surface of the IOL is another reason for opacity. The adsorption is assumed to

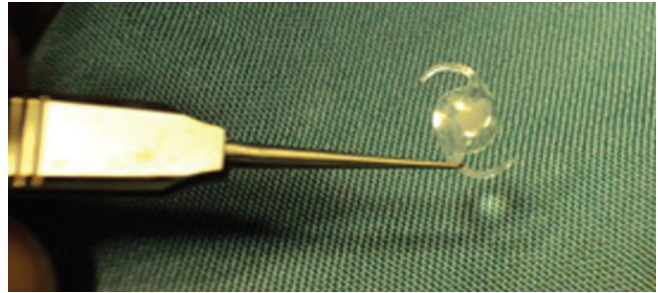


Figure 3. The IOL was extracted and viscocondensolysis (VGS) was performed.

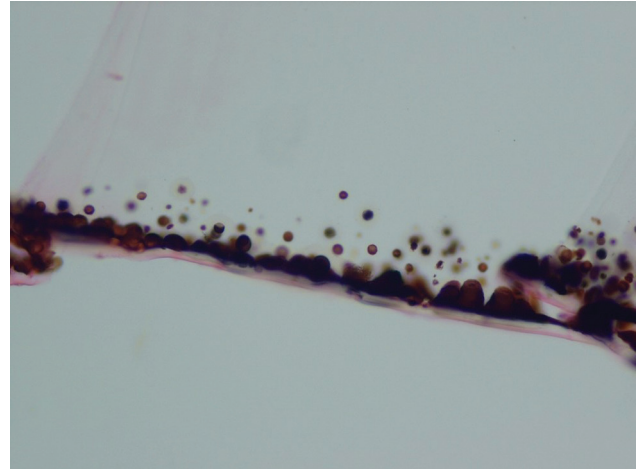


Figure 5. The Von Kossa stain revealed dense linear deposition of dark, calcium-containing deposits ($\times 1200$ magnification).

be due to an immunologic response (antigen-antibody complexes) of the eye, followed by precipitation of the immune proteins and their attachment to the IOL.^[7,13,14]

Numerous studies have reported calcification as a primary reason for IOL opacification; the formation of deposits containing calcium phosphate due to excessive saturation of the aqueous humor with calcium crystals is a possible mechanism.^[10,13,14] Similarly, the calcification of biomaterials in ophthalmology including scleral buckles (a soft silicon sponge for the treatment of retinal detachment) and contact lenses have been reported. After the first report of IOL calcification, random calcification of various IOL surfaces and materials have also been reported.

Various mechanisms have been proposed to explain IOL calcification. One possible mechanism is the precipitation of calcium due to the dispersion or adsorption of materials in the polymer component of the IOL. The fabrication and packing process and the foldability system may delay opacity, which in turn has been most frequently reported in acrylic hydrophilic IOLs. However, underlying conditions of the patient, including DM or uveitis, have also been suggested as a possible cause. The role of the blood-aqueous barrier changes in the eye as a factor in triggering inflammation

and subsequent opacity of the hydrophilic lens components remains unclear.^[1,12-14]

Calcification may occur on the external or internal surface of the IOL. Izak et al^[5] observed two types of deposits using electron and optical microscopy: granular deposits on the external optical surface, and fine seed-like deposits inside the lens optics. Both were observed as parallel lines on the anterior and posterior surfaces. Another study reported that modification of polymethyl methacrylate to increase the number of hydroxyl groups on the surface resulted in the formation of calcium phosphate on the surface.

The calcium content of the natural aqueous humor is low and half of the serum calcium. Any local increase in calcium phosphate may lead to dystrophic calcification, which may be caused by inadequate cleaning of the cortex during cataract surgery and the residues of the "crystalline lens" after cataract surgery.

Biological calcification is the precipitation of calcium phosphate salts in tissues of living organisms due to the saturation of biological fluids, resulting in the formation of nuclei and crystals. Calcification occurs on external surfaces such as implants after prolonged exposure, as well as on vessel septa. The saturation of the aqueous humor is the primary mechanism of the delayed calcification of crystalline lenses.^[12,13]

Nevertheless, calcification is affected by some factors including the polymer structure and water content. Surface complexes with calcium ions may act as the cores of organic phases. Hydroxyl and phosphate ions in polymers accelerate the growth of hydroxyapatite on the polymer components of IOLs. Some studies have reported calcification of various types of IOLs. Werner reported four primary IOLs in the United States namely, the Hydroview (Bausch and Lomb), Memorylens (Ciba Vision), SC60B-OUV (Medical Developmental Research, MDR), and Aqua-Sense (International Ophthalmic Innovations) lenses that were affected by calcification. Some of these lenses have been collected from the market.^[5,7,13,14]

Three types of calcification were proposed by Irmgard et al:^[12] including primary, secondary, and false calcification. Primary calcification is caused by the IOL. Patients with primary calcification have no history of previous or simultaneous eye disease. This case report indicates that the cause of the problem is the fabrication process, which may include deficiencies in the IOL polymer, the lens fabrication steps, or the IOL packing steps. The calcium usually diffuses into the lens structure. Secondary calcification is due to the precipitation of calcium onto the surface of the IOL under ambient conditions. Usually, this type is not associated with the IOL. Ambient conditions include existing diseases, simultaneous problems, and any diseases that result in deterioration of the blood-aqueous barrier and cause exudation of proteins and cellular compounds. Secondary,

and transudative substances are always observed in secondary calcification. False calcification may be caused by a false diagnosis due to tissue artifacts or the inappropriate use of specific substances.^[12]

Manufacturing companies have presented various justifications for calcification. The deficiencies caused by polishing procedures, which contribute to increased protein adsorption, trigger calcification on the surface of the Memory Lens IOL. The manufacturer of the Hydroview IOLs considers calcification to be due to the formation of calcium deposits on the lens surface adjacent to lipid-based acids and silicon particles so that the particles migrate into the lens. The manufacturer of Aqua-Sense IOLs has argued that the solvent causes calcification of the lens during formation of the remaining compounds. MDR considers primary deficiencies in the polymer of SC60B-OUV IOLs to be the cause of calcification. However, only a small percentage of the IOLs of each of these manufacturers experiences calcification due to the stated reasons. Thus, another factor, such as underlying disease, facilitates calcification, but no persistent factor has been identified.

Secondary calcification is relatively rare and occurs only in cases where the IOL is placed in the eye of a patient with an underlying disease or other pathological features. This underlying disease can act as a catalyst or substrate for calcification.^[7,11,12]

False calcification is observed in cases where well-known and important pathological features are cited as the cause of calcification, or where abnormal changes are confused with calcium deposits.^[12,15] This type is observed in cases where the residues of viscoelastic materials, balanced salt solution (used during IOL replacement), or both, precipitate onto the IOL surface. Therefore, these IOLs are replaced due to reasons unrelated to opacity, such as disability, lack of concentration, or trauma.^[11,15-18]

Acrylic hydrophilic materials may have a higher biocompatibility with uvea tissues than other IOLs, while the incidence of post-surgery inflammation is lower. However, the higher risk of glistening must be considered.

Delayed opacity predominantly forms on hydrophilic acrylic lenses. In addition to the existence of polymethyl methacrylate, risk factors including systematic diseases such as DM and eye inflammation, as well as factors related to IOL fabrication and packaging, contribute to this phenomenon.^[7,15,19,20]

To evaluate IOL calcification, we should first distinguish between the three types of calcification. Hence, it must be determined if the existing deficiencies within the lens cause calcification, or if it is due to environmental conditions (secondary calcification is irrelevant in IOLs). Thus, calcification can be evaluated by determining the primary cause, while secondary calcification can occur due to environmental conditions

and involve any IOL. The effect of other diseases such as DM and eye-related rheumatologic disorders which triggers IOL opacity must be considered. Although the effect of accurate control of underlying diseases in the prevention of IOL opacity is still unknown, control of the underlying disease can significantly decrease the possible effects on the eye. In false calcification, the incorrect diagnoses and possible improper invalidation of IOLs must be avoided. Nonetheless, the mechanism of some IOL opacities remains unknown. Thus, this result cannot be generalized for all IOLs. Further studies are required to discover the primary causes and mechanisms of biomaterial calcification, including the calcification of IOLs.

Declaration of Patient Consent

The authors certify that they have obtained all appropriate patient consent forms. In the form the patient(s) has/have given his/her/their consent for his/her/their images and other clinical information to be reported in the journal. The patients understand that their names and initials will not be published and due efforts will be made to conceal their identity, but anonymity cannot be guaranteed.

Financial Support and Sponsorship

Nil.

Conflicts of Interest

There are no conflicts of interest.

REFERENCES

- Apple DJ, Mamalis N, Olson RJ, Kincaid MC. IOLs: Evolution, designs, complications, and pathology. Baltimore: Williams & Wilkins; 1989.
- Mamalis N. Hydrophilic acrylic intraocular lenses. *J Cataract Refract Surg* 2001;27:1339-1340.
- Dorey MW, Brownstein S, Hill VE, Mathew B, Botton G, Kertes PJ, et al. Proposed pathogenesis for the delayed postoperative opacification of the hydroview hydrogel intraocular lens. *Am J Ophthalmol* 2003;135:591-598.
- Werner L, Apple DJ, Escobar-Gomez M. Postoperative deposition of calcium on the surface of a hydrogel intraocular lens. *Ophthalmology* 2000;107:2179-2185.
- Izak AM, Werner L, Pandey SK, Apple DJ. Calcification of modern foldable hydrogel intraocular lens designs. *Eye* 2003;17:393-406.
- Abela-Formanek C, Amon M, Schauersberger J, Schild G, Kolodjaschna J, Barisani-Asenbauer T, et al. Uveal and capsular biocompatibility of 2 foldable acrylic intraocular lenses in patients with uveitis or pseudoexfoliation syndrome; comparison to a control group. *J Cataract Refract Surg* 2002;28:1160-1172.
- Werner L, Apple DJ, Kaskaloglu M, Pandey SK. Dense opacification of the optical component of a hydrophilic acrylic intraocular lens; a clinicopathological analysis of 9 explanted lenses. *J Cataract Refract Surg* 2001;27:1485-1492.
- Pandey SK, Werner L, Apple DJ, Kaskaloglu MM. Hydrophilic acrylic intraocular lens optic and haptics opacification in a diabetic patient: Bilateral case report and clinicopathological correlation. *Ophthalmology* 2002;109:2042-2051.
- Neuhann IM, Werner L, Izak AM, Pandey SK, Kleinmann G, Mamalis N, et al. Late postoperative opacification of a hydrophilic acrylic (hydrogel) intraocular lens. A clinicopathological analysis of 106 explants. *Ophthalmology* 2004;111:2094-2101.
- Habib NE, Freegard TJ, Gock G, Newman PL, Moate RM. Late surface opacification of Hydroview intraocular lenses. *Eye* 2002;16:69-74.
- Khakshoor H, Gharaee H, Vejan AI, Khakshoor H, Shahabian M. Clinicopathological Report of Three Cases of Opacification in Hydrophilic Acrylic Intraocular Lenses. *Iranian J Ophthalmol* 2013;25:238-243.
- Neuhann IM, Kleinmann G, Apple DJ. A New Classification of Calcification of Intraocular Lenses. *Ophthalmology* 2008;115:73-79.
- Altaie R, Loane E, O'Sullivan K, Beatty S. Surgical and visual outcomes following exchange of opacified Hydroview intraocular lenses. *Br J Ophthalmol* 2007;91:299-302.
- Neuhann IM, Neuhann TF, Szurman P, Koerner S, Rohrbach JM, Bartz-Schmidt KU. Clinicopathological correlation of 3 patterns of calcification in a hydrophilic acrylic intraocular lens. *J Cataract Refract Surg* 2009;35:593-597.
- Tanaka T, Saika S, Hashizume N, Ohnishi Y. Brown haze in an Allergan SI-40NB silicone intraocular lens. *J Cataract Refract Surg* 2004;30:250-252.
- Hilgert CR, Hilgert A, Höfling-Lima AL, Farah ME, Werner L. Early opacification of SI-40NB silicone intraocular lenses. *J Cataract Refract Surg* 2004;30:2225-2229.
- Sathyan P, Myint K, Singh G, Mon S, Sathyan P, Dhillon B. Late green discoloration of Allergan SI-40NB silicone intraocular lens. *J Cataract Refract Surg* 2006;32:1584-1585.
- Werner L. Glistenings and surface light scattering in intraocular lenses. *J Cataract Refract Surg* 2010;36:1398-1420.
- Johnston RL, Spalton DJ, Hussain A, Marshall J. *In vitro* protein adsorption to 2 intraocular lens materials. *J Cataract Refract Surg* 1999;25:1109-1115.
- Rezaei-Kanavi M, Javadi MA, Mirbabaee-Ghafghazi F. Intraocular lens calcification; a clinicopathologic report. *J Ophthalmic Vis Res* 2009;4:122-124.