

Review

Paediatric pulmonary Langerhans cell histiocytosis

Paediatric pulmonary Langerhans cell histiocytosis (pPLCH) is a rare diffuse cystic lung disease. Unlike pulmonary Langerhans cell histiocytosis (LCH) in adults, which is often seen as an isolated condition with smoking being a major risk factor, isolated pPLCH is vanishingly rare in children and it is most often a component of multisystem LCH. Diagnosis should be based on histological and immunophenotypic examination of affected tissue in addition to clinical and radiological features. It should be considered an important differential for diffuse cystic lung disease in paediatric patients. Recent progress in the biological understanding of the disease supports the classification of LCH as an inflammatory myeloid neoplasia. Chemotherapy and specific management of respiratory complications are the mainstays of treatment. The lungs are no longer considered a “risk organ” in LCH as pulmonary involvement is not associated with a worse prognosis than the involvement of other organs. Multidisciplinary treatment approaches are needed.

Prognosis can be good but is adversely influenced by multisystem involvement, and complications such as pneumothoraces and respiratory failure can be life threatening. This review aims to give an overview of this condition, with a focus on the diagnosis, monitoring and management of complications such as pneumothoraces and respiratory failure, which can be challenging for the paediatric respiratory specialist.

Cite as: Barclay M, Devaney R, Bhatt JM. Paediatric pulmonary Langerhans cell histiocytosis. *Breathe* 2020; 16: 200003.

Educational aims

- To give an overview of paediatric pulmonary LCH.
- To discuss the differential diagnosis of paediatric cystic lung disease.

Background

Langerhans cell histiocytosis (LCH), formally known as histiocytosis X, is a rare disease in childhood. It is characterised by clonal proliferation and abnormal

accumulation of immature histiocytes in various tissues and organs, with an associated inflammatory infiltrate. The aetiology of this disorder of myeloid-derived dendritic cells is poorly understood. The pathologic Langerhans-like dendritic cells nearly

 @ERSpublications

Paediatric pulmonary Langerhans cell histiocytosis is a rare diffuse lung disease. Involvement of the lungs is not associated with a worse prognosis than the involvement of other organs but management of respiratory complications are challenging. <http://bit.ly/38mJHFq>



CrossMark



© ERS 2020

Table 1 Similarities and differences between PLCH in children and adults

	Children	Adults
Sites involved	Mostly as part of multisystem LCH	Mostly isolated PLCH
Smoking	Not generally associated with smoking	Nearly universally associated with smoking
Pneumothoraces	Less common as first presentation	More common as first presentation
Radiological findings	Involvement of the costophrenic angle and lower lung fields	Sparing of the costophrenic angle and lower lung fields

always carry mutations in the mitogen-activated protein kinase (MAPK) pathway, most commonly *BRAFV600E* [1–3]. Debate is ongoing as to whether it should be classified as a cancer or a reactive disorder of immune function. Recent progress in the biological understanding of the disease supports the classification of LCH as an inflammatory myeloid neoplasia [4–6].

LCH has a broad clinical spectrum ranging from localised disease, which may be benign and self-limiting, to life-threatening, disseminated disease. LCH can be categorised as single-system LCH, which can be unifocal or multifocal, or less commonly, LCH may involve multiple organs (multisystem LCH), which may involve a limited number of organs or be disseminated disease. Most commonly affected sites include the skin, bone, lymph nodes, thymus, lungs, pituitary gland, liver, spleen, bone marrow and central nervous system. Patients who have liver, spleen or bone marrow involvement are classified as having “high-risk disease” that is associated with a higher risk of death and may be more difficult to treat. The lung was previously considered a “risk organ” but has been excluded from the definition following a multivariate analysis of pulmonary disease in multisystem LCH that showed that pulmonary involvement was not an independent prognostic variable [7], replicating earlier findings by BRAIER *et al.* [8]. Those with “low-risk” disease are at a lower risk of death but may still have a high risk of developing life-threatening complications in the short term (*e.g.* pneumothoraces) or long-term complications of the disease.

LCH has been diagnosed in all age groups but it is most common in young children. There are few published epidemiological studies on paediatric LCH. A prospective surveillance study in the UK and Ireland found the incidence of LCH in children aged 0–14 years to be 4.1 per million per year with median age at diagnosis of 5.9 years [9]. Similar findings were reported in a French study with overall incidence of 4.6 per million per year in children aged 0–15 and median age at diagnosis of 3.5 years [10]. Both studies found a slight male predominance and the incidence to be much higher in those under the age of 1 year at 9.9 per million per year [9] and 15.3 per million per year respectively [10].

Pulmonary Langerhans cell histiocytosis (PLCH) is rare in childhood. Large case series of LCH in children, which included both single

and multisystem disease, showed 7–16% of all LCH cases had pulmonary involvement [8, 11]. The majority of PLCH cases are associated with multisystem disease, as reflected by a higher prevalence of 24–41% when looking only at multisystem LCH cases [7, 8, 11]. ODAME *et al.* [11] found that all the cases of PLCH in their cohort were in the context of multisystem LCH. Isolated PLCH is vanishingly rare in children, though some cases have been described [8, 12–16]. In contrast, the lungs are the most commonly and usually the only organ affected in adults, where there is a clear association with cigarette smoking [17]. Similarities and differences between PLCH in children and adults are described in table 1.

Presentation

Paediatric pulmonary Langerhans cell histiocytosis (pPLCH) is a cystic interstitial lung disease that commonly presents with nonproductive cough, tachypnoea and shortness of breath. Chest pain, wheeze and constitutional symptoms such as malaise, weight loss and fever may also be present [8, 11, 18, 19]. Confluence of cysts can lead to bullous formation; acute pain, dyspnoea and respiratory failure secondary to subsequent pneumothoraces may be the first presentation of pPLCH and can be recurrent [12, 13, 15]. A recent case series by ECKSTEIN *et al.* [20] described seven severely affected paediatric patients with extensive pulmonary cystic LCH, complicated by pneumothoraces at initial presentation or following initiation of treatment. With intensive care support, chest drain insertions and pleurodesis in addition to chemotherapy, five of these patients survived. Pneumothoraces are less common in children compared to the adult population [8, 18, 19]. RADZIKOWSKA *et al.* [21] found that 32% of their predominantly adult population group had pneumothoraces at initial presentation.

pPLCH is most often a component of multisystem LCH. Given that LCH can affect such a variety of organs, the clinical manifestation can be similarly broad, and symptoms reflect the severity and site of involvement. Respiratory symptoms or acute respiratory deterioration may be the primary presentation; however, many patients with lung involvement may have mild or

no respiratory symptoms, with extrapulmonary signs and symptoms being evident first. A case series by ODAME *et al.* [11] showed that only half of the patients with pPLCH presented with significant respiratory symptoms despite diffuse lung involvement demonstrated radiologically. Specific enquiry regarding respiratory symptoms and respiratory examination at diagnosis and at each follow-up visit is therefore important for all patients with LCH. Regardless of the history given or examination findings, chest radiography is recommended as one of the mandatory investigations at diagnosis and disease reactivation as part of pre-treatment clinical evaluation in order to assess for lung involvement [22].

Conversely, in those patients where the lungs are the first identified site of LCH, assessment for involvement of other sites is essential. Detailed history should elicit specific symptoms including skin rashes, pain, swelling, fever, otorrhoea, polydipsia, polyuria, behaviour changes and neurological symptoms. Experts who contributed to the 2013 Euro Histo Network guidelines for paediatric LCH agreed that baseline pre-treatment evaluation should include full blood count, blood chemistry, erythrocyte sedimentation rate, coagulation studies, abdominal ultrasound and skeletal radiograph survey in addition to the aforementioned chest radiography, with further investigations recommended depending on the clinical scenario [22].

Diagnosis

PLCH is a rare disease with heterogeneous presentation, which can make diagnosis challenging. Diagnosis should be based on histological and immunophenotypic examination of

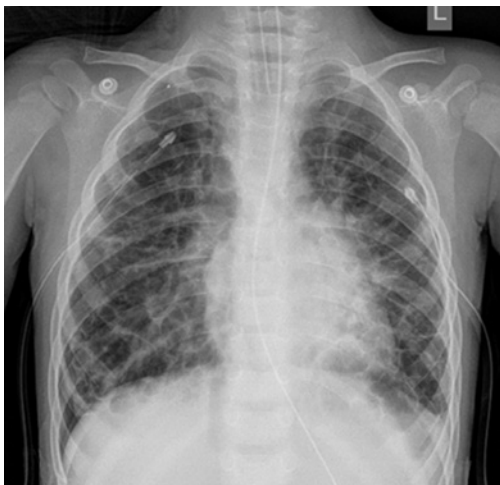

Figure 1 Chest radiograph of a patient with pPLCH. An endotracheal tube and bilateral intercostal chest drains are in situ with a residual right-sided pneumothorax. Extensive cystic changes and abnormal linear interstitial opacification can be seen.

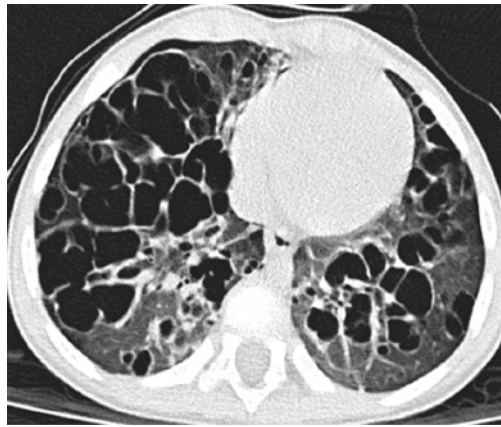


Figure 2 CT image of a patient with pPLCH with extensive cystic changes.

affected tissue in addition to clinical and radiological features [22].

Radiology

The characteristic radiological findings of pPLCH can aid diagnosis (figure 1). Bilateral interstitial infiltrates with a reticulonodular pattern, often with peribronchial thickening, is the commonest radiological finding on chest radiography [8, 11]. Cystic changes and pneumothoraces may also be seen. A high-resolution computed tomography (HRCT) scan would subsequently be recommended [22] and can detect lung lesions in patients where there are no radiological changes on chest radiography but high clinical suspicion due to respiratory symptoms. Characteristic findings on HRCT scan include a reticulonodular infiltrate early in the disease process and cystic changes predominating in more advanced disease (figure 2). These findings are classically symmetrical, and affect the upper and middle lobes. Paediatric and adult populations with PLCH have similar computed tomography (CT) findings, with the exception of sparing of the costophrenic angle in adults, which is almost always involved in children [23–25].

Immunohistological findings

Definitive diagnosis of pPLCH is by bronchoalveolar lavage (BAL) or lung biopsy; however, these may not be necessary if clinical and radiological findings suggest pulmonary involvement, and biopsy from another site (*e.g.* skin) has already confirmed LCH. In this instance, a diagnosis of pPLCH in the context of multisystem LCH could be concluded to avoid the need for a lung biopsy, which has more associated risks. The preferred site for biopsy for histological diagnosis in multisystem disease is the site that requires least invasive biopsy techniques with the lowest associated risk. If isolated PLCH is suspected, which is extremely rare, BAL and lung biopsy would be important to confirm pPLCH and exclude other

causes of cystic lung disease in order to guide management. Of the eight cases found in the literature of isolated pPLCH, all had lung biopsies to confirm the diagnosis [8, 12–16].

Bronchoalveolar lavage

BAL can be performed with flexible bronchoscopy in an area of radiological abnormality. Samples of BAL fluid are sent for cytology with immunostaining; the presence of >5% CD1a⁺ and CD207⁺ cells strongly supports the diagnosis of pPLCH in a nonsmoker [17, 26]. BAL also provides an opportunity to look for respiratory infection, as samples of BAL fluid are also sent for cell count, microscopy and culture.

Lung biopsy

Transbronchial lung biopsies have variable diagnostic yield; therefore, surgical biopsy may be preferable, which is often by video-assisted thoracoscopy and guided by findings on HRCT [17, 27]. A recent French review of 17 lung biopsy samples from pPLCH patients found histological features similar to those more extensively described previously in adult patients with PLCH. These included Langerhans cell nodules with cavitation, cysts, fibrotic scars, peribronchiolar distribution of the lesions and accessory changes like stretch emphysema [25]. Morphological identification of characteristic pathological LCH cells (mononucleated cells with “coffee bean”-shaped nuclei) and positive immunohistochemical staining with CD1a and/or CD207 (langerin) is needed in order to make a definitive diagnosis [22, 28–31]. Staining of the intracellular S100 protein may help to detect LCH cells; however, it is less specific [32]. The indication for lung biopsy is determined by evaluating potential risks and benefits to the patient, as it may be that clinical and radiological findings are sufficient to make a working diagnosis of pPLCH. In children with multisystem disease, diagnosis based on noninvasive biopsies will be less risky and so is preferred. Even when lung biopsy is considered essential, it is best performed in centres where there is a significant throughput of children

undergoing these procedures for diffuse lung diseases. Lung biopsies can yield a confirmatory histological diagnosis in a large proportion of cases but can be associated with significant morbidity and some mortality [33, 34].

According to the initial Histiocyte Society criteria, diagnosis can be described as either definitive (the presence of Birbeck granules on electron microscopy or demonstration of CD1a expression on lesional cells) or presumptive (morphology compatible with LCH and expression of S100 protein by immunohistochemistry in the correct clinical context) [35]. The presence of Birbeck granules identified by electron microscopy was previously considered the “gold standard” for diagnosis; however, detection is no longer required as they have been replaced by CD207 (langerin), which is a cell-surface receptor that induces the formation of Birbeck granules. Hence, the presence of langerin correlates with the presence of Birbeck granules (figure 3) [30, 31, 36].

Pulmonary function testing

Though not part of any diagnostic criteria, pulmonary function testing may be helpful to assess the baseline degree of impairment and to monitor progress over time. This will not, of course, be appropriate, reliable or possible for a number of patients due to their young age. In one study it was noted that abnormalities in pulmonary function preceded chest radiographic changes and clinical abnormalities in a few patients [18]. BERNSTRAND *et al.* [37] found a correlation between HRCT findings and pulmonary function tests; diffusing capacity corrected for alveolar volume and total lung capacity (TLC) were significantly decreased in PLCH patients with extensive abnormalities on HRCT. They propose that pulmonary function testing could be a valuable complement to imaging in monitoring PLCH in the longer term, although the majority of their cohort were adults at the point of follow-up [37]. Further studies in adult populations have shown that physiological evidence of impaired pulmonary function, such as lower forced expiratory volume in 1 s (FEV₁), lower FEV₁/forced vital capacity (FVC) ratio and higher residual volume/TLC ratio (indicating air trapping) are predictive of worse outcomes [38]. Similar data are yet to be collected from paediatric patients but these studies provide a useful premise for exploring use of pulmonary function tests in children with PLCH where appropriate, not only at diagnosis as a prognostic indicator but also for longer term follow-up, which in some cases would be into adulthood.

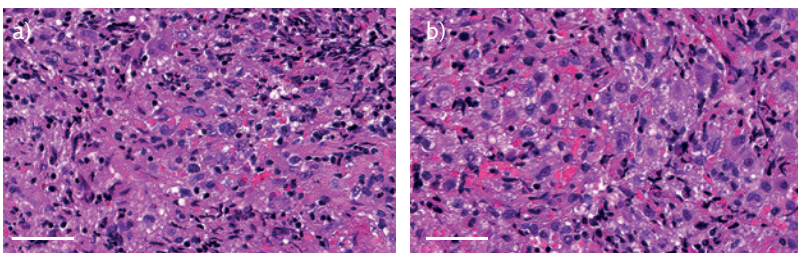


Figure 3 a and b) Lung biopsy from the patient in figure 2 shows lung parenchyma that features conspicuous nodular aggregates, typically extending into airspaces, of variably sized medium and large cells, some multinucleated, featuring open nuclei that are focally clefted. Cells within the nodular infiltrates are highlighted under antisera to CD1a and S100 protein by immunohistochemical staining. Scale bars=50 µm.

Differential diagnosis of paediatric cystic lung disease

LCH affecting just the lung tissue is rare in children. It is worth considering that cystic lung disease in

Table 2 Differential diagnoses of diffuse cystic lung disease in children [39–42]

Cystic lung disease	Pulmonary manifestations	Other potential features	Genetic defect/ association, if known	Prevalence/onset
Birt-Hogg-Dubé syndrome	Characteristic CT findings of multiple, thin-walled, air-filled cysts; no interstitial lung disease	Hair follicle tumours, renal tumours, family history of pneumothorax in 35% [39]	Autosomal dominant, <i>FLCN</i> (folliculin gene) on chromosome 17	Rare and often diagnosed in early to mid-adulthood but has been reported in teenagers
Lung cysts associated with <i>FLNA</i> mutation [43, 44]	Multiple lung cysts	Cerebral periventricular nodular heterotopia, cardiac valvular disease, skeletal abnormalities	<i>FLNA</i> (filamin A gene) mutation	Childhood cases
Congenital cystic lung lesions	Bronchogenic cysts/ congenital pulmonary airway malformations	Infection, bleeding, compression of other structures, concerns over malignancy		Antenatally or may be detected later in childhood or in an adult
Bronchopulmonary dysplasia	Disruption in distal lung growth	Preterm birth, complications associated with this	Genetic contribution unclear	Normally suspected from history of preterm birth or need for oxygen/ventilation
Infective	Staphylococcal infections may be associated with pneumatocele development	May occur in association with hyper-IgE syndrome	<i>STAT3</i> and <i>DOCK8</i> mutations associated with hyper-IgE syndrome [46]	Can present in childhood
Pleuropulmonary blastoma	Can have cystic and solid components depending on subtype	Most common paediatric pulmonary neoplasm	<i>DICER1</i> mutations [47]	Children <6 years of age
Down syndrome [45]	Subpleural cystic areas	Cardiac problems, developmental delay	Trisomy 21	Can be suspected and diagnosed antenatally or shortly after birth

children has a wide differential diagnosis (table 2). This can be divided into congenital cystic lung lesions and those acquired later (*e.g.* post-infective or the cystic form of pleuropulmonary blastoma) [48]. The most common type of cystic lung lesion in children are those found as a result of a congenital abnormality. There are also conditions such as congenital lobar hyperinflation/hyperlucent lung and bronchopulmonary dysplasia that may present with hyperlucent areas on imaging.

Acquired conditions

Acquired cystic conditions include post infective or cystic areas acquired after infarction [48].

Management

As PLCH is relatively rare in children, most clinicians may only see a small number of cases in their career. There are several case reports in the literature describing management strategies used by different clinicians; given the rarity of the condition, some of these are international collaborations [20]. Many of the approaches have been adapted from treatments

used in adults where pulmonary disease is more common. Most children with pPLCH, however, have this as part of multisystem disease rather than isolated lung involvement and the pathophysiology may differ [11]. Multidisciplinary treatment approaches are needed.

General respiratory health including smoking cessation

In adults, unlike in children, PLCH is most often isolated and is strongly associated with smoking. One of the most important management steps for adults is therefore smoking cessation, which can result in significant clinical improvement and often complete resolution of disease, whereby systemic treatment may not be needed [17, 22, 49]. If an adolescent patient with pPLCH were a smoker, it would therefore be prudent to evaluate response to smoking cessation prior to systemic therapy. Disease in children is often a multisystem disease and is thought to represent a different condition; however, avoidance of second-hand smoke/vaping exposure is a sensible strategy for maintaining general respiratory health in children and should be advised. Annual

Self-assessment questions

1. A 6-year-old boy presents with limp and worsening pain in his right thigh. Radiography of the femur shows a lytic lesion of the femur. There is hepatosplenomegaly on examination. Subsequent biopsy of the bone lesion shows positive immunohistochemical staining of CD1a and CD207. On further questioning, the child had a persistent cough but no other respiratory symptoms. Which of the following statements are true?
 - a) This patient has multifocal, multisystem LCH.
 - b) This patient has high-risk disease.
 - c) This patient is at risk of pneumothoraces.
 - d) This patient is unlikely to have pPLCH.
2. These patients may have no significant respiratory symptoms despite diffuse lung involvement demonstrated radiologically. In a patient with suspected pPLCH, which of the following are true?
 - a) Presence of Birbeck granules on bone biopsy confirms diagnosis.
 - b) Diffuse multicystic disease and isolated pulmonary involvement are common.
 - c) Pulmonary involvement is considered as high risk for death.
 - d) If the patient passes a hypoxic challenge test, it is safe for them to fly.

influenza vaccination is also recommended [50] and other aspects to good respiratory health such as dry, warm housing and exercise should be emphasised.

The potential implications of hypoxia or air leak during commercial flights in children with diffuse/severe cystic lung disease need to be discussed with young people/parents. They may require a normobaric hypoxic challenge test to determine the need for supplemental oxygen. Additionally, in flight, there is a decrease in barometric pressure with an increase in altitude that can lead to a 25–30% expansion of gas within enclosed spaces in the human body. In a closed cyst, this expansion may lead to rupture, potentially causing pneumothorax or pneumomediastinum. A controlled depressurisation, in a clinically supervised environment by hypobaric chamber testing, may afford a degree of confidence that the patient would tolerate the pressure changes during commercial flights [51].

Chemotherapy

Chemotherapy has been used in the management of children with multisystem LCH including drugs such as vinblastine and 6-mercaptopurine [52]. A combination of vinblastine and steroids is an accepted first-line treatment for paediatric multisystem LCH according to international guidelines [22]. This is based on evidence from randomised trials and prospective studies from the Histiocyte Society that began as international collaborations in the 1990s [53–55]. Vinblastine with prednisolone has been studied to help improve 5-year survival probability and reduce

disease reactivation. Interestingly, in adult patients, those with PLCH and impaired lung function did not appear to improve with the use of vinblastine [56]. Some children have shown a poor response to chemotherapy with vinblastine, prednisone and etoposide, but have shown some improvement with other drugs such as cyclosporine, oral methotrexate and 6-mercaptopurine [57]. It is important to consider offering patients the opportunity to enrol in clinical trials to improve the evidence base of management for this rare condition. It can be difficult to tell which is the most effective treatment strategy, as often children are treated with a variety of different agents [20].

Cytarabine, a pyrimidine analogue that inhibits DNA synthesis, is a chemotherapeutic agent that has been used in patients with LCH [20, 27], sometimes in combination with other agents.

In 2015, cladribine (a purine analogue) was described in the *European Respiratory Journal* in the treatment of a child with pPLCH [52]. This child showed improvement in lung cysts on imaging, and FEV₁ and FVC values on spirometry. There was also reported symptomatic improvement in terms of dyspnoea. The child had previously received treatment with vinblastine and 6-mercaptopurine [52]. The use of cladribine has been used in adult patients for much longer than in paediatrics, however, and the efficacy and safety are still being fully evaluated in trials. Cladribine has been noted to cause immunosuppression and pancytopenia [49], and so cover for opportunistic infection is important to consider.

Haemopoietic stem cell transplant has been attempted in children with refractory LCH and risk-organ involvement; however, the indications and prognostic factors remain unclear [58].

Specific management of pulmonary disease

Patients with recurrent pneumothoraces associated with their cystic lung disease may benefit from surgical management such as pleurodesis (in 85% of cases in the Eckstein *et al.* [20] case series) and commonly may require the insertion of chest drains, sometimes recurrently.

Ventilation strategies to deal with the risk of recurrent air leaks must be considered in intensive care for children with respiratory failure. The use of ECMO (extracorporeal membrane oxygenation) to allow time for the benefits of chemotherapy or for lung transplantation has also been discussed [59]. Clearly, this is a difficult consideration when prognosis is often unpredictable. Recurrence of disease in transplanted lungs has also been reported [60].

New/emerging treatment approaches

Now that more of the biology behind LCH is understood, the use of targeted MAPK therapy

agents such as vemurafenib, dabrafenib or trametinib looks promising, especially for patients with disease that has been recurrent or difficult to treat [61].

Prognosis

The prognosis of children with pPLCH is generally considered to be positive, even in children with severe disease, if there is an early diagnosis and appropriate treatment. In a 2009 UK and Ireland study looking at the incidence of LCH, three out of 94 children with LCH identified over a 2-year period died [9]. Two-thirds of these children had a *post mortem* diagnosis and all of the children that died had multisystem LCH. The majority of children in this study had single-system LCH, however [9]. Although spontaneous resolution may occur in patients with single-system, unifocal LCH (*e.g.* solitary bone or skin lesions), PLCH is most often a component of multisystem LCH, which is not known to regress spontaneously. Treatment is therefore justified according to international guidelines to help control disease activity, and therefore reduce associated complications, morbidity and mortality [22]. Treatment not only aims to mitigate against immediate risk from complications such as life-threatening pneumothoraces and respiratory failure, but also reduces the impact of possible long-term sequelae such as fibrosis and restrictive lung disease [11], and therefore would also be recommended in cases of isolated pPLCH [22].

With appropriate treatment, children with pPLCH can show marked improvement in the appearance of

their disease on CT scans [11, 20]. An international case series of children with severe pLCH described how after treatment, five out of seven patients survived and overall had a good functional outcome in terms of good exercise tolerance, with several showing disease resolution and remaining well having had many years off treatment. These children were noted to show improved pulmonary function at follow-up [20].

The prognosis in paediatric LCH is significantly influenced by whether other organs are involved (multisystem disease). In children with multisystem LCH, who make up the majority of those with pulmonary disease, intensified treatment regimens have been associated with a better prognosis. Clearly for this to be possible, however, a prompt diagnosis is necessary [53]. In an Austrian study of 420 children with paediatric multisystem LCH, the 5-year survival rate varied from 65% to 73% in children with involvement of the liver, spleen or haematopoietic system, but was 94–96% in children who did not have this involvement. Pulmonary involvement was not considered to be an independent prognostic variable [7]. Complications of the condition and associated treatment for pulmonary disease, however, may lead to morbidity [62] and can potentially be life threatening (*e.g.* pneumothoraces and respiratory failure), leading to the need for intensive care support. There are cases in the literature of isolated pPLCH being associated with rapid deterioration, and consideration of treatments such as ECMO and lung transplantation [63]. Children with this condition require careful surveillance as the outcome can be difficult to predict.

Suggested answers

1. a, b and c.
2. a.

Key points

- Paediatric pulmonary Langerhans cell histiocytosis (LCH) is a rare disease but an important differential diagnosis for diffuse cystic lung disease.
- Paediatric pulmonary LCH is most often a component of multisystem LCH.
- The lungs are no longer considered a “risk organ” in LCH as pulmonary involvement is not associated with a worse prognosis than the involvement of other organs.
- Chemotherapy and specific management of respiratory complications are the mainstays of treatment.
- Prognosis can be good but is adversely affected by multisystem involvement. Complications such as pneumothoraces and respiratory failure can be life threatening. Early response to treatment is associated with improved outcomes, however.

Affiliations

Mhairi Barclay¹, Rebecca Devaney¹, Jayesh. M. Bhatt²

¹Paediatric Respiratory Medicine, Nottingham University Hospitals NHS Trust, Nottingham, UK. ²Nottingham Children’s Hospital, Nottingham University Hospitals NHS Trust, Nottingham, UK.

Conflict of interest:

M. Barclay has nothing to disclose. R. Devaney has nothing to disclose. J.M. Bhatt has nothing to disclose.

References

- Badalian-Very G, Vergilio JA, Degar BA, *et al.* Recurrent *BRAF* mutations in Langerhans cell histiocytosis. *Blood* 2010; 116: 1919–1923.
- Berres ML, Lim KPH, Peters T, *et al.* *BRAF*-V600E expression in precursor versus differentiated dendritic cells defines clinically distinct LCH risk groups. *J Exp Med* 2014; 211: 669–683.
- Chakraborty R, Hampton OA, Shen X, *et al.* Mutually exclusive recurrent somatic mutations in *MAP2K1* and *BRAF* support a central role for ERK activation in LCH pathogenesis. *Blood* 2014; 124: 3007–3015.
- Berres ML, Merad M, Allen CE. Progress in understanding the pathogenesis of Langerhans cell histiocytosis: back to Histiocytosis X? *Br J Haematol* 2015; 169: 3–13.
- Zinn DJ, Chakraborty R, Allen CE. Langerhans cell histiocytosis: emerging insights and clinical implications. *Oncology* 2016; 30: 122–132.
- Allen C, Merad M, McClain K. Langerhans-cell histiocytosis. *N Engl J Med* 2018; 379: 856–868.
- Ronceray L, Pötschger U, Janka G, *et al.* Pulmonary involvement in pediatric-onset multisystem langerhans cell histiocytosis: effect on course and outcome. *J Pediatr* 2012; 161: 129–133.
- Braier J, Latella A, Balancini B, *et al.* Outcome in children with pulmonary Langerhans cell histiocytosis. *Pediatr Blood Cancer* 2004; 43: 765–769.
- Salotti JA, Nanduri V, Pearce MS, *et al.* Incidence and clinical features of Langerhans cell histiocytosis in the UK and Ireland. *Arch Dis Child* 2009; 94: 376–380.
- Guyot-Goubin A, Donadieu J, Barkaoui M, *et al.* Descriptive epidemiology of childhood Langerhans cell histiocytosis in France, 2000–2004. *Pediatr Blood Cancer* 2008; 51: 71–75.
- Odame I, Li P, Lau L, *et al.* Pulmonary Langerhans cell histiocytosis: a variable disease in childhood. *Pediatr Blood Cancer* 2006; 47: 889–893.
- Chatkin JM, Bastos JC, Stein RT, *et al.* Sole pulmonary involvement by Langerhans' cell histiocytosis in a child. *Eur Respir J* 1993; 6: 1226–1228.
- Braier J, Latella A, Balancini B, *et al.* Isolated pulmonary Langerhans cell histiocytosis presenting with recurrent pneumothorax. *Pediatr Blood Cancer* 2007; 48: 241–244.
- Nagy B, Soós G, Nagy K, *et al.* Natural course of isolated pulmonary Langerhans' cell histiocytosis in a toddler: 3-year follow-up. *Respiration* 2008; 75: 215–220.
- Valliani L, Schwartz A. Isolated pulmonary Langerhans cell histiocytosis with recurrent bilateral pneumothoraces treated with chemotherapy and chemical pleurodesis. *Pediatr Blood Cancer* 2009; 53: 128–129.
- Varkki S, Tergestina M, Bhonsle VS, *et al.* Isolated pulmonary Langerhans cell histiocytosis. *Indian J Pediatr* 2013; 80: 700–703.
- Vassallo R, Ryu JH, Colby TV, *et al.* Pulmonary Langerhans'-cell histiocytosis. *N Engl J Med* 2000; 342: 1969–1978.
- Ha SY, Helms P, Fletcher M, *et al.* Lung involvement in Langerhans' cell histiocytosis: prevalence, clinical features and outcome. *Pediatrics* 1992; 89: 466–469.
- Jezierska M, Stefanowicz J, Romanowicz G, *et al.* Langerhans cell histiocytosis in children – a disease with many faces. Recent advances in pathogenesis, diagnostic examinations and treatment. *Postepy Dermatol Alergol* 2018; 35: 6–17.
- Eckstein OS, Nuchtern JG, Mallory GB. Management of severe pulmonary Langerhans histiocytosis in children. *Pediatr Pulmonol* 2020; in press.
- Radzikowska E, Błasińska-Przerwa K, Wiatr E, *et al.* Pneumothorax in patients with pulmonary Langerhans cell histiocytosis. *Lung* 2018; 196: 715–720.
- Haupt R, Minkov M, Astigarraga I, *et al.* Langerhans cell histiocytosis (LCH): guidelines for diagnosis, clinical work-up, and treatment for patients till the age of 18 years. *Pediatr Blood Cancer* 2013; 60: 175–184.
- Abbritti M, Mazzei MA, Bargagli E, *et al.* Utility of spiral CAT scan in the follow-up of patients with pulmonary Langerhans cell histiocytosis. *Eur J Radiol* 2012; 81: 1907–1912.
- Bano S, Chaudhary V, Narula MK, *et al.* Pulmonary Langerhans cell histiocytosis in children: a spectrum of radiologic findings. *Eur J Radiol* 2014; 83: 47–56.
- Kambouchner M, Emile JF, Copin MC, *et al.* Childhood pulmonary Langerhans cell histiocytosis: a comprehensive clinical–histopathological and *BRAF*^{V600E} mutation study from the French national cohort. *Hum Pathol* 2019; 89: 51–61.
- Harari S, Torre O, Cassandro R, *et al.* Bronchoscopic diagnosis of Langerhans cell histiocytosis and lymphangioleiomyomatosis. *Respir Med* 2012; 106: 1286–1292.
- King TE, Flaherty KR, Newburger P, *et al.* Pulmonary Langerhans cell histiocytosis. <https://www.uptodate.com/contents/pulmonary-langerhans-cell-histiocytosis?search=pulmonary> Date last accessed: 4 June 2020.
- Leung AKC, Lam JM, Leong KF. Childhood Langerhans cell histiocytosis: a disease with many faces. *World J Pediatr* 2019; 15: 536–545.
- Emile JF, Abla O, Fraitag S, *et al.* Revised classification of histiocytoses and neoplasms of the macrophage-dendritic cell lineages. *Blood* 2016; 127: 2672–2681.
- Lau SK, Chu PG, Weiss LM. Immunohistochemical expression of Langerin in Langerhans cell histiocytosis and non-Langerhans cell histiocytic disorders. *Am J Surg Pathol* 2008; 32: 615–619.
- Valladeau J, Ravel O, Dezutter-Dambuyant C, *et al.* Langerin, a novel C-type lectin specific to Langerhans cells, is an endocytic receptor that induces the formation of Birbeck granules. *Immunity* 2000; 12: 71–81.
- Tazi A. Adult pulmonary Langerhans' cell histiocytosis. *Eur Respir J* 2006; 27: 1272–1285.
- Greenhalgh R, Yardley I, Child F, *et al.* Lung biopsy for chronic pulmonary disease in children. *J Pediatr Surg* 2014; 49: 1075–1077.
- Houmes R, ten Kate C, Wildschut E, *et al.* Risk and relevance of open lung biopsy in pediatric ECMO patients: the Dutch experience. *J Pediatr Surg* 2017; 52: 405–409.
- Writing group of the Histiocyte Society. Histiocytic syndromes in children. *Lancet* 1987; 1: 208–209.
- Morimoto A, Oh Y, Shioda Y, *et al.* Recent advances in Langerhans cell histiocytosis. *Pediatr Int* 2014; 56: 451–461.
- Bernstrand C, Cedurlund K, Henter J. Pulmonary function testing and pulmonary Langerhans cell histiocytosis. *Pediatr Blood Cancer* 2007; 49: 323–362.
- Vassallo R, Ryu J, Schroeder D, *et al.* Clinical outcomes of Pulmonary Langerhans'-cell histiocytosis in Adults. *N Engl J Med* 2002; 346: 484–490.
- Gupta N, Seyama K, McCormack F. Pulmonary manifestations of Birt-Hogg-Dubé syndrome. *Fam Cancer* 2013; 12: 387–396.
- Gupta N, Vassallo R, Wikenheiser-Brokamp KA, *et al.* Diffuse cystic lung disease: part I. *Am J Respir Crit Care Med* 2015; 191: 1354–1366.
- Gupta N, Vassallo R, Wikenheiser-Brokamp KA, *et al.* Diffuse cystic lung disease: part II. *Am J Respir Crit Care Med* 2015; 192: 17–29.
- Obaidat B, Yazdani D, Wikenheiser-Brokamp K, *et al.* Diffuse cystic lung diseases. *Respir Care* 2020; 65: 111–126.
- Carlens J, Price T, Bültmann E, *et al.* Interstitial lung disease caused by filamin A gene mutations: clinical course of three paediatric cases. *Eur Respir J* 2016; 48: Suppl. 60, PA3913.
- Emiralioglu N, Kiper N, Schwerk N, *et al.* An insight of lung cysts with filamin A mutation. *Eur Respir J* 2015; 46: Suppl. 59, PA3833.

45. George M, Amodio J, Lee H. Cystic lung disease in Down syndrome: a case report and literature review. *Case Rep Pediatr* 2016; 2016: 4048501.
46. Deng Y, Li T, Xie X, *et al.* Hyper IgE syndrome associated with novel and recurrent *STAT3* mutations: two case reports. *Medicine (United States)* 2019; 98: 1-5.
47. Schultz KA, Yang J, Ph D, *et al.* DICER1 -pleuropulmonary blastoma familial tumor predisposition syndrome: a unique constellation of neoplastic conditions. *Pathol Case Rev* 2014; 19: 90-100.
48. Stocker JT. Cystic lung disease in infants and children. *Fetal Pediatr Pathol* 2009; 28: 155-184.
49. Lorillon G, Tazi A. How I manage pulmonary langerhans cell histiocytosis. *Eur Respir Rev* 2017; 26: 170070.
50. Girschikofsky M, Arico M, Castillo D, *et al.* Management of adult patients with Langerhans cell histiocytosis: recommendations from an expert panel on behalf of Euro-Histio-Net. *Orphanet J Rare Dis* 2013; 8: 72.
51. Loo S, Campbell A, Vyas J, *et al.* Case report of a hypobaric chamber fitness to fly test in a child with severe cystic lung disease. *Pediatrics* 2017; 140: e20162376.
52. Epaud R, Ducou Le Pointe H, Fasola S, *et al.* Cladribine improves lung cysts and pulmonary function in a child with histiocytosis. *Eur Respir J* 2015; 45: 831-833.
53. Gadner H, Grois N, Pötschger U, *et al.* Improved outcome in multisystem Langerhans cell histiocytosis is associated with therapy intensification. *Blood* 2008; 111: 2556-2562.
54. Gadner H, Grois N, Arico M, *et al.* A randomized trial of treatment for multisystem Langerhans' cell histiocytosis. *J Pediatr* 2001; 138: 728-734.
55. Gadner H, Minkov M, Grois N, *et al.* Therapy prolongation improves outcome in multisystem Langerhans cell histiocytosis. *Blood* 2013; 121: 5006-5014.
56. Tazi A, Lorillon G, Haroche J, *et al.* Vinblastine chemotherapy in adult patients with langerhans cell histiocytosis: a multicenter retrospective study. *Orphanet J Rare Dis* 2017; 12: 95.
57. Zeller B, Storm-Mathisen I, Smevik B, *et al.* Multisystem Langerhans-cell histiocytosis with life-threatening pulmonary involvement - good response to cyclosporine A. *Med Pediatr Oncol* 2000; 35: 438-442.
58. Kudo K, Maeda M, Suzuki N, *et al.* Nationwide retrospective review of hematopoietic stem cell transplantation in children with refractory Langerhans cell histiocytosis. *Int J Hematol* 2020; 111: 137-148.
59. Yule SM, Hamilton JRL, Windebank KP. Recurrent pneumomediastinum and pneumothorax in Langerhans cell histiocytosis. *Med Pediatr Oncol* 1997; 29: 139-142.
60. Habib SB, Congleton J, Carr D, *et al.* Recurrence of recipient langerhans' cell histiocytosis following bilateral lung transplantation. *Thorax* 1998; 53: 323-325.
61. Thacker NH, Abla O. Pediatric Langerhans cell histiocytosis: state of the science and future directions. *Clin Adv Hematol Oncol* 2019; 17: 122-131.
62. Smets A, Mortelé K, De Praeter G, *et al.* Pulmonary and mediastinal lesions in children with Langerhans cell histiocytosis. *Pediatr Radiol* 1997; 27: 873-876.
63. Sacco O, Moscatelli A, Conte M, *et al.* Long-term extracorporeal membrane oxygenation as bridging strategies to lung transplantation in rapidly devastating isolated Langerhans cell histiocytosis. *Pediatr Blood Cancer* 2016; 63: 941-943.