

Intra-arterial infusion of fasudil hydrochloride for cerebral vasospasm secondary to carotid artery stenting: illustrative case

Nozomi Sasaki, MD, Yoshinori Kotani, MD, PhD, Yohei Ito, MD, and Shinji Noda, MD, PhD

Department of Neurosurgery, Chuno Kosei Hospital, Gifu-ken, Japan

BACKGROUND Hypoperfusion due to intracranial cerebral vasospasm after carotid artery stenting (CAS) is rare. The authors presented a case of selective intraarterial infusion of fasudil hydrochloride for cerebral vasospasm after CAS.

OBSERVATIONS A 73-year-old man received CAS for asymptomatic right cervical internal carotid artery stenosis. Twelve hours after CAS, disturbance of consciousness, left hemiplegia, and right conjugate deviation appeared in the patient. Head computed tomography angiography showed diffuse vasospasm of the right middle cerebral artery (MCA). The authors hypothesized that the cause of the symptoms was hypoperfusion due to intracranial cerebral vasospasm. Medical treatment was started; however, the focal symptoms worsened rapidly. Therefore, the authors decided to infuse fasudil intraarterially. This treatment resulted in a remarkable improvement in blood flow and gradual recovery from neurological symptoms. Head magnetic resonance angiography on the day after fasudil infusion showed improved visualization of the right MCA. The neurological symptoms almost completely disappeared 22 hours after fasudil infusion (40 hours after CAS).

LESSONS As a complication after CAS, the possibility of hypoperfusion due to cerebral vasospasm should be considered. If symptoms due to hypoperfusion worsen even after medical treatment, intraarterial infusion of fasudil may be an effective option.

<https://thejns.org/doi/abs/10.3171/CASE2251>

KEYWORDS carotid artery stenting; cerebral vasospasm; intra-arterial infusion of fasudil hydrochloride

The most common complications of carotid artery stenting (CAS) include cerebral infarction due to debris or thrombus from a plaque, intrastent thrombus formation, restenosis, hyperperfusion syndrome, cerebral hemorrhage, and myocardial infarction.¹ Because hypoperfusion due to intracranial cerebral vasospasm after CAS is rare, few such cases have been reported.^{2,3} We present a case that, to the best of our knowledge, is the first report of selective intraarterial infusion of fasudil hydrochloride for cerebral vasospasm after CAS.

Illustrative Case

A 73-year-old man was admitted to receive CAS for asymptomatic right cervical internal carotid artery (ICA) stenosis that gradually worsened over 2 years. Neck magnetic resonance angiography (MRA) revealed right cervical ICA stenosis (Fig. 1A). Black-blood

T1-weighted magnetic resonance imaging showed a high-intensity signal in the plaque (Fig. 1B). Carotid ultrasound showed an echolucent plaque with a maximum peak systolic velocity of 149 cm/s. Neck computed tomography angiography (CTA) showed 70% stenosis in the right cervical ICA according to the North American Symptomatic Carotid Endarterectomy Trial criteria (Fig. 1C).

The patient received dual antiplatelet therapy for 2 weeks to be hospitalized and received CAS using the Mo.Ma Ultra (Medtronic) and distal filter protection device (FilterWire EZ, Boston Scientific). The stent (Carotid Wallstent, 10 × 31 mm, Boston Scientific) was deployed after predilation. Angiography after postdilation showed no in-stent thrombus or intracranial abnormalities (Fig. 1D–F). When we completed the CAS procedure, the patient had no neurological abnormalities. However, 12 hours after CAS, disturbance of consciousness, left hemiplegia, and right conjugate deviation appeared. We

ABBREVIATIONS CAS = carotid artery stenting; CBF = cerebral blood flow; CBV = cerebral blood volume; CPP = cerebral perfusion pressure; CTA = computed tomography angiography; CTP = computed tomography perfusion; ICA = internal carotid artery; MCA = middle cerebral artery; MRA = magnetic resonance angiography; MTT = mean transit time; RCVS = reversible cerebral vasoconstriction syndrome; SAH = subarachnoid hemorrhage.

INCLUDE WHEN CITING Published May 9, 2022; DOI: 10.3171/CASE2251.

SUBMITTED January 29, 2022. **ACCEPTED** March 3, 2022.

© 2022 The authors, CC BY-NC-ND 4.0 (<http://creativecommons.org/licenses/by-nc-nd/4.0/>).

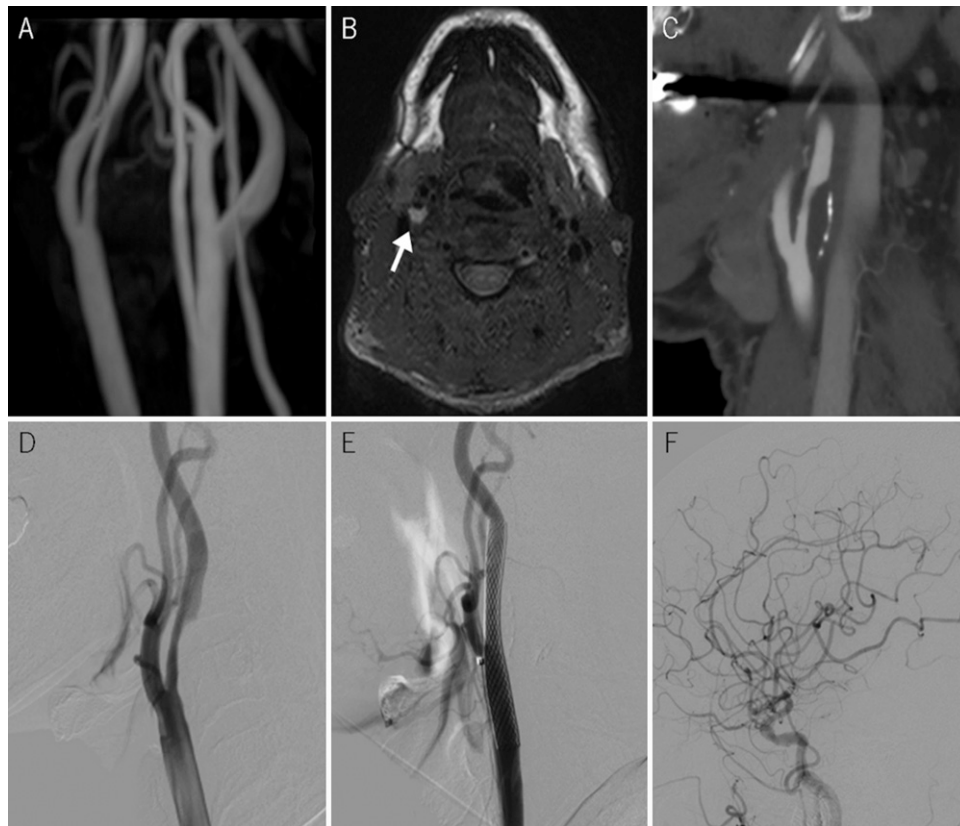


FIG. 1. A: Neck MRA shows right cervical ICA stenosis **B:** Black-blood T1-weighted magnetic resonance imaging shows a high-intensity signal in the plaque (*arrow*). **C:** Neck CTA shows 70% stenosis according to the North American Symptomatic Carotid Endarterectomy Trial criteria. **D:** Preoperative digital subtraction angiography (DSA), lateral view, showing severe stenosis in the right ICA. Postoperative DSA, lateral views, shows a dilated stenotic lesion after CAS (**E**) and no intracranial abnormalities (**F**).

considered that the cause of the symptoms was the distal embolism of thrombus or epilepsy due to hyperperfusion, a major complication of CAS. Thus, we administered levetiracetam and a continuous infusion of argatroban. At the same time, we performed radiological examination. Head MRA showed poor visualization of the right middle cerebral artery (MCA) (Fig. 2A). Head CTA showed diffuse vasospasm of the right MCA (Fig. 2B), and neck CTA showed no problems with the carotid stent. Computed tomography perfusion (CTP) showed that the cerebral blood flow (CBF) and cerebral blood volume (CBV) were lower in the right hemisphere than in the contralateral hemisphere, whereas the mean transit time (MTT) was higher (Fig. 2C–E). Therefore, we hypothesized that the cause of the symptoms was hypoperfusion due to intracranial cerebral vasospasm. Medical treatment, such as a continuous infusion of calcium channel blocker, hypervolemic therapy due to low molecular weight dextran administration, and hypertension therapy were started. We used nicardipine hydrochloride as calcium channel blocker and dobutamine hydrochloride as hypertension therapy. Despite the use of low dose of nicardipine, it resulted in a decrease in blood pressure. The focal symptoms worsened rapidly. Therefore, we decided to administer intraarterial fasudil hydrochloride infusion therapy. Because calcium channel blocker might have a particularly strong effect on lowering blood pressure for this patient, we chose fasudil for intraarterial infusion therapy. Digital subtraction angiography revealed a diffuse vasospasm of the right MCA

(Fig. 3A). Notably, 30 mg of fasudil hydrochloride (1.5 mg/ml) was administered by superselective infusion via a microcatheter positioned at the proximal portion of the right MCA by an infusion pump at a constant rate of 4 mg/min. There was no decrease in blood pressure due to intraarterial infusion of fasudil. This treatment resulted in a remarkable improvement of the blood flow on angiography (Fig. 3B) and gradual recovery from neurological symptoms. In the intensive care unit, the patient received a continuous infusion of calcium channel blockers and hypervolemic therapy. We used diltiazem hydrochloride instead of nicardipine as calcium channel blocker. No decrease in blood pressure due to diltiazem was observed. Head MRA on the day after fasudil infusion showed improved visualization of the right MCA (Fig. 3C). Additionally, CTP performed 4 days after fasudil infusion showed an improvement in the CBF, CBV, and MTT of the right hemisphere. The neurological symptoms were observed to almost completely disappear 22 hours after fasudil infusion (40 hours after CAS). The patient was discharged without neurological deficits 3 weeks after CAS.

Discussion

Observations

The mechanism of cerebral vasospasm after CAS is unclear because it is a rare condition. However, three possible mechanisms can be considered based on the literature. The first mechanism is

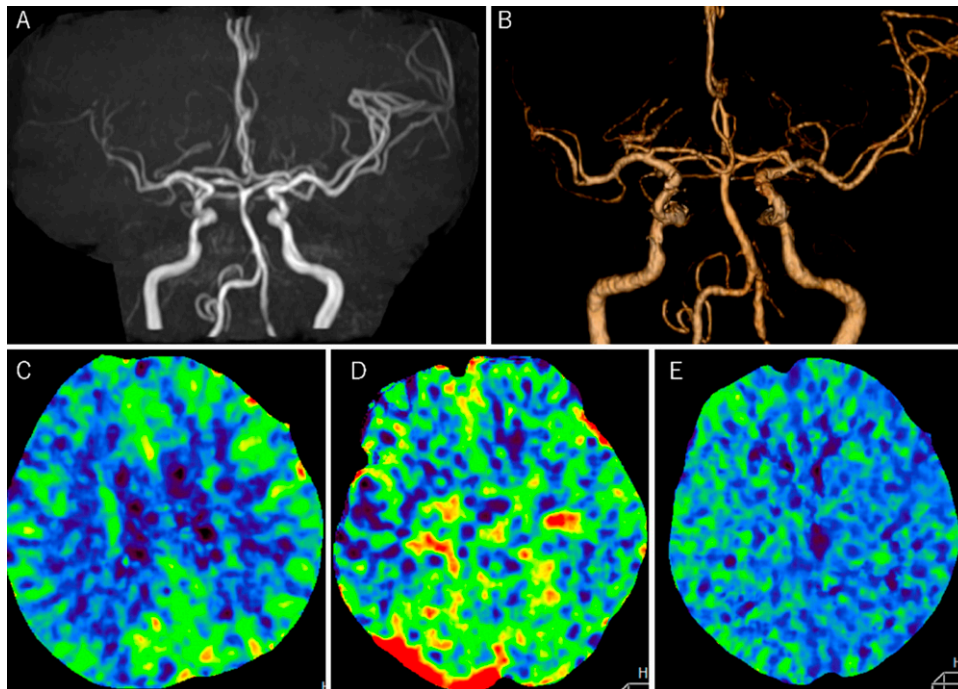


FIG. 2. Head MRA and CTA 12 hours after CAS show poor visualization and diffuse vasospasm of the right MCA (**A and B**). CT perfusion shows that CBF (**C**) and CBV (**D**) in the right hemisphere were lower than that in the contralateral hemisphere, whereas MTT (**E**) was higher.

that the distal embolism of debris or thrombus from a plaque causes mechanical irritation.² If a distal embolism occurs during surgery, neurological symptoms may occur during or immediately after surgery. However, plaque deviation and thrombus formation can occur after surgery. If a thrombus was scattered several hours later, a late-onset vasospasm was observed.⁴ The second mechanism is reversible cerebral vasoconstriction syndrome (RCVS).^{2,4-7} RCVS is a reversible cerebral vasospasm that develops with thunderclap headache and usually improves within 3 months.⁷ Various triggers, such as pregnancy, migraine, drugs, head trauma, hypercalcemia, and carotid endarterectomy, have been reported.^{2,4,6} Vascular endothelial cell dysfunction and abnormal sympathetic nerve excitement cause cerebral vasospasm.⁵⁻⁷ Watanabe et al. reported that RCVS after CAS often occurs more than 2 weeks later.⁷ However, our case occurred several hours after surgery. The third mechanism involves the disruption of autoregulation of the cerebral vasculature.^{2,3} Normally, due to autoregulation of the cerebral vasculature, the cerebral vessels constrict when cerebral perfusion pressure (CPP) increases and dilates when CPP decreases. Owing to this autoregulation system, CBF is constantly maintained regardless of the increase or decrease in CPP. However, in the presence of chronic intracranial hypoperfusion due to carotid artery stenosis, autoregulation of the cerebral vasculature is often impaired.^{2,3} If autoregulation is completely disrupted, the cerebral vessels cannot constrict, which results in hyperperfusion syndrome after CAS. If autoregulation is incompletely disrupted, diffuse cerebral vasospasm may occur due to excessive cerebral vascular contraction.³ Chronic hypoperfusion affects autoregulation. It has been reported that cerebral vasospasm after CAS occurs more frequently in patients with near-total occlusion and without Willisian collaterals.³

It has been reported that cerebral vasospasm occurs within 24 hours^{2,3,5} and a few weeks after CAS.^{6,7} The mechanism of vasospasm may differ between the two groups. It is thought that if autoregulation of the cerebral vasculature is disrupted, it will occur relatively early after CAS; additionally, if the cause is RCVS, it will occur a little later. In our case, the onset was relatively early (12 hours after the operation); additionally, there was no intrastent thrombus on angiography at the time of symptom onset. We speculated that the mechanism of cerebral vasospasm in our case was the disruption of autoregulation of the cerebral vasculature.

The selective intraarterial infusion of fasudil hydrochloride is generally performed for the treatment of vasospasm after subarachnoid hemorrhage (SAH). Fasudil is often used for cerebral vasospasm in recent years because it has fewer complications than intraarterial infusion of papaverine hydrochloride.⁸ Fasudil, a protein kinase inhibitor, has been shown to affect smooth muscle cell contraction by inhibiting myosin light-chain phosphatase and preventing myosin light chain phosphorylation.^{8,9} This mechanism is different from that of calcium antagonists. Cerebral vasospasm after CAS is similar to the condition of vasospasm after SAH in that it is hypoperfusion due to vasospasm. Fasudil, which dilates the vascular smooth muscle, is theoretically effective even for vasospasms after CAS; in fact, in this case, an intraarterial infusion of 30 mg of fasudil resulted in a dramatic improvement in cerebral vasospasm. Although some reports show that cerebral vasospasm after CAS recovered transiently,^{2,3,7} other reports indicate that serious neurological deficits remain.^{5,6} Even after medical treatment, the symptoms of the patient worsened quickly, and for this patient, use of a low dose of nicardipine prior to the intraarterial infusion of fasudil resulted in a decrease in blood pressure. Therefore, we decided to infuse fasudil

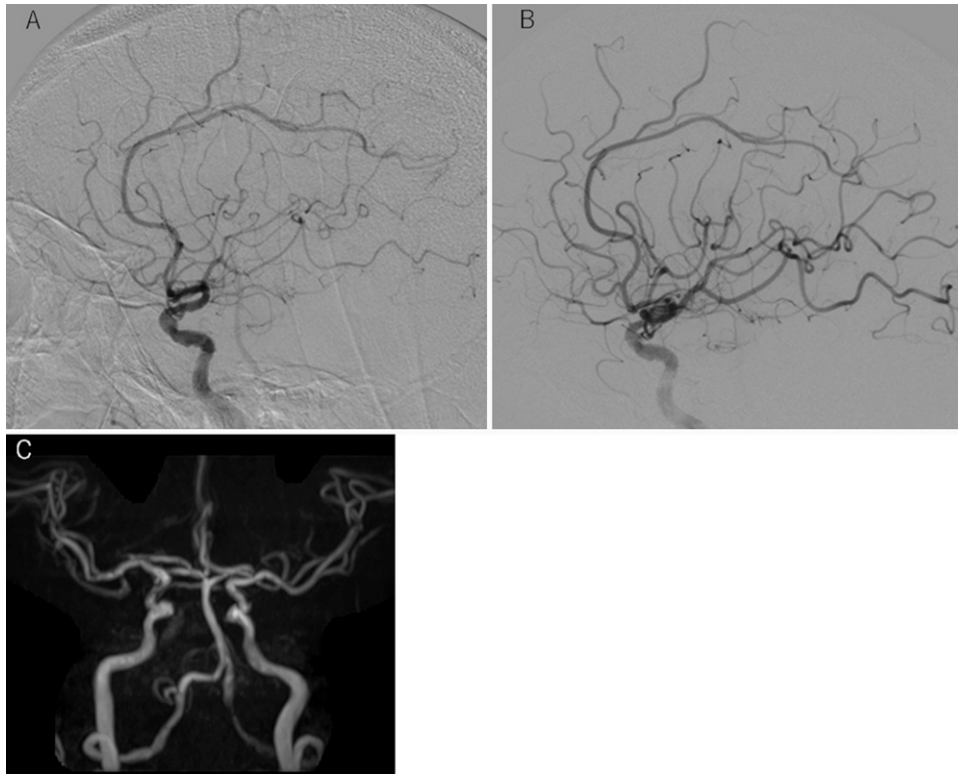


FIG. 3. When the symptoms became worse, the lateral view of DSA showed diffuse vasospasm of the right MCA (A). DSA, immediately after intraarterial infusion of fasudil hydrochloride, shows obvious improvement of CBF (B). Head MRA on the day after fasudil infusion shows improved visualization of the right MCA (C).

intraarterially. If symptoms worsen rapidly even after medical treatment, a decision to perform invasive treatment may be inevitable. This report may provide evidence that the intraarterial infusion of fasudil for hypoperfusion due to cerebral vasospasm after CAS is effective, such as for cerebral vasospasm after SAH. Also, intraarterial infusion of other vasodilators such as calcium channel blocker may be effective. It has been shown that the minimum onset time for fasudil to be effective on the cerebrovasculature is 5 minutes and CBF reaches a peak 30 minutes after intraarterial infusion of fasudil.^{8,9} However, the duration of the effect is within 6 hours.¹⁰ It is unclear how long cerebral vasospasm after CAS lasts; however, according to previous reports, it often improves within a few days, as in our case. Therefore, even if the duration of the effect is short, intraarterial infusion of fasudil at the peak of cerebral vasospasm, which is refractory to medical treatment, may help to overcome the most affected times by hypoperfusion. If the period of hypoperfusion can be overcome, it may be unlikely that fasudil will have to be readministered, such as in cerebral vasospasm after SAH. It seems important to perform intraarterial infusion of vasodilators in addition to medical treatment before the sequelae of ischemia occur.

Lessons

Cerebral vasospasm after CAS requires an immediate diagnosis because it involves a completely different treatment than hyperperfusion syndrome. The possibility of hypoperfusion as a complication of CAS should be considered. In cases that are resistant to medical

treatment, intraarterial infusion of fasudil at the right time may lead to good results.

References

1. Bates ER, Babb JD, Casey DE, et al. ACCF/SCAI/SVMB/SIR/ASTIN 2007 clinical expert consensus document on carotid stenting: a report of the American College of Cardiology Foundation Task Force on Clinical Expert Consensus Documents. *J Am Coll Cardiol.* 2007;49:126–170.
2. Kuwabara M, Nakahara T, Mitsuhashi T, et al. Transient cerebral vasospasm after carotid artery stenting: a case report and literature review. *World Neurosurg.* 2020;135:107–111.
3. Kang CH, Roh J, Yeom JA, et al. Asymptomatic cerebral vasoconstriction after carotid artery stenting. *AJNR Am J Neuroradiol.* 2020;41(2):305–309.
4. Rosenbloom MH, Singhal AB. CT angiography and diffusion-perfusion MR imaging in a patient with ipsilateral reversible cerebral vasoconstriction after carotid endarterectomy. *AJNR Am J Neuroradiol.* 2007;28(5):920–922.
5. Higashi E, Uwatoko T, Mizokami T, Sakaki Y, Sakata S, Sugimori H. Reversible cerebral vasoconstriction complicated with brain infarction immediately after carotid artery stenting. *Interv Neuroradiol.* 2018;24(6):688–692.
6. Causey MW, Amans MR, Han S, Higashida RT, Conte M. Reversible cerebral vasoconstriction syndrome is a rare cause of stroke after carotid endarterectomy. *J Vasc Surg.* 2016;64(6):1847–1850.
7. Watanabe Y, Takechi A, Kajiwara Y, Seyama G. Reversible cerebral vasoconstriction syndrome following carotid artery stenting: a case report. *J-STAGE.* 2017;39:299–303.

8. Shibuya M, Suzuki Y, Sugita K, et al. Effect of AT877 on cerebral vasospasm after aneurysmal subarachnoid hemorrhage. Results of a prospective placebo-controlled double-blind trial. *J Neurosurg.* 1992;76(4):571–577.
9. Liu J, Yao GE, Zhou HD, Jiang XJ, Xie P. Clinical investigation of fasudil for the prevention of cerebral vasospasm in extracranial carotid artery stenting. *Cell Biochem Biophys.* 2014;68(1):185–188.
10. Ono K, Shirotani T, Wada K, et al. Intra-arterial administration of fasudil hydrochloride: duration of action. Article in Japanese. *No Shinkei Geka.* 2005;33(2):133–140.

Disclosures

The authors report no conflict of interest concerning the materials or methods used in this study or the findings specified in this paper.

Author Contributions

Conception and design: Sasaki. Acquisition of data: Sasaki, Noda. Drafting the article: Sasaki. Critically revising the article: Kotani, Ito. Reviewed submitted version of manuscript: Sasaki, Kotani. Approved the final version of the manuscript on behalf of all authors: Sasaki. Study supervision: Noda.

Correspondence

Nozomi Sasaki: Chuno Kosei Hospital, Gifu-ken, Japan. nshope0130@yahoo.co.jp.