

Sciatic nerve injury following analgesic drug injection in rats: A histopathological examination

Habib Bostan,¹ Murat Cabalar,¹ Serdar Altınay,² Yildiray Kalkan,³ Levent Tumkaya,³ Ayhan Kanat,⁴ Sabri Balik,⁵ Adem Erkut,⁵ Dudu Altuner,⁶ Ziya Salihoglu,¹ Abdulkadir Kocer⁷

¹Department of The Ministry of Justice, Council of Forensic Medicine, Istanbul, Turkey

²Department of Pathology, Selcuk University Faculty of Medicine, Konya, Turkey

³Department of Histology, Recep Tayyip Erdogan University Faculty of Medicine, Rize, Turkey

⁴Department of Neurosurgery, Recep Tayyip Erdogan University Faculty of Medicine, Rize, Turkey

⁵Department of Orthopaedic Surgery, Recep Tayyip Erdogan University Faculty of Medicine, Rize, Turkey

⁶Department of Pharmacology, Rize University Faculty of Medicine, Rize, Turkey

⁷Department of Neurology, Medeniyet University Faculty of Medicine, Istanbul, Turkey

ABSTRACT

OBJECTIVE: Sciatic nerve neuropathy can be observed following intramuscular gluteal injections. The histopathological examination of sciatic nerve damage following intramuscular injection in the gluteal region for acute pain treatment is not feasible in humans due to the inability to dissect and examine the nerve tissue. To overcome this issue, we used a rat model for demonstrating damage to the sciatic nerve tissue after the application of commonly used drug injections.

METHODS: We investigated possible damage following the intramuscular injection of diclofenac, lornoxicam, morphine, and pethidine in a rat model based on histopathological characteristics such as myelin degeneration, axon degeneration, epineurium degeneration, fibrosis, epineurium thickening, perineurium thickening, lymphocyte infiltration, vacuolization, and edema.

RESULTS: All the analgesic drugs used in our study induced histopathological changes in the sciatic nerve. Anti-S100 positivity, showing nerve damage, was found to be the lowest in the group treated with diclofenac. Neurotoxic effects of diclofenac on the sciatic nerve were greater than those of the other drugs used in the study. Lornoxicam induced the least histopathological changes in the nerve.

CONCLUSION: Diclofenac induced severe nerve damage not only after direct injection in the sciatic nerve but also after injection in the area around the nerve. Thus, we recommend restricting the use of intramuscular gluteal injections of diclofenac. Intramuscular use of morphine and pethidine should also be overviewed.

Keywords: Acute pain treatment; sciatic neuropathy; diclofenac; lornoxicam; morphine; pethidine.

Cite this article as: Bostan H, Cabalar M, Altınay S, Kalkan Y, Tumkaya L, Kanat A, et al. Sciatic nerve injury following analgesic drug injection in rats: A histopathological examination. *North Clin Istanbul* 2018;5(3):176–185.

Intramuscular drug injection is preferred over oral drug administration in patients with pain complaints due to its observed immediate effects. Intramuscular drug administration is usually performed in the gluteal region [1, 2]. Even if the correct site, the correct method, a suitable injector, and an ideal dose are selected, sciatic nerve neu-

ropathy can be observed following intramuscular gluteal injections. The composition of the drug, the selection of an unsuitable injection site, unsterile conditions, the use of inappropriate tools, the level of technical skills and ability of the medical staff, as well as the condition of the patient may contribute to the undesirable results. In de-



Received: February 25, 2017 Accepted: November 05, 2017 Online: May 29, 2018

Correspondence: Dr. Abdulkadir KOCER. Medeniyet Universitesi Tip Fakultesi Noroloji Anabilim Dalı, Istanbul, Turkey
Phone: +90 505 426 28 28 e-mail: abduladirkocer@yahoo.com

© Copyright 2018 by Istanbul Provincial Directorate of Health - Available online at www.northclinist.com

veloping countries lacking adequate healthcare facilities, the risk of sciatic nerve neuropathy after an intramuscular injection is higher [3–5]. The drugs most commonly causing sciatic neuropathy via the intramuscular route are antibiotics and analgesics [5, 6].

The histopathological examination of sciatic nerve damage following intramuscular injection in the gluteal region for acute pain treatment is not feasible in humans due to the inability to dissect and examine the nerve tissue. In this study, we compared the pathological effects of intramuscular drugs commonly used in medical practice, including diclofenac, lornoxicam, morphine, and pethidine, on the sciatic nerve in a rat model. In this animal model, the histopathological effects depending on the drug type and the selection of injection site were compared.

MATERIALS AND METHODS

Histopathological changes in the sciatic nerve can be identified by examining the nerve tissue, and sciatic nerve damage can be easily shown in a rat model. In this study, we investigated possible damage following the intramuscular injection of diclofenac, lornoxicam, morphine, and pethidine for acute pain treatment in a rat model. The histopathological characteristics evaluated for the assessment of the neural defect included myelin degeneration, axon degeneration, epineurium degeneration, fibrosis, epineurium thickening, perineurium thickening, lymphocyte infiltration, vacuolization, and edema. The study was conducted at the Istanbul Bagcilar Education and Research Hospital Animal Laboratory Section between June 1, 2013 and June 1, 2014.

In this study, 50 male Sprague Dawley rats (weighing 180–200 g) were used. All animals were fed with 7–8 mm rat chow pellets ad libitum and water. White fluorescent light controlled with automated photoperiod was used to provide a 12-h light and 12-h dark environment, and ambient temperature and humidity were set at $21^{\circ}\text{C}\pm 2^{\circ}\text{C}$ and 55%–60%, respectively. The methods used for animal experiments were adjusted according to the protocols of the National Institute of Health Guide for the Care and Use of Laboratory Animals. The necessary permissions were obtained from the Local Ethics Committee for Animal Experiments of the Istanbul Bagcilar Education and Research Hospital (Date: 12.27.2012, Issue no: 63). In total, 10 groups of animals, including control (saline) and drug-treated groups, each containing five subjects were evaluated.

The administered drugs, drug administration route, and drug doses were as follows [7–10]:

Diclofenac injection in the sciatic nerve, 2 mg/kg/ 0.5 ml;
Lornoxicam injection in the sciatic nerve, 1.3 mg/kg/0.5 ml;
Morphine injection in the sciatic nerve, 0.2 mg/kg/0.5 ml;
Pethidine injection in the sciatic nerve, 3 mg/kg/0.5 ml;
Diclofenac injection in the surrounding muscle tissue of the sciatic nerve, 2 mg/kg/0.5 ml;
Lornoxicam injection in the surrounding muscle tissue of the sciatic nerve, 1.3 mg/kg/0.5 ml;
Morphine injection in the surrounding muscle tissue of the sciatic nerve, 0.2 mg/kg/0.5 ml;
Pethidine injection in the surrounding muscle tissue of the sciatic nerve, 3 mg/kg/0.5 ml;
Saline (a mixture of sodium chloride in water) injection in the sciatic nerve, 0.5 ml; and
Saline injection in the surrounding muscle tissue of the sciatic nerve, 0.5 ml.

The rats were anesthetized with ketamine and xylazine. Thereafter, the sciatic nerve was exposed after dissecting through the gluteal muscles. The analgesics and saline were injected in the sciatic nerve and the muscles adjacent to the sciatic nerve. Subsequently, the gluteal muscles and skin tissues were sutured. After this, the rats were kept for 7 days in cages. Later, all the animals were decapitated under deep anesthesia with sodium pentothal (50–60 mg/kg), and the sciatic nerves were removed. The removed sciatic nerve tissues were used for histopathological and immunohistochemical examination, and the samples were stained within 24 h.

For staining, the labeled sciatic nerve tissues were fixed in 10% neutral buffered formalin. After keeping for 24 h in the fixative, the samples were washed for about 6–8 h in running water, following which the tissue tracking and processing were performed using an automatic device (Citadel 2000, Thermo Fisher Scientific Shandon, England) passing the samples through ethanol–xylene series. Later, the samples were embedded in liquid paraffin. The tissues were sectioned 4–6- μm thick for routine hematoxylin–eosin staining and 3–4- μm thick for immunohistochemical staining. The cut sections for immunohistochemical staining were incubated for 20 min in xylene and kept in 3% H_2O_2 solution for 10 min after passing through the series of alcohol (70%–99%). After washing with PBS, the sections were heated in the citrate buffer solution for 5–10 min at 600–800 W; they

were allowed to stand for 10 min in the secondary blocking agent. Each slide was held for 60–75 min in various dilutions (1/100–1/300) of the primary antibody (Anti-S100-Coder: ab66041, Abcam plc, Cambridge CB4 0FL UK). Diaminobenzidine (DAB) solution was used as the chromogen, and Mayer's hematoxylin was used for counterstaining. PBS was used for negative controls.

After 1 month, the samples were examined within the same day. The appropriate slide regions under the light microscope were examined at different magnifications, and their pictures were taken. The blind reading and grading of slides were made by two histologists and by a pathologist. The positivity according to the percentage values was categorized in four grading categories: mild (+), moderate (++), severe (+++), and very severe (++++). The histopathological findings such as myelin degeneration, axon degeneration, epineurium degeneration, fibrosis, epineurium thickening, perineurium thickening, lymphocytic infiltration, vacuolization, and edema were evaluated. Additionally, these histopathological findings were divided into four grading categories according to the positivity for anti-S100: mild (+), moderate (++), severe (+++), and very severe (++++).

The observed histopathological findings in the groups with drug injections in the sciatic nerve were statistically compared with those in the control groups with saline injections in the sciatic nerve (Table 1). The observed histopathological findings in the groups with drug injections in the muscles adjacent to the sciatic nerve were statistically compared with those in the control groups with saline injections in the muscles adjacent to the sciatic nerve (Table 2). The groups with injections in the sciatic nerve and the ones with injections in the muscles adjacent to the sciatic nerve were also statistically compared with each other in terms of histopathological findings for each drug (Table 3).

The groups with drug injections in the sciatic nerve were statistically compared with the control groups with saline injections in the sciatic nerve in terms of anti-S100 positivity.

Statistical analysis

The statistical analysis and assessment of the study findings were performed using Number Cruncher Statistical System 2007 and Power Analysis and Sample Size 2008 Statistical Software (NCSS LLC, Kaysville, Utah, USA). Mann–Whitney U test was used for comparisons of abnormally distributed parameters between the

groups. The results were evaluated at 95% confidence interval and at $p < 0.05$ level of significance.

RESULTS

Histopathological results

On evaluating the damage after drug injection in the sciatic nerve, axon and myelin degeneration was observed to be greater in the diclofenac group (Table 1). In the epineurium of the nerve, moderate cell degeneration and edema were detected (Figure 1C, D). In the lornoxicam group, nerve fascicular structures comprising myelinated and non-myelinated nerve fibers were shown to preserve their round morphology with distinct borders. In the mor-

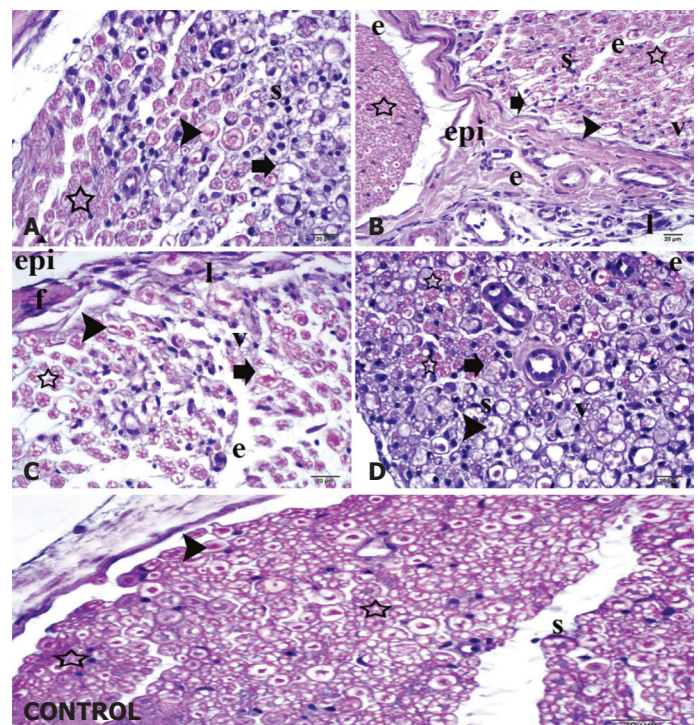


FIGURE 1. (A, B) Histopathological changes after injection in the muscle tissue adjacent to the sciatic nerve: epi, epineurium; e, edema; v, vacuolization; l, lymphocyte infiltration; star, normal axons; arrow head, degenerated axons; s, swollen Schwann cells; thick arrow, myelin degeneration; hematoxylin–eosin staining, $\times 40$. (C, D) Histopathological changes after injection in the sciatic nerve: epi, epineurium; e, edema; v, vacuolization; l, lymphocyte infiltration; star, normal axons; arrow head, degenerated axons; s, swollen Schwann cells; thick arrow, myelin degeneration; hematoxylin–eosin staining, $\times 40$. Control: star, normal axons; arrow head, mildly degenerated axons; s, normal Schwann cells; hematoxylin–eosin staining, $\times 40$.

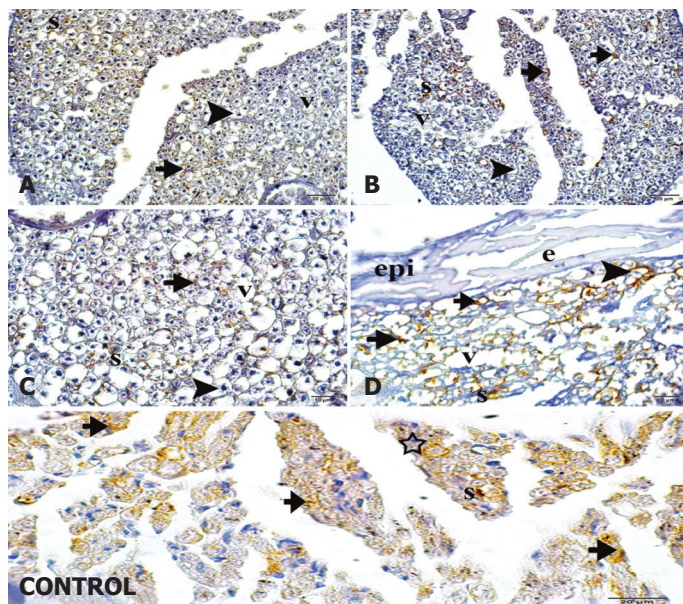


FIGURE 2. (A, B) Histopathological changes after injection in the muscle tissue adjacent to the sciatic nerve detected using anti-S100 immunohistochemical staining: arrow head, degenerated axons; s, swollen Schwann cells; short arrow, immunopositive cells; v, vacuolization; immunoperoxidase staining. (C, D) Histopathological changes after injection in the sciatic nerve detected using anti-S100 immunohistochemical staining: arrow head, degenerated axons; s, swollen Schwann cells; short arrow, immunopositive cells; v, vacuolization; epi, epineurium; e, edema; immunoperoxidase staining. Control: star, normal axons; short arrow, moderate immunopositive cells; s, intense immunopositive Schwann cells; immunoperoxidase.

phine group, axon and myelin degeneration was present at a certain rate around the epineurium. In the pethidine group, axon and myelin degeneration was observed. The degenerated regions between the epineurium and endoneurium showed a gradual increase.

On evaluating the samples where drug was injected in the tissue adjacent to the sciatic nerve, axon degeneration, abundant lymphocyte infiltration, edema and vacuolization, and thickening at perineural areas, fibrosis, and granulation tissue formation at injection sites were observed in the diclofenac group. Inflammation around the axons and mild degeneration of the myelin sheath were observed in the lornoxicam group. In the muscles, vacuolization areas increased but lacked a homogeneous distribution throughout (Fig. 1A, B). In the morphine group, dense edema, vacuolization, fibrosis, and granulation tissue formation were observed (Fig. 1A, B). Myelin degeneration around

the epineurium was increased and both edema and degeneration were observed in the pethidine group (Fig. 1C, D).

In group where saline was injected in the sciatic nerve, swelling surrounding the axons of some nerve fibers, formation of degenerated regions in the myelin sheaths, separation of the lamellae of myelin from each other, and mild degeneration of axons in some nerve fibers were detected, but significant number of myelinated nerve fibers presented with normal morphological features (Fig. 1, Control). In the group where saline was injected adjacent to the sciatic nerve group, no histopathological changes were observed on the examination of the sciatic nerves using light microscopy.

Immunohistochemical results

Immunohistochemical staining performed using the immunoperoxidase method in the groups in which injections were performed in the sciatic nerve yielded the following results for anti-S immunopositivity: (+) 60% and (++) 40% in the diclofenac group; (++) 60% and (+++) 40% in the lornoxicam group; (+) 40%, (++) 40%, and (+++) 20% in the morphine group; and (++) 20% and (+++) 40% in the pethidine group(+++). Furthermore, anti-S immunopositivity was (+++) 40% and (++++) 60% in the saline group (Fig. 2A–D-Control).

Statistical Findings

Myelin degeneration

Myelin degeneration was found to be significantly higher in the groups in which drugs were injected directly in the sciatic nerve than in the groups in which saline was injected ($p < 0.05$) (Table 1). Furthermore, myelin degeneration was significantly greater in the groups in which drugs (except pethidine) were injected around the sciatic nerve than in the groups in which saline was injected around the sciatic nerve ($p < 0.05$) (Table 2). In the diclofenac and pethidine groups, myelin degeneration was shown to be significantly higher than that in the diclofenac and pethidine groups in which drugs were injected in the tissue adjacent to the sciatic nerve ($p < 0.05$) (Table 3).

Axon degeneration

In the diclofenac and pethidine groups, axon degeneration was found to be significantly higher than that in the group in which saline was injected directly in the sciatic nerve ($p < 0.05$) (Table 1). The axon degeneration with the injection of any drug except pethidine in the tissue adjacent

TABLE 1. The assessment of histopathological damage comparing saline with other drugs when the agents were injected in the sciatic nerve

Pathological Changes Level		^A Saline (n)	^B Morphine (n)	^C Pethidine (n)	^D Diclofenac (n)	^E Lornoxicam (n)	p
Myelin degeneration	None	1	0	0	0	0	
	+1	3	0	0	0	0	A-B p=0.016*
	+2	1	3	1	0	4	A-C p=0.010*
	+3	0	2	2	2	1	A-D p=0.007**
	+4	0	0	2	3	0	A-E p=0.018*
Median (Min-Max)		1 (0-2)	2 (2-3)	3 (2-4)	4 (3-4)	2 (2-3)	
Axon degeneration	None	1	0	0	0	0	
	+1	3	2	0	0	2	A-B p=0.090
	+2	1	0	0	0	1	A-C p=0.006**
	+3	0	3	4	2	2	A-D p=0.007**
	+4	0	0	1	3	0	A-E p=0.116
Median (Min-Max)		1 (0-2)	3 (1-3)	3 (3-4)	4 (3-4)	2 (1-3)	
Epineurium degeneration	None	0	0	0	0	0	
	+1	4	3	1	0	1	A-B p=0.513
	+2	1	2	3	1	4	A-C p=0.065
	+3	0	0	1	4	0	A-D p=0.007**
Median (Min-Max)		1 (1-2)	1 (1-2)	2 (1-3)	3 (2-3)	2 (1-2)	A-E p=0.072
Fibrosis	None	3	0	0	0	0	A-B p=0.006**
	+1	2	0	0	0	1	A-C p=0.006**
	+2	0	4	1	1	3	A-D p=0.006**
	+3	0	1	4	4	1	A-E p=0.013*
Median (Min-Max)		0 (0-1)	2 (2-3)	3 (2-3)	3 (2-3)	2 (1-3)	
Epineurium thickening	None	3	0	0	0	0	A-B p=0.048*
	+1	2	5	0	0	2	A-C p=0.007**
	+2	0	0	3	2	3	A-D p=0.007**
	+3	0	0	2	3	0	A-E p=0.020*
Median (Min-Max)		0 (0-1)	1 (1-1)	2 (2-3)	3 (2-3)	2 (1-2)	
Perineurium thickening	None	0	0	0	0	0	A-B p=0.513
	+1	4	3	1	0	2	A-C p=0.054
	+2	1	2	2	5	3	A-D p=0.014*
	+3	0	0	2	0	0	A-E p=0.221
Median (Min-Max)		1 (1-2)	1 (1-2)	2 (1-3)	2 (2-2)	2 (1-2)	
Lymphocyte infiltration	None	0	0	0	0	0	
	+1	4	0	0	0	0	A-B p=0.006**
	+2	1	0	0	0	4	A-C p=0.006**
	+3	0	3	3	0	1	A-D p=0.004**
	+4	0	2	2	5	0	A-E p=0.015*
Median (Min-Max)		1 (1-2)	3 (3-4)	3 (3-4)	4 (4-4)	2 (2-3)	
Vacuolisation	None	0	0	0	0	0	
	+1	2	0	0	0	1	A-B p=0.093
	+2	3	4	2	0	2	A-C p=0.033*
	+3	0	1	1	1	1	A-D p=0.006**
	+4	0	0	2	4	1	A-E p=0.214

TABLE 1. CONT.

Pathological Changes Level		^A Saline (n)	^B Morphine (n)	^C Pethidine (n)	^D Diclofenac (n)	^E Lornoxicam (n)	p
Median (Min-Max)		2 (1-2)	2 (2-3)	3 (2-4)	4 (3-4)	2 (1-4)	
Edema	None	1	0	0	0	0	
	+1	3	0	0	0	0	A-B p=0.005**
	+2	1	0	2	0	2	A-C p=0.013*
	+3	0	0	2	0	2	A-D p=0.005**
	+4	0	5	1	5	1	A-E p=0.013*
Median (Min-Max)		1 (0-2)	4 (4-4)	3 (2-4)	4 (4-4)	3 (2-4)	

n: number of subjects with pathological changes, Mann Whitney U test; * p<0.05 **p<0.01.

to the sciatic nerve was significantly higher than that with the injection of saline in the tissue adjacent to the sciatic nerve ($p<0.05$) (Table 2). Similar to myelin degeneration results, axon degeneration was found to be significantly higher in the diclofenac and pethidine groups in which the drugs were injected directly in the sciatic nerve than in those in which the drugs were injected in the tissue adjacent to the sciatic nerve ($p<0.05$) (Table 3).

Epineurium degeneration

Epineurium degeneration in the diclofenac group was significantly higher than that in the saline group ($p<0.05$) (Table 1). The degeneration was found to be significantly higher with the injection of any drug in the tissue adjacent to the sciatic nerve than with the injection of saline in the tissue adjacent to the sciatic nerve ($p<0.05$) (Table 2). Even epineurium degeneration was found to be greater in the group in which saline was directly injected in the sciatic nerve than in the group in which saline was injected in the tissue adjacent to the sciatic nerve ($p<0.05$) (Table 3).

Fibrosis

In comparison with saline, all drugs injected directly in the sciatic nerve resulted in a greater level of fibrosis ($p<0.05$) (Table 1). Similar findings were observed in the groups in which injection was performed in the tissue adjacent to the sciatic nerve ($p<0.05$) (Table 2). Greater fibrosis was observed in the groups in which morphine and pethidine were injected directly in the nerve than in those in which morphine and pethidine were injected in the tissue adjacent to the sciatic nerve ($p<0.05$) (Table 3).

Epineurium thickening

Compared with saline, all drugs injected directly in the sciatic nerve resulted in greater epineurium thickening ($p<0.05$) (Table 1). Similar findings were observed in the groups in which injection was performed in the tissue adjacent to the sciatic nerve ($p<0.05$) (Table 2). Saline injected directly in the sciatic nerve caused more epineurium problems compared with that injected in the tissue adjacent to the nerve ($p<0.05$) (Table 3).

Perineurium thickening

Although any type of diclofenac injection resulted in greater perineurium thickening, lornoxicam injection in the area adjacent to the sciatic nerve resulted in greater perineurium thickening compared with saline injection ($p<0.05$) (Table 1 and 2). Perineurium thickening was greater in the groups in which pethidine and saline were directly injected in the sciatic nerve than in those in which pethidine and saline were injected in the tissue adjacent to the sciatic nerve ($p<0.05$) (Table 3).

Lymphocyte infiltration

Lymphocyte infiltration in all the groups in which drugs were directly injected in the sciatic nerve was significantly higher than that in the groups in which saline was injected ($p<0.05$) (Table 1). On comparing the different drugs injected in the tissue adjacent to the sciatic nerve, the diclofenac and lornoxicam groups showed higher lymphocyte infiltration than the saline-injected groups ($p<0.05$) (Table 2). The injections of diclofenac, morphine, or pethidine in the sciatic nerve caused higher lymphocyte infiltration than those in the tissue adjacent to the sciatic nerve ($p<0.05$) (Table 3).

TABLE 2. The assessment of histopathological damage comparing saline with other drugs when the agents were injected in the muscle tissue adjacent to the sciatic nerve

Pathological Changes Level		^A Saline (n)	^B Morphine (n)	^C Pethidine (n)	^D Diclofenac (n)	^E Lornoxicam (n)	p
Myelin degeneration	None	3	0	2	0	0	
	+1	2	3	2	0	2	A-B p=0.032*
	+2	0	1	1	2	1	A-C p=0.419
	+3	0	1	0	3	2	A-D p=0.007**
	+4	0	0	0	0	0	A-E p=0.021*
Median (Min-Max)		0 (0-1)	1 (1-3)	1 (0-2)	3 (2-3)	2 (1-3)	
Axon degeneration	None	4	0	2	0	0	
	+1	1	3	2	0	2	A-B p=0.014*
	+2	0	1	1	3	2	A-C p=0.189
	+3	0	1	0	2	1	A-D p=0.006**
	+4	0	0	0	0	0	A-E p=0.012*
Median (Min-Max)		0 (0-1)	1 (1-3)	1 (0-2)	2 (2-3)	2 (1-3)	
Epineurium degeneration	None	4	0	0	0	0	A-B p=0.014*
	+1	1	3	3	0	3	A-C p=0.014*
	+2	0	2	2	4	2	A-D p=0.005**
	+3	0	0	0	1	0	A-E p=0.014*
	Median (Min-Max)		0 (0-1)	1 (1-2)	1 (1-2)	2 (2-3)	1 (1-2)
Fibrosis	None	4	0	0	0	0	A-B p=0.015*
	+1	1	4	4	0	3	A-C p=0.015*
	+2	0	1	1	4	2	A-D p=0.005**
	+3	0	0	0	1	0	A-E p=0.014*
	Median (Min-Max)		0 (0-1)	1 (1-2)	1 (1-2)	2 (2-3)	1 (1-2)
Epineurium thickening	None	4	0	0	0	1	A-B p=0.015*
	+1	1	4	3	0	3	A-C p=0.014*
	+2	0	0	1	2	1	A-D p=0.006**
	+3	0	1	1	3	0	A-E p=0.065
	Median (Min-Max)		0 (0-1)	1 (1-3)	1 (1-3)	3 (2-3)	1 (0-2)
Perineurium thickening	None	3	1	2	0	0	A-B p=0.221
	+1	2	4	3	2	2	A-C p=0.549
	+2	0	0	0	3	2	A-D p=0.020*
	+3	0	0	0	0	1	A-E p=0.021*
	Median (Min-Max)		0 (0-1)	1 (0-1)	1 (0-1)	2 (1-2)	2 (1-3)
Lymphocyte infiltration	None	2	0	0	0	0	
	+1	3	4	3	0	0	A-B p=0.093
	+2	0	1	2	2	3	A-C p=0.058
	+3	0	0	0	3	2	A-D p=0.007**
	+4	0	0	0	0	0	A-E p=0.007**
Median (Min-Max)		0 (0-1)	1 (1-2)	1 (1-2)	3 (2-3)	2 (2-3)	
Vacuolisation	None	3	0	1	0	0	A-B p=0.031*
	+1	2	3	3	0	1	A-C p=0.166
	+2	0	2	1	3	3	A-D p=0.007**
	+3	0	0	0	2	0	A-E p=0.013*
	Median (Min-Max)		0 (0-1)	1 (1-2)	1 (1-2)	3 (2-3)	2 (2-3)

n: number of subjects with pathological changes, Mann-Whitney U test; * p<0.05, **p<0.01.

Vacuolization

Vacuolization was significantly higher in the diclofenac and pethidine groups in which drugs were directly injected in

the sciatic nerve than in the saline group (p<0.05) (Table 1). Furthermore, vacuolization was significantly higher in the diclofenac, morphine, and lornoxicam groups in which

TABLE 3. The comparison of histopathological damage after the injection of agents in the sciatic nerve and in the muscle tissue adjacent to the nerve

	Morphine	Pethidine	Diclofenac	Lornoxicam	Saline (SF)
Miyelin Degeneration	0.121	0.011*	0.031*	0.734	0.166
Axon Degeneration	0.356	0.007**	0.020*	0.74	0.065
Epineurium Degeneration	1.000	0.166	0.072	0.221	0.015*
Fibrosis	0.015*	0.007**	0.072	0.166	0.513
Epineurium Thickening	0.317	0.121	1.000	0.166	0.513
Perineurium Degeneration	0.093	0.017*	0.134	0.729	0.042*
Lymphocyte Infiltration	0.006**	0.007**	0.005**	0.513	0.093
Vacuolisation	0.042*	0.013*	0.011*	0.736	0.020*
Edema	0.005**	0.023*	0.005**	0.142	0.166

Mann Whitney U test; * $p < 0.05$ ** $p < 0.01$.

drugs were injected in the tissue adjacent to the sciatic nerve than in the saline groups ($p < 0.05$) (Table 2). On comparing the different injection sites, the vacuolization in the diclofenac, morphine, pethidine, and saline groups was found to be significantly higher ($p < 0.05$) (Table 3).

Edema

Edema in all the groups in which drugs were directly injected in the sciatic nerve was significantly higher than that in the groups in which saline was injected ($p < 0.05$) (Table 1). On comparing different injections in the tissue adjacent to the sciatic nerve, the diclofenac and lornoxicam groups showed greater edema than the saline-injected groups ($p < 0.05$) (Table 2). The injection of diclofenac, morphine, and pethidine in the sciatic nerve causes higher edema than that in the tissue adjacent to the sciatic nerve ($p < 0.05$) (Table 3).

Anti-S100 positivity

The level of anti-s100 positivity was the highest in the saline group ($p < 0.05$). It was the lowest in the diclofenac group.

DISCUSSION

The sciatic nerve is prone to injury following drug injection, and the proportion of sciatic nerve damage resulting from intramuscular injections is reported to be high (86% of all cases) [11]. Sciatic nerve damage arises from an injection either directly in the sciatic nerve or in the surrounding tissue [12–19]. Inappropriate drug injection

in the gluteal region can result in direct damage to the sciatic nerve. The mechanism of injury appears to be a direct toxic effect of the injected compound on the neural tissue [12–20]. During injection in the sciatic nerve, the drug sometimes may get injected between the nerve and the sheath or between the fascicles. In these cases, neuronal damage occurs due to the effect of the drug rather than a physical damage to the nerve. Furthermore, the accumulation of the drug around the sciatic nerve or at an epineural level may result in sciatic nerve damage [12–14, 20, 21]. The neurological defects following drug injection directly in the sciatic nerve are observed depending on the level of damage induced by the specific agent injected [14, 15]. In addition, the quantity of the drug injected is important in determining the degree of injury [18]. The most severe injuries are associated with widespread axon and myelin degeneration, and the pathological alterations in the nerve are evident as early as 30 min following the injury due to the injection [17, 18]. In their study investigating the toxic effect of non-steroidal anti-inflammatory drugs during development, Canan et al reported that axon loss was significantly prominent in rats exposed to diclofenac sodium [20]. In our study, we demonstrated that analgesic drug or saline injection directly in the sciatic nerve caused nerve damage. This result was similar to the report by Canan et al. [20]. The histopathological changes were most prominent in the diclofenac group and least prominent in the lornoxicam group, as shown in Table 1. The diclofenac group showed many types of pathological changes, including axon damage in the subjects in which drugs or saline were injected in the tissue adjacent to the sciatic nerve, although the

other drug groups did not show any prominent findings related to the nerve damage (Table 2). All these findings supported the fact that nerve damage resulted from injection either directly in the sciatic nerve or in the tissue adjacent to the nerve. As another important finding of our study, we have shown toxic effects of all the drugs, although we used the lowest dosages reported in the literature [7–10, 19].

The intramuscular use of diclofenac, lornoxicam, morphine, and pethidine has been well established for the treatment of acute pain [22–31]. Among these, diclofenac and pethidine have both analgesic and anti-inflammatory effects [26–29]. Morphine and pethidine are narcotic drugs with analgesic effects [30, 31]. There is currently no report demonstrating the histopathological effects of diclofenac on the sciatic nerve, although diclofenac has been reported to induce anaphylaxis after intramuscular injection for acute pain treatment [28]. In our study, the histopathological changes observed with the injection of diclofenac in the sciatic nerve were more than those with the other drugs. Compared with other drugs, diclofenac induced more histopathological changes after injection in not only the sciatic nerve but also the tissue adjacent to the nerve. It is known that the protein level of S-100 decreases, and it can be demonstrated using immunohistochemical staining when there is nerve damage [32]. In the present study, anti-s100 positivity, showing nerve damage, was found to be the lowest in the diclofenac group with direct injection in the sciatic nerve. This observation indicates that diclofenac is the most toxic agent among the drugs injected in this study. Milder histopathological changes were observed on evaluating the toxic effects of the other drugs. Lornoxicam seems to be one of the drugs that can be intramuscularly used for acute pain treatment, and there are no reports on sciatic nerve damage induced by an intramuscular injection of this drug in the gluteal region or its histopathological effects on the sciatic nerve [24, 25]. Lornoxicam injection in the sciatic nerve resulted in greater damage supported based on the histopathological evidence, and anti-S100 positivity was detected to be lower in the lornoxicam group with injection in the sciatic nerve than in the control group with serum physiological injection in the sciatic nerve. This data suggests that the histopathological effects of lornoxicam on the sciatic nerve were more than those of serum physiological but milder than those of diclofenac.

Both morphine and pethidine are administered intramuscularly in the gluteal region for acute pain treatment [22, 29–31]. Morphine is a narcotic analgesic lacking

anti-inflammatory properties and is known to suppress respiration at higher doses and to pose an addiction risk. [22]. In our study, the histopathological changes were more severe in the morphine and pethidine groups in which the drugs were directly injected in the sciatic nerve than in the groups in which these drugs were injected in the tissue adjacent to the nerve. The anti-S100 positivity was found to be lower in the groups in which morphine and pethidine were directly injected in the sciatic nerve than in the groups in which serum physiological was injected. This proved the histopathological effects of morphine and pethidine on the sciatic nerve; however, their effects were found to be milder than those of diclofenac. Compared with the other drug injections, pethidine injection in the muscle tissue adjacent to the nerve resulted in less damage. Anti-S100 positivity in the group with pethidine injected in the sciatic nerve was found to be lower than that in the group injected with serum physiological; this supports the evidence for the histopathological effects of pethidine on the sciatic nerve. Moreover, the injection of pethidine resulted in minor histopathological changes compared with that of other drugs. To our knowledge, these are the first results of damage after direct injections in the sciatic nerve or the tissue adjacent to the nerve; thus, no laboratory or clinical study is available in the literature to compare our findings.

CONCLUSION

In conclusion, the site of injection is the most crucial factor in determining the degree of nerve injury. Most widely used analgesic drugs can easily induce damage-related changes in the sciatic nerve when the drug is directly injected in the sciatic nerve or in the tissue adjacent to the sciatic nerve. Neurotoxic effects of diclofenac on the sciatic nerve were detected to be greater than those of other drugs used in the present study. Thus, we recommend that the use of diclofenac intramuscularly should be restricted in emergency units and even inpatient clinics. Additionally, lornoxicam, morphine, and pethidine have been demonstrated to have neurotoxic effects on the sciatic nerve tissue despite lack of relevant studies. Lornoxicam, with anti-inflammatory effects, has also been shown to exert neurotoxic effects on the sciatic nerve, although its effects were the mildest. Furthermore, we suggest that intramuscular use of morphine and pethidine should be overviewed.

Acknowledgment: This study was partially presented at National Neurology Congress 20016, Antalya-Turkey.

Ethics: The necessary permissions were obtained from the Local Ethics Committee for Animal Experiments of the Istanbul Bagcilar Education and Research Hospital (Date: 12.27.2012, Issue no: 63).

Conflict of Interest: The authors declare no conflict of interest.

Financial Disclosure: The authors declared that this study has received no financial support.

Authorship Contributions: Concept – H.B., A.K.; Design – H.B., A.K., M.C., L.T., Y.K.; Supervision – H.B., L.T., Y.K.; Materials – H.B., L.T., Y.K., A.K., S.B., A.E.; Data collection &/or processing – H.B., D.A., L.T., Y.K., A.K., S.B., A.E.; Analysis and/or interpretation – H.B., M.C., D.A., L.T., Y.K., A.K., S.B., A.E.; Writing – A.K., H.B., M.C., Z.S.; Critical review – A.K., H.B.

REFERENCES

1. Aysegul G, Nurten U, Nevzat A, Kiziltan ME. Injection Neuropathies of the Sciatic Nerve: Experience of an Electrophysiology Laboratory and Medicolegal Approach in Turkey. *Noropsikiyatri Arsivi* 49:208–11.
2. Nicoll LH, Hesby A. Intramuscular injection: An integrative research review and guideline for evidence-based practice. *Applied Nursing Res* 2002;15:149–62.
3. Mishra P, Stringer MD. Sciatic nerve injury from intramuscular injection: a persistent and global problem. *Int J Clin Pract* 2010;64:1573–9.
4. Idowu AO, Ogunrinu AE, Akinremi A, Aladeyelu OE, Kaka B, Adelugba JK. Injection-induced Sciatic Nerve Injury Among Children Managed in a Nigerian Physiotherapy Clinic: A five-year review. *AJPARS* 2011;3:13–6.
5. Bağış S, Adam M, Leblebici ÜB, Karataş M, Güven AZ, Çelikler AR. Sciatic nerve injury due to intramuscular injection: electrophysiological findings and one-year follow-up. *Turk J Med Sci* 2012;42:913–7.
6. Dönertaş B, Alkan A, Mollahaliloğlu S, Seçkin C, Akıcı A. Investigation of paraneural drug use in family health care centers across 32 provinces of Turkey. *Anatolian J Clin Invest* 2013;7:31–40.
7. Peris-Ribera JE, Torres-Molina F, Garcia-Carbonell MC, Aristorena JC, Pla-Delfina JM. Pharmacokinetics and bioavailability of diclofenac in the rat. *J Pharmacokinet Biopharm* 1991;19:647–65.
8. Topcu I, Vatanserver S, Bayram E, Var A, Cetin I, Civi M. The effects of lornoxicam on neuroprotection following diffuse traumatic brain injury in rats. *Turk Neurosurg* 2013;23:764–71.
9. Thomas A, Miller A, Roughan J, Malik A, Haylor K, Sandersen C, et al. Efficacy of Intrathecal Morphine in a Model of Surgical Pain in Rats. *PLoS One* 2016;11:e0163909.
10. Randolph BC, Peters MA. Analgesic effectiveness of ketorolac compared to meperidine in the rat formalin test. *Anesthesia Prog* 1997;44:11–6.
11. Huang Y, Yan Q, Lei W. Gluteal sciatic nerve injury and its treatment [Article in Chinese]. *Zhongguo Xiu Fu Chong Jian Wai Ke Za Zhi* 2000;14:83–6.
12. Mayer M, Romain O. Sciatic paralysis after a buttock intramuscular injection in children: an ongoing risk factor [Article in French]. *Arch Pediatr* 2001;8:321–3.
13. Gentili F, Hudson AR, Hunter D, Kline DG. Nerve injection injury with local anesthetic agents: a light and electron microscopic, fluorescent microscopic, and horseradish peroxidase study. *Neurosurgery* 1980;6:263–72.
14. Kline DG, Kim D, Midha R, Harsh C, Tiel R. Management and results of sciatic nerve injuries: a 24-year experience. *J Neurosurg* 1998;89:13–23.
15. Kline DG. Diagnostic approach to individual nerve injuries. In: Wilkins R, Rengachary S, editors. *Neurosurgery*. 2nd ed. New York: McGraw-Hill; 1996. p. 3125–46.
16. Todd PA, Sorkin EM. Diclofenac sodium. A reappraisal of its pharmacodynamic and pharmacokinetic properties, and therapeutic efficacy. *Drugs* 1988;35:244–85.
17. Yaffe B, Pri-Chen S, Lin E, Engel J, Modan M. Peripheral nerve injection injury: an experimental pilot study of treatment modalities. *J Reconstr Microsurg* 1986;3:33–7.
18. Gentili F, Hudson A, Kline DG, Hunter D. Peripheral nerve injection injury: an experimental study. *Neurosurgery* 1979;4:244–53.
19. Strasberg JE, Atchabahian A, Strasberg SR, Watanabe O, Hunter DA, Mackinnon SE. Peripheral nerve injection injury with antiemetic agents. *J Neurotrauma* 1999;16:99–107.
20. Canan S, Aktaş A, Ulkay MB, Colakoglu S, Ragbetli MC, Ayyildiz M, et al. Prenatal exposure to a non-steroidal anti-inflammatory drug or saline solution impairs sciatic nerve morphology: a stereological and histological study. *Int J Dev Neurosci* 2008;26:733–8.
21. Emir A, Kalkan Y, Bostan H. Histopathological effects of intramuscular metamizole sodium on rat sciatic nerve. *Iran J Basic Med Sci* 2016;19:829–36.
22. Holdgate A, Pollock T. Nonsteroidal anti-inflammatory drugs (NSAIDs) versus opioids for acute renal colic. *Cochrane Database Syst Rev* 2004;CD004137.
23. Renal colic in adults: NSAIDs and morphine are effective for pain relief. *Prescrire Int* 2009;18:217–21.
24. Balfour JA, Fitton A, Barradell LB. Lornoxicam. A review of its pharmacology and therapeutic potential in the management of painful and inflammatory conditions. *Drugs* 1996;51:639–57.
25. Radhofer-Welte S, Dittrich P, Simin M, Branebjerg PE. Comparative bioavailability of lornoxicam as single doses of quick-release tablet, standard tablet and intramuscular injection: a randomized, open-label, crossover phase I study in healthy volunteers. *Clin Drug Investig* 2008;28:345–51.
26. Dash A, Maiti R, Akantappa Bandakkanavar TK, Arora P. Intramuscular drotaverine and diclofenac in acute renal colic: a comparative study of analgesic efficacy and safety. *Pain Med* 2012;13:466–71.
27. Zippel H, Wagenitz A. A multicentre, randomised, double-blind study comparing the efficacy and tolerability of intramuscular dextropropofol versus diclofenac in the symptomatic treatment of acute low back pain. *Clin Drug Investig* 2007;27:533–43.
28. Colak S, Gunes H, Afacan MA, Kandis H, Erdogan MO, Ayranci M, et al. Anaphylaxis after intramuscular injection of diclofenac sodium. *Am J Emerg Med* 2014;32:815.e1–2.
29. Maurset A, Skoglund LA, Hustveit O, Oye I. Comparison of ketamine and pethidine in experimental and postoperative pain. *Pain* 1989;36:37–41.
30. Pincus DF. When and why I use pethidine. *Aust Fam Physician* 1991;20:392–4.
31. Bardo MT, Hughes RA. Exposure to a nonfunctional hot plate as a factor in the assessment of morphine-induced analgesia and analgesic tolerance in rats. *Pharmacol Biochem Behav* 1979;10:481–5.
32. Rezajooi K, Pavlides M, Winterbottom J, Stallcup WB, Hamlyn PJ, Lieberman AR, et al. NG2 proteoglycan expression in the peripheral nervous system: upregulation following injury and comparison with CNS lesions. *Mol Cell Neurosci* 2004;25:572–84.