

Case Report

Metastatic Ductal Eccrine Adenocarcinoma with Excellent Response to Immunotherapy

Matthew Fadhil^a Alistair Lochhead^b Hon Trinh^c Daniel Brungs^{a,d}

^aDepartment of Medical Oncology, Wollongong Hospital, Wollongong, NSW, Australia;

^bSouthern IML Pathology, Wollongong, NSW, Australia; ^cDepartment of Radiation Oncology, Shoalhaven Cancer Care Centre, Nowra, NSW, Australia; ^dGraduate School of Medicine, University of Wollongong, Wollongong, NSW, Australia

Keywords

Eccrine carcinoma · Ductal eccrine adenocarcinoma · Metastasis · Immunotherapy · Pembrolizumab

Abstract

Eccrine carcinoma, a subtype of which is ductal eccrine adenocarcinoma (DEA), is a rare cutaneous malignancy. For metastatic eccrine carcinoma, there are very limited data to guide treatment. Conventional chemotherapy is of limited benefit and there is only a small body of evidence for the use of immunotherapy in non-DEA eccrine carcinomas. We report the first case of metastatic DEA treated with a multimodality approach including surgery, radiotherapy, and immunotherapy, with an excellent prolonged response to pembrolizumab, and provide a review of the literature on pathological and management aspects for this rare tumour subtype. A 60-year-old male with a history of pT1N0M0 left scalp DEA, managed 2 years prior with excision and adjuvant radiotherapy, represented with a symptomatic right pontine metastasis. Imaging demonstrated intracranial, pulmonary, and hilar disease; biopsy of the cranial and lung lesions showed metastatic adenocarcinoma, morphologically similar to the previously resected scalp DEA. The patient was treated with stereotactic resections of his pontine metastases and adjuvant cranial radiotherapy, then commenced on immunotherapy with pembrolizumab. The patient has completed 21 months of pembrolizumab with a significant radiological response of the pulmonary and hilar disease and nil evidence of intracranial recurrence or further metastases. In this case report, we provide the first evidence of efficacy of immunotherapy in metastatic DEA, demonstrating an excellent and prolonged response of metastatic DEA to pembrolizumab. Further research is required to better establish the role of immunotherapy within the management protocol for this uncommon but aggressive tumour subtype.

© 2023 The Author(s).
Published by S. Karger AG, Basel

Correspondence to:
Matthew Fadhil, mattfadhil97@gmail.com

Introduction

Malignant cutaneous adnexal tumours (MCATs) are uncommon malignancies derived from the adnexal structures present in the normal skin, namely, sweat glands, sebaceous glands, and hair follicles. Eccrine carcinomas represent a subset of MCATs originating from eccrine glands, the most widely distributed sweat gland type. Eccrine carcinomas account for less than 0.01% of all cutaneous malignancies [1]. While the classification of eccrine carcinomas is complex and the nomenclature is often inconsistent, well-described subtypes include eccrine porocarcinoma, eccrine spiradenocarcinoma, and syringoid eccrine carcinoma [2]. Ductal eccrine adenocarcinoma (DEA) is a particularly rare subtype of eccrine carcinoma characterised by prominent ductal and variable glandular differentiation. It is reported to affect individuals of both sexes, primarily aged 50–80 years [3].

Eccrine carcinomas typically present as slow-growing nodules, plaques, or ulcerative lesions, with the most common sites of disease the being lower extremities, head and neck and trunk. DEA appears to have a predilection for the head and neck [2, 4]. The diagnosis of eccrine carcinoma relies on histopathological analysis of biopsy or excision specimens. Immunohistochemical techniques (including staining for CEA, EMA, ER, PR, and CK7) and molecular testing have been described for these tumours, though their role remains limited at present. Therefore, diagnosis is based primarily on morphological assessment. However, the diversity and rarity of eccrine carcinomas makes correct morphological classification challenging [1, 5]. In DEA, the appearance of marked ductal proliferation mimics metastatic adenocarcinoma from non-cutaneous sites such as the breast, further complicating the differential diagnosis [3].

The prognosis of eccrine carcinomas, as for other MCATs, is relatively poor. Eccrine carcinomas are typically locally aggressive and display a propensity for local recurrence. In addition, regional and distant metastasis rates as high as 30% have been reported for these tumours [6]. For DEA specifically, while data are limited, the prognosis appears particularly unfavourable, with a 70–80% risk of local recurrence and 40–50% risk of distant metastasis [2, 4].

The mainstay of management for localised eccrine carcinomas is surgical resection. This involves either wide local excision or Mohs micrographic surgery to achieve negative resection margins [5]. Regional lymph node dissection is recommended only if there is clinical suspicion of nodal disease [2]. Radiotherapy is often utilised as an adjunct to resection in high-risk cases such as large tumours, close resection margins, or lymphovascular or perineural invasion [5].

For metastatic eccrine carcinoma, conventional chemotherapy has been shown to be of limited benefit [7]. Data for the use of other systemic therapies, including targeted agents such as cetuximab, are limited to single-case reports only [8].

The utility of immunotherapy and immunotherapy-based combinations as a treatment modality for solid tumours is well demonstrated [9, 10], and there is an increasing understanding of the predictive factors and biomarkers for response to immunotherapy [11, 12]. The role of immunotherapy for metastatic non-melanoma skin cancer (NMSC) is an area of active research. Only a handful of case reports of immunotherapy in the setting of eccrine carcinomas are available, the majority for metastatic eccrine porocarcinoma [7, 8, 13–16]. The use of immunotherapy for metastatic DEA has not previously been published.

We present here the first case of DEA complicated by cerebral and pulmonary metastases, treated with a multimodality approach including surgery, radiotherapy, and immunotherapy, with an excellent response to immunotherapy on follow-up. We then proceed to review the literature on pathological and management aspects for this rare tumour subtype.

Case Presentation

A 60-year-old male presented to the emergency department at our centre in November 2020 with a 2-week history of progressive ataxia, dysarthria, and headache. The patient had an extensive history of NMSCs. He had undergone multiple excisions of basal cell cancers of the scalp, nose, upper limb, and back over the preceding decade, as well as a pT2N0M0 basaloid squamous cell cancer (SCC) of the scalp vertex in 2017. In December 2018, the patient presented with a rapidly enlarging, 2 cm nodular skin lesion of the left anterior scalp, 4 cm inferior to the previous scalp SCC. The lesion was treated with wide local excision and a rotational flap repair. Histopathology demonstrated an ovoid-shaped tumour with a peripherally circumscribed margin which appeared to be rising from the basal epidermis and infiltrating downward through the full thickness of the skin and subcutaneous adipose tissue onto underlying scalp aponeurosis. The tumour was composed mainly of anastomosing ductal and glandular structures lined by neoplastic cuboidal or columnar cells. On immunohistochemistry, EMA staining was strongly positive, CEA had focal ductal staining but was otherwise negative, and ER/PR and SOX10 were negative. The findings were most consistent with a primary pT1N0M0 DEA (Fig. 1a–c). Resection margins were negative, with nil lymphovascular or perineural invasion. On the consensus recommendation of the hospital multidisciplinary team, the patient was further treated with a course of adjuvant radiotherapy to the scalp – 55 Gy in 25 fractions – and scheduled for serial monitoring. The remainder of the past history was noncontributory with no other history of malignancies; the patient was a lifelong nonsmoker with occasional alcohol intake.

At the time of emergency department presentation in November 2020, physical examination demonstrated bilateral horizontal nystagmus, right-sided dysmetria and dysdiadochokinesis, and gait ataxia, with otherwise normal cranial nerve, upper limb, and lower limb neurological examinations. Neuroimaging revealed a solitary 25 mm peripherally enhancing cystic lesion of the right pons, with moderate surrounding oedema and mass effect, without significant midline shift (Fig. 2a). Further imaging, including a staging fluorodeoxyglucose positron emission tomography-computed tomography scan showed two left-sided pulmonary lesions (45 mm left lower lobe, 12 mm left lingula) and ipsilateral hilar lymphadenopathy (Fig. 2b). The pulmonary lesions were lobulated with an appearance more suggestive of metastases than a primary tumour. The patient underwent stereotactic retrosigmoid craniotomy and resection of the pontine tumour. The postoperative course was complicated by cerebral venous sinus thrombosis, for which required therapeutic anticoagulation. He also proceeded to a biopsy of the left lower lobe lung lesion. Histopathological review of both the lung and brain specimens demonstrated metastatic adenocarcinoma, morphologically similar to his previously resected scalp DEA (Fig. 1d, e). The specimens were CK7 positive, CK20 negative, and TTF-1 negative (making a primary lung adenocarcinoma less likely). PD-L1 expression by immunohistochemistry was negative (<1%). On further analysis of histopathology from the skin primary, mismatch repair protein expression by immunohistochemistry was also negative.

The patient was discussed at the neuro-oncology multidisciplinary team meeting, and the consensus decision was for adjuvant cranial radiotherapy and systemic treatment. However, the patient was readmitted prior to commencing radiotherapy with recurrence of his neurological symptoms, and repeat neuroimaging demonstrated rapid progression of his pontine disease. A redo right craniotomy and tumour decompression were performed with resolution of symptoms, and 2 weeks later, he commenced stereotactic radiotherapy to the pontine tumour – 25 Gy in 5 fractions. As there are no accepted treatments for metastatic eccrine carcinoma, and given the excellent efficacy of immunotherapy in other NMSCs, 1 week following radiotherapy, he commenced on immunotherapy with the anti-programmed death-1 (PD-1) checkpoint inhibitor pembrolizumab (200 mg every 3 weeks).

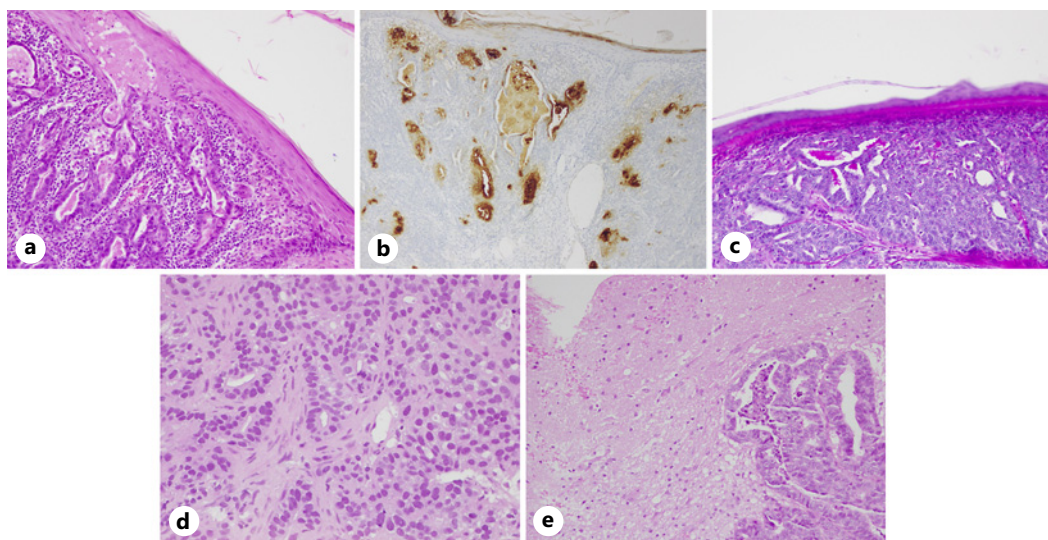


Fig. 1. Histopathology for scalp primary tumour and metastatic lesions. **a** H&E stain of malignant glandular epithelium deep to the epidermis ($\times 400$ magnification). **b** CEA stain positive in eccrine glands ($\times 100$ magnification). **c** PAS following diastase stain positive in eccrine glands ($\times 200$ magnification). **d** Metastatic adenocarcinoma in the lung ($\times 400$ magnification). **e** Metastatic adenocarcinoma in the brain ($\times 200$ magnification).

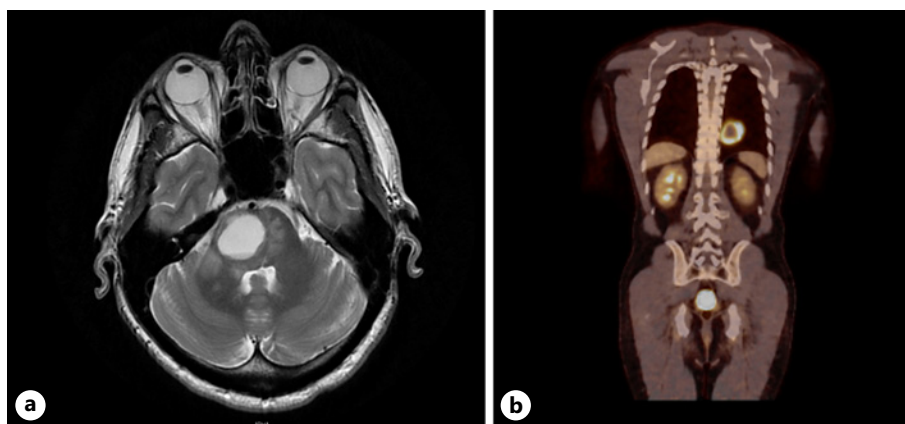


Fig. 2. Radiological evidence of distant metastasis on MRI brain demonstrating right pontine lesion (**a**), and PET-CT scan demonstrating PET-avid left-sided pulmonary lesion (**b**). PET, positron emission tomography; MRI, magnetic resonance imaging.

At the time of writing, the patient has completed 21 months of pembrolizumab with a significant radiological response of lung metastases and hilar lymphadenopathy (Fig. 3), and nil evidence of metastatic disease at other sites. He has completed 3 monthly magnetic resonance imaging brain scans with no evidence of intracranial recurrence. He has tolerated the pembrolizumab well with typical immunotherapy grade 1 rash only managed successfully with topical steroids.

A timeline of the events of the case is depicted in Figure 4. The CARE Checklist has been completed by the authors for this case report and is attached as supplementary material (for all online suppl. material, see <https://doi.org/10.1159/000533956>).

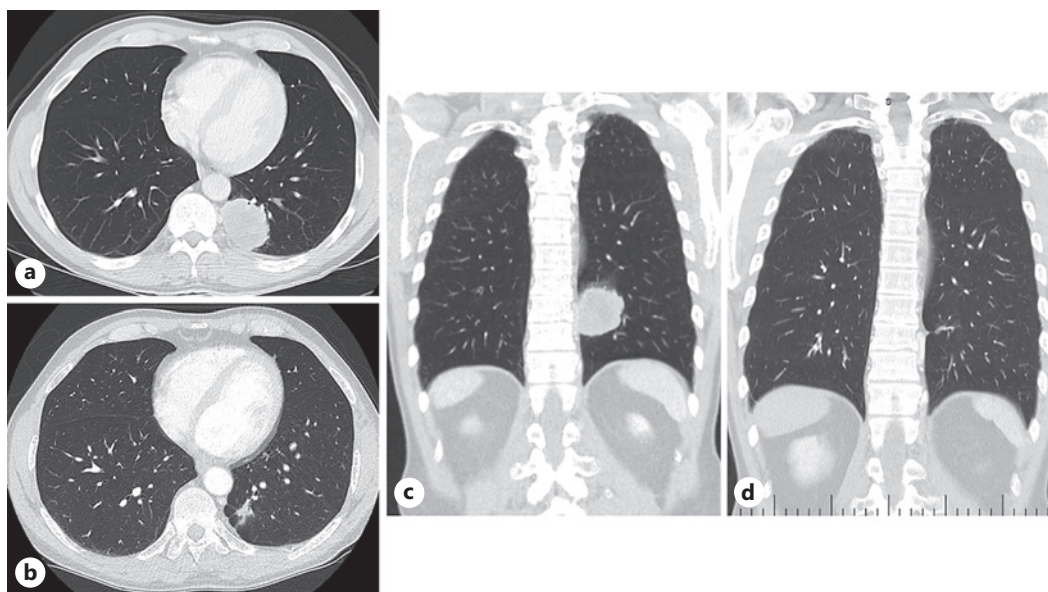


Fig. 3. CT of the chest in axial (**a, b**) and coronal slices (**c, d**): prior to immunotherapy (**a, c**); and following 21 months of immunotherapy, demonstrating radiological response of the lung metastases and hilar lymphadenopathy to pembrolizumab (**b, d**). CT, computed tomography.

Discussion

DEA, a subtype of eccrine carcinoma, is a very rare cutaneous malignancy characterised by eccrine origin with ductal differentiation [2]. Just under 20 cases of DEA reported under this label have been published in the last 2 decades, though further cases reported using synonyms or overlapping terms likely exist. In light of its rarity, no standardised management protocol for DEA has been established.

Our case is notable for the excellent response of the patient's metastatic disease to the anti-PD-1 antibody pembrolizumab. To our knowledge, this is the first paper to report on the use of immunotherapy for the management of metastatic DEA. On review of the published literature, 5 case reports in the last decade have presented favourable outcomes for immunotherapy used in other subtypes of eccrine carcinoma: two for eccrine porocarcinoma [14, 15], two for eccrine spiradenocarcinoma [7, 16], and one for eccrine carcinoma not otherwise specified [13] (Table 1). Of these, the report by Singh et al. shared many similarities with our own case: the authors described an elderly male with eccrine porocarcinoma of the anterior scalp, initially managed with surgical excision and adjuvant radiotherapy, later complicated by multiple distant metastases. The patient was then commenced on pembrolizumab, with evidence of favourable response at the sites of metastases, and at 27-month follow-up, the patient remained clinically and radiologically in remission [15]. Notably, one case of nonresponse to immunotherapy has also been reported (Table 1): Comito et al. [8] described progression of metastatic eccrine porocarcinoma despite 3 months of pembrolizumab; this patient was switched to cetuximab given tumour EGFR overexpression, with transient good effect. The influence of porocarcinoma histology in these conflicting papers, and to what extent the results for non-DEA eccrine carcinomas can be extrapolated to decision-making for metastatic DEA, remains unclear. Given the rarity of DEA, it is likely that in the short term we will need to continue to extrapolate management-related findings from the literature on other eccrine carcinoma subtypes, if not from other types of NMSC. Nevertheless, further research is critical in future to establish standardised recommendations around immunotherapy for patients with DEA.

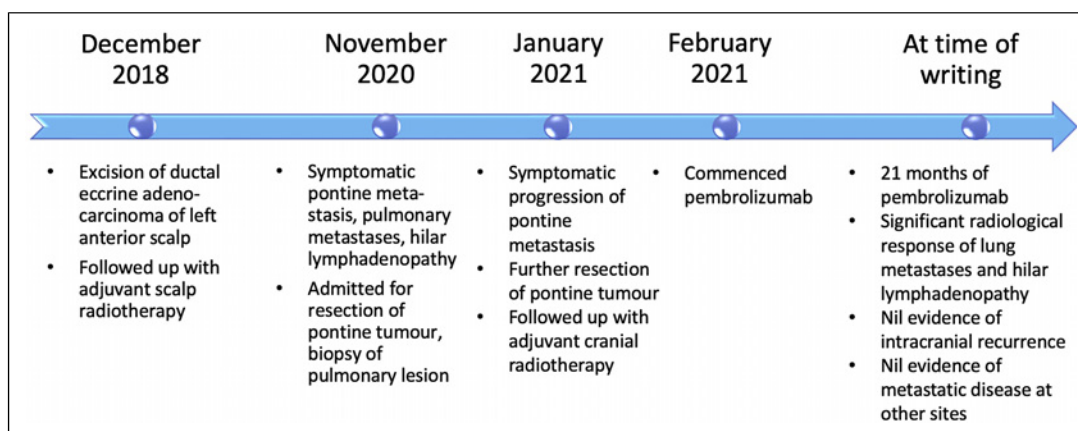


Fig. 4. Timeline of events of case presentation.

Interestingly, our patient had an excellent response to PD-1 inhibition despite negative PD-L1 expression. PD-L1 expression is strongly associated with response to immune checkpoint inhibitors in a number of solid tumours including non-small cell lung cancer [17]. However, data from tumour types such as hepatocellular cancer are mixed, with some trials showing no statistically significant differences between immunotherapy responders and nonresponders stratified by PD-L1 status, and favourable responses to immunotherapy documented regardless of PD-L1 expression [11]. In melanoma, durable responses are seen in PD-L1-negative patients [18]. Similarly in NMSC, the evidence for PD-L1 expression as a biomarker to predict response to immunotherapy is limited, although there are some signals for higher response rates in PD-L1-positive patients [19]. Pembrolizumab was used in this patient due to the high mutational burden seen in skin cancers secondary to ultraviolet exposure (including cutaneous SCC, basal cell cancer, and Merkel cell carcinoma), which is thought to explain the well-established sensitivity of skin cancers to immunotherapy [20].

In our patient, the scalp DEA primary was complicated by both cerebral and pulmonary metastases. Of these, the cerebral metastasis proved more overt clinically, resulting in significant symptom burden and requiring two operative decompressions and adjuvant stereotactic radiotherapy. In the previous literature on DEA, high rates of distant metastasis have been reported, occurring in 40–50% of cases [2, 4]. These figures are higher than, but generally comparable to, the prognostic data for other eccrine carcinomas and for MCATs more generally [6]. Sites of metastasis described in DEA include the lungs, liver, bone, and brain [4]. Intracranial involvement, while present in our patient, is not common in the eccrine carcinoma literature. A 2020 series by Gupta et al. [13] reported three cases of CNS-involving eccrine carcinoma, one of which was classified as DEA; on a literature review, the authors identified 20 previous cases of CNS invasion or metastasis in eccrine carcinoma, with duration of survival after diagnosis of CNS involvement ranging from weeks to 4 years. The propensity of DEA for local and regional nodal spread has also been well noted [6]. In one Brazilian series, a direct association of nodal status with mortality was suggested: 10-year survival rates for DEA were 9% and 56% for lymph node positive and negative disease, respectively [3]. As case reports of DEA continue to accumulate, our understanding of the specific biological behaviour of this extremely rare tumour subtype will continue to improve.

Our study has several key implications. It identifies a possible novel, efficacious treatment approach for patients with metastatic DEA which should be explored in subsequent trials. This case also highlights the need to take a more comprehensive view when considering the role of immunotherapy in rare malignancies, making sure to account for a range of factors including tumour biology rather than restricting selection criteria to limited biomarkers such

Table 1. Cases of eccrine carcinoma managed with immunotherapy in the literature

Author, year	Age, sex	Histology, site	Staging	Treatment	Immunotherapy agent	Outcome post-immunotherapy
Lee et al. [14] (2019)	67, female	Eccrine porocarcinoma, left lower limb	Metastatic	2012: surgical excision 2014: left inguinal and pelvic sidewall lymphadenectomy, adjuvant radiotherapy to nodal basin 2015: surgical excision, stereotactic radiosurgery 2016: carboplatin and capecitabine (12 cycles) 2017: immunotherapy	Pembrolizumab single agent 2 mg/kg 3-weekly	At 12 weeks, excellent partial response At 15 months, no clinical or radiological evidence of disease At 22 months, continues on treatment
Gupta et al. [13] (2020)	75, female	Eccrine carcinoma not otherwise specified, scalp vertex	Locally recurrent/inoperable with distal metastases	Initial: surgical excision 42 months later: paclitaxel and carboplatin dual therapy, proton beam radiotherapy 17 months later: palliative immunotherapy, radiotherapy	Pembrolizumab	At 2 months, developed radiculopathy requiring laminectomy and fusion At 5 months, mild progression of C5 and temporal bone lesions, then stable for 10 months At 15 months, haemorrhagic metastasis At 19 months, died of disease
Singh et al. [15] (2021)	79, male	Eccrine porocarcinoma, anterior scalp	Locally recurrent/inoperable	Initial: Mohs micrographic surgical excision Over next 11 months: two further Mohs excisions, adjuvant radiotherapy 11 months later: immunotherapy	Pembrolizumab	At 9 months, resolution of local recurrence, significant improvement of parotid masses, progression of submandibular nodal disease At 14 months, resolution of submandibular nodal disease, no distant metastasis At 27 months, in remission
Wu et al. [7] (2021)	56, male	Eccrine spiradenocarcinoma, right ring finger	Metastatic	2017: surgical excision, right thoracotomy with wedge excisions of lung lesions 2018: immunotherapy	Pembrolizumab, 200 mg 3-weekly	After 4 cycles, improvement of pulmonary nodules, increase in axillary node At further follow-up, remains stable on serial imaging

Table 1 (continued)

Author, year	Age, sex	Histology, site	Staging	Treatment	Immunotherapy agent	Outcome post-immunotherapy
Comito et al. [8] (2021)	70, male	Eccrine porocarcinoma, right scapula	Metastatic	June 2017: surgical excision September 2017: right axillary lymphadenectomy, docetaxel November 2018, April 2019: surgical excisions of recurrences October 2019: immunotherapy January 2020: cetuximab and capecitabine	Pembrolizumab 200 mg flat dose 3-weekly	At 4 months, progression in all organs involved with new brain and lymph node metastases After immunotherapy ceased, clinical and radiological response on cetuximab, treatment later suspended due to toxicity, 2 months later patient died of disease
Wargo et al. [16] (2022)	64, female	Eccrine spiradenocarcinoma, right upper arm	Metastatic	Initial: surgical excision, right radical axillary lymphadenectomy, carboplatin, and paclitaxel 3 months later: immunotherapy 10 months later: stereotactic radiosurgery, paclitaxel added 2 months later: switched to oral capecitabine, palliative radiotherapy to bowel, switched to gemcitabine and docetaxel	Pembrolizumab 200 mg 3-weekly	At 6 months, decrease in lung metastases At 10 months, progression with new single brain metastasis At 12 months, progression of lung metastases After immunotherapy ceased, progression on capecitabine, then on gemcitabine and docetaxel, 1 month later patient died of disease
Current case	60, male	DEA, left anterior scalp	Metastatic	December 2018: excision of lesion, adjuvant radiotherapy (55 Gy, 25 fractions) November 2020: stereotactic resection of pontine metastasis January 2021: repeat pontine metastasis resection, adjuvant cranial radiotherapy, immunotherapy	Pembrolizumab 200 mg every 3 weeks	At 21 months post-immunotherapy commencement, significant resolution of lung metastases and mediastinal nodes, nil evidence intracranial recurrence or metastatic disease at other sites

T, tumour stage; N, nodal stage; M, metastasis stage.

as PD-L1 only. Knowledge gaps remain, including the role of immunohistochemical and molecular testing for DEA, a clear understanding of the natural history of DEA, and identification of biomarkers to predict immunotherapy response in eccrine carcinomas. Unfortunately, there remain very little data to guide the management of patients with DEA, with no trials available comparing outcomes with chemotherapy, targeted therapies such as cetuximab, and immunotherapy. Researchers should aim to address these gaps by continuing to publish clinical and pathological data on DEA whenever this histology is encountered in practice. Designing comparative studies of treatments for eccrine carcinomas will likely continue to prove challenging given the rarity of this malignancy. Clinicians encountering very rare cases such as the case described herein should feel equipped to evaluate the NMSC and broader immunotherapy literature and, where appropriate, translate lessons learnt from this literature to the care of their patients with less-studied tumour subtypes.

Conclusions

In this case report, we describe a case of DEA, a rare subtype of eccrine carcinoma, with excellent response of metastatic disease to immunotherapy with pembrolizumab. Further research is required to better establish the role of immunotherapy within the management protocol for this uncommon but aggressive tumour subtype.

Statement of Ethics

The authors are accountable for all aspects of the work in ensuring that questions related to the accuracy or integrity of any part of the work are appropriately investigated and resolved. All procedures performed in studies involving human participants were in accordance with the ethical standards of the Institutional and/or National Research Committee(s) and with the Helsinki Declaration (as revised in 2013).

Written informed consent was obtained from the patient for the publication of this case report and the accompanying images. A copy of the written consent is available for review by the editorial office of this journal. This retrospective review of patient data did not require Ethical Review Board approval in accordance with local/national guidelines.

Conflict of Interest Statement

The authors have no conflicts of interest to declare.

Funding Sources

The authors received no funding for the research, authorship, and/or publication of this article.

Author Contributions

M.F. wrote the main manuscript text. D.B. was responsible for study conceptualisation and edited the main manuscript text. M.F. and H.T. prepared Figures 2 and 3. A.L. prepared Figure 1. All authors reviewed the manuscript.

Data Availability Statement

All data generated or analysed during this study are included in this article. Further enquiries can be directed to the corresponding author.

References

- 1 Rownose CS, Mohamad Saupi MS, Sharif SZ, Lah N. Aggressive scalp and sternal lesion: a presentation of rare case of metastatic eccrine carcinoma. *Ann Med Surg.* 2021;65:102322.
- 2 Brito MHTS, Dionísio CSNd M, Ferreira C, Rosa M, Cunha F, Garcia M. Ductal eccrine carcinoma of the axilla: a diagnostic pitfall. *An Bras Dermatol.* 2017;92(2):239–42.
- 3 Tavares G, Ledsham C, Oliveira IVD, Barcelos V. Carcinoma ductal de glândulas sudoríparas écrinas: desafio diagnóstico. *Surg Cosmet Dermatol.* 2019;11(4):338–41.
- 4 Kacker A, Shaha AR. Ductal eccrine carcinoma arising in the postaural area. *Ear Nose Throat J.* 1999;78(8):576–7.
- 5 Płachta I, Kleibert M, Czarnecka AM, Spałek M, Szumera-Ciećkiewicz A, Rutkowski P. Current diagnosis and treatment options for cutaneous adnexal neoplasms with apocrine and eccrine differentiation. *Int J Mol Sci.* 2021;22(10):5077.
- 6 Wang LS, Handorf EA, Wu H, Liu JC, Perlis CS, Galloway TJ. Surgery and adjuvant radiation for high-risk skin adnexal carcinoma of the head and neck. *Am J Clin Oncol.* 2017;40(4):429–32.
- 7 Wu C, Chow M, Temby M, McCalmont TH, Daud A. Response to PD-1 immunotherapy in metastatic spiradenocarcinoma. *JCO Precis Oncol.* 2021;5:340–3.
- 8 Comito F, Nigro MC, Sperandi F, Melotti B, Ardizzoni A. Immunotherapy-refractory, EGFR overexpressing metastatic porocarcinoma responding to cetuximab. *Eur J Cancer.* 2021;146:84–6.
- 9 Santoni M, Rizzo A, Kucharz J, Mollica V, Rosellini M, Marchetti A, et al. Complete remissions following immunotherapy or immuno-oncology combinations in cancer patients: the MOUSEION-03 meta-analysis. *Cancer Immunol Immunother.* 2023;72(6):1365–79.
- 10 Di Federico A, Rizzo A, Carloni R, De Giglio A, Bruno R, Ricci D, et al. Atezolizumab-bevacizumab plus Y-90 TARE for the treatment of hepatocellular carcinoma: preclinical rationale and ongoing clinical trials. *Expert Opin Investig Drugs.* 2022;31(4):361–9.
- 11 Rizzo A, Cusmai A, Gadaleta-Caldarola G, Palmiotti G. Which role for predictors of response to immune checkpoint inhibitors in hepatocellular carcinoma? *Expert Rev Gastroenterol Hepatol.* 2022;16(4):333–9.
- 12 Rizzo A, Cusmai A, Giovannelli F, Acquafredda S, Rinaldi L, Misino A, et al. Impact of proton pump inhibitors and histamine-2-receptor antagonists on non-small cell lung cancer immunotherapy: a systematic review and meta-analysis. *Cancers.* 2022;14(6):1404.
- 13 Gupta S, Hulsbergen AFC, Segar DJ, Hauser BM, Bernstock JD, Nazarian RM, et al. Central nervous system-invading eccrine gland carcinoma: a clinicopathologic case series and literature review. *World Neurosurg.* 2020;138:e17–25.
- 14 Lee KA, Cioni M, Robson A, Bataille V. Metastatic porocarcinoma achieving complete radiological and clinical response with pembrolizumab. *BMJ Case Rep.* 2019;12(9):e228917.
- 15 Singh A, Nguyen L, Everest S, Vinogradov M. Metastatic porocarcinoma effectively managed by pembrolizumab. *Cureus.* 2021;13(11):e20004.
- 16 Wargo JJ, Carr DR, Plaza JA, Verschraegen CF. Metastatic spiradenocarcinoma managed with PD-1 inhibition. *J Natl Compr Canc Netw.* 2022;20(4):318–20.
- 17 Garon EB, Rizvi NA, Hui R, Leigh N, Balmanoukian AS, Eder JP, et al. Pembrolizumab for the treatment of non-small-cell lung cancer. *N Engl J Med.* 2015;372(21):2018–28.
- 18 Daud AI, Wolchok JD, Robert C, Hwu W-J, Weber JS, Ribas A, et al. Programmed death-ligand 1 expression and response to the anti-programmed death 1 antibody pembrolizumab in melanoma. *J Clin Oncol.* 2016;34(34):4102–9.
- 19 D'Angelo SP, Lebbé C, Mortier L, Brohl AS, Fazio N, Grob JJ, et al. First-line avelumab in a cohort of 116 patients with metastatic Merkel cell carcinoma (JAVELIN Merkel 200): primary and biomarker analyses of a phase II study. *J Immunother Cancer.* 2021;9(7):e002646.
- 20 Zelin E, Maronese CA, Dri A, Toffoli L, Di Meo N, Nazzaro G, et al. Identifying candidates for immunotherapy among patients with non-melanoma skin cancer: a review of the potential predictors of response. *J Clin Med.* 2022;11(12):3364.