

Radiosurgery in treatment of cerebral arteriovenous malformation: Mid-term results of 388 cases from a single center

Mohammad Ali Bitaraf, Ramon Katoozpour, Mazyar Azar¹, Mohsen Nouri², Seyed Abolghasem Mortazavi³, Abbas Amirjamshidi³

Department of Neurosurgery, Imam Khomeini Hospital, ¹Rassoul Akram Hospital, ²Consultant Neurosurgeon, Gundishapour Academy of Neuroscience, Ahvaz, ³Sina Hospital, Tehran University of Medical Sciences, Tehran, Iran

ABSTRACT

Background and Objectives: The purpose of this study is to evaluate the outcome and risks of radiosurgery for patients with arteriovenous malformations (AVM) of the brain all treated in a single center in the 3rd world with all its limitations.

Materials and Methods: We performed a retrospective analysis of 388 patients with AVM treated with radiosurgery during an 8-year period. Factors associated with increased chance of AVM obliteration or hemorrhages during the follow-up period were analyzed.

Results: Among 388 cases included in our series, 74 were Spetzler-Martin (SM) grade IV or V. Forty-four patients (11.3%) experienced post-radiosurgery hemorrhage in their follow-up period. The number of feeders (one/multiple) and deep location of the AVM did not alter the chance of bleeding ($P < 0.05$). Higher SM grading of the AVM was associated with increased chance of hemorrhage and decreased obliteration rate ($P > 0.05$) in the mid-term follow up.

Conclusions: Our case series showed that radiosurgery can be considered a viable alternative in the treatment of even large AVMs which might not be considered good candidates for surgery or endovascular treatment. Further data including large size lesions are warranted to further support our findings.

Key words: Arteriovenous malformation of the brain, post-radiosurgery hemorrhage, radiosurgery

Introduction

There is no doubt that cerebral arteriovenous malformations (AVM) still pose one of the greatest challenges in neurosurgery. The prevalence of brain AVMs varies between 15 and 18 per 100 000 adults.^[1] The treatment of choice for AVMs remains controversial as the technological advancements continue to provide alternative options for their management and when long-term follow-up studies

become increasingly available. Microsurgical resection, stereotactic radiosurgery, and endovascular embolization, alone or in combination, are the treatment options currently available for these lesions.^[2,3] During the past two decades, stereotactic radiosurgery has been widely used to treat cerebral AVMs.^[4] In this communication, we present (a) our mid-term results with treatment of patients with cerebral AVMs, (b) Analyze factors associated with post-radiation hemorrhage, (c) the chance of AVM occlusion in our hands, and (d) compare our results with similar series in the literature.

Access this article online	
Quick Response Code:	Website: www.asianjns.org
	DOI: 10.4103/1793-5482.145121

Address for correspondence:

Dr. Abbas Amirjamshidi, MPH, Professor of Neurosurgery, Sina Hospital, Tehran University of Medical Sciences, Tehran, Iran. E-mail: abamirjamshidi@yahoo.com

This is an open access article distributed under the terms of the Creative Commons Attribution-NonCommercial-ShareAlike 3.0 License, which allows others to remix, tweak, and build upon the work non-commercially, as long as the author is credited and the new creations are licensed under the identical terms.

For reprints contact: reprints@medknow.com

How to cite this article: Bitaraf MA, Katoozpour R, Azar M, Nouri M, Mortazavi SA, Amirjamshidi A. Radiosurgery in treatment of cerebral arteriovenous malformation: Mid-term results of 388 cases from a single center. Asian J Neurosurg 2017;12:159-66.

Materials and Methods

Our gamma knife center is the only referral center for radiosurgery in a country with population of more than 70 million. Between 2002 and 2010, 388 consecutive patients with angiographically proved cerebral arteriovenous malformations underwent radiosurgery in this gamma knife center using a 201 source 60Co gamma unit (Elekta Instruments B, Stockholm, Sweden). Definition of the nidus and localization of the irradiation target were done using stereotactic magnetic resonance imaging (MRI).

The cases were referred from neurologists or neurosurgeons working all along the country and each one had selection criteria preferred by their attending physician. They were evaluated in our group only regarding the suitability of the cases for radiosurgery (RS). In this regard, nearly all the referred cases were included to be treated by RS.

After gamma knife surgery, patients would undergo (a) brain MRI every 6 months for 2 years and then annually, (b) conventional angiography was performed when MRI suggested complete obliteration, (c) a brain CT-scan or MRI was performed if patients experienced new or aggravated symptoms such as headache, seizure, decreased vision, or other neurological deficits to rule out hemorrhage, infarction, or radiation-induced edema. Medical records of these patients were retrospectively reviewed. Demographic, clinical, pre- and post-radiosurgery angiographies, and follow-up data were collected. Data analysis was performed using SPSS (version 13.0, Inc., Chicago, IL) and $P < 0.05$ were considered statistically significant. Data are represented as mean \pm standard error of mean (SEM) throughout the script.

Statistical analysis

Data analysis was performed using SPSS (version 13.0, Inc., Chicago, IL) and $P < 0.05$ were considered statistically significant. Data are represented as mean \pm standard error of mean (SEM) throughout the script.

Case illustrations

Case 1 - A 34-year-old man presented with epilepsy for the first time. He was also suffering from chronic headache for several years which had been treated with different kinds of medications without any imaging. CTS and MRI taken after epileptic attack were compatible with a large AVM located in the left posterior parietal region. He was referred for RS. Figures 1 and 2 show the angiography before and after RF. He has been followed for 5 years without any new event or bleeding.

Case 2 - A 39-year-old man presented with epilepsy which could be controlled with phenytoin three times daily. He was referred for RS after a deep right thalamic AVM [Figure 3] was

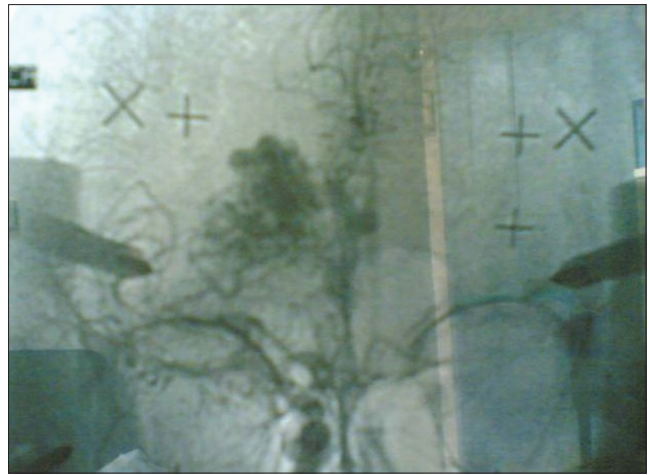


Figure 1: Angiograms obtained in a 34-year-old man revealing an AVM in the left posterior parietal region

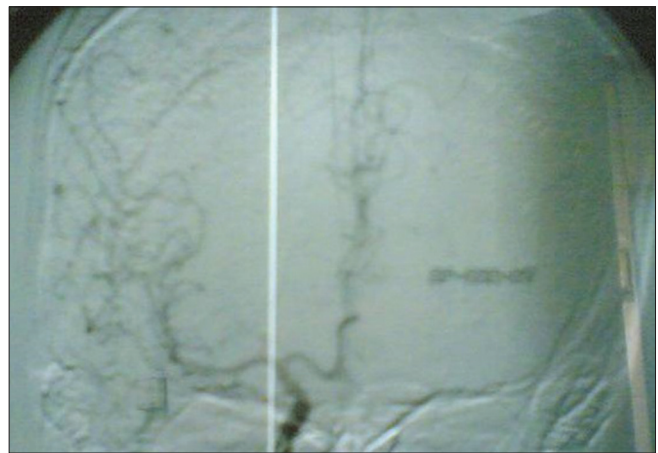


Figure 2: Follow-up angiography after one year showed AVM was obliterated without a residual AVM or any other abnormal vessels

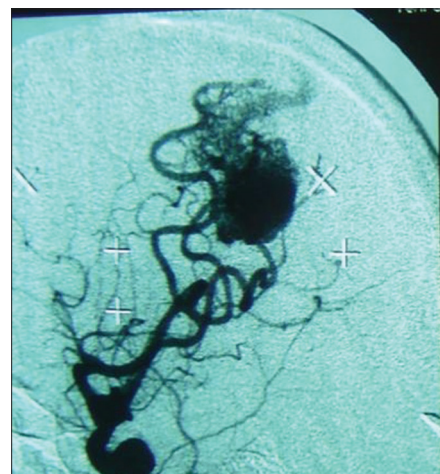


Figure 3: Digital subtraction angiography (DSA) before GKS showing a deep right thalamic AVM

detected. The angiogram performed after one year showed complete obliteration of the AVM [Figure 4].

Results

Demographic features and radiosurgical parameters

Among 388 patients enrolled in our study, 226 were male (58%). Mean age at the time of treatment was 27.52 ± 12.12 years. Fifteen patients had undergone CSF shunting and 12 had been embolized before undergoing radiosurgery. The mean follow-up duration was 61.59 ± 1.14 months (with range of 12 to 93 months). The characteristics of radiosurgical parameters which we used for the patients are showed in Table 1. One-sample Kolmogorov Smirnov test showed that none of these variables (i.e., treatment volume, prescription iso-dose line, maximum and marginal doses, iso-centers per AVM, and tumor coverage) followed a normal distribution ($P < 0.001$). So, for data analysis, non-parametric tests such as Kruskal-Wallis (KW) or Mann-Whitney U (MWU) tests were utilized instead of analysis of variance or *t*-tests.

Radiologic and clinical characteristics

The anatomic characteristics of the AVMs were: 215 (55.4%) had only one feeder and the others had multiple arterial feeders. Venous drainage was superficial in 225 (58%) cases and 163 (42%) were located in eloquent areas. The number of patients with AVMs smaller than 3 cm was 232 and 104 cases had lesions larger than 6 cm in diameter. One hundred eighty patients were grade I or II, 116 were graded III, and 74 were graded IV or V in SM classification. Table 2 shows the distribution of location of the treated AVMs. Supra-tentorial lesions (i.e., frontal, parietal, temporal, and occipital) compose the most frequent AVMs in our series (83.5%).

Clinical features of the patients at presentation are described in Table 3. The most frequent signs and symptoms included headache, seizure, hemorrhage, and limb paresis.

Neurological outcome

Neurological deficits happened in 15 patients (3.8%) after

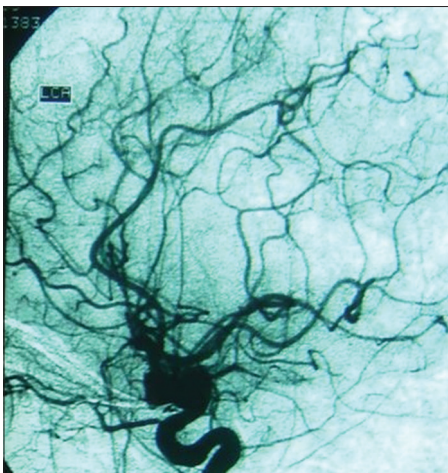


Figure 4: DSA performed one year after gamma knife showing complete obliteration of the nidus

gamma therapy and summarized in Table 4. All patients with radiation-induced edema had lesions larger than 3 cm with

Table 1: The characteristics of RS parameters

Treatment parameter	Mean±SEM	Range
Treatment volume (cc)	6.51±0.60	0.5-100
Prescription isodose line (%)	49.49±0.36	32-80
Maximum dose (cGy)	44.10±0.36	20-63
Marginal dose (cGy)	21.49±0.17	12-30
Isocenters per AVM	17.70±0.55	1-51
Tumor coverage (%)	98.38±0.08	91-100

SEM – Standard error of mean; RS – Radiosurgery; AVM – Arteriovenous malformations

Table 2: The anatomic distribution of AVMs

Location	Number of cases (%)
Frontal	59 (15.2)
Parietal	92 (23.7)
Temporal	64 (16.5)
Occipital	33 (8.5)
Basal ganglia	76 (19.6)
Brain stem	16 (4.1)
Corpus callosum	20 (5.2)
Intra-ventricular	17 (4.4)
Cerebellar	11 (2.8)
Total	388 (100)

AVMs – Arteriovenous malformations

Table 3: The clinical findings in patients with AVM

Signs and symptoms	Number of cases (%)
Headache	222 (57.2)
Seizure	194 (50.0)
Diplopia	32 (8.2)
Visual loss	52 (13.4)
Nystagmus	8 (2.1)
Gaze palsy	16 (4.1)
Proptosis	12 (3.1)
Pan-ophtalmoplegia	4 (1.0)
Ptosis	4 (1.0)
Dizziness	44 (11.3)
Anopsia	0 (0.0)
Drop attack	12 (3.1)
Hearing loss	16 (4.1)
Tinnitus	4 (1.0)
Facial numbness	16 (4.1)
Facial asymmetry	12 (3.1)
Nausea or vomiting	80 (20.6)
Dysarthria	20 (5.2)
Limb paresis	170 (43.8)
Imbalance	76 (19.6)
Spastic gait	6 (1.5)
Abnormal mentation	12 (3.1)
Hemorrhage (IVH/ICH)	174 (44.8)

AVM – Arteriovenous malformations; IVH – Intraventricular hemorrhage; ICH – Intracerebral hemorrhage

12 of them classified as grade IV or V of SM grading. Due to the small number of complications, in this series, statistical interpretation for finding the risk factors in developing new neurological deficits would be impossible.

Post-radiosurgery hemorrhage

Forty-four patients (11.3%) of the patients experienced post-radiosurgery hemorrhage (PRH) in their follow-up period. The duration of follow up did not affect the chance of hemorrhage ($P > 0.05$). Patients who had hemorrhage in one time point at their follow up were younger than those without hemorrhage ($P < 0.05$) considering the fact that younger patients were not followed for a longer time ($P < 0.05$). On the other hand, patients younger than 40 years were more likely to develop (12.4% vs 6.2% in those older than 40 years); however, this difference was not statistically significant ($P > 0.05$).

The number of feeders (one/multiple) or type of drainage (superficial/deep) did not alter the chance of bleeding ($P > 0.05$). The size of the AVMs with bleeding was less than 3 cm in 45.5% ($n = 20$) and more than 6 cm in 54.5% ($n = 24$) of cases. The size of the AVM proved to be an important factor in determining the chance of bleeding. AVMs smaller than 3 cm and those larger than 6 cm bled in 8.6% and 23.1% of cases, respectively ($P < 0.001$). Table 5 depicts the tendency to bleeding of our cases according to SM classification. Higher grades in this classification were associated with increased chance of bleeding after radiation ($P < 0.05$).

Brain stem, intra-ventricular, and cerebellar AVMs did not show any bleeding during the follow up. In the remaining

locations (i.e., frontal, parietal, occipital, temporal, basal ganglia, and corpus callosum), no significant difference was found regarding the chance of hemorrhage ($P > 0.05$).

Complete or partial obliteration of the AVM significantly reduced the chance of bleeding ($P < 0.001$). No bleeding was observed in patients with complete obliteration ($n = 249$) and among the patients with partial obliteration ($n = 103$), 27.2% developed hemorrhage in their follow up while 44.4% of the patients without obliteration of their AVMs ($n = 36$) were complicated with intra-cranial bleeding.

Overall, patients presented with headache were less likely to develop PRH (Post-radiosurgery hemorrhage) ($P < 0.05$). However, if one considers only supra-tentorial lesions, neither headache nor seizure showed prognostic value for chance of bleeding ($P > 0.05$). In supra-tentorial AVMS, presence of nausea/vomiting, hemorrhage, or motor weakness at presentation were associated with increased chance of PRH ($P < 0.01$). Due to the limited number of cases and data stratification, logistic regression analysis with matching of the cases and analysis for other locations (i.e., callosal, brain stem, intra-ventricular, and cerebellar AVMs) and for other signs and symptoms were not performed.

Among the treatment parameters [Table 4], only the number of iso-centers had good prognostic value with the higher number of iso-centers radiated per AVM, the higher the chance of PRH. In patients with iso-center dose less or higher than 20, the chance of PRH was 7.5% and 20.7%, respectively ($P < 0.001$). The numbers of iso-centers were significantly different based upon the location of AVM (with corpus callosum AVMs having the least number of iso-centers). Also, those AVMs larger than 6 cm were significantly radiated with higher iso-centers than the smaller ones. Eloquent lesions and number of draining veins or feeding arteries did not affect the therapeutic regimen in number of iso-centers ($P > 0.05$).

Pre-radiation embolization was associated with 33.3% chance of PRH ($P < 0.05$), but none of the cases treated previously with CSF diversion (i.e. shunting) developed PRH.

Obliteration of AVM

Among 388 patients, 249 (64.2%) showed complete and another 103 (26.5%) showed partial obliteration of their AVMs on follow up. Only 36 subjects (9.3%) had no evidence of obliteration on their follow-up imaging [Table 6]. The follow-up time and age were not statistically different between patients with complete, partial, or no obliteration (MWU, $P > 0.05$).

Eloquent locations, number of feeders, and type of drainage did not affect the chance of obliteration ($P > 0.05$), whereas the size of the lesions proved to be an important factor ($P < 0.001$) as AVMs smaller than 3 cm had 65.5% chance of complete obliterations vs lesions larger than 6 cm with 51.0% chance of complete occlusion. The SM grading of AVMs had significant correlation with the

Table 4: Neurological deficits observed after RS of AVMs

Neurologic complications	Number of cases (%)
Radiation induced edema	8 (2.0)
Transient hemi-paresis	4 (1.0)
Visual deficit	2 (0.5)
Cranial nerve palsy	1 (0.2)

RS – Radiosurgery; AVM – Arteriovenous malformations

Table 5: Distribution of patients with and without post-RS intracranial hemorrhage according to SM grading for cerebral AVMs

SM grading	Intracranial hemorrhage after RS		Total
	Yes	No	
I	8	68	76
II	12	110	122
III	8	108	116
IV	12	50	62
V	4	8	12
Total	44	344	388

RS – Radiosurgery; AVM – Arteriovenous malformations; SM – Spetzler-Martin

chance of obliteration ($P < 0.01$) with grade I and II having 9.2% and 4.9% chance of failure of obliteration, respectively, in contrast with grade V of which 33.3% had no obliteration at all [Table 7].

All infra-tentorial and intra-ventricular AVMs showed complete or at least partial obliteration, whereas supra-tentorial or callosal lesions showed 9.9% and 20.0% likelihood of no obliteration, respectively. If one classifies basal ganglia, corpus callosum, intra-ventricular, and brain stem AVMs as deep malformations, their obliteration rate was not different from other lesions ($P > 0.05$).

Among therapeutic parameters, fewer iso-centers, increased maximal and marginal dosages, and smaller treatment volumes were associated with enhanced obliteration rate ($P < 0.05$). In spite of being statistically different among the groups, the marginal dose, number of iso-centers, and treatment iso-dose differences were not of clinical importance [Table 6].

Although previous CSF shunting did not affect obliteration outcome ($P > 0.05$), but past history of embolization was associated with significantly increased rate of treatment failure ($P < 0.001$) with 25.0% showing no response to radiosurgery vs 8.9% in the absence of previous embolization. These results are unlikely to be due to selection bias as 66.6% of patients with previous embolization were grade I or II SM vs 50.5% in higher grades. However, due to limited number of patients with pre-radiosurgery embolization ($n = 12$), clinical interpretation should be done cautiously.

Table 6: RS parameters in patients with complete, partial or no obliteration of cerebral AVMs after RS

Treatment parameter	Obliteration		
	Complete	Partial	No
Treatment volume	4.82±0.37	6.82±0.92	17.17±4.98
Prescription isodose line	49.71±0.53	48.30±0.38	51.39±0.98
Maximum dose	51.80±3.53	42.60±0.58	43.72±0.79
Marginal dose	21.90±0.22	20.57±0.31	21.31±0.38
Isocenters per AVM	17.09±0.72	18.63±1.09	19.14±1.01
Tumor coverage	98.29±0.10	98.50±0.16	98.61±0.14

RS – Radiosurgery; AVM – Arteriovenous malformations

Table 7: Obliteration rate in different grades of SM in the AVMs

SM grading	Obliteration		Total
	Complete or partial	No obliteration	
I	69	7	76
II	116	6	122
III	109	7	116
IV	50	12	62
V	8	4	12
Total	352	36	388

RS – Radiosurgery; AVM – Arteriovenous malformations; SM – Spetzler-Martin

Among supra-tentorial lesions, headache and nausea/vomiting proved to be associated with worse obliteration rate ($P < 0.05$ and $P < 0.001$), but this correlation was not observed with seizure or hemorrhage at presentation ($P > 0.05$).

Discussion

Adverse effects of radiation

The risk of a radiation injury resulting in a permanent neurological deficit has been reported to be 2 to 3% in most reports.^[5-8] Our series suffered a slightly higher rate of complications (3.8%) which may be explained by higher percentage of complex lesions included. In our study, 8 patients (2.1%) developed symptomatic radiation-induced edema after a mean duration of 61.6 months (range, 12 to 94 months) after GKS. The incidence of radiation-induced edema was correlated with larger size of AVM and higher grade of S-M but according to the small numbers of these events, it is impossible to make a definite clinical interpretation.

Post radiosurgery hemorrhage

The risk of bleeding remains in 1.8 to 5% of patients per year until obliteration can be confirmed.^[9-11] The exact mechanisms through which radiosurgery reduces the chance of bleeding is not completely elucidated. However, the histopathological studies of arteriovenous malformations after radiosurgery have suggested some theories: (a) progressive thickening of the intimal layer, which begins as early as three months after radiosurgery, appears to decrease the stress to the vessel walls, (b) partial or complete thrombosis of the irradiated vessels may decrease the number of patent vessels in the malformation.^[12-16]

The risk of hemorrhage from AVM rupture persists after radiosurgery treatment.^[9] The risk of PRH is the subject of major debate among members of the neurosurgical community due to associated mortality and morbidity.^[17] The risk of hemorrhage during the latency period, i.e. usually 2 to 3 years, has not been well-defined because there are different studies reporting varying rates of increased,^[18] stabilized,^[19,20] or decreased risk of PRH.^[6,14,21]

Kurita *et al.*,^[22] Maruyama *et al.*,^[14] and N.A.S. Kiran *et al.*^[23] found no significant correlation between pre-treatment hemorrhage and hemorrhage in the period of latency. Our analysis also did not show any correlation between these two events. In our series, 11.3% of the population experienced hemorrhagic events after treatment, which is slightly higher than those published in the literature ranging from 6 to 10%.^[5,9] This can be partly explained by the fact that 19.0% of AVMs in our series were graded IV or V in S-M classification with 26.8% larger than 6 cm.

Our results demonstrated the size of the AVM to be an important factor in predicting the chance of future bleeding. Also, younger patients with AVMs larger than 6 cm (23.3%), higher S-M grade, and lack of obliteration were associated

with increased chance of PRH. Although higher number of iso-centers showed positive correlation with the chance of PRH, it can be explained by higher number of iso-centers in larger tumors. With a few exceptions, location of the AVM did not affect the chance of PRH. Brain stem, cerebellar, and intra-ventricular AVMs depicted no PRH during the time course of the study. Regarding the presenting symptoms, as there was extensive variability, no definite conclusion could be drawn. In our series, the number of feeders or type of drainage did not predict the chance of future bleeding.

The literature related with radiosurgery of AVMs is replete with predicting factors of PRH. Friedman *et al.*^[9] established that AVM volume was significantly correlated with PRH. Other studies reveal 3 main factors associated with hemorrhage: (1) a history of a prior bleed; (2) a single draining vein; and (3) a diffuse AVM morphology. Seven other less important predicting factors include intra-nidal aneurysm, venous reflux, and RS dosing parameters of AVM coverage and minimal dosing.^[24] A history of AVM hemorrhage may also predispose the patient to an increased risk of subsequent bleeding in cases of untreated AVMs.^[25-28]

Arteriovenous malformation obliteration rate

Cerebral angiography is considered the most accurate imaging to confirm complete AVM obliteration after radiosurgery.^[6] Pollock *et al.* reported that serial MRI was predictive of total obliteration in 84% of patients.^[6,11] Because of its low risk and high reliability, it is reasonable to use MRI to evaluate obliteration after radiosurgery.^[6]

The reported obliteration rate of the nidus in the brain AVMs after radiosurgery varies between 43 to 92%.^[4,20,22-24,29-32] In our study, complete or partial obliteration rate was achieved in 352 of the patients (90.7%) which looks quite acceptable.

Kano *et al.* found that factors associated with a higher rate of total obliteration on angiography included smaller target volume, smaller maximum diameter, and larger marginal dose.^[6] Larger size and higher than S-M grade IV were found to influence the obliteration rate in some series of AVMs.^[8,33-35]

Friedman *et al.* reported that complete obliteration was obtained in 81% of AVMs between 1 ml and 4 ml in volume, in 89% of AVMs between 4 ml and 10 ml, and in 69% of AVMs >10ml.^[9] Chang *et al.* reported a series of 53 patients with giant AVMs treated with a combination of modalities (microsurgery, endovascular therapy, RS) and the obliteration rate was 36% in their series (12). Murray *et al.* published increased volume was significantly associated with non-obliteration. Volume was a more important factor than eloquent location, patient age, or gender.^[5] Morphological features of the AVM and its density influence the success of AVM obliteration.^[5] Diffuse AVM structure is associated with higher risk of radiosurgery failure.^[5,35] In our study, the size of the lesions was an important factor ($P < 0.001$) as AVMs smaller than 3 cm had 65.5% chance

of complete obliterations vs lesions larger than 6 cm with 51.0% chance of complete occlusion.

Other factors such as S-M grade, radiation dosing, and targeting have been associated with obliteration success.^[1,9,21,35]

In our study, AVM S-M grade was associated with obliteration status. AVMs with S-M grade IV or V were less likely to be obliterated than AVMs of lower grades. G. Murray *et al.* reported that radiation dosage was not different between obliterated and non-obliterated lesions, or between large and small AVMs.^[5] Our analysis revealed that radiation dosage resulted in higher obliteration rate. Factors such as number of iso-centers, and prior embolization, were not found to influence the obliteration rate in our series.

Results for deep vs other intra-cranial locations of arteriovenous malformations

Sasaki *et al.* found a significantly higher prevalence of radiation edema in deep regions compared to AVMs at other regions.^[32] Kobayashi *et al.* reported a higher obliteration rate in basal ganglia AVMs compared to 76% in AVMs at other locations.^[22,29] Kiran *et al.* reported higher incidence of hemorrhage in the period of latency (9.4% vs 3%) in patients with central AVMs. He found lower obliteration rates and development of symptomatic radiation edema were associated with central location of AVM.^[23] Nicolato *et al.* noted no difference in obliteration rates, permanent morbidity, and hemorrhage in the period of latency.^[31] In our study, neither the obliteration rate nor the incidence of PRH were different between deeply located and other AVMs.

Limitations of the study

Despite above findings, our study also had some shortcomings. Because we did not enroll a control group of patients who did not undergo radiosurgery, it was not clear whether the decrease in the risk of hemorrhage after radiosurgery reflects the natural history of the lesions, rather than effects of the procedure itself. A natural decline in the rate of recurrent bleeding has been reported within one year after the rupture of arteriovenous malformations.^[27,28,38,39] The most accurate way to evaluate the effect of radiosurgery on AVM re-bleeding would be a randomized controlled trial which may face ethical issues regarding already-known high risk of hemorrhage in the control group with no treatment. So, this limitation is not confined only to our study.

Recommendations for management of cerebral arteriovenous malformations

Every therapeutic modality that treats AVMs should be associated with reduction of the risk of re-bleeding to a level less than AVM natural history. To reach this aim, the treatment should obliterate the AVM partially or totally. Also, we should keep in mind that side effects, neurological status, and mortality of the patients should be addressed when evaluating a therapeutic plan. When treating these formidable

malformations, an optimal treatment may be far from ideal and reducing the risk, may outweigh its elimination in some cases.

Decreasing the risk of bleeding in patients with AVMs via the obliteration is the primary goal of radiosurgery. The benefits of radiosurgery compared with surgical and endovascular treatments are that it is non-invasive, has minimal risk of severe complications, and is performed as an outpatient procedure. The Latency between RS and occlusion is disadvantage of this method compared with surgical excision. Another potential disadvantage of RS is possible adverse effects of radiation. Finally, RS has been shown to be less effective for lesions more than 10 ml in volume.^[8]

Radiosurgery is a reasonable alternative to surgical treatment when an AVM is less than 3 cm in diameter and is located in an area of eloquent cortex.^[6,40,14] Obliteration is more likely with smaller lesions and with higher radiation doses.^[7,41] In experienced hands, the surgical morbidity of resection for Grade I and II AVMs is quite low which may make them prone to surgery.^[42,43] Favorable outcome has been achieved by different therapeutic modalities for low S-M grade AVMs but more argument is about treatment of higher grade AVMs.^[6,42] This series included 74 patients with either grade IV or V AVMs of which 35 (47.2%) patients showed complete and 23 (31.0%) showed partial occlusion of the AVM in their follow up. All infra-tentorial and intra-ventricular AVMs (104 cases) developed complete or partial obliteration without any PRH during the medium follow-up period. When considering an optimal treatment for these challenging lesions, we believe that radiosurgery seem a viable option.

Conclusions

Our case series showed that radiosurgery can be considered even in patients with large cerebral AVMs. However, careful follow up is warranted and due to risk of re-bleeding, alternative interventions for those with partial or no obliteration should be considered. Literature of surgery, interventional radiology, and radio-surgery require more studies to elucidate case selection for each modality and timing for shift to another alternative, if required.

Financial support and sponsorship

Nil.

Conflicts of interest

The authors declare that the article content was composed in the absence of any commercial or financial relationships that could be construed as a potential conflict of interest.

References

- Al-Shahi R, Fang JS, Lewis SC, Warlow CP. Prevalence of adults with brain arteriovenous malformations: A community based study in Scotland using capture- recapture analysis. *J Neurol Neurosurg Psychiatry* 2002;73:547-51.
- Maruyama K, Shin M, Tago M, Kurita H, Kawahara N, Morita A, *et al.* Management and outcome of hemorrhage after Gamma Knife surgery for arteriovenous malformations of the brain. *J Neurosurg* 2006;105:52-7.
- Ogilvy CS, Stieg PE, Awad I, Brown RD Jr, Kondziolka D, Rosenwasser R, *et al.* AHA Scientific Statement: Recommendations for the management of intracranial arteriovenous malformations: A statement for healthcare professionals from a special writing group of the Stroke Council, American Stroke Association. *Stroke* 2001;32:1458-71.
- Maruyama K, Kondziolka D, Niranjana A, Flickinger JC, Lunsford LD. Stereotactic radiosurgery for brain stem arteriovenous malformations: Factors affecting outcome. *J Neurosurg* 2004;100:407-13.
- Murray G, Brau RH. A 10-year experience of radiosurgical treatment for cerebral arteriovenous malformations: A perspective from a series with large malformations. *J Neurosurg* 2011;115:337-46.
- Kano H, Kondziolka D, Flickinger JC, Yang HC, Flannery TJ, Niranjana A, *et al.* Stereotactic radiosurgery for arteriovenous malformations, Part 5: Management of brainstem arteriovenous malformations. *J Neurosurg* 2012;116:44-53.
- Liscák R, Vladyka V, Simonová G, Urgosik D, Novotný J Jr, Janoušková L, *et al.* Arteriovenous malformations after Leksell gamma knife radiosurgery: Rate of obliteration and complications. *Neurosurgery* 2007;60:1005-16.
- Shin M, Kawamoto S, Kurita H, Tago M, Sasaki T, Morita A, *et al.* Retrospective analysis of a 10-year experience of stereotactic radiosurgery for arteriovenous malformations in children and adolescents. *J Neurosurg* 2002;97:779-84.
- Friedman WA, Blatt DL, Bova FJ, Buatti JM, Mendenhall WM, Kubilis PS. The risk of hemorrhage after radiosurgery for arteriovenous malformations. *J Neurosurg* 1996;84:912-9.
- Geibprasert S, Pongpech S, Jiarakongmun P, Shroff MM, Armstrong DC, Krings T. Radiologic assessment of brain arteriovenous malformations: What clinicians need to know. *Radiographics* 2010;30:483-501.
- Pollock BE, Flickinger JC, Lunsford LD, Bissonette DJ, Kondziolka D. Hemorrhage risk after stereotactic radiosurgery of cerebral arteriovenous malformations. *Neurosurgery* 1996;38:652-61.
- Chang SD, Shuster DL, Steinberg GK, Levy RP, Frankel K. Stereotactic radiosurgery of arteriovenous malformations: Pathologic changes in resected tissue. *Clin Neuropathol* 1997;16:111-6.
- Karlsson B, Lindquist C, Steiner L. Effect of gamma knife surgery on the risk of rupture prior to AVM obliteration. *Minim Invasive Neurosurg* 1996;39:21-7.
- Maruyama K, Kawahara N, Shin M, Tago M, Kishimoto J, Kurita H, *et al.* The risk of hemorrhage after radiosurgery for cerebral arteriovenous malformations. *N Engl J Med* 2005;352:146-53.
- Phillips TL. Early and late effects of radiation on normal tissues. In Gutin PH, Leibel SA, Sheline GE. *Radiation Injury to the Nervous System*. New York, NY: Raven Press Ltd; 1991. p. 37-55.
- Schneider BF, Eberhard DA, Steiner LE. Histopathology of arteriovenous malformations after gamma knife radiosurgery. *J Neurosurg* 1997;87:352-7.
- Nataf F, Ghossoub M, Schlienger M, Moussa R, Meder JF, Roux FX. Bleeding after radiosurgery for cerebral arteriovenous malformations. *Neurosurgery* 2004;55:298-306.
- Colombo F, Pozza F, Chierago G, Casentini L, De Luca G, Francescon P. Linear accelerator radiosurgery of cerebral arteriovenous malformations: An update. *Neurosurgery* 1994;34:14-21.
- Karlsson B, Lindquist C, Steiner L. Prediction of obliteration after gamma knife surgery for cerebral arteriovenous malformations. *Neurosurgery* 1997;40:425-31.
- Pollock BE, Flickinger JC, Lunsford LD, Bissonette DJ, Kondziolka D. Factors that predict the bleeding risk of cerebral arteriovenous malformations. *Stroke* 1996;27:1-6.
- Karlsson B, Lax I, Söderman M. Risk for hemorrhage during the 2-year latency period following gamma knife radiosurgery for arteriovenous malformations. *Int J Radiat Oncol Biol Phys* 2001;49:1045-51.
- Kurita H, Kawamoto S, Sasaki T, Shin M, Tago M, Terahara A, *et al.*

- Results of radiosurgery for brainstem arteriovenous malformations. *J Neurol Neurosurg Psychiatry* 2000;68:563-70.
23. Kiran NA, Kale SS, Kasliwal MK, Vaishya S, Gupta A, Singh Sharma M, *et al.* Gamma knife radiosurgery for arteriovenous malformations of basal ganglia, thalamus and brainstem: retrospective study comparing the results with that for AVMs at other intracranial locations. *Acta Neurochir* 2009;151:1575-82.
 24. AndradeSouza YM, Zadeh G, Scora D, Tsao MN, Schwartz ML. Radiosurgery for basal ganglia, internal capsule and thalamus arteriovenous malformation: Clinical outcome. *Neurosurgery* 2005;56:56-62.
 25. Crawford PM, West CR, Chadwick DW, Shaw MD. Arteriovenous malformations of the brain: Natural history in unoperated patients. *J Neurol Neurosurg Psychiatry* 1986;49:1-10.
 26. Forster DM, Steiner L, Hakanson S. Arteriovenous malformations of the brain. A long-term clinical study. *J Neurosurg* 1972;37:562-70.
 27. Fults D, Kelly DL Jr. Natural history of arteriovenous malformations of the brain: A clinical study. *Neurosurgery* 1984;15:658-62.
 28. Graf CJ, Perret GE, Torner JC. Bleeding from cerebral arteriovenous malformations as part of their natural history. *J Neurosurg* 1983;58:331-7.
 29. Kobayashi T, Tanaka T, Kida Y, Oyama H, Niwa M, Maesawa S. Gamma knife treatment of AVM of basal ganglia and thalamus. *No To Shinkei* 1996;48:351-6.
 30. Massager N, Régis J, Kondziolka D, Njee T, Levivier M. Gamma knife radiosurgery for brainstem arteriovenous malformations: Preliminary results. *J Neurosurg* 2000;103:563-70.
 31. Nicolato A, Foroni R, Crocco A, Zampieri PG, Alessandrini F, Bricolo A, *et al.* Gamma knife radiosurgery in the management of arteriovenous malformations of the basal ganglia region of the brain. *Minim Invasive Neurosurg* 2002;45:211-23.
 32. Sasaki T, Kurita H, Saito I, Kawamoto S, Nemoto S, Terahara A, *et al.* Arteriovenous malformations in the basal ganglia and thalamus: Management and results in 101 cases. *J Neurosurg* 1998;88:285-92.
 33. Levy EI, Niranjana A, Thompson TP, Scarrow AM, Kondziolka D, Flickinger JC, *et al.* Radiosurgery for childhood intracranial arteriovenous malformations. *Neurosurgery* 2000;47:834-42.
 34. Smyth MD, Sneed PK, Ciricillo SF, Edwards MS, Wara WM, Larson DA, *et al.* Stereotactic radiosurgery for pediatric intracranial arteriovenous malformations: The University of California at San Francisco experience. *J Neurosurg* 2002;97:48-59.
 35. Zipfel GJ, Bradshaw P, Bova FJ, Friedman WA. Do the morphological characteristics of arteriovenous malformations affect the results of radiosurgery? *J Neurosurg* 2004;101:393-401.
 36. Pollock BE, Lunsford LD, Kondziolka D, Maitz A, Flickinger JC. Patient outcomes after stereotactic radiosurgery for "operable" arteriovenous malformations. *Neurosurgery* 1994;35:1-8.
 37. Sun DQ, Carson KA, Raza SM, Batra S, Kleinberg LR, Lim M, *et al.* The radiosurgical treatment of arteriovenous malformations: Obliteration, morbidities, and performance status. *Int J Radiat Oncol Biol Phys* 2010;80:354-61.
 38. Mast H, Young WL, Koennecke HC, Sciacca RR, Osipov A, Pile-Spellman J, *et al.* Risk of spontaneous haemorrhage after diagnosis of cerebral arteriovenous malformation. *Lancet* 1997;350:1065-8.
 39. Itoyama Y, Uemura S, Ushio Y, Kuratsu J, Nonaka N, Wada H, *et al.* Natural course of unoperated intracranial arteriovenous malformations: Study of 50 cases. *B J Neurosurg* 1989;71:805-9.
 40. Lanzino G. Role of radiosurgery for arteriovenous malformations. *J Neurosurg* 2012;116:7-8.
 41. Orto P, Stelzer KJ, Goodkin R, Douglas JG. Treatment of arteriovenous malformations with linear accelerator-based radiosurgery compared with Gamma Knife surgery. *J Neurosurg* 2006;105 Suppl: 58-63.
 42. Hamilton MG, Spetzler RF. The prospective application of a grading system for arteriovenous malformations. *Neurosurgery* 1994;34:2-7.
 43. Heros RC, Korosue K, Diebold PM. Surgical excision of cerebral arteriovenous malformations: Late results. *Neurosurgery* 1990;26:570-8.