

# Surgical Outcomes After Total or Subtotal Resection of Large Vestibular Schwannoma: A Single-Institution Experience

Sujin Rujimethapass , Anant Ananthanandorn , Krissanee Karnchanapandh ,  
Mathee Wongsirisuwan , Ittipon Gunnarat , Noppatee Segkaphant 

Division of Neurosurgery, Department of Surgery, Rajavithi Hospital, College of Medicine, Rangsit University, Bangkok, Thailand

**Background** Patients with large vestibular schwannomas have various surgical outcomes. The aim of this study is to evaluate facial nerve outcome and surgical complications in patients who underwent total and subtotal resection.

**Methods** Between October 2008 and September 2020, 72 patients underwent surgery in Rajavithi Hospital. Of these, 48 had total or subtotal resection. We classified these participants into two groups: VS  $\geq 3$  cm (Group A, n=30); and VS  $< 3$  cm (Group B, n=18). Both groups were compared in terms of clinical presentation, imaging data, facial nerve outcomes, and surgical complications. The retrosigmoid approach was used in each case, and all patients had follow-up for at least 1 year. Chi-square and Fisher's exact test were used for statistical analysis.

**Results** The mean tumor size in Group A was 3.8 cm compared with 1.5 cm in Group B. In Group A, clinical signs of hearing dysfunction, gait ataxia, and facial paresthesia were present in 96.7%, 66.7%, 50% of patients respectively, compared with 100%, 5.6%, and 11.1% respectively in Group B. Radiographic signs of hydrocephalus were observed in 56.7% of Group A subjects, and 5.6% of those in Group B. At 1 year follow-up, 40% of patients with large VS and 94.4% of patients with small to medium size VS had good facial nerve outcomes (House-Brackmann [HB] facial grading scale grade I-III). Significant differences between the two groups were found only in gait ataxia ( $p < 0.001$ ), facial paresthesia ( $p = 0.006$ ), radiographic signs of hydrocephalus ( $p = 0.002$ ), facial nerve outcome 1 month ( $p < 0.001$ ) and facial nerve outcome 1 year ( $p < 0.001$ ).

**Conclusion** In patients with large size VS, microsurgical resection had poor facial nerve outcomes compared with those of their counterparts with small to medium size VS. Planned subtotal resection with postoperative radiosurgery might attain superior facial nerve outcomes and result in better quality of life in subjects with large VS.

**Keywords** Schwannoma; Facial nerve; Outcome.

**Received** November 8, 2021

**Revised** February 19, 2022

**Accepted** April 4, 2022

## Correspondence

Sujin Rujimethapass  
Division of Neurosurgery,  
Department of Surgery,  
Rajavithi Hospital,  
College of Medicine, Rangsit University,  
2 Phayathai Road, Ratchathewi District,  
Bangkok 10400, Thailand  
**Tel:** +66-2-206-2900  
**Fax:** +66-2484-4808  
**E-mail:** neurosurg.rj@gmail.com

## INTRODUCTION

Vestibular schwannomas (VS), also known as acoustic neuroma, are benign tumors of schwann cells that mostly originate from the superior vestibular nerve [1]. Many studies in the literature have reported that the incidence of VS ranges from 0.6 to 1.9 per 100,000 population [2-5]. The incidence of

VS has also been shown to be increasing, mostly because of technological advancements in detection methods, such as magnetic resonance imaging [3,4]. Classically, VS are found within the internal acoustic meatus, and when the tumors grow, they tend to expand into the cerebellopontine angle, with various symptoms resulting from mass effect. Treatment modalities include observation with serial imaging, stereotactic radiosurgery, or stereotactic radiotherapy and microsurgery. The choice of treatment is dependent on patient age, underlying diseases, clinical symptoms, and tumor size.

In certain situations, it is impossible to eradicate VS completely because the position of the tumor involves vital struc-

This is an Open Access article distributed under the terms of the Creative Commons Attribution Non-Commercial License (<https://creativecommons.org/licenses/by-nc/4.0>) which permits unrestricted non-commercial use, distribution, and reproduction in any medium, provided the original work is properly cited.

Copyright © 2022 The Korean Brain Tumor Society, The Korean Society for Neuro-Oncology, and The Korean Society for Pediatric Neuro-Oncology

tures, such as facial nerves, other cranial nerves, or brain stems, which often lead to postoperative complications. Facial nerve weakness after VS resection is one of the most common complications following tumor removal, along with cerebrospinal fluid (CSF) leak, meningitis, and other cranial nerve deficits, or even death.

We recorded demographic data, clinical presentations, imaging data, facial nerve outcomes, and surgical complications among patients who underwent total and subtotal resection and compared results of patients having small to medium size VS with those with large VS and who underwent surgery in the same institution.

## MATERIALS AND METHODS

### Patient population

A retrospective study was conducted of patients who were surgically treated for VS between October 2008 and September 2020 at Rajavithi Hospital, Bangkok, Thailand. This study was approved by the Institutional Review Board of Rajavithi Hospital (approval no. 64057). Informed consent was waived due to the retrospective data collection. Of the total 72 patients who underwent surgery, 24 were excluded from this study: 17 of these were not included because they had undergone partial resection; 4 had no preoperative or postoperative data; 2 had preoperative facial nerve palsy; and 1 had bilateral VS. Information relevant to the study was recorded, including age, sex, clinical presentation, duration of symptoms, imaging data, tumor size, presence of hydrocephalus, and type of resection. Type of resection was classified by subjective intraoperative impression correlated with first postoperative imaging. More than 5% of residual tumors were defined as partial resection, 2%–5% were classified as subtotal resection (STR) and less than 2% were considered gross total resection (GTR) or near total resection (NTR) [6]. The tumor size was measured as the largest single preoperative tumor diameter including the intracanalicular portion of the lesion. Definition of cystic VS was a cyst component that is more than 50% of total volume [7]. Facial nerve outcomes at 1 month, 1 year follow-up and surgical complications were observed only in those who underwent total and subtotal resection. Postoperative facial nerve function was classified according to the House-Brackmann (HB) facial grading scale as good (HB grade I–III) or poor (HB grade IV–VI). In all operations, the retrosigmoid approach was used, with the patient in the parkbench or sitting position, and continuous facial nerve monitoring was performed in most cases. The patients were divided into two groups: Group A consisted of patients with VS  $\geq 3$  cm, and Group B comprised patients with VS  $< 3$  cm [8,9].

### Statistical analysis

The chi-square and Fisher's exact tests were used to compare clinical presentation, imaging data, facial nerve outcomes, and surgical complications in the two groups. A difference at probability level  $< 0.05$  was considered statistically significant.

## RESULTS

The records were reviewed of 48 patients, all of whom had undergone the retrosigmoid approach; 30 patients (62.5%) had tumor size  $\geq 3$  cm (Group A), and 18 patients (37.5%) had tumor size  $< 3$  cm (Group B). The subjects ranged in age from 21 to 72 years, with a mean age of 52.8 years, and females accounted for 72.9% of the total number of patients studied.

### Clinical presentation and imaging data

#### Group A

Patients' mean age was 51.4 years (range 21–71 years) (Fig. 1A and B). There were more women (70%) than men (30%), and the left side was involved in 22 cases (73.3%) and the right side in 8 (26.7%). The mean duration of symptoms was 10.1 months (range 1–24 months), and the mean tumor size was 3.8 cm (range 3.0–5.3 cm) (Table 1). Preoperative imaging showed cystic VS in 10 patients (33.3%) and solid VS in 20 (66.7%). Nearly all patients had hearing dysfunction; 20 (66.7%) had gait ataxia; 15 (50%) had decreased facial sensation; 6 (20%) had signs of intracranial hypertension; 4 (13.3%) had dysphagia; and 2 (6.7%) had tinnitus. Radiographic signs of hydrocephalus were observed in 17 patients (56.7%): 16 (53.3%) had obstructive hydrocephalus; 1 (3.3%) had communicated hydrocephalus. Five patients (16.7%) had ventriculoperitoneal shunts inserted previously at another institute. After surgery, 10 patients (33.3%) had improvement in hydrocephalus, only 2 patients (6.7%) had undergone postoperative shunt placement.

#### Group B

Patients' mean age was 55.2 years (range 30–72 years) (Fig 1C), 14 patients (77.8%) were female. The left side was involved in 5 cases (27.8%) and the right side in 13 (72.2%). The mean duration of symptoms was 18.3 months (range 1–108 months), and the mean tumor size was 1.5 cm (range 0.6–2.4 cm) (Table 1). Preoperative imaging showed solid VS in every cases. All patients had hearing dysfunction; 4 (22.2%) had tinnitus; 2 (11.1%) had decreased facial sensation; 1 (5.6%) had gait ataxia; but no patient had signs of intracranial hypertension or dysphagia. Radiological evidence of hydrocephalus was found in 1 case (5.6%). None of these patients had undergone preoperative or postoperative ventriculoperitoneal shunt placement.

Statistical analysis revealed significant differences in the 2

groups in terms of gait ataxia, facial paresthesia, radiographic signs of hydrocephalus (Table 1).

### Facial nerve outcomes and surgical complications

#### Group A

HB grade I–III (good) was found in 9 patients (30%) at 1 month and 12 patients (40%) at 1 year follow-up, and HB grade IV–VI (poor) was observed in 21 (70%) at 1 month and 18 (60%) at 1 year follow-up (Table 2). Comparing facial nerve outcome at 1 year between GTR/NTR and STR showed HB grade I–III (good) in 7 patients (46.7%) in GTR/NTR group and 5 patients (33.3%) in STR group, HB grade IV–VI (poor) was found in 8 (53.3%) and 10 (66.7%) in GTR/NTR group and STR group, respectively (Table 3). Two patients (6.7%) were discovered to have postoperative hematoma on immediate postoperative CT scan and were reoperated on with craniectomy

and clot removal. Two patients (6.7%) developed CSF leaks, and one developed meningitis and epidural abscess. Both patients underwent further surgery repaired with fat graft (Table 4).

**Table 1.** Clinical presentation and imaging data (n=48)

Variables	Group A (n=30)	Group B (n=18)	p value
Tumor size (cm), mean±SD	3.8±0.58	1.5±0.53	
Tinnitus	2 (6.7)	4 (22.2)	0.179
Facial paresthesia	15 (50)	2 (11.1)	0.006*
Hearing loss	29 (96.7)	18 (100)	1.000
Dysphagia	4 (13.3)	0 (0)	0.282
Gait ataxia	20 (66.7)	1 (5.6)	<0.001*
Intracranial hypertension	6 (20)	0 (0)	0.071
Radiographic signs of hydrocephalus	17 (56.7)	1 (5.6)	0.002*

Data are presented as n (%) unless otherwise indicated. \* $p < 0.05$  according to the Pearson chi-square and Fisher's exact test

**Table 2.** Facial nerve outcomes at 1 month and 1 year according to HB grade

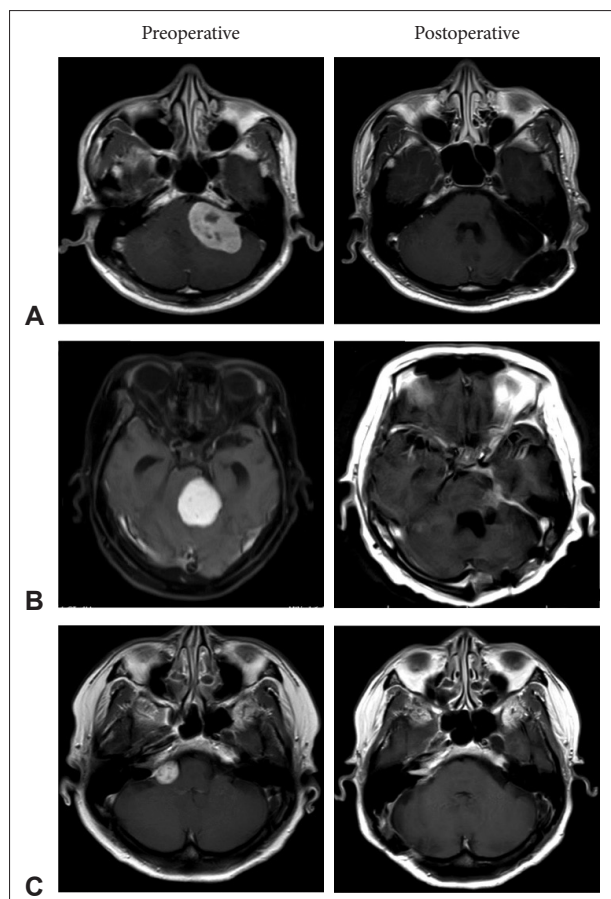
HB grade	Group A (n=30)	Group B (n=18)	p value
At 1 month			
I–III (good)	9 (30)	15 (83.3)	
IV–VI (poor)	21 (70)	3 (16.7)	<0.001*
At 1 year			
I–III (good)	12 (40)	17 (94.4)	
I	7 (23.3)	13 (72.2)	
II	2 (6.7)	3 (16.6)	
III	3 (10)	1 (5.6)	
IV–VI (poor)	18 (60)	1 (5.6)	<0.001*
IV	10 (33.3)	1 (5.6)	
V & VI	8 (26.7)	0 (0)	

Patients with preoperative facial nerve palsy were excluded. Data are presented as n (%). \* $p < 0.05$  according to the Pearson chi-square and Fisher's exact test. HB grade, House-Brackmann facial grading scale

**Table 3.** Facial nerve outcome 1 year in patients with VS  $\geq 3$  cm after GTR/NTR and STR

HB grade	GTR/NTR (n=15)	STR (n=15)	p value
I–III (good)	7 (46.7)	5 (33.3)	
I	5 (33.3)	2 (13.3)	
II	1 (6.7)	1 (6.7)	
III	1 (6.7)	2 (13.3)	
IV–VI (poor)	8 (53.3)	10 (66.7)	0.46
IV	4 (26.7)	6 (40)	
V & VI	4 (26.7)	4 (26.7)	

Data are presented as n (%). GTR, gross total resection; NTR, near total resection; STR, subtotal resection; HB grade, House-Brackmann facial grading scale



**Fig. 1.** Contrast-enhanced T1-weighted MR images showing surgically treated vestibular schwannomas patient in Group A (size  $\geq 3$  cm) and Group B (size  $< 3$  cm). A: Images obtained from a patient with size  $\geq 3$  cm who underwent total resection. B: Images obtained from a patient with size  $\geq 3$  cm who had subtotal resection. C: Images obtained from a patient with size  $< 3$  cm who underwent near total resection.

**Table 4.** New neurological deficits and surgical complication rates

	Group A (n=30)	Group B (n=18)
Blood collections	2 (6.7)	0 (0)
Cerebrospinal fluid leakage	2 (6.7)	1 (5.6)
Meningitis	1 (3.3)	0 (0)
Cerebral venous sinus thrombosis	0 (0)	1 (5.6)

Data are presented as n (%).

### Group B

HB grade I–III (good) was found in 15 patients (83.3%) at 1 month and 17 patients (94.4%) at 1 year follow-up, while the remaining 3 (16.7%) and 1 (5.6%) had HB grade IV–VI (poor) at 1 month and 1 year follow-up, as shown in Table 2. One patient (5.6%) developed CSF leaks that required surgical repair, and one person (5.6%) developed sagittal sinus thrombosis on postoperative day 5; this was treated with an oral anticoagulant (Table 4). The perioperative mortality rate in both groups was 0%.

Statistical analysis showed that there were significant differences between the two groups in terms of facial nerve outcomes 1 month and 1 year (Tables 2, 3, and 4).

## DISCUSSION

The incidence of large and giant tumors among all cases of VS has been estimated to be 14% in Western countries [5], but in developing countries they may comprise the majority [10]. Patients most typically present with hearing loss and tinnitus, which occur in 95% and >60% of cases, respectively [11]. Clinical presentations of patients with large VS differ from those of people with smaller tumors. According to the literature reviewed, patients with large VS tended to present with gait instability from compressive effects on the middle cerebellar peduncle in 64%–88% of cases, facial paresthesia from trigeminal nerve dysfunction in 34%–78% of cases, and dysphagia from lower cranial nerve dysfunction in 10%–14% of patients [10,12,13]. Since we carried out our research in a tertiary care hospital, we found large VS in 62.5% of all treated cases. Presenting symptoms included gait imbalance at 66.7%, facial paresthesia at 50%, and intracranial hypertension at 20%; these findings were consistent with those of other studies [10,12,13].

The main factor influencing postoperative facial nerve function was tumor size [11,14]. The risk of facial nerve dysfunction in patients with VS >3 cm is 6-fold greater than in those with smaller VS [14]. Many studies have revealed rates of preservation of function of facial nerve after removal in large size of VS varying between 42% and 84% [12,15–17]. In other research, facial weakness after surgery was found to result in lower quality of life scores [18,19]. Some studies have revealed

contrasting long-term tumor control outcomes in terms of GTR and STR. The strongest predictor of recurrence was type of resection, patients undergoing STR having a nearly 11-fold greater risk of recurrence than those treated with GTR [20].

In this study, we analyzed facial nerve outcomes at 1-month and 1-year follow up and divided the results into good (HB grade I–III) and poor (HB grade IV–VI) outcomes. There were 30% and 40% of patients with large VS had good facial nerve outcomes at 1 month and 1 year follow-up in contrast with their counterparts with small to medium tumors, who had good facial nerve results. Regarding in different resection type (GTR/NTR and STR), there were no significant difference in facial nerve outcome statistically. Since the primary goal of surgery in our center is to attempt complete surgical removal of all tumors, large tumor size (mean tumor size in Group A about 3.8 cm) and we do not routinely use continuous facial nerve monitoring, we have achieved lower rates of preservation of facial nerve function than those found in some other studies. Radiosurgery is not our first option for VS treatment because there are very limited resources available and cost is also cannot be reimbursed. Therefore microsurgical resection is the first option of treatment in Thailand. With regard to primary treatment for radiosurgery in large size VS (2–4 cm), some studies have shown good tumor control rates, ranging from 87.0%–90.5%, and also acceptable preservation of neurological function [21–23], even though there have been some cases of treatment failure. To obtain good tumor control and facial nerve function preservation, a combination of STR and postoperative radiosurgery might be a superior treatment option for large VS [24,25] and may also result in good quality of life [25].

In the present study, there were no cases of postoperative mortality and no significant neurological complications. Two patients had postoperative hematoma that required surgery; one developed hemiparesis and the other had no neurological deficit. One case developed CSF leakage and, subsequently, epidural abscess.







There were some limitations to this study. Firstly, we did not collect data regarding recurrence or regrowth of tumors. Secondly, it was a retrospective study with data collection only from medical records.

In conclusion, patients with large-sized VS ( $\geq 3$  cm) microsurgical resection had significantly poorer facial nerve outcomes than those who had VS <3 cm. As an alternative treatment for large VS, planned STR with postoperative radiosurgery might be superior in terms of neurological outcomes and may result in better quality of life in cases of large VS.

### Availability of Data and Material

The datasets generated or analyzed during the study are available from the corresponding author on reasonable request.

## ORCID iDs

Sujin Rujimethapass  <https://orcid.org/0000-0003-2538-1009>  
 Anant Ananthanandorn  <https://orcid.org/0000-0002-1444-0520>  
 Krissanee Karnchanapandh  <https://orcid.org/0000-0002-6869-1675>  
 Mathee Wongsirisuwan  <https://orcid.org/0000-0003-2323-2149>  
 Ittipon Gunnarat  <https://orcid.org/0000-0002-3852-0197>  
 Noppatee Segkhaphant  <https://orcid.org/0000-0002-2102-3063>

## Author Contributions

Conceptualization: Sujin Rujimethapass. Data curation: Sujin Rujimethapass. Formal analysis: Sujin Rujimethapass. Investigation: Sujin Rujimethapass. Methodology: Sujin Rujimethapass. Project administration: Sujin Rujimethapass. Resources: all authors. Software: all authors. Supervision: Sujin Rujimethapass. Validation: all authors. Visualization: all authors. Writing—original draft: Sujin Rujimethapass. Writing—review & editing: Sujin Rujimethapass.

## Conflicts of Interest

The authors have no potential conflicts of interest to disclose.

## Funding Statement

None

## REFERENCES

1. Delong M, Kirkpatrick J, Cummings T, Adamson DC. Vestibular schwannomas: lessons for the neurosurgeon: part II: molecular biology and histology. *Contemp Neurosurg* 2011;33:1-3.
2. Gal TJ, Shinn J, Huang B. Current epidemiology and management trends in acoustic neuroma. *Otolaryngol Head Neck Surg* 2010;142:677-81.
3. Propp JM, McCarthy BJ, Davis FG, Preston-Martin S. Descriptive epidemiology of vestibular schwannomas. *Neuro Oncol* 2006;8:1-11.
4. Stangerup SE, Tos M, Thomsen J, Caye-Thomasen P. True incidence of vestibular schwannoma? *Neurosurgery* 2010;67:1335-40.
5. Tos M, Stangerup SE, Caye-Thomasen P, Tos T, Thomsen J. What is the real incidence of vestibular schwannoma? *Arch Otolaryngol Head Neck Surg* 2004;130:216-20.
6. Chen Z, Prasad SC, Di Lella F, Medina M, Piccirillo E, Taibah A, et al. The behavior of residual tumors and facial nerve outcomes after incomplete excision of vestibular schwannomas. *J Neurosurg* 2014;120:1278-87.
7. Nair S, Baldawa SS, Gopalakrishnan CV, Menon G, Vikas V, Sudhir JB. Surgical outcome in cystic vestibular schwannomas. *Asian J Neurosurg* 2016;11:219-25.
8. Anderson DE, Leonetti J, Wind JJ, Cribari D, Fahey K. Resection of large vestibular schwannomas: facial nerve preservation in the context of surgical approach and patient-assessed outcome. *J Neurosurg* 2005;102:643-9.
9. Pollock BE, Driscoll CL, Foote RL, Link MJ, Gorman DA, Bauch CD, et al. Patient outcomes after vestibular schwannoma management: a prospective comparison of microsurgical resection and stereotactic radiosurgery. *Neurosurgery* 2006;59:77-85.
10. Jain VK, Mehrotra N, Sahu RN, Behari S, Banerji D, Chhabra DK. Surgery of vestibular schwannomas: an institutional experience. *Neurol India* 2005;53:41-5; discussion 45.
11. Samii M, Matthies C. Management of 1000 vestibular schwannomas (acoustic neuromas): the facial nerve—preservation and restitution of function. *Neurosurgery* 1997;40:684-94; discussion 694-5.
12. Yamakami I, Uchino Y, Kobayashi E, Yamaura A, Oka N. Removal of large acoustic neurinomas (vestibular schwannomas) by the retrosigmoid approach with no mortality and minimal morbidity. *J Neurol Neurosurg Psychiatry* 2004;75:453-8.
13. Samii M, Gerganov VM, Samii A. Functional outcome after complete surgical removal of giant vestibular schwannomas. *J Neurosurg* 2010;112:860-7.
14. Wiet RJ, Mamikoglu B, Odom L, Hoistad DL. Long-term results of the first 500 cases of acoustic neuroma surgery. *Otolaryngol Head Neck Surg* 2001;124:645-51.
15. Lanman TH, Brackmann DE, Hitselberger WE, Subin B. Report of 190 consecutive cases of large acoustic tumors (vestibular schwannoma) removed via the translabyrinthine approach. *J Neurosurg* 1999;90:617-23.
16. Sluyter S, Graamans K, Tulleken CA, Van Veelen CW. Analysis of the results obtained in 120 patients with large acoustic neuromas surgically treated via the translabyrinthine-transtentorial approach. *J Neurosurg* 2001;94:61-6.
17. Mamikoglu B, Wiet RJ, Esquivel CR. Translabyrinthine approach for the management of large and giant vestibular schwannomas. *Otol Neurotol* 2002;23:224-7.
18. Lee J, Fung K, Lownie SP, Parnes LS. Assessing impairment and disability of facial paralysis in patients with vestibular schwannoma. *Arch Otolaryngol Head Neck Surg* 2007;133:56-60.
19. Magliulo G, Zardo F, Damico R, Varacalli S, Forino M. Acoustic neuroma: postoperative quality of life. *J Otolaryngol* 2000;29:344-7.
20. Nakatomi H, Jacob JT, Carlson ML, Tanaka S, Tanaka M, Saito N, et al. Long-term risk of recurrence and regrowth after gross-total and subtotal resection of sporadic vestibular schwannoma. *J Neurosurg* 2017;19:1-7.
21. Chung WY, Pan DH, Lee CC, Wu HM, Liu KD, Yen YS, et al. Large vestibular schwannomas treated by Gamma Knife surgery: long-term outcomes. *J Neurosurg* 2010;113 Suppl:112-21.
22. Yang HC, Kano H, Awan NR, Lunsford LD, Niranjan A, Flickinger JC, et al. Gamma Knife radiosurgery for larger-volume vestibular schwannomas. *J Neurosurg* 2011;114:801-7.
23. van de Langenberg R, Hanssens PE, Verheul JB, van Overbeeke JJ, Nellemans PJ, Dohmen AJ, et al. Management of large vestibular schwannoma. Part II. Primary Gamma Knife surgery: radiological and clinical aspects. *J Neurosurg* 2011;115:885-93.
24. van de Langenberg R, Hanssens PE, van Overbeeke JJ, Verheul JB, Nellemans PJ, de Bondt BJ, et al. Management of large vestibular schwannoma. Part I. Planned subtotal resection followed by Gamma Knife surgery: radiological and clinical aspects. *J Neurosurg* 2011;115:875-84.
25. Pan HC, Sheehan J, Sheu ML, Chiu WT, Yang DY. Intracapsular decompression or radical resection followed by Gamma Knife surgery for patients harboring a large vestibular schwannoma. *J Neurosurg* 2012;117 Suppl:69-77.