

Tooth decalcification: A correlation between weight loss in a decalcified tooth with different decalcifying agents

Mohammad Imran Khan^{*}, Abhisheik Khare, Sameera Shamim khan, Anupama Mahendra, Abdullah Nasir, Arshad Khan

Career Post Graduate Institute of Dental Sciences and Hospital, Ghaila, IIM Road, Lucknow, UP, India

ARTICLE INFO

Keywords:

Tooth decalcification
10%EDTA
Nitric acid
Von Ebner's solution

ABSTRACT

The histopathological examination of mineralized tissues requires decalcification of teeth which is an essential and important step during tissue processing. In the present study we attempted to decalcify teeth using strong and weak acids and a chelating agent with various methods to identify completion of decalcification along with the observance of weight loss percentage of a tooth.

Aim: To compare decalcification with conventional decalcification method with strong acid, weak acids and a chelating agent with respect to preservation of tissue structure, efficacy of staining in association with weight change.

Materials and methods: A total of 64 multi-rooted and single rooted teeth were used, with group of 16 teeth, (16 molars, 16 pre-molars, 16 canines and 16 incisors) for each of the solution as Chelating agent (10% EDTA), Strong acid(10%HNO₃), Weak acid (5% Tri Carboxylic acid) and Von Ebner's solution (hydrochloric acid & sodium chloride), were used in the study respectively. The efficacy of decalcifying agents was evaluated by recording the time taken by particular acid to decalcify the tooth completely and the weight change was observed at set intervals till the completion of decalcification. The endpoint of decalcification was also confirmed with radiographic and chemical methods. The decalcified teeth were then routinely processed, sectioned, and stained with haematoxylin and eosin stains. Different methods were used to confirm the completion of decalcification. After decalcification, all the teeth were examined macroscopically and microscopically.

Results: At 70–80% of weight change of a tooth decalcification is complete. 10% EDTA was best suited to the soft and hard tissues in comparison to other solutions. 5% TCA was fair in staining quality and maintenance of hard tissue structures was satisfactory to 10%HNO₃ and Von Ebner's solution.

Conclusion: The final impression led to the proposition that EDTA was indeed the best decalcifying agent available if the results required are not urgent. For situations where time constraint is there, 5% Tri Carboxylic Acid can be used.

1. Introduction

Demineralization is a rapidly growing and challenging aspect of various scientific disciplines specially for forensic odontology and also for histopathological evaluation of the cellular structures of the teeth. The technique involved in decalcification must preserve the hard tissue structures and the dental soft tissue structures as close as to in living state.^{1–3}

For histological observations of the pulp, enamel, dentin and cementum, require the removal of the mineral component from the

dentin and cementum. Dental pulp evaluation is often a part of research to study the effect of restorative materials on dental pulp and its biological response to new restorative materials. Examination of demineralized sections of other dental tissues and bone is required to study various pathological changes and developmental processes and stages. Also, various other soft tissues may get calcified and need decalcification following changes due to dystrophic and metastatic processes. In all these cases, the histopathologist is required to provide hard tissue biopsy reports after the process of decalcification.⁴

The routine procedure to obtain sections for microscopic observation

^{*} Corresponding author.

E-mail addresses: imranplz@yahoo.co.in (M.I. Khan), dr_abhi_khare@yahoo.co.in (A. Khare), sameerashamim@yahoo.com (S. Shamim khan), khare888anupama@gmail.com (A. Mahendra), anasir5bds@gmail.com (A. Nasir), hepcatkhan@gmail.com (A. Khan).

<https://doi.org/10.1016/j.jobcr.2022.08.029>

Received 5 August 2022; Received in revised form 25 August 2022; Accepted 29 August 2022

Available online 5 September 2022

2212-4268/© 2022 Craniofacial Research Foundation. Published by Elsevier B.V. This is an open access article under the CC BY-NC-ND license (<http://creativecommons.org/licenses/by-nc-nd/4.0/>).

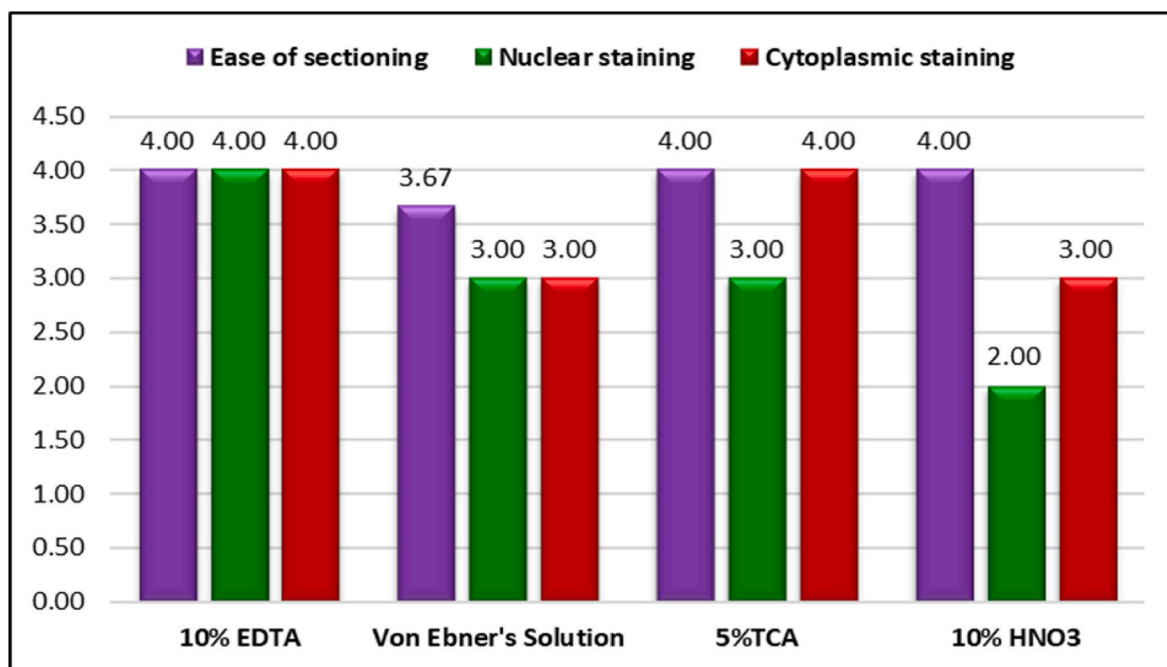


Fig. 1. Bar diagram representing overall Comparison of Various Staining at decalcification 70–80%.

from a calcified tooth or bone is to demineralize the hard tissues with acids or chelating agents, with care that only calcium salts are extracted and soft and hard tissue integral structures are preserved.

In a routine, radiographic, chemical or physical methods are used to evaluate the completion of decalcification.⁵ We have tried to achieve an end point by observing weight changes in a tooth.

2. Objectives

1. To establish correlation between complete decalcification and weight change by observing the weight change during decalcification.
2. To determine ideal decalcification technique.
3. To study and compare the effect of various decalcifying agents on hard and soft tissue of the tooth.
4. To assess the best decalcification agent.

3. Materials and method

The study was conducted in the Department of Oral and Maxillofacial Pathology. Freshly extracted, non-carious, non-atruded 64 human permanent teeth including, 16 of each incisor, canine, premolar and molar were collected for the study.

The teeth were fixed in formalin for a day, after that they were kept in different decalcifying solutions. Four chemical agents were used in our study, Strong acid (10% HNO₃), Chelating agent (10% EDTA), Weak Acid (5% TCA) and Von Ebner's solution.

Demineralization of the teeth was carried out at room temperature and teeth were completely submerged in about 200ml of the solution. The solution for strong acid (10% HNO₃) and 5% TCA was replaced every 24hr with freshly prepared solution.⁶ EDTA solution and Von Ebner's solution was replaced after every 5 days.⁷

The status of decalcification was evaluated with weight change, followed by chemical and radiographic confirmation method. Periodic weight loss was weighed and weight loss percentage was calculated and tooth were sectioned, stained and examined under microscope for evaluation at each set interval of weight loss. In our study four sets of teeth were evaluated for given percentage change in weight. We observed and recorded weight change at 40–50%, 50–60%, 60–70% and

70–80%.

For chemical method we used calcium oxalate test. With this method the detection of calcium in acid solutions is observed by precipitation of insoluble calcium hydroxide or calcium oxalate.⁶ End point was also assessed radiographically with an RVG for confirmation.

The specimens were processed by routine tissue processing, sectioning and staining was done with haematoxylin and eosin. The stained sections were observed under microscope and were graded from 1–4. [1–Poor, 2–Fair, 3–Good, 4–Excellent] on the following criteria.

1. Ease of sectioning
2. Cytoplasmic staining
3. Nuclear staining

results: It was observed as teeth were subjected to histological examination under microscope on the selected criteria at different percentage of weight loss (ex. 40–50%, 50–60%, 60–70% and 70–80%) best results were obtained histologically at 70–80% of weight change of a tooth and significant statistical differences observed among different solutions for soft tissue integrity leading to EDTA as best decalcifying agent. (Table 1 and Fig. 1).

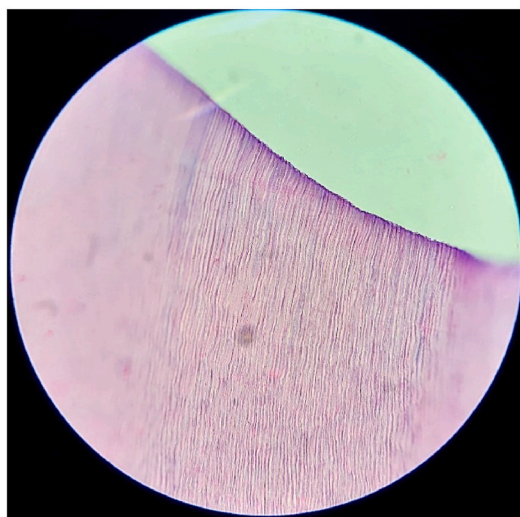
4. Discussion

Decalcification is commonly used technique in most of the histopathology laboratories for microscopic examination of calcified or mineralized tissues including teeth and bones.⁸ The decalcification of teeth is done to study the tooth structure, pulp calcifications, and also to understand the biological response of dental pulp to restorative materials.

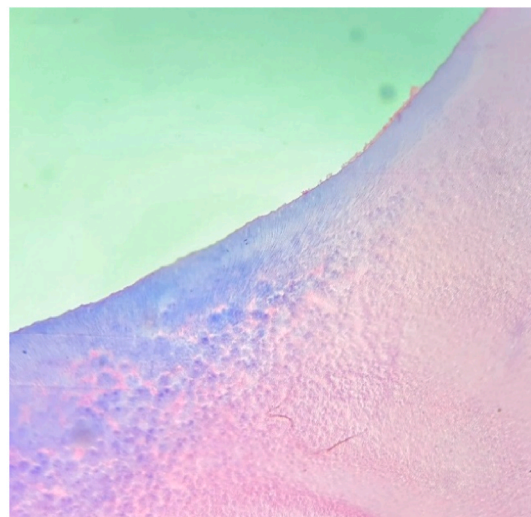
A good decalcifying agent must make certain complete calcium removal at a reasonable speed with minimal damage to cellular structures and tissues.

The selection of decalcifying agents depends on multiple factors such as time limit of case, mineralization stage, aim of research as well as what staining technique is being used. The decalcifying agents must maintain the balance between rapid decalcification and preservation of structural morphology.

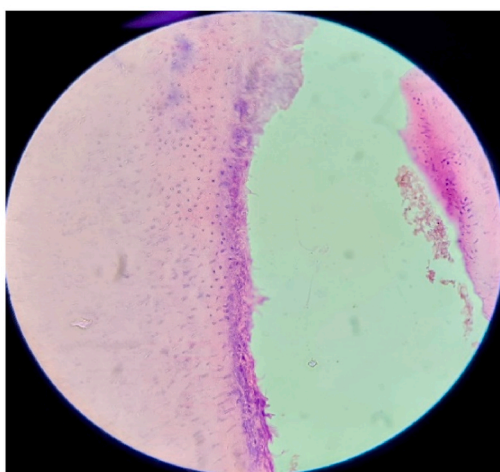
Many researchers carried out multiple studies to introduce new



(a)



(b)



(c)

Fig. 2. (a) H&E stained section decalcified with EDTA (b) H&E stained section decalcified with TCA. (c) H&E stained section of soft tissue after decalcification with EDTA.

Table 1
Overall Comparison of Various Staining at decalcification 70–80%.

Material	Decalcification 70–80%					
	Ease of sectioning		Nuclear staining		Cytoplasmic staining	
	Mean	SD	Mean	SD	Mean	SD
10% EDTA	4.00	0.00	4.00	0.00	4.00	0.00
Von Ebner's Solution	3.67	0.58	3.00	0.00	3.00	0.00
5%TCA	4.00	0.00	3.00	0.00	4.00	0.00
10% HNO3	4.00	0.00	2.00	0.00	3.00	0.00
Intergroup (Kruskal Wallis test)	chi sq = 3.00, p = 0.392		chi sq = 11.00, p=0.012		chi sq = 11.00, p=0.012	

decalcifying agents and to modify the presently used agents and tried to full fill the criteria of the most efficient chemical agent which completely extracts calcium without causing any structural damage to tissue morphology and provide good staining characteristics.⁹

Use of a decalcifying agent without strict observance specially with strong acids can often lead to tissue damage, usually characterized by maceration of soft tissue and the loss of cytoplasmic and nucleic staining.

A number of tests including physical testing by pressure or bending to detect hardness, mechanical testing by pricking, chemical method (chemical detection of calcium salts in the decalcification solution, bubble tests and radiographic evaluation of calcium in the subjected specimen) are used to test the completion of decalcification.

It has been observed that disadvantages such as generation of artefacts, destruction of cellular and structural details and false-positive interpretations came across while using physical and chemical tests.

Table 2

As per the Descriptive Table, for soft and hard tissue scoring: cytoplasmic staining, 10% EDTA solution has maximum impact followed by 5% TCA on soft and hard tissue scoring.

Descriptive		N	Mean	Std. Deviation	Std. Error	95% Confidence Interval for Mean		Minimum	Maximum
						Lower Bound	Upper Bound		
Tissue Ease of Sectioning	10% EDTA	4	3.75	.500	.250	2.95	4.55	3	4
	10% HNO ₃	4	4.00	.000	.000	4.00	4.00	4	4
	Von-Ebner's Sol	4	3.50	.577	.289	2.58	4.42	3	4
	5% TCA	4	4.00	.000	.000	4.00	4.00	4	4
	Total	16	3.81	.403	.101	3.60	4.03	3	4
Tissue Nuclear Staining	10% EDTA	4	4.00	.000	.000	4.00	4.00	4	4
	10% HNO ₃	4	2.00	.000	.000	2.00	2.00	2	2
	Von-Ebner's Sol	4	3.00	.000	.000	3.00	3.00	3	3
	5% TCA	4	3.00	.000	.000	3.00	3.00	3	3
	Total	16	3.00	.730	.183	2.61	3.39	2	4
Tissue Cytoplasmic Staining	10% EDTA	4	4.00	.000	.000	4.00	4.00	4	4
	10% HNO ₃	4	2.75	.500	.250	1.95	3.55	2	3
	Von-Ebner's Sol	4	3.00	.000	.000	3.00	3.00	3	3
	5% TCA	4	3.75	.500	.250	2.95	4.55	3	4
	Total	16	3.38	.619	.155	3.05	3.70	2	4

To achieve quick results with decalcification of calcified tissues many histopathologists intend to use mineral acids for decalcification but the control at intervals is difficult to achieve accurately with the chemical tests and is expensive with radiographs. A simple, economical, and an accurate method of controlling acid decalcification is to measure the weight change of the tissue as it is demineralized.¹⁰

In the present study we attempted to conclude that at certain percentage of weight loss of the tooth being decalcified, decalcification is complete and is confirmed histologically with, ease of sectioning, hard-tissue staining, soft-tissue staining and pulpal organization. We have also tried to establish END point of decalcification using weighing method with different types of decalcifying agents.

The time taken for decalcification with 10% HNO₃ was 5 days and 3 h (123 h), 5% TCA was 10 days (240 h), Von Ebner's solution took 28 days (672 h) 10% EDTA it took 3 months 2 days and 4 h: 91 days (2188 h) concluding that 10% took least of time and decalcification with EDTA was longest for achieving 70–80% weight loss.

In our study we concluded, acids like nitric acid, cause more tissue damage and interfere with staining, due to formation of urea as it gives the yellow discoloration to the demineralized tooth sections for histological observance.¹¹ Due to acid exposure, strong acids as HNO₃ causing significant tissue damage because of protein hydrolysis results in poor nuclear staining with positively charged dyes such as haematoxylin and cytoplasm overstains by the briefest exposure to negatively charged dyes like Eosin. This effect has important clinical significance as these under stained nuclei may be falsely transliterated as of no importance.⁴

The weak organic acids like Tri-carboxylic acid are slow in action and are more tissue compatible causing lesser structural and morphological damage.¹² (Fig. 2: b)

Among the different solutions we found EDTA as the best solution for decalcification if time is not a factor and it gave best histological results for hard and soft tissue staining (Fig. 2: a,c), preserving overall tissue integrity and cellular structures were well appreciated microscopically (Table 2).

The comprehensive best results were obtained with neutral EDTA are because of the process of capturing metallic ions like calcium which attaches to the chelating agent. By this mechanism the calcium ions from the external layer of the apatite crystals are removed. When whole of the calcium ions from the outer layer are removed, they get replaced by ions from the deeper layers. In this way, the size of crystal decreases gently, eventually presenting an excellent preservation of tissue components.^{13–15}

We observed gradual changes in weight of the teeth kept in solution for decalcification and observed that at approx.70–80% of weight

change decalcification can said to be complete, confirmed radiographically and achieved best histopathological results for hard and soft tissue staining.

On radiographs we observed significant changes in loss of radio opacity gradually, radiographs were taken with an RVG every 24 h for acid decalcifier, and every 5 days for chelating solution.

In our study we have taken different types of teeth such as incisors, premolars and molars. We concluded that shape and size of the tooth has no co-relation with weight loss and histological impression. We concluded that at 70–80% of weight change of a tooth decalcification process is complete and going beyond this percentage of weight change and continuing the decalcification process it destroys the structural organization of the tooth. We also can comment that radiographs are the other good method to observe completion of decalcification. If we want to avoid radiographs to confirm completion of decalcification, weight change observation is another simple and equivalent method to radiographs, which can be carried out to assess completion of decalcification without physically distorting the tooth structure as with needling or bending the tooth.

Acknowledgement

The authors wish to acknowledge the support extended by the Chairman, Azmat Ali, Vice Chairman, Dr Iqbal Ali, Career Post Graduate Institute of Dental Sciences and Hospital, Professors and Readers, Dept of Oral Pathology and Microbiology, Principal, Career Post Graduate Institute of Dental Sciences and Hospital, Lucknow and whole of the management of the college. Special thanks to Dr Masood Siddiqui for helping us to formulate and present our study in statistical format.

References

- 1 Ali Sheeba, Bansal Pujja, Bhargava Deepak, et al. Evaluating the efficacy of two decalcifying agents on hard and soft tissues of human permanent teeth. *J Evolution Med Dent*. 2021. Sci/eISSN - 2278-4802, pISSN - 2278-4748/Vol. 10/Issue 31/Aug. 02.
- 2 Zappa J, Cieřlik–Bielecka A, Adwent M, et al. Comparison of different decalcification methods to hard teeth tissues morphological analysis. *Dent Med Probl*. 2005;42(1): 21–26.
- 3 Keklikoglu N, Akinci S. Comparison of three different techniques for histological tooth preparation. *Folia Histochem Cytobiol*. 2013;51(4):286–291.
- 4 Prasad Prathibha, Donoghue Mandana. A comparative study of various decalcification techniques. *Indian J Dent Res*. 2013;24(3).
- 5 Choube A, Astekar M, Choube A, Sapra G, Agarwal A, Rana A. Comparison of decalcifying agents and techniques for human dental tissues. *Biotech Histochem*. 2018;1–10. Early Online.
- 6 S. Kim Suvarna, Christopher Layton, John D: Bancroft's Theory and Practice of Histological Techniques. 7th edition, Page vol. 326,328.

- 7 Sanjai Karpagaselvi, Kumarswamy Jayalakshmi, Patil Archana, Papaiah Lokesh, Jayaram Srinivas, Krishnan Lakshmi. Evaluation and comparison of decalcification agents on the human teeth. *J Oral Maxillofac Pathol.* 2012;16. Issue 2 May - Aug.
- 8 Gupta Sonia, KaurJawanda Manveen, Manjunath SM. Achla bharti: qualitative histological evaluation of hard and soft tissue components of human permanent teeth using various decalcifying agents - a comparative study. *J Clin Diagn Res.* 2014 Sep;8(9):ZC69–ZC72.
- 9 Amberpreet Kaur Khangura, Gupta Shally, Gulati Anubha, Singh Simranjit. Tooth decalcification using different decalcifying agents – a comparative study. *J Oral Maxillofac Pathol.* 2021 Sep-Dec;25(3):463–469.
- 10 Whb Mawhinney, E Richardson, Aj Malcolm Department of Histopathology, Royal Victoria Infirmary. Newcastle upon Tyne: technical methods Control of rapid nitric acid decalcification. *J Clin Pathol.* 1984;37:1409–1415.
- 11 Bhardwaj Nandini, Puri Abhiney, Nangia Rajat, Dogra Alisha, Kaur Prabhpreet. Decalcification: an amenable process in oral histology. *Indian J Pharmaceut Biol Res.* 2021;9(4):1–5.
- 12 Sangeetha R, Uma K, Chandavarkar V. Comparison of routine decalcification methods with microwave decalcification of bone and teeth. *J Oral Maxillofac Pathol.* 2013;17(3):386–391.
- 13 Mattuella LG, Bento LW, Vier-Pelisser FV, Araiyo FB, Fossati AC. Comparative analysis of two fixating and two decalcifying solutions for processing of human primary teeth with inactive dentin carious lesion. *Rev Odonto Ciênci.* 2007;22:99–105.
- 14 Callis MG, Bancroft JD, Gamble M. *Theory and Practice of Histological Techniques.* sixth ed. Philadelphia: Churchill Livingstone; 2008:333–363.
- 15 Singh S, Sircar K. Evaluation of efficacy of various chemicals for decalcification of dental hard tissues - an in-vitro study. *J Orofac Sci.* 2010;1:5–10.