

# Perspective of nuclear fractal dimension in diagnosis and prognosis of oral squamous cell carcinoma

Juber Rahman<sup>1</sup>, Swagatika Panda<sup>1</sup>, Santisudha Panigrahi<sup>2</sup>, Neeta Mohanty<sup>1</sup>, Tripti Swarnkar<sup>2</sup>, Umashankar Mishra<sup>3</sup>

<sup>1</sup>Department of Oral Pathology and Microbiology, Institute of Dental Sciences, Siksha 'O' Anusandhan Deemed to be University, <sup>2</sup>Department of Computer Science and Engineering, Institute of Technical Education and Research, Siksha 'O' Anusandhan Deemed to be University, Bhubaneswar, Odisha, <sup>3</sup>Department of Management, School of Commerce and Management, Central university of Rajasthan, Ajmer, India

## Abstract

**Background:** Owing to the restricted predictive value of conventional prognostic factors and the inconsistent treatment strategies, several oral squamous cell carcinoma (OSCC) patients are still over-treated or under-treated. In recent years, computer-assisted nuclear fractal dimension (nFD) has emerged as an objective approach to predict the outcome of OSCC.

**Objective:** This study is an attempt to find out the differences in nFD values of epithelial cells of normal tissue, fibroepithelial hyperplasia, verrucous carcinoma, and OSCC. Further effort to evaluate the predictive potential of nFD of tumor cells for cervical lymph node metastasis (cLNM) was also assessed.

**Methodology:** Formalin-fixed paraffin-embedded blocks of OSCC tissues of patients treated with neck dissection were collected. Photomicrographs of H&E-stained sections were subjected to the image analysis by ImageJ and Python programming to calculate nFD. The association of categorical variables with nFD was studied using cross-tabulation procedure and the Fisher exact test. Receiver operating curve analysis was performed to find out cutoff value of nFD. A logistic regression model was developed to test the individual and combined predictive potential of grading and nFD for cLNM.

**Results:** A significant difference between the mean nFD of healthy cells and malignant epithelial cells was observed ( $P = 0.01$ ). nFD was not found to be an independent predictor of cLNM, although nFD and grading together demonstrated significant predictive potential ( $P = 0.004$ ).

**Conclusion:** nFD combined with grading can predict lymph node metastasis in OSCC. To the best of our knowledge, this is the first study of its kind.

**Keywords:** H&E staining, lymph node metastasis, nuclear fractal dimension, oral squamous cell carcinoma

**Address for correspondence:** Dr. Swagatika Panda, Department of Oral Pathology and Microbiology, Institute of Dental Sciences, Siksha 'O' Anusandhan Deemed to be University, Bhubaneswar - 751 003, Odisha, India.

E-mail: swagatikapanda@soa.ac.in

**Submitted:** 20-Nov-2020, **Accepted:** 24-Oct-2021, **Published:** 31-Mar-2022

### Access this article online

#### Quick Response Code:



#### Website:

www.jomfp.in

#### DOI:

10.4103/jomfp.jomfp\_470\_20

This is an open access journal, and articles are distributed under the terms of the Creative Commons Attribution-NonCommercial-ShareAlike 4.0 License, which allows others to remix, tweak, and build upon the work non-commercially, as long as appropriate credit is given and the new creations are licensed under the identical terms.

**For reprints contact:** WKHLRPMedknow\_reprints@wolterskluwer.com

**How to cite this article:** Rahman J, Panda S, Panigrahi S, Mohanty N, Swarnkar T, Mishra U. Perspective of nuclear fractal dimension in diagnosis and prognosis of oral squamous cell carcinoma. J Oral Maxillofac Pathol 2022;26:127.

## INTRODUCTION

Cancer of with head-and-neck region is the 6<sup>th</sup> most commonly occurring human cancer, comprising 3% of all types of cancer.<sup>[1]</sup> Oral carcinogenesis owing to the multifactorial etiologies consequentially results in multiple adverse outcomes which include cervical lymph node metastasis (cLNM), distant metastasis, recurrence, second primary tumor and increased mortality. The prediction of adverse outcomes in incision biopsy may facilitate appropriate individualized treatment strategies, thereby may decrease the mortality due to oral cancer. TNM staging, histopathologic grading system,<sup>[2-4]</sup> interactions between stroma and invasive tumor front,<sup>[5,6]</sup> lymphovascular invasion,<sup>[7,8]</sup> perineural infiltration,<sup>[8]</sup> and tumor thickness<sup>[9]</sup> are few explored prognostic factors. Histopathology remains the gold standard for the diagnosis as well as prognostication. However, pathologists diverge in the importance they give to particular histopathological features, and the interpretation varies from one pathologist to another. The wide subjective variation in evaluating the above-mentioned prognostic factors has always sought for the necessity of objective means of evaluation. The vast expansion of the scope of information technology over the past few decades along with an increase in the incidence of cancer has led to the diagnostic medicine amenable to automated computational technology. Computer-assisted morphometry of cell was suggested as an objective approach to correlate with the outcome of several malignancies, including oral squamous cell carcinoma (OSCC).<sup>[10-13]</sup> Early diagnosis and objective means of prognostication shall contribute to the prediction of outcomes of oral cancer as well as may lower the burden of pathologists following the traditional approaches.

Conventional morphometry depends upon Euclidean geometry which uses a single arbitrary measuring scale to analyze the reductive representation or unrealistic approximation of cellular and nuclear irregularities. However, to the great dismay, the uncontrolled growth in cancer leads to the irregular surface area, uneven contour length and other complex dimensional parameter making application of conventional morphometry unacceptable. This aspect necessitated the invention of fractal dimension, and its applicability in cancer which can measure the statistical intensity and distribution of irregularities present in the cell contour. A vast number of studies have claimed a probable link between cancer and fractals.<sup>[14-16]</sup> Mandelbrot stated that this could be grouped by index like the fractal dimension, which is defined as an analysis of the geometrical complexity and

the space-filling properties of a structure.<sup>[17]</sup> Nuclear fractal dimension (nFD) is the measure of fractal geometry of surface of nucleus. A three-step process including preprocessing the photomicrographs followed by extraction and analysis of relevant features such as fractal dimension, textural features and entropy has proven to diagnose and prognose cancer such as breast tumors, glioblastomas and pancreatic cancer,<sup>[18-20]</sup> with great success. However, prognostic potential of nFD in oral cancer has been studied by only five researchers out of which four studies associated nFD with disease-free survival (DFS) and one study assessed the potential of nFD in differentiating normal, dysplastic and malignant oral epithelial cells.<sup>[21-25]</sup> The objective of the present study was to evaluate potential of nFD in differentiating normal mucosa, fibroepithelial hyperplasia (FEH), verrucous carcinoma (VC), and OSCC as well as predicting cLNM in OSCC.

## METHODOLOGY

### Design and settings of the study

This is a retrospective cross-sectional study conducted on formalin-fixed paraffin-embedded (FFPE) blocks of tissues of patients undergone radical neck dissection for OSCC. After approval by the Institutional Ethical Committee, patient records were examined to isolate the FFPE blocks. The collection of archival blocks was conducted retrospectively from 2018 to 2017, and a total of 114 FFPE tissue blocks were included in the study. Thirty FFPE tissue blocks each of VC and FEH were also retrieved. Healthy tissues as control ( $n = 20$ ) were collected in that time period during the procedure of crown lengthening, operculectomy and impaction surgery. Patients undergoing treatment for a recurrent and metastatic tumor in the oral cavity were excluded. The clinicopathological characteristics of each patient such as demographic details, age, gender, site, habit, TNM staging, and histopathological grading were recorded.

All FFPE blocks were sectioned into 4  $\mu\text{m}$  thickness and stained with hematoxylin and eosin. Appropriate slides were selected based upon the review of a single experienced pathologist who confirmed the original diagnosis and level of cLNM. The slides were viewed under  $\times 1000$  magnifications of light microscope coupled with a digital camera having a resolution of  $1280 \times 1024$  (Lawrence and Mayo research microscope, USA). Photomicrographs were captured from ten randomly selected representative sites for each case and stored on the computer as high-quality JPEG files with  $4032 \times 3024$  pixels and 16.7 million colors (24-bit). Satisfactorily stained, well-defined, nonoverlapping nuclei of invaded epithelial cells with clear margins in OSCC were

selected for the study. Epithelial cells in the normal tissue were chosen from epithelium, whereas epithelial cells of FEH and VC were selected from pseudoepitheliomatous hyperplastic islands. The microscope and camera settings were kept consistent during the entire study process. The images were then subjected to the image analysis using two softwares (Python, Image J) to calculate nFDs.

### Fractal dimension analysis

Analysis of nFD was achieved in three steps with image preprocessing as the first step, followed by segmentation

and feature extraction. Color images were converted to binary images with simple thresholding suitable for fractal analysis. nFD of each image was estimated by implementing the widely used box-counting method of Minkowski-Bouligand dimension in two specially designed applications such as Python programming software with custom Python script (Delaware, United States) and Image J software1.43u with FracLac plugin java 1.6 (Wayne Rasband, National Institutes of Health, Bethesda, USA).

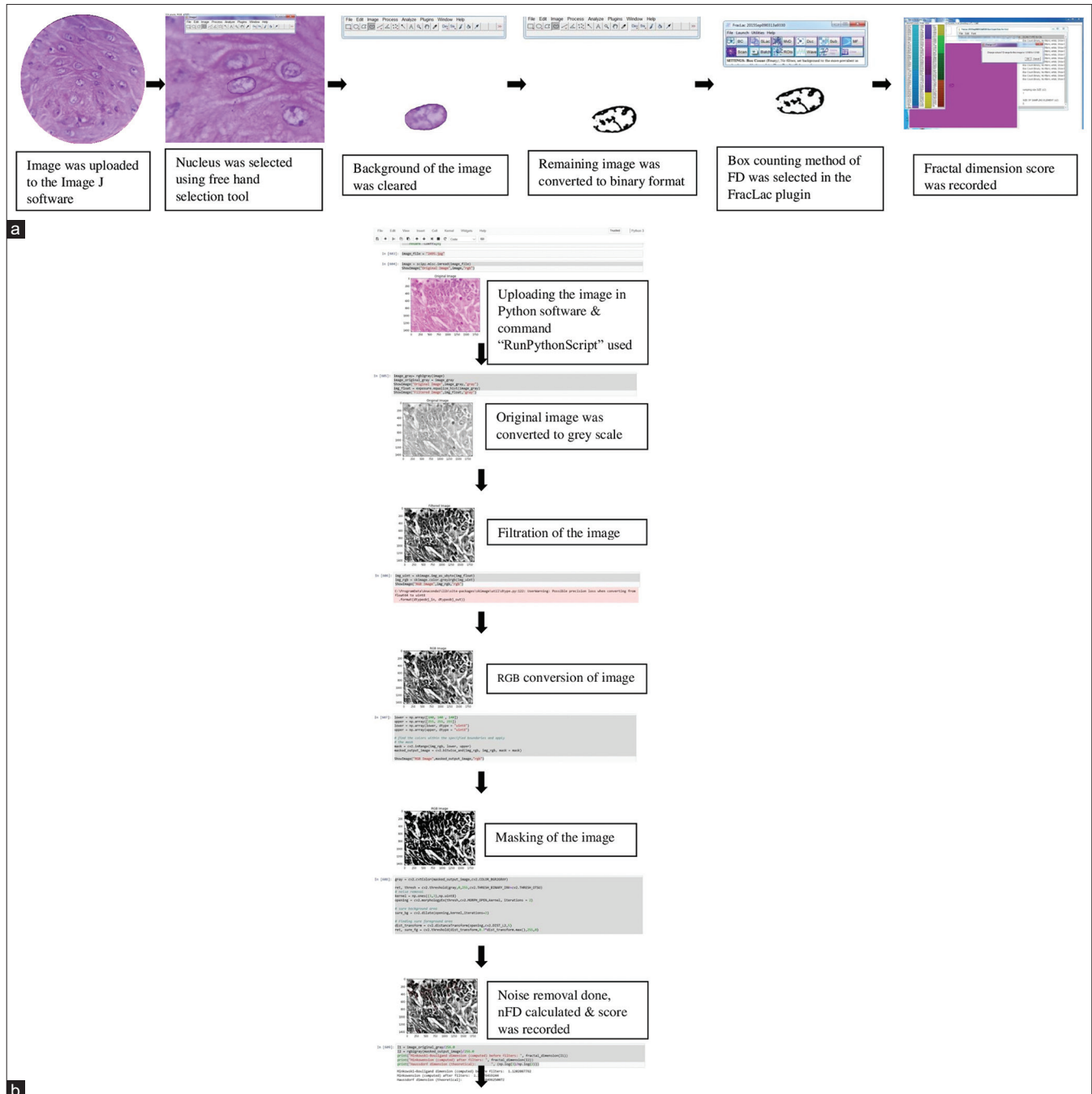


Figure 1: Step wise recording of fractal dimension of nucleus in Image J (a) and Python (b)

The selection of the nucleus was a manual procedure in Image J, whereas Python has extracted nFD through automatic image processing and feature extraction. Simple box count method was followed in both applications. Stepwise recording of nFD by both applications was presented in Figure 1a and b. According to this method, a grid with multiple small boxes of particular pixel length is superimposed on the digital image. Irregular image profiles were then automatically “boxed” by the software into an appropriate number of boxes which depends on the number of pixels in the image. This generates an output in the form of a regression line graph. The slope of the regression line equals to the fractal dimension of the object. It also depends on the number of intercepts of the surface with the boxes. A smoother surface will have fewer intercepts and therefore a lower fractal dimension value than a rougher surface. The software automatically estimates the fractal dimension using the box-counting algorithm that applies the equation:

$DF = \log N / \log \epsilon$  (where DF-Fractal dimension, N-number of pieces which the line can be broken into when using pieces of scale  $\epsilon$ ).

### Statistics

The data collected in the process of the study were analyzed using IBM SPSS 24.0 software (IBM SPSS Statistics for Windows, Version 24.0. Armonk, NY, USA: IBM Corp). *T*-test compared the efficacy of nFD in differentiating epithelial cells of normal tissue, tumor epithelial cells of OSCC and pseudoepitheliomatous hyperplastic islands in FEH and VC. The association of categorical variables such as age group, gender, site, tumor size and histopathological features with nFD was studied using cross-tabulation procedure, Fischer exact test and Chi-square test of independence. Receiver operating curve (ROC) analysis was performed using MEDCAL 17.9.7 software to find out cutoff value of nFD. Each point in the ROC curve represents a sensitivity and specificity pair corresponding to a particular decision threshold. A logistic regression model was developed to test the individual and combined predictive potential of histopathological grading and nFD for cLNM.

## OBSERVATION AND RESULTS

### Descriptive data

Descriptive data of the sample are presented in Table 1.

### Efficacy of nuclear fractal dimension in differentiating normal tissue, fibroepithelial hyperplasia, verrucous carcinoma and oral squamous cell carcinoma

Mean nFD of epithelial cells in normal tissue, FEH, VC and OSCC were found to be 1.46, 1.46, 1.45 and 1.56,

**Table 1: Demographic details of patients**

Parameters	Number of cases
Age (years)	
Below 40	17
Above 40	97
Gender	
Male	73
Female	41
Site	
GB sulcus	86
Buccal mucosa	1
Tongue	21
Palate	2
Retromolar	4
TNM staging	
Present	12
Absent	102
Lymph node	
Positive	42
Negative	72
Cervical lymph node metastasis	
Level 1	28
Level 2	12
Level 3	2
Negative	72
Histopathological grading	
Well differentiated	65
Moderately differentiated	48
Poorly differentiated	1
Total number of cases	114

TNM: Tumor node metastasis

respectively. Potential of nFD to differentiate OSCC from lesions mimicking malignancy was found to be significant ( $P < 0.03$ ).

### Association of age and histopathological grading with nuclear fractal dimension

Fisher's test showed that there was no significant association of either age (Image J:  $P = 0.122$ ; Python:  $P = 0.315$ ) or histopathological grading (image J:  $P = 0.903$ ; Python:  $P = 0.413$ ) with nFD in both the software.

### Efficacy of histopathological grading in predicting cervical lymph node metastasis

It was found that histopathological grading was significantly ( $P = 0.004$ ) correlated with cLNM.

### Efficacy of nuclear fractal dimension in predicting cervical lymph node metastasis

For determining the diagnostic efficacy, ROC analysis has been performed where nFD in both Image J and Python were plotted individually against cLNM. In Image J, Area Under ROC Curve (AUC) was  $0.493 \pm 0.055$  ( $P = 0.906$ ). The cutoff value was 1.492. The sensitivity was 72.0% with 95% confidence interval (CI) 38.5%–60.2%. The specificity was 46.5% with 95% CI (35%–57.6%). Sensitivity and specificity can be considered as high. In Python, the Area under ROC curve (AUC) was  $0.494 \pm 0.056$  ( $P = 0.920$ ). The cutoff value was 1.351.



The sensitivity 72% was with 95% CI 38.5%–60.2%. The specificity was. 597% with % CI 0.385%–0.604%. Sensitivity can be considered moderate and specificity as low. However, Fisher’s test showed that nFD was not significantly predicting nodal metastasis in either Image J ( $P = 0.220$ ) or Python ( $P = 0.297$ ). Cross tabulation is presented in Table 2.

**Combined efficacy of nuclear fractal dimension and grade in predicting cervical lymph node metastasis**

When the predictive potential of histopathological grading and nFD combined was tested in logistic regression, a significant effect was obtained in both Python [ $P = 0.004$ , Table 3] and ImageJ [ $P = 0.004$ , Table 4].

**DISCUSSION**

While nFD has been successfully used to diagnose and prognosticate several neoplasms, evidence in oral cancer is lacking.<sup>[18-20,26]</sup> Fractal dimension of the nucleus in oral cancer has been correlated with staging,<sup>[21,24]</sup> histopathological grading,<sup>[21,24]</sup> and survival.<sup>[21,24,25,27]</sup> Therefore, for the first time, this study has been conducted hypothesizing the correlation of nFD with cLNM. With a preliminary objective of identifying the potential of nFD to differentiate between epithelial cells of normal tissue, OSCC and oral lesions mimicking malignancy like VC and pseudoepitheliomatous hyperplasia, the present study was designed to evaluate the potential of nFD to predict

cLNM in oral cancer. The present study has resulted in a significant ( $P < 0.03$ ) potential of nFD in differentiating OSCC from normal as well as oral lesions mimicking malignancy like VC and FEH. Although differentiating potential of nFD between normal and tumor epithelial cells has been suggested by few studies,<sup>[22,23]</sup> there exists no study comparing nFD in OSCC and lesions mimicking malignancy. This study has resulted in a nonsignificant correlation of age and histopathological grading with nFD, which contradicts previous findings.<sup>[21,24]</sup> According to Yinti *et al.* and Mincione *et al.*, nFD was found to be progressively increased from well to poorly differentiated tumors.<sup>[21,24]</sup>

In oral cancer, there is a continuous search for clinicopathological indicators predicting clinical outcomes. Although there have been few studies attempted at associating nFD with DFS, TNM staging and grading there have been no studies conducted to prove the efficacy of nFD in predicting cLNM.<sup>[21,23-25]</sup> Therefore, with the further objective of understanding the potential of nFD to predict cLNM, we compared the nFD of two groups of OSCC patients with lymph node metastasis (N+) and without lymph node metastasis (N0). Measurement of nFD in this study was achieved by two software, Image J and Python to increase the validity of the hypothesis. A cutoff value of nFD as 1.49 in Image J, and 1.35 in Python was found out in ROC analysis. However, nFD was not found to influence cLNM as an independent prognostic factor significantly ( $P$  value in image J = 0.435 and Python = 0.549) in either of these applications. As is already established, our study has shown a significant association ( $P = 0.004$ ) of histological grading with cLNM.<sup>[28,29]</sup> We attempted developing a logistic regression model to test the combined influence of histopathological grading and nFD to predict cLNM. nFD in both the applications combined with histopathological grading was found to be significantly influencing cLNM ( $P = 0.004$ ). This result is in concordance with Tambasco and Magliocco, where the author suggested the same in breast cancer.<sup>[30]</sup> To the best of our knowledge, this is the first study to negate the predictive potential of nFD for cLNM as an independent factor. At the same time, this study has concluded that predictive potential of nFD combined with grading in cLNM is significant. This study is the first of its kind; therefore, the result is not supported by the literature. However, owing to the large sample size and validation of nFD by two softwares, the findings of this study may be regarded as reliable.

Not considering the effect of lymphovascular invasion and perineural invasion upon cLNM may be the limitation of this study. 4',6-diamidino-2-phenylindole (DAPI) and Feulgen-stained nuclei would give a better estimation of

**Table 2: Cervical lymph node metastasis\* nuclear fractal dimension cross tabulation**

Node	nFD_python_category		nFD_image J category		Total
	Low	High	Low	High	
No	29	43	8	40	72
Yes	14	28	0	1	42
Total	43	71	11	54	114

nFD: Nuclear fractal dimension

**Table 3: Combined effect of nuclear fractal dimension and grade on node in python**

	Variables in the equation					
	B	SE	Wald	df	Significant	Exp(B)
nFD python	1.343	3.445	0.152	1	0.697	3.832
nFD python grade	-0.843	0.294	8.202	1	0.004	0.431
Constant	0.561	4.598	0.015	1	0.903	1.752

nFD: Nuclear fractal dimension, SE: Standard error

**Table 4: Combined effect of nuclear fractal dimension and grade on the node in Image J**

	Variables in the equation					
	B	SE	Wald	df	Significant	Exp(B)
nFD Image J	6.412	4.442	2.084	1	0.149	609.073
nFD Image J Grade	-0.762	0.267	8.163	1	0.004	0.467
Constant	-7.367	6.597	1.247	1	0.264	0.001

nFD: Nuclear fractal dimension, SE: Standard error

nFD compared to hematoxylin-stained nuclei. Analyzing Bose's<sup>[25]</sup> result of combined efficiency of nFD of tumor cells and stromal cells in predicting DFS, we may suggest further research should be carried out to evaluate the combined potential of nFD of tumor cells and stromal cells in predicting cLNM. Prospective studies in this regard with larger sample size would strengthen the evidence. Predictive potential of other modalities of objective measurement of the spatial distribution of the nucleus in cancer cells like lacunarity and entropy may also be explored.

## CONCLUSION

To the best of our knowledge this study is the first of its kind which concludes that nFD combined with grading may predict lymphnode metastasis. Further studies on larger sample size is required to incorporate this during regular histopathology reporting of oral squamous cell carcinoma.

## Financial support and sponsorship

Nil.

## Conflicts of interest

There are no conflicts of interest.

## REFERENCES

- Vigneswaran N, Williams MD. Epidemiologic trends in head and neck cancer and aids in diagnosis. *Oral Maxillofac Surg Clin North Am* 2014;26:123-41.
- Bryne M, Koppang HS, Lilleng R, Kjaerheim A. Malignancy grading of the deep invasive margins of oral squamous cell carcinomas has high prognostic value. *J Pathol* 1992;166:375-81.
- Anneroth G, Hansen LS, Silverman S Jr. Malignancy grading in oral squamous cell carcinoma. I. Squamous cell carcinoma of the tongue and floor of mouth: Histologic grading in the clinical evaluation. *J Oral Pathol* 1986;15:162-8.
- Woolgar JA, Scott J. Prediction of cervical lymph node metastasis in squamous cell carcinoma of the tongue/floor of mouth. *Head Neck* 1995;17:463-72.
- Gabriel A, Namyslowski G, Ziolkowski A, Morawski K, Steplewska-Mazur K, Urbaniec P. Immunohistochemical analysis of lymphocytic infiltration in the tumor microenvironment in patients operated on for laryngeal cancer. *Eur Arch Otorhinolaryngol* 1999;256:384-7.
- Partridge M, Emilion G, Pateromichelakis S, A'Hern R, Lee G, Phillips E, et al. The prognostic significance of allelic imbalance at key chromosomal loci in oral cancer. *Br J Cancer* 1999;79:1821-7.
- Adel M, Kao HK, Hsu CL, Huang JJ, Lee LY, Huang Y, et al. Evaluation of lymphatic and vascular invasion in relation to clinicopathological factors and treatment outcome in oral cavity squamous cell carcinoma. *Medicine (Baltimore)* 2015;94:e1510.
- Arora A, Husain N, Bansal A, Neyaz A, Jaiswal R, Jain K, et al. Development of a new outcome prediction model in early-stage squamous cell carcinoma of the oral cavity based on histopathologic parameters with multivariate analysis: The Aditi-Nuzhat lymph-node prediction score (ANLPS) system. *Am J Surg Pathol* 2017;41:950-60.
- Mücke T, Kanatas A, Ritschl LM, Koerdt S, Tannapfel A, Wolff KD, et al. Tumor thickness and risk of lymph node metastasis in patients with squamous cell carcinoma of the tongue. *Oral Oncol* 2016;53:80-4.
- Kumar M, Chatterjee K, Purkait SK, Samaddar D. Computer-assisted morphometric image analysis of cells of normal oral epithelium and oral squamous cell carcinoma. *J Oral Maxillofac Pathol* 2017;21:24-9.
- Ananjan C, Jyothi M, Laxmidevi BL, Gopinathan PA, Nazir SH, Pradeep L. Morphometric computer-assisted image analysis of epithelial cells in different grades of oral squamous cell carcinoma. *J Cancer Res Ther* 2018;14:361-7.
- Briggs RJ, Pienta KJ, Hruban RH, Richtsmeier WJ. Nuclear morphometry for prediction of metastatic potential in early squamous cell carcinoma of the floor of the mouth. *Arch Otolaryngol Head Neck Surg* 1992;118:531-3.
- Giardina C, Caniglia DM, D'Aprile M, Lettini T, Serio G, Cipriani T, et al. Nuclear morphometry in squamous cell carcinoma (SCC) of the tongue. *Eur J Cancer B Oral Oncol* 1996;32B:91-6.
- Baish JW, Jain RK. Fractals and cancer. *Cancer Res* 2000;60:3683-8.
- Cross SS. Fractals in pathology. *J Pathol* 1997;182:1-8.
- Landini G. Fractals in microscopy. *J Microsc* 2011;241:1-8.
- Feder J. Fractals. US: Springer; 2013.
- Chen C, He ZC, Shi Y, Zhou W, Zhang X, Xiao HL, et al. Microvascular fractal dimension predicts prognosis and response to chemotherapy in glioblastoma: An automatic image analysis study. *Lab Invest* 2018;98:924-34.
- Grizzi F, Fiorino S, Qehajaj D, Fornelli A, Russo C, de Biase D, et al. Computer-aided assessment of the extra-cellular matrix during pancreatic carcinogenesis: A pilot study. *J Transl Med* 2019;17:61.
- Rajković N, Li X, Plataniotis KN, Kanjer K, Radulovic M, Milošević NT. The pan-cytokeratin staining intensity and fractal computational analysis of breast tumor malignant growth patterns prognosticate the occurrence of distant metastasis. *Front Oncol* 2018;8:348.
- Yinti SR, Srikant N, Boaz K, Lewis AJ, Ashokkumar PJ, Kapila SN. Nuclear fractal dimensions as a tool for prognostication of oral squamous cell carcinoma. *J Clin Diagn Res* 2015;9:C21-5.
- Phulari RG, Rathore RS, Talegaon TP. Nuclear fractal dimension: A new objective approach for discriminating normal mucosa, dysplasia and carcinoma. *J Oral Maxillofac Pathol* 2016;20:400-4.
- Goutzanis L, Papadogeorgakis N, Pavlopoulos PM, Katti K, Petsinis V, Plochoras I, et al. Nuclear fractal dimension as a prognostic factor in oral squamous cell carcinoma. *Oral Oncol* 2008;44:345-53.
- Mincione G, Di Nicola M, Di Marcantonio MC, Muraro R, Piattelli A, Rubini C, et al. Nuclear fractal dimension in oral squamous cell carcinoma: A novel method for the evaluation of grading, staging, and survival. *J Oral Pathol Med* 2015;44:680-4.
- Bose P, Brockton NT, Guggisberg K, Nakoneshny SC, Kornaga E, Klimowicz AC, et al. Fractal analysis of nuclear histology integrates tumor and stromal features into a single prognostic factor of the oral cancer microenvironment. *BMC Cancer* 2015;15:409.
- Maipas S, Nonni A, Politi E, Sarlanis H, Kavantzias NG. The goodness-of-fit of the fractal dimension as a diagnostic factor in breast cancer. *Cureus* 2018;10:e3630.
- Goutzanis LP, Papadogeorgakis N, Pavlopoulos PM, Petsinis V, Plochoras I, Eleftheriadis E, et al. Vascular fractal dimension and total vascular area in the study of oral cancer. *Head Neck* 2009;31:298-307.
- Thomas B, Stedman M, Davies L. Grade as a prognostic factor in oral squamous cell carcinoma: A population-based analysis of the data. *Laryngoscope* 2014;124:688-94.
- Kademani D, Bell RB, Bagheri S, Holmgren E, Dierks E, Potter B, et al. Prognostic factors in intraoral squamous cell carcinoma: The influence of histologic grade. *J Oral Maxillofac Surg* 2005;63:1599-605.
- Tambasco M, Magliocco AM. Relationship between tumor grade and computed architectural complexity in breast cancer specimens. *Hum Pathol* 2008;39:740-6.