

[CASE REPORT]

Successful Treatment of Rapidly Progressive Unclassifiable Idiopathic Interstitial Pneumonia with Anti-melanoma Differentiation-associated Gene-5 Antibody by Intensive Immunosuppressive Therapy

Takuma Koga¹, Shinjiro Kaieda¹, Masaki Okamoto¹, Ken Masuda¹, Kyoko Fujimoto¹, Satoshi Sakamoto¹, Masayuki Nakamura¹, Masaki Tominaga¹, Tomotaka Kawayama¹, Kiminori Fujimoto², Tomoaki Hoshino¹ and Hiroaki Ida¹

Abstract:

We describe a case of a woman who presented with a persistent cough, general fatigue, and a fever. Interstitial lung disease was rapidly progressive and resistant to high-dose steroid therapy. She tested positive for the presence of anti-melanoma differentiation-associated gene 5 (MDA-5) antibody, although she had no skin manifestations of dermatomyositis. She was eventually diagnosed with unclassifiable idiopathic interstitial pneumonia and was successfully treated with intensive immunosuppressive therapy including intravenous cyclophosphamide. To our knowledge, this is the first report of anti-MDA-5 antibody in a patient with idiopathic interstitial pneumonia.

Key words: anti-MDA-5 antibody, idiopathic pneumonia with autoimmune features (IPAF), rapidly progressive interstitial lung disease, unclassifiable idiopathic interstitial pneumonia (UCIP)

(Intern Med 57: 1039-1043, 2018)

(DOI: 10.2169/internalmedicine.9553-17)

Introduction

Anti-melanoma differentiation-associated gene 5 (MDA-5) antibody has a close relationship with rapidly progressive interstitial lung disease (RP-ILD) in East Asian patients with clinically amyopathic dermatomyositis (CADM) and is associated with increased mortality (1-3). Anti-MDA-5 antibody has been reported to be a diagnostic marker for classic dermatomyositis (DM) and CADM and it is not detected in polymyositis (PM), non-PM/DM connective tissue disease (CTD), or idiopathic interstitial pneumonia (IIP) (2, 4). Nevertheless, we encountered a patient with anti-MDA-5 antibody positive-RP-ILD who lacked typical skin manifestations of DM. She was diagnosed with unclassifiable idiopathic interstitial pneumonia (UCIP) according to the global classification of IIP (5). UCIP is the term used for

cases that cannot be classified into the major subtypes of IIP. The patient had an autoimmune-featured ILD, and she did not meet the criteria for a defined CTD.

To our knowledge, the presence of anti-MDA-5 antibody in a patient with IIP has not been reported previously.

Case Report

A 61-year-old woman presented at another institution with a persistent cough, general fatigue, and fever in August 2016. She had no history of smoking. No skin alterations, including heliotrope rash and Gottron's sign, were observed. Chest radiographs showed consolidations and ground-glass opacities (GGOs), predominantly in the bilateral lower lung fields, as well as a decrease in basal lung volume (Fig. 1a). Chest high-resolution computed tomography (HRCT) revealed patchy consolidation and GGOs with dilated air

¹Department of Medicine, Division of Respiriology, Neurology, and Rheumatology, Kurume University School of Medicine, Japan and ²Department of Radiology, Kurume University School of Medicine, Japan

Received: May 24, 2017; Accepted: August 8, 2017; Advance Publication by J-STAGE: December 21, 2017

Correspondence to Dr. Shinjiro Kaieda, kaieda@med.kurume-u.ac.jp

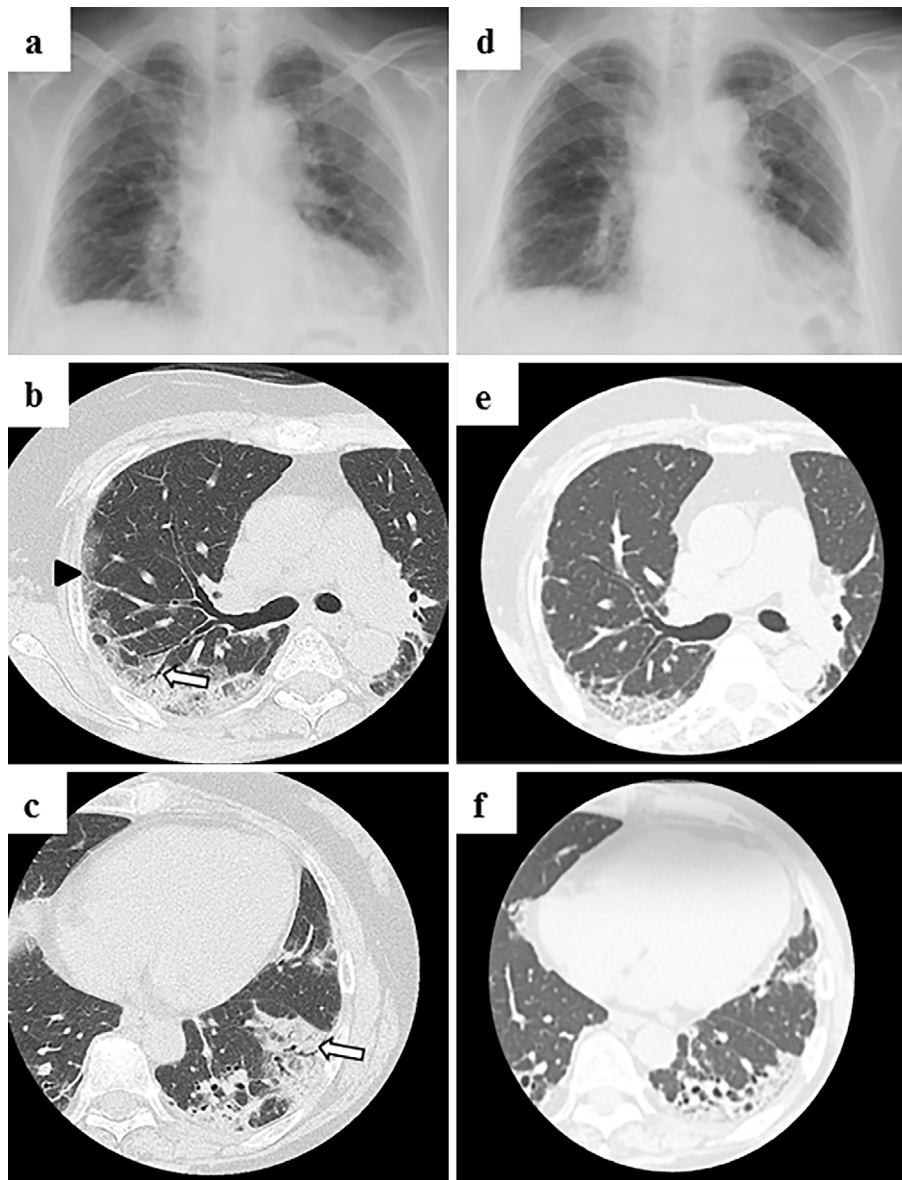


Figure 1. Pulmonary manifestations at the initial diagnosis (a, b, and c) and on the 106th day of hospitalization (d, e, and f). Chest radiograph (a) shows consolidations and GGOs in the bilateral lung fields and decrease in the basal lung volume at the initial diagnosis of interstitial lung disease. HRCT (b, right middle lung zone and c, left lower lung zone) shows patchy consolidations and GGOs (arrowhead) with dilated air bronchogram (white arrows). Lung volume loss in the bilateral lung fields at the 106th day of hospitalization is indicated on chest radiography (d). Bilateral consolidations and GGOs are shown to be reduced on chest HRCT (e and f). GGOs: ground-glass opacities, HRCT: high-resolution computed tomography

bronchogram, predominantly in the bilateral middle and lower lung zones, suggesting ILD with a radiologic pattern of non-specific interstitial pneumonia (NSIP) with organizing pneumonia (OP) (Fig. 1b and c). Pleural effusion was not detected. A transbronchial lung biopsy demonstrated non-specific inflammatory changes. A predominance of lymphoid cells was confirmed in bronchopulmonary lavage (total cell count, 530/ μ L; lymphocytes, 57%; neutrophils, 9%; monocytes, 31%; eosinophils 3%). Infectious lung disease was excluded by the bronchoscopy results, and the patient was diagnosed with IIP. The subtype of IIP was classified according to the global classification of IIP as UCIP (5). A

surgical lung biopsy was not performed because of hypoxia. Steroid pulse therapy was initiated in mid August, followed by oral prednisolone 60 mg/day (1 mg/kg). High-dose steroid therapy did not improve ILD. She was transferred to our department for further therapy in late August.

On admission to our hospital, a physical examination revealed no skin alterations, including heliotrope rash, Gottron's sign, palmar papules, or skin ulcers (Fig. 2). In addition, we did not observe Koebner phenomenon around the joint, periungual erythema, or nail fold bleeding. Furthermore, Raynaud's phenomenon, arthralgia, and myalgia were not present. Manual muscle testing (MMT) by a neurologist

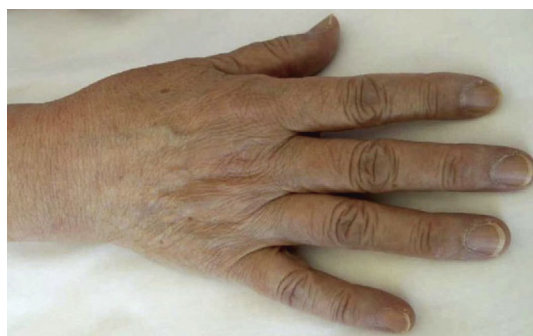

Figure 2. Clinical presentation on admission to our hospital. Gottron's sign, periungual erythema, and mechanic's hands were not observed.

revealed mild weakness of the gluteus maximus muscle on both sides (MMT score, 4/4). On chest auscultation, heart sounds were clear, but fine crackles were audible over bilateral lower lung fields. A laboratory evaluation revealed slight elevation of aldolase at 11.1 U/L (normal range: 2.1-6.1 U/L), whereas creatinine phosphokinase and myoglobin were within normal range. In addition, levels of C-reactive protein, lactate dehydrogenase, aspartate aminotransferase, and alanine aminotransferase were slightly elevated (0.35 mg/dL, 264 U/L, 48 U/L, and 95 U/L, respectively), and levels of serum ferritin and KL-6 were elevated (344 ng/mL and 822 U/mL, respectively). Results of immunologic tests were negative for antinuclear antibodies, anti-aminoacyl-tRNA synthetase antibodies and anti-neutrophil cytoplasmic antibodies. An arterial blood gas analysis on 0.5 L/min oxygen showed hypoxia (PaO₂, 80.5 Torr). The percentage vital capacity predicted (%VC) was very low, 35.4% on admission, and because of this, the percentage diffusing capacity of the lung for carbon monoxide predicted was not evaluated.

Chest radiograph indicated an exacerbation of volume loss via lung fibrosis (Fig. 1, 3). Cardiac ultrasonography revealed that left ventricular function was well-maintained, and pulmonary hypertension was excluded. Myopathy was not detected in the iliopsoas, gluteus, or femoral muscles by magnetic resonance imaging (MRI). Myogenic alterations of the iliopsoas and the quadriceps muscles were not observed by electromyography. A muscle biopsy was not performed because myopathy was not detected by MRI or electromyography. Although the patient did not meet the Japanese criteria for a diagnosis of DM (revised in 2015), anti-MDA-5 antibody was detected by an enzyme-linked immunosorbent assay (MESACUP anti-MDA-5 ELISA kit; Medical & Biological Laboratories, Nagoya, Japan) with a high titer (index 147, normal range: <32). We noted that lung involvement progressed rapidly, and the patient's hypoxia worsened. PaO₂ was 58.6 torr under 1 L/min oxygen on the 50th day of hospitalization (Fig. 3). The patient met the diagnostic criteria of RP-ILD because of the severe and rapidly progressing condition of ILD, as previously reported (6).

Her ILD was resistant to steroid therapy and showed a

similar pathophysiology to RP-ILD complicated by anti-MDA-5 antibody-positive DM. Intravenous cyclophosphamide [IVCY; 840 mg (500 mg/mm²)] and tacrolimus therapy was initiated. The dose of tacrolimus was started at 0.025 mg/kg twice a day, and the trough was adjusted to 10 ng/mL. A dose of 3 mg of tacrolimus elevated the trough level to 13.8 ng/mL, and nephrotic syndrome was induced. The dose of tacrolimus was decreased to 2.4 mg, but the nephrotic syndrome did not improve, and tacrolimus was discontinued. After the nephrotic syndrome improved, tacrolimus was resumed, and the trough was adjusted to 5-10 ng/mL. We repeated IVCY every 2 weeks and increased the IVCY dosage to 900 mg. High-dose intravenous immunoglobulin was also given. Levels of serum ferritin were elevated to a maximum of 893 ng/mL on the 50th day of hospitalization.

After the fourth cycle of IVCY therapy, hypoxia began to improve, and the serum levels of ferritin were decreased to 767 ng/mL on the 64th day of hospitalization and reached the lowest values, 226 ng/mL, before discharge from our hospital. The titer of anti-MDA-5 antibodies was also decreased. Although a loss of volume in the bilateral lung fields was indicated on chest radiography, the bilateral consolidations and GGOs were reduced on chest HRCT on the 106th day of hospitalization (Fig. 1d-f). We recorded a %VC ranging from 34% to 40.7%. The clinical course is summarized in Fig. 3.

Discussion

The presence of anti-MDA-5 antibodies identifies a population of patients with CADM who have an increased risk for RP-ILD. The 5-year survival rate of patients with anti-MDA-5 antibodies has been reported to be 56% (2). Serum ferritin levels \geq 450 ng/mL on admission have been reported to be poor prognostic markers (3, 7, 8). Furthermore, right middle lobe GGO involving $>$ 5% of the lobe on HRCT has also been indicated as a poor prognostic factor in anti-MDA-5 antibody-positive DM-ILD patients (7). While serum ferritin levels were elevated only slightly (344 ng/mL) in the present case, the GGO areas in the right middle lobe on HRCT accounted for 10%, representing a poor prognostic factor.

The administration of intensive immunosuppressive therapy, including high-dose corticosteroids, oral calcineurin inhibitor, and IVCY, prior to the onset of irreversible pulmonary changes might lead to an improved prognosis (9). In the present case, UCIP was rapidly progressive and resistant to high-dose steroid therapy. Repeated IVCY inhibited the acute exacerbation of ILD and decreased the serum ferritin and anti-MDA-5 antibody titer.

While the patient had mild muscle weakness with a slight elevation of serum aldolase, myopathy was not confirmed on MRI or electromyography. We could not exclude the possibility of polymyositis because a muscle biopsy was not performed. However, a diagnosis of CADM or DM was ruled

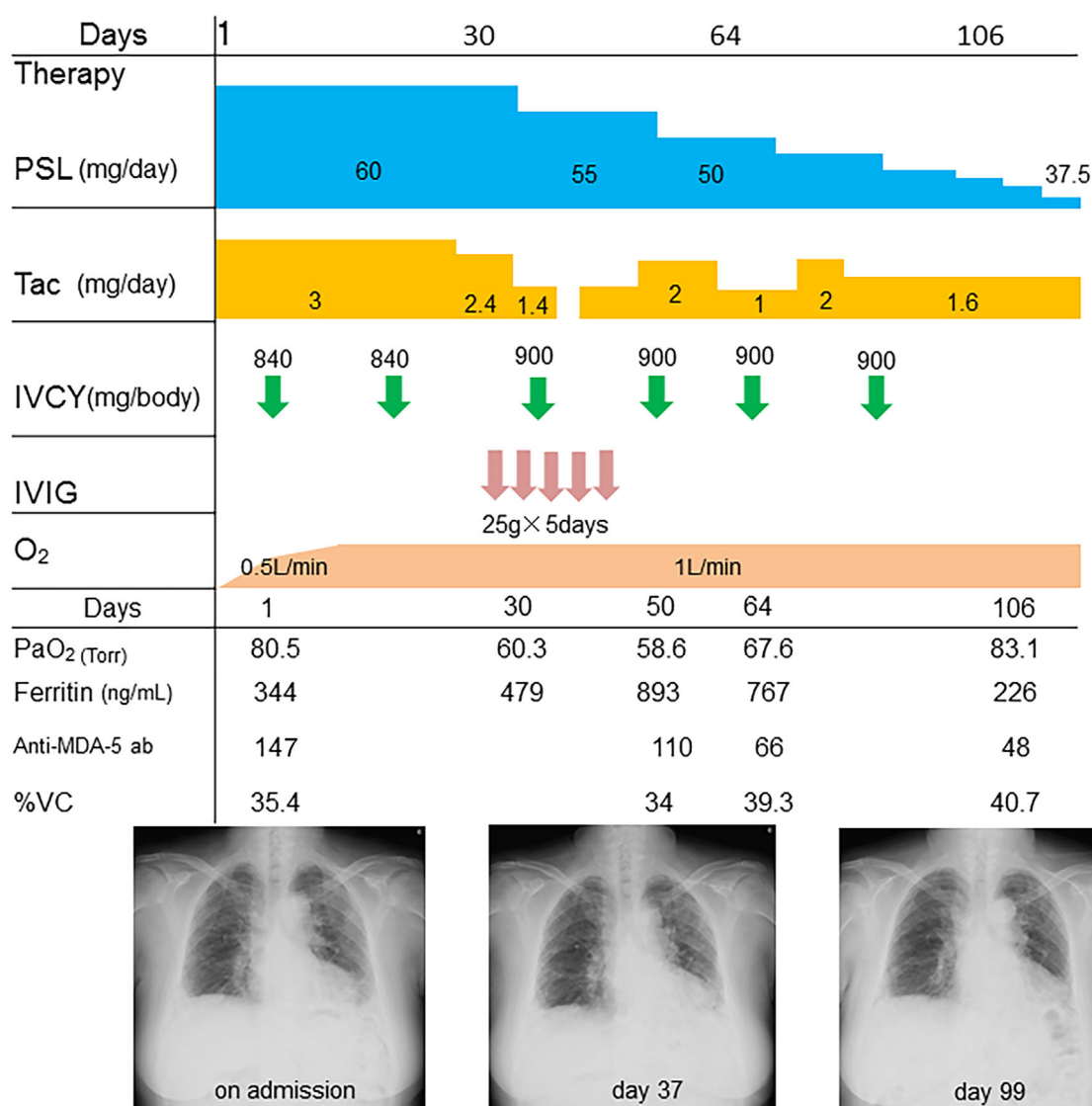


Figure 3. The clinical course of the patient. IVCY: intravenous pulse cyclophosphamide, IVIG: intravenous immunoglobulin, PSL: prednisolone, Tac: tacrolimus, %VC: percentage vital capacity predicted

out because our patient lacked the typical skin manifestations observed with DM. A multicenter cross-sectional study indicated that a subset of anti-CADM-140 (MDA-5) antibody-positive patients develop lung disease without skin or muscle manifestation as initial symptoms (2). ILD may precede skin involvement, and high-dose steroid therapy may mask the development of skin and muscle damage. However, the patient was diagnosed with UCIP because the underlying disorder did not meet the classification criteria of a given CTD.

Many patients with IIPs have subtle features suggestive of an autoimmune etiology; however, these patients are classified as having UCIP because they do not meet the diagnostic criteria for CTD. Recently, classification criteria for interstitial pneumonia with autoimmune features (IPAF) were proposed (10). These criteria are organized around three central domains: a clinical domain consisting of specific extrathoracic features such as arthritis, Raynaud's phenome-

non, and Gottron's sign; a serologic domain consisting of specific circulating autoantibodies, including anti-MDA-5 antibody; and a morphologic domain consisting of specific chest imaging features. In addition to the typical skin manifestations, which include Gottron's sign, minor skin alterations such as periungual erythema and nail fold bleeding should be noted. To be classified as having IPAF, an individual must present with at least one feature from at least two domains. Our patient was classified as having IPAF due to the presence of anti-MDA-5 antibody in the serologic domain and NSIP with an OP pattern on HRCT in the morphologic domain. If patients develop RP-ILD with autoimmune features and demonstrate a pathology similar to anti-MDA-5 antibody-positive DM-ILD, the presence of anti-MDA-5 antibody should be suspected. Thus, knowledge of the clinical features of anti-MDA-5 antibody-positive DM-ILD, including skin alterations, radiological findings, and changes in pulmonary function, is crucial. In addition, the

collaboration of dermatologists, rheumatologists, radiologists, and respiratory medicine specialists might be required in order to identify all of these clinical features.

If a patient develops RP-ILD with autoimmune features and anti-MDA-5 antibody is detected, intensive immunosuppressive therapy including IVCY should be considered.

The authors state that they have no Conflict of Interest (COI).

Shinjiro Kaieda and Masaki Okamoto contributed equally to this work.

References

1. Sato S, Hoshino K, Satoh T, et al. RNA helicase encoded by melanoma differentiation-associated gene 5 is a major autoantigen in patients with clinically amyopathic dermatomyositis: association with rapidly progressive interstitial lung disease. *Arthritis Rheum* **60**: 2193-2200, 2009.
2. Hamaguchi Y, Kuwana M, Hoshino K, et al. Clinical correlations with dermatomyositis-specific autoantibodies in adult Japanese patients with dermatomyositis: a multicenter cross-sectional study. *Arch Dermatol* **147**: 391-398, 2011.
3. Gono T, Sato S, Kawaguchi Y, et al. Anti-MDA5 antibody, ferritin and IL-18 are useful for the evaluation of response to treatment in interstitial lung disease with anti-MDA5 antibody-positive dermatomyositis. *Rheumatology (Oxford)* **51**: 1563-1570, 2012.
4. Sato S, Murakami A, Kuwajima A, et al. Clinical utility of an enzyme-linked immunosorbent assay for detecting anti-melanoma differentiation-associated gene 5 autoantibodies. *PLoS One* **11**: e0154285, 2016.
5. Travis WD, Costabel U, Hansell DM, et al. An official American Thoracic Society/European Respiratory Society statement: update of the international multidisciplinary classification of the idiopathic interstitial pneumonias. *Am J Respir Crit Care Med* **188**: 733-748, 2013.
6. Kondoh Y, Taniguchi H, Kataoka K, et al. Prognostic factors in rapidly progressive interstitial pneumonia. *Respirology* **15**: 257-264, 2010.
7. Fujiki Y, Kotani T, Isoda K, et al. Evaluation of clinical prognostic factors for interstitial pneumonia in anti-MDA5 antibody-positive dermatomyositis patients. *Mod Rheumatol* **1-8**, 2017.
8. Tanizawa K, Handa T, Nakashima R, et al. The prognostic value of HRCT in myositis-associated interstitial lung disease. *Respir Med* **107**: 745-752, 2013.
9. Nakashima R, Mimori T. [Anti-MDA5 (melanoma differentiation-associated gene 5) antibody and dermatomyositis with rapidly progressive interstitial pneumonia]. *Nihon Rinsho Meneki Gakkai Kaishi (Jpn J Clin Immunol)* **36**: 71-76, 2013 (in Japanese, Abstract in English).
10. Fischer A, Antoniou KM, Brown KK, et al. An official European Respiratory Society/American Thoracic Society research statement: interstitial pneumonia with autoimmune features. *Eur Respir J* **46**: 976-987, 2015.

The Internal Medicine is an Open Access article distributed under the Creative Commons Attribution-NonCommercial-NoDerivatives 4.0 International License. To view the details of this license, please visit (<https://creativecommons.org/licenses/by-nc-nd/4.0/>).