

Acute epiglottic abscess in adults: Still a challenge!

Sir,

Assistance of an Anesthesiologist for airway management in acute epiglottitis is often sought, although administration of anesthesia for epiglottic abscess drainage in an adult is rarely needed. The last two decades have witnessed an increase in the incidence of both acute epiglottitis and epiglottic abscesses, necessitating a more frequent role for an anesthesiologist in the management.^[1] The difficult airway scenario associated with this condition and the risk of total occlusion of the larynx and pharynx are well known. The management of acute epiglottitis and associated airway compromise is clearly documented.^[2] We report successful management of an acute epiglottic abscess, but with a minimally traumatic endotracheal intubation.

A 40-year-old man with a 5-day history of 'painful throat' and dysphagia diagnosed to have acute epiglottitis with abscess was posted for drainage under anesthesia. The patient was febrile (101.9°F) with a respiratory rate of 24/min, pulse of 92/min, and BP 100/50 mmHg. In the upright position, the patient had an audible mild stridor and oxygen saturation was 98% on room air. Auscultation of lung fields revealed normal breath sounds. Epiglottic abscess was diagnosed by indirect laryngoscopy and a lateral radiograph of the neck which showed the thumb sign [Figure 1]. Blood count revealed leucocytosis (16,000 cells/mm³) with neutrophilia (72%).

Under cover of ceftazidime 1 g i.v., the patient was brought to the operating room for immediate drainage of the abscess and securing the airway. Awake fiberoptic nasal intubation was planned with a surgeon in attendance for possible emergency tracheostomy. Topical airway anesthesia was planned. Cotton pledgets soaked with lignocaine 2% solution were used for nasal mucosal anesthesia. Pharyngeal surface anesthesia was achieved with metered dose lignocaine 10% spray (10 mg/puff, four puffs) administered trans-orally in the sitting position. Oral topical viscous lignocaine solution gargle was not possible as the patient complained of painful throat. 2 ml lignocaine 4% was injected trans-tracheal for laryngeal anesthesia. Nasotracheal intubation was performed with 7.0 mm I.D. cuffed endotracheal tube (Portex, Smiths, U.K) using fiberoptic aid.

The patient had tolerable discomfort but intact swallowing reflexes resulted in trauma and minimal bleeding from the oropharynx. Intubation was however achieved without rupturing the abscess. Suctioning and additional injection of 3 ml lignocaine 4% from the side port of the bronchoscope was done before advancement of the endotracheal tube. Total duration of fiberoptic intubation was about 10 min. After confirming the endotracheal tube placement, the anesthesia was induced with thiopentone 250 mg, vecuronium 4 mg, and fentanyl 100 mcg intravenously. Anesthesia was maintained with nitrous oxide:oxygen (66%:33%), isoflurane and intermittent positive pressure ventilation. After the procedure, neuromuscular block reversal was achieved with neostigmine 2.5 mg and glycopyrrolate 0.5 mg. The patient was shifted to the post-anesthesia intensive care unit with the endotracheal tube *in situ* and breathing spontaneously. Humidified oxygen was administered for 2 h through T-piece. In addition to intravenous antibiotics, dexamethasone 8 mg i.v. was administered twice daily for 5 days. Blood culture did not reveal any specific pathogen.

Clinical recovery was uneventful. The patient was extubated on the fourth day after the "cuff leak test" was positive, implying the absence of any soft tissue swelling and obstruction. The postextubation [Figure 2] period was uneventful and the

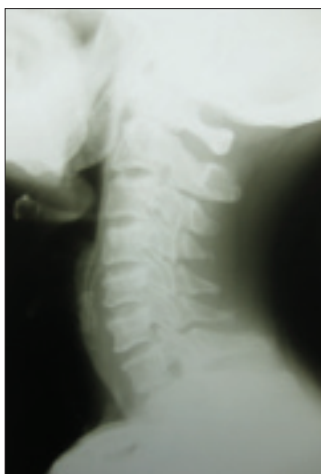

Figure 1: Preoperative lateral view neck radiograph showing thumb sign

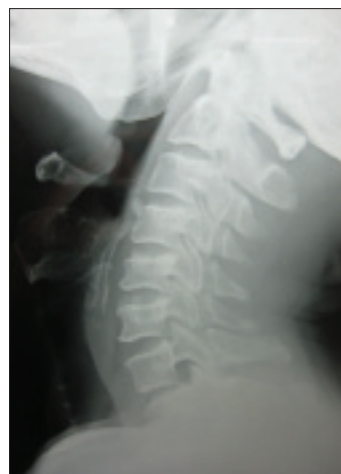

Figure 2: Postoperative X-ray

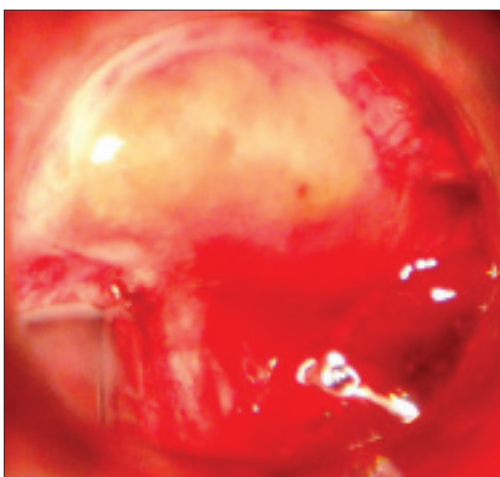


Figure 3: Acute epiglottic abscess, note the trauma following intubation in the fiberoptic scope view

patient was discharged to home on the seventh day.

Available airway management techniques in an acute epiglottitis patient are intubation in the awake status, after inhalation induction, rapid sequence intubation, fiberoptic bronchoscopic intubation, or tracheostomy under local anesthesia, though the last two techniques are preferred.^[2] However the same cannot be applied for an epiglottic abscess due to the potential risks associated with each technique.^[3] There is need for proper selection and caution in approach. Fatal outcomes can occur, while attempting to secure an airway, in case an abscess is not anticipated.

Conventionally, tracheostomy is considered safe. However, numerous reports mention its varied complications including prolonged hospitalization and higher mortality.^[2] Awake fiberoptic nasal intubation was preferred in our case to avoid tracheostomy. Awake intubation also negates the possibility of precipitating or increasing airway obstruction on induction of

general anesthesia.^[4,5] Certain factors hinder complete airway anesthesia for awake intubation in a patient with intraoral pathology. Pain and infection contraindicate administration of a nerve block and the presence of pus obviates its effectiveness. Throat pain precludes viscous gargling for oral mucosal surface anesthesia. In our case, oral local anesthetic spray did not completely abolish gag reflexes and pain. Gag reflex, due to moderate discomfort during fiberoptic intubation, traumatized the pharynx but fortunately left the abscess intact [Figure 3]. Additional injection of local anesthetic through the side port of the bronchoscope probably facilitated the intubation. Though the endotracheal tube was placed *in situ* only after adequate visualization, a few factors need mention. Temporary airway obstruction, bleeding and rupture of the abscess may occur while passing the bronchoscope or endotracheal tube through the narrowed larynx.^[6] Surgical support for emergency tracheostomy is mandatory while managing such compromised airways.

**Thrivikrama Padur Tantry, Ajay Prasad Hrishi,
Reshma Koteswar, Sunil P Shenoy¹,
Karunakara Kenjar Adappa**

Departments of Anaesthesiology and ¹Urology, A J Institute of Medical Sciences, Kuntikana, Mangalore, India

Address for correspondence: Dr. Thrivikrama Padur Tantry,
Department of Anaesthesiology, A J Institute of Medical Sciences,
Kuntikana, Mangalore - 575 004, India.
E-mail: drpptantry@yahoo.com

References

- Berger G, Landau T, Berger S, Finkelstein Y, Bernheim J, Ophir D. The rising incidence of adult acute epiglottitis and epiglottic abscess. *Am J Otolaryngol* 2003;24:374-83.
- Baxter FJ, Dunn GL. Acute epiglottitis in adults. *Can J Anaesth* 1988;35:428-35.
- Saeed I, Malik SM, Waleem SS, Ahmed S. Acute epiglottic abscess

- in an adult. *J Coll Physicians Surg Pak* 2007;17:427-8.
4. Snijdelaar DG, Dole DJ. Anaesthesia for ENT procedures and laser surgery. Chap 50. In: Healy T, Knight PR, editor. *A Practice Of Anesthesia*, 7th ed. London, Arnold: Wylie And Churchill-Davidsons; 2003. p. 837-46.
 5. Wilson WC, Benumof JL. Pathophysiology, evaluation and treatment of the difficult airway. *Anesth Clin North Am* 1998;16:29-75.
 6. Muller BJ, Fliegel JE. Acute epiglottitis in a 79-year-old man. *Can Anaesth Soc J* 1985;32:415-7.

Access this article online	
Quick Response Code:	Website: www.joacp.org
	DOI: 10.4103/0970-9185.83711