

CASE REPORT

Repair of an acute Type A aortic dissection with LVAD patient after failed mitral and tricuspid operation

Jan Dieter Schmitto, Felix Fleissner, Jasmin Hanke, Sebastian Rojas, Murat Avsar, Andreas Martens, Malakh Shrestha, Axel Haverich & Martin Strueber

Division of Cardiac, Thoracic, Transplantation and Vascular Surgery, Hannover Medical School, Hannover, Germany

Correspondence

Felix Fleissner, Division of Cardiac, Thoracic, Transplantation and Vascular Surgery, Hannover Medical School, Carl-Neuberg-Strasse 1 30625 Hannover, Germany.
Tel: +49 (0)511 532 2184; Fax: +49 (0) 511 532 9833;
E-mail: Fleissner.Felix@mh-hannover.de

Funding Information

No sources of funding were declared for this study.

Received: 13 April 2015; Revised: 8 June 2015; Accepted: 24 June 2015

Clinical Case Reports 2016; 4(4): 387–389

doi: 10.1002/ccr3.332

Introduction

We describe a patient with left ventricular assist device implantation followed by an acute type A aortic dissection four weeks after the operation. He received replacement of the ascending aorta by a prosthesis with a side branch (Gelweave Ante-Flo) connected to the left ventricular assist device outflow branch.

Case Report

A 58-year-old male patient was primarily operated for mitral valve replacement and tricuspidal valve reconstruction after cardiogenic shock and septic shock subsequently. Weaning from the respirator was impossible and the patient developed a low cardiac output during the postoperative course. Echocardiography showed a severely impaired ejection fraction of 15% postoperatively. Due to progression of decompensated heart failure, a left ventricular assist device (Heartware HVAD) was implanted via anterolateral thoracotomy and upper partial sternotomy without the use of cardiopulmonary bypass as described earlier [1]. The patient recovered accordingly to his

Key Clinical Message

An acute type A dissection in a patient with a left ventricular assist device was treated by replacement of the ascending aorta and the proximal arch using a prosthesis with a side branch which was connected to the left ventricular assist device outflow branch, greatly simplifying the procedure.

Keywords

Centrifugal pump, Heartware, HVAD, left ventricular assist device, Typ A dissection.

underlying disease and general condition. After 4 weeks, the patient's X-rays revealed a progressive pleural effusion in the right thorax (Fig. 1). A computed tomography and

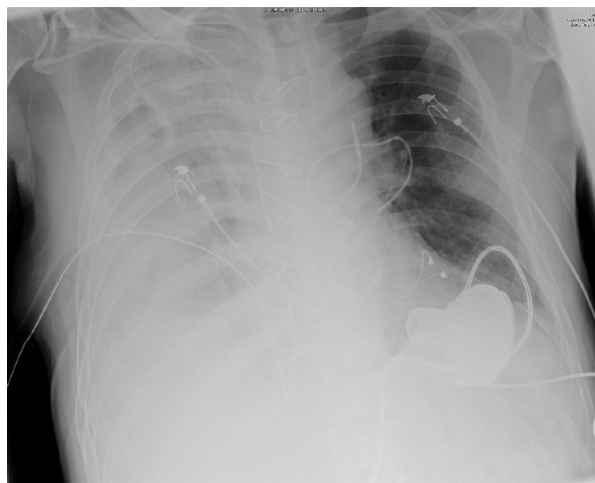


Figure 1. Preoperative, conventional p.a. X-ray resulting in prompt operation showing a right-sided hemothorax.

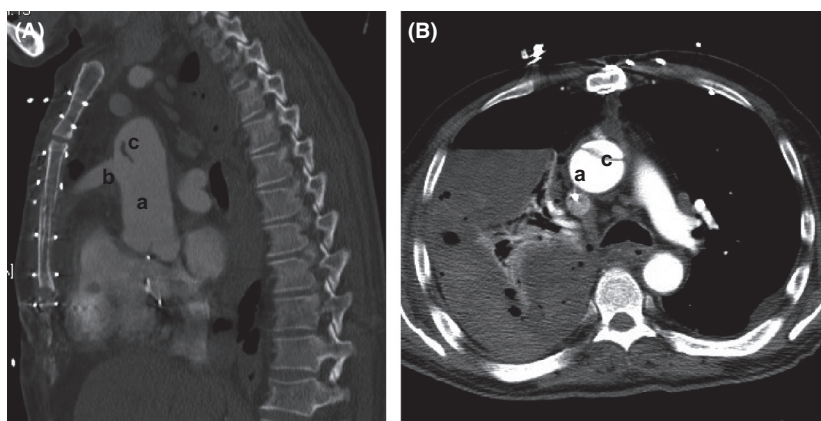


Figure 2. (A, B) Computed angiogram showing the ascending aorta (a) with the outflow tract (b) and the aortic dissection (c).

angiogram revealed no active bleeding, however a type A dissection just cranial of the outflow tract anastomosis (Fig. 2). He was immediately referred to the operation theatre. Through a complete sternotomy, the patient was put on cardiopulmonary bypass. After aortotomy and clamping of the aorta, a short dissection of the ascending aorta most likely due to a calcified atherosclerotic plaque just distal of the former aortic cannulation from the previous mitral and tricuspid valve operation was found. There was no obvious cause for the bleeding, however it came most likely from the sternotomy. The patient was put on deep hypothermia (25°C) and a replacement of the ascending aorta and the proximal aortic arch with a 26 mm Vaskutec Gelweave Ante-Flo prosthesis was carried out without selective antegrade perfusion due to the expected short time of cardiopulmonary arrest (15 min). Cold blood cardioplegic solution was used. The outflow tract prosthesis was connected to the prosthesis' side branch. Bleeding could be stopped by massive substitute of thrombocytes, fresh frozen plasma, and coagulation factors. The operation was completed and the patient was weaned from cardiopulmonary bypass. Cardiopulmonary bypass time was 104 minutes, aortic clamping time was 41 minutes. The patient recovered from the operation and was discharged home 30 days later after receiving a postoperative computed angiogram (Fig. 3).

Considerations

The surgical complication rate after left ventricular assist device (LVAD) implantation is high, due to complicated cases in patients with various comorbidities. Especially bleeding rates of up to 30 percent have been reported [2]. The most common complication is however infection related. Other reported complications are thrombus related or malfunction of the device itself [3,4]. Iatrogenic aortic dissection after cardiac surgery using Cardiopul-

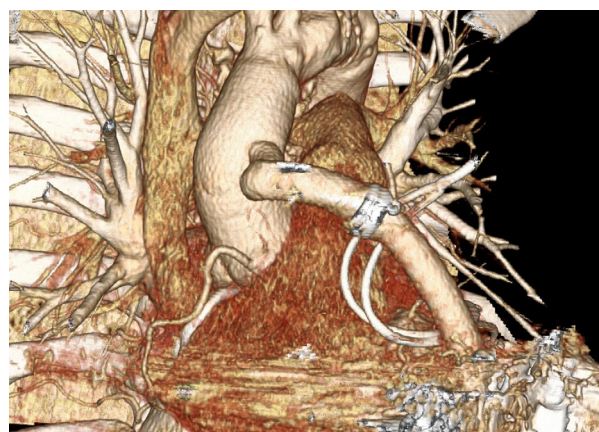

Figure 3. Postoperative computed angiogram, 3d reconstruction showing the ascending aortic "anteflow" prosthesis with the branch connected to the LVAD outflow graft.

monary bypass (CBP) is a rare complication with about 0.3% prevalence [5]. However, in our patient with generalized atherosclerosis, the dissection occurred nearby but not directly at the site of the former cannulation, instead at the site of an atherosclerotic plaque.

The usage of a branched prosthesis for the aortic and proximal aortic arch replacement with a connection to the outflow tract, however, proved to be feasible. This operational method might also be of use for co-occurring aortic replacement and LVAD implantation. The need for operation of an acute type A dissection, however, needs further consideration. In our case, since there was a symptomatic and progressive hemothorax and the diagnosis of a type A dissection, our patient needed an immediate operation. Although there was no direct bleeding from the aortic dissection visible preoperatively, the conclusion had to be made that the hemothorax was caused by dissection itself. As it turned out, that was

not the case, since the bleeding came most likely from the sternotomy. The need for surgical intervention in a LVAD patient with an acute type A dissection without the simultaneous bleeding justifying a re-thoracotomy has to be made individually for each patient in recognition of comorbidities and expected outcome. Patients with assist devices often present with coagulopathy, especially an acquired von Willebrand syndrome [6]. This results in a high intraprocedural bleeding risk. However, general agreement exists in the prompt need for operation of an acute type a dissection. In general, patients with assist devices are most often complex and individual choices on how and when to operate have to be made especially in patients with a poor prognosis.

Using the Ante-Flo prosthesis with a single-side branch, usually for connection of the extracorporeal circulation, for connection to the LVAD outflow graft simplified the anastomosis, omitting the need for the more difficult ascending aortic prosthesis/outflow graft anastomosis.

In conclusion, in this case, a patient with a left ventricular assist device and subsequent type A dissection could be operated with good outcome alienating an Ante-Flo single- branched prosthesis.

Conflict of Interest

The authors declare that they have no conflicts of interest concerning this article.

References

1. Schmitto, J. D., U. Molitoris, A. Haverich, and M. Strueber. 2012. Implantation of a centrifugal pump as a left ventricular assist device through a novel, minimized approach: upper hemisternotomy combined with anterolateral thoracotomy. *J. Thorac. Cardiovasc. Surg.* 143:511–513.
2. Schaffer, J. M., G. J. Arnaoutakis, J. G. Allen, E. S. Weiss, N. D. Patel, S. D. Russell, et al. 2011. Conte JV. Bleeding complications and blood product utilization with left ventricular assist device implantation. *Ann. Thorac. Surg.* 91:740–747; discussion 747–9.
3. Strueber, M., G. O'Driscoll, P. Jansz, A. Khaghani, W. C. Levy, G. M. Wieselthaler, and Heart Ware Investigators. 2011. Multicenter evaluation of an intrapericardial left ventricular assist system. *J. Am. Coll. Cardiol.* 57:1375–1382.
4. Schmitto, J. D., M. Avsar, and A. Haverich. 2014. Increase in left ventricular assist device thrombosis. *N. Engl. J. Med.* 370:1463–1464.
5. Hwang, H. Y., D. S. Jeong, K. H. Kim, K. B. Kim, and H. Ahn. 2010. Iatrogenic type A aortic dissection during cardiac surgery. *Interact. Cardiovasc. Thorac. Surg.* 10:896–899.
6. Crow, S., D. Chen, C. Milano, W. Thomas, L. Joyce, V. 3rd Piacentino, et al. 2010. Acquired von Willebrand syndrome in continuous-flow ventricular assist device recipients. *Ann. Thorac. Surg.* 90:1263–1269; discussion 1269.