

## CLINICAL IMAGE

# MR Imaging of an Intramural Adenosarcoma with Pathologic Correlation

Shinya Fujii<sup>1\*</sup>, Kanae Nosaka<sup>2</sup>, Naoko Mukuda<sup>1</sup>, Takeru Fukunaga<sup>1</sup>,  
Shinya Sato<sup>3</sup>, and Toshihide Ogawa<sup>1</sup>

**Keywords:** *magnetic resonance imaging, uterus, uterine, adenosarcoma, adenomyosis*

## Introduction

Adenosarcomas are rare tumors with low-malignant potential; they are characterized by a mixture of benign glandular epithelial and malignant mesenchymal elements. Adenosarcomas usually occur as endometrial lesions. Intramural adenosarcomas have been rarely reported, and they are commonly found in foci of adenomyosis or in a mural adenomyoma without the involvement of eutopic endometrium.<sup>1</sup> Herein, we demonstrate a case of intramural adenosarcoma with pathologic correlation.

## Case Report

The patient was a 58-year-old woman (Gravidity [G]0 Parity [P]0) diagnosed with uterine fibroid and adenomyosis, and she was treated with uterine artery embolization (UAE) 10 years previously. After her treatment, she had been treated with a gonadotropin-releasing hormone agonist. Recently, growth of intramyometrial mass was suspected on vaginal ultrasonography (US). Magnetic resonance imaging was performed for further examination. Magnetic resonance images demonstrated an intramyometrial mass in the anterior wall of the uterine body. The mass showed slightly low intensity on T<sub>1</sub>-weighted images (WI) and clearly defined inhomogeneous high intensity on T<sub>2</sub>WI (Fig. 1). The mass showed inhomogeneous contrast

enhancement with cystic changes of variable sizes, mild high intensity on diffusion-weighted (DW) images and high intensity ( $1.71 \times 10^{-4}$  mm<sup>2</sup>/s) on apparent diffusion coefficient (ADC) maps. In addition, the margins of the mass showed low-intensity rim on T<sub>2</sub>WI (Fig. 1). In contrast, the myometrium adjacent to the mass showed low intensity with unclear margins suggesting adenomyosis (Fig. 1). We considered that the mass was endometrial stromal sarcoma arising from adenomyosis. On pathological examination, benign glandular epithelial components surrounded by atypical stromal cells with mitosis (2–3/10HPF) were identified. Sarcomatous overgrowth was absent. The tumor was diagnosed as adenosarcoma. The marginal area showed an increase in collagen fibers accompanied by hypertrophic smooth muscle cells (Fig. 2). Adenomyosis was found in the myometrium which included the area adjacent to the mass. Therefore, the mass was diagnosed as adenosarcoma arising from adenomyosis.

## Discussion

Adenosarcomas show iso or high-signal intensity compared to the myometrium on T<sub>1</sub> and T<sub>2</sub>WI. Small cystic areas are usually observed, which reflect glandular cavities on T<sub>2</sub>WI. The lesions show strong contrast enhancement similar to that of the myometrium and do not show strong signal intensities on DW imaging.<sup>2</sup> In the present case, the intramyometrial mass showed features consistent with what was previously reported. Moreover, the mass was adjacent to the low-intensity area on T<sub>2</sub>WI thus reflecting adenomyosis, which is consistent with the previously reported MR imaging findings on a subserosal adenosarcoma.<sup>1</sup>

However, we suspected that the lesion was a low-grade endometrial stromal sarcoma, because the marginal area showed low-intensity rim on T<sub>2</sub>WI.<sup>3</sup> Low-intensity rim consisting of fibrous tissue layers and/or a decrease in free water caused by the distortion of myometrial tissue following tumor expansion, are reported in endometrial

<sup>1</sup>Division of Radiology, Department of Pathophysiological and Therapeutic Science, Faculty of Medicine, Tottori University, 36-1 Nishi-cho, Yonago, Tottori 683-8504, Japan

<sup>2</sup>Division of Organ Pathology, Department of Pathology, Faculty of Medicine, Tottori University, Yonago, Tottori, Japan

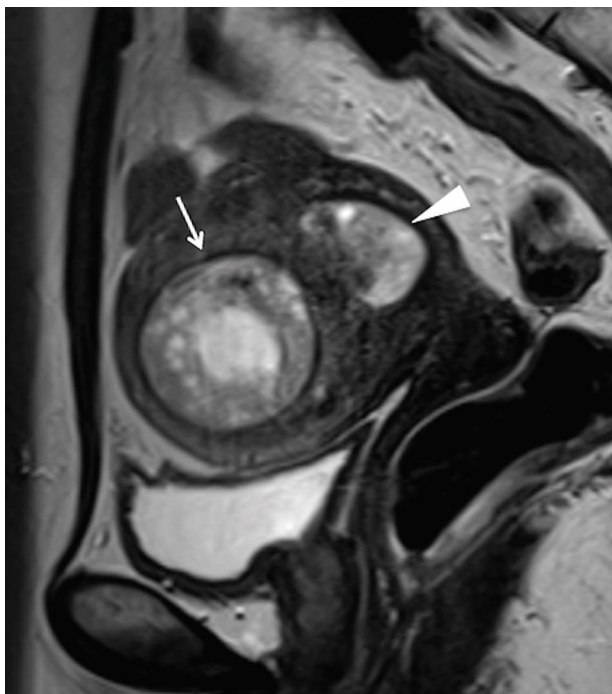
<sup>3</sup>Division of Reproductive-Perinatal Medicine and Gynecological Oncology, Department of Surgery, Faculty of Medicine, Tottori University, Yonago, Tottori, Japan

\*Corresponding author, E-mail: sfujii@grape.med.tottori-u.ac.jp

©2017 Japanese Society for Magnetic Resonance in Medicine

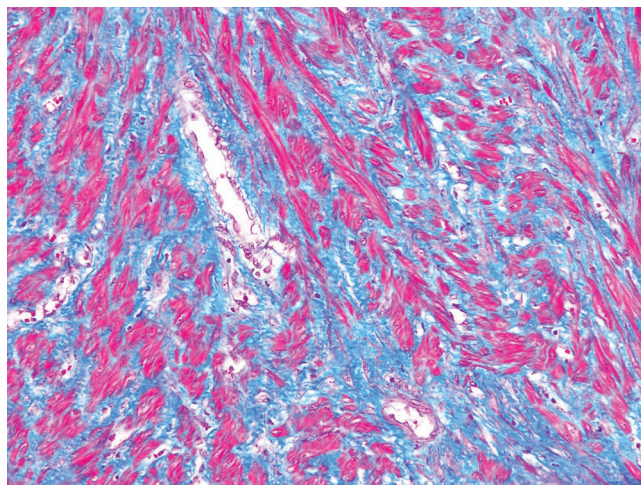
This work is licensed under a Creative Commons Attribution-NonCommercial-NoDerivatives International License.

Received: October 28, 2016 | Accepted: March 29, 2017



**Fig. 1** Sagittal T<sub>2</sub>-weighted image (WI). An intramyometrial mass in the anterior wall of the uterine body shows inhomogeneous high intensity. The margin of the mass shows low-intensity rim (arrow). In contrast, the myometrium adjacent to the mass shows low intensity with unclear margin, suggesting adenomyosis. Intracavitary polypoid adenomyoma is also seen (arrow head).

stromal sarcoma cases.<sup>3</sup> In the present case, the marginal area showed hypertrophic myometrium with an increase in collagen fibers. Although we cannot confirm the histologic findings from the previous report, our findings are considered to be consistent with previous findings. We therefore should include adenosarcomas in the differential diagnosis of intramyometrial masses with a low-intensity rim on T<sub>2</sub>WI.



**Fig. 2** Histopathological specimen, Masson trichrome stain (high-power field). The marginal area shows increased collagen fibers with hypertrophic smooth muscle cells.

## Conflicts of Interest

The authors declare that they have no conflicts of interest.

## References

1. Jha P, Ansari C, Coakley FV, et al. Case report: Imaging of Mullerian adenosarcoma arising in adenomyosis. *Clin Radiol* 2009; 64:645–648.
2. Yoshizako T, Wada A, Kitagaki H, Ishikawa N, Miyazaki K. MR imaging of uterine adenosarcoma: case report and literature review. *Magn Reson Med Sci* 2011; 10:251–254.
3. Furukawa R, Akahane M, Yamada H, et al. Endometrial stromal sarcoma located in the myometrium with a low-intensity rim on T<sub>2</sub>-weighted images: report of three cases and literature review. *J Magn Reson Imaging* 2010; 31:975–979.