



Case report

Measles in a measles-eliminated country: A case report of a measles-infected postpartum mother and infant in Japan



Haruki Mito^a, Ryota Hase^{a,b,*}, Nozomu Oshima^c, Hiroyuki Ikeda^c

^a Department of Infectious Diseases, Japanese Red Cross Narita Hospital, 90-1 Iida-cho, Narita, Chiba, 286-8523, Japan

^b Department of Infectious Diseases, Kameda Medical Center, 929 Higashi-cho, Kamogawa, Chiba, 296-8602, Japan

^c Department of Pediatrics, Japanese Red Cross Narita Hospital, 90-1, Iida-cho, Narita, Chiba, 286-8523, Japan

ARTICLE INFO

Article history:

Received 25 April 2021

Received in revised form 6 May 2021

Accepted 6 May 2021

Keywords:

Measles

Childbearing age

Neonatal measles

Postexposure prophylaxis

ABSTRACT

Japan has maintained measles elimination status since 2015. However, sporadic outbreaks of measles have been continuously reported. Here, we report a case of a measles-infected postpartum mother and infant in Japan. A 28-year-old Japanese woman, who had previously received a dose of the measles vaccination, experienced fever 5 days postpartum. Subsequently, a maculopapular rash appeared, and she was diagnosed with measles. Moreover, her baby developed a fever and maculopapular rash on the 13th day of life, 2 days after postexposure prophylaxis with intravenous immunoglobulin, and was also diagnosed with measles. Both showed full recovery. This case suggests that measles can still be a threat in a measles-eliminated country, and the administration of two doses of measles vaccination to women prior to childbearing age is crucial to protect newborns from measles.

© 2021 The Author(s). Published by Elsevier Ltd. This is an open access article under the CC BY-NC-ND license (<http://creativecommons.org/licenses/by-nc-nd/4.0/>).

Introduction

Measles is a highly contagious viral disease that has been targeted for eradication through vaccination programs. Globally, the vast majority of cases occur in countries with weak healthcare systems, and measles remains the leading cause of mortality among young children [1]. In 2015, the Measles Regional Verification Commission in the Western Pacific Region verified that Japan had eliminated measles [2]. However, cases have been continuously reported in Japan, with 1377 reported measles cases from 2016 through 2019 [3].

We report two related measles cases: a woman with only a single-dose measles vaccination history who developed measles 5 days postpartum and her newborn who developed measles despite subsequent postexposure prophylaxis with immunoglobulin.

Case report

A 28-year-old woman with no significant medical history gave birth via Caesarean section at a maternity hospital 10 days prior to admission to our hospital. She was discharged from the maternity hospital after 5 days. Eventually, she began to develop a persistent

fever with subsequent cough, nasal discharge, and sore throat. She noticed a facial rash and visited the emergency department of our hospital. Her vital signs on admission were as follows: blood pressure, 118/70 mmHg; heart rate, 115 beats per minute; respiratory rate, 28 breaths per minute; oxygen saturation on room air, 97 %; and temperature, 39.4 °C. Physical examination revealed Koplik spots on her buccal mucosa and a maculopapular rash that spread across her face, trunk, and extremities (Fig. 1). Chest X-ray did not show any sign of pneumonia. She had been tested for rubella but not for measles during pregnancy. Measles was suspected on the basis of her symptoms and characteristic skin rash, and she was admitted to the negative pressure room at our hospital. Polymerase chain reaction (PCR) tests results from a throat swab and urine and blood specimens were positive for measles. The genotype of measles virus was determined as B3. Serological tests for measles using enzyme immunoassay were also conducted on hospital day 2, and IgM (titer 8.03; positive ≥ 1.21) and IgG (titer 12.0; positive ≥ 4.0) antibodies against measles were detected. Additional history obtained by the infectious diseases team revealed that until just before the birth, she had frequently visited a hospital where a measles outbreak had occurred. Her fever and rash gradually improved after admission. She showed full recovery and was discharged on hospital day 7.

As postexposure prophylaxis, we administered a measles vaccine to her husband on hospital day 3 as his measles vaccination history was unknown. In addition, we administered intravenous immunoglobulin to her 11-day-old daughter on the same day.

* Corresponding author at: Department of Infectious Diseases, Japanese Red Cross Narita Hospital, 90-1, Iida-cho, Narita, Chiba, 286-8523, Japan.

E-mail address: Hase.ryota@kameda.jp (R. Hase).

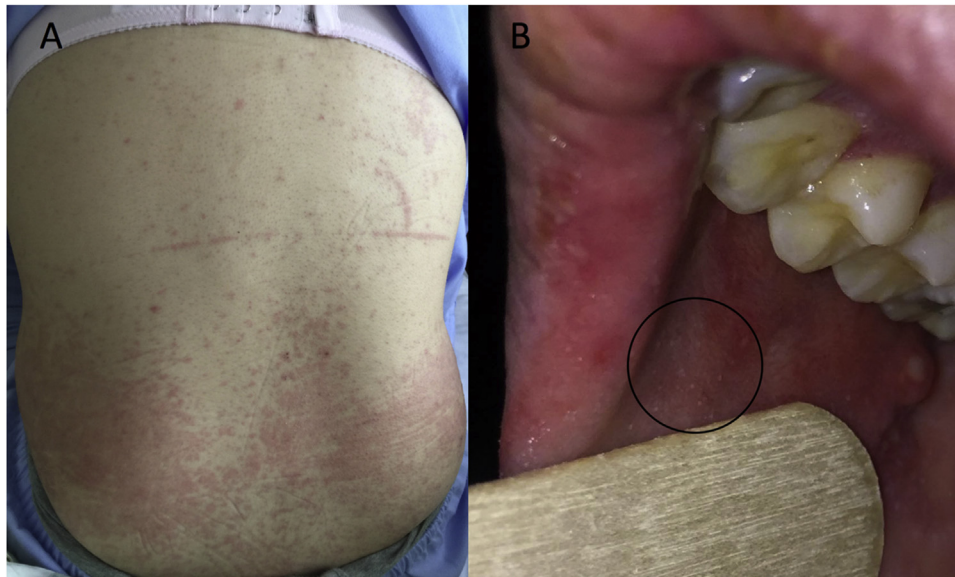


Fig. 1. A. Maculopapular rashes on the patient's skin; B. Koplik spots on her buccal mucosa.

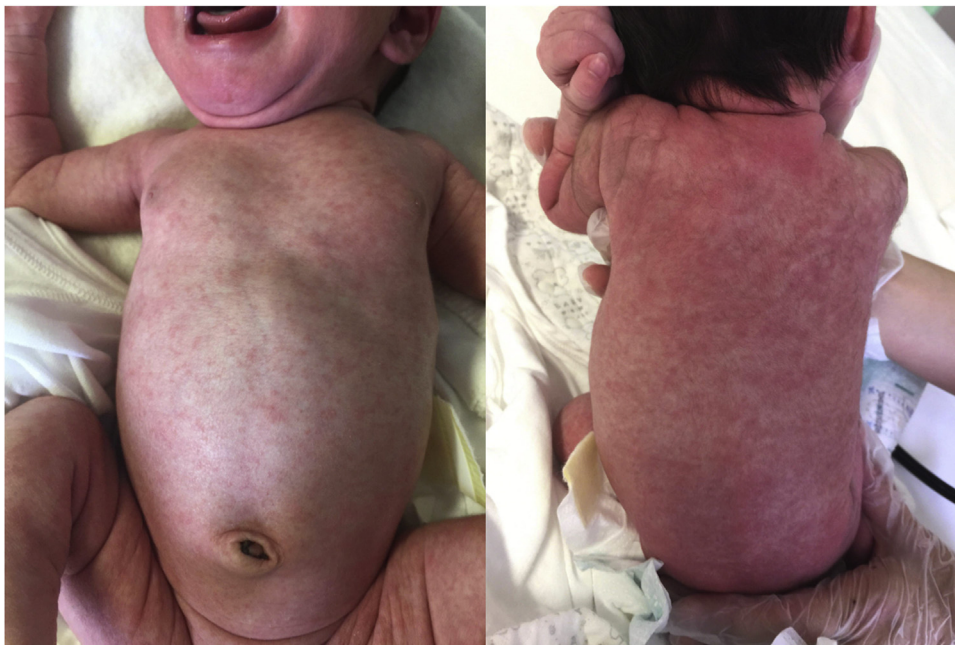

Fig. 2. Maculopapular rashes all over the infant.

However, 2 days later, the infant developed a fever as well as a rash that spread from her face to the trunk of her body (Fig. 2). Subsequently, she was diagnosed with neonatal measles after positive confirmation by PCR analysis of her throat swab and urine and blood specimens. Her chest X-ray showed signs of pneumonia. She developed respiratory distress and was transferred to another hospital for further treatment. Eventually, she showed complete recovery and was discharged without any further complications after 10 days of inpatient treatment. We also offered measles vaccine or serologic testing to 10 members of the hospital staff and five patients who were exposed to the index patient in the ER. The local health department followed up approximately 150 people, including some newborns and pregnant women who might have

had contact with the index patient. No secondary measles case was identified during the follow-up period.

Discussion

This case demonstrates the importance of two doses of measles vaccine for women of childbearing age and the need for all healthcare providers to have measles immunity even in a measles-eliminated country.

One should be cautious about measles even in a measles-eliminated country because cases arriving from other countries may easily cause outbreaks. Measles elimination is defined by the World Health Organization as the absence of endemic measles

virus transmission in a defined geographic area (e.g., region or country) for at least 12 months in the presence of a verified well-performing surveillance system [4]. In Japan, a case of the endemic measles virus genotype D5 has not been reported since May 2010 and has been verified as “eliminated” in 2015 [5]. The genotype of the measles virus in our case was B3, which used to be endemic only to the sub-Saharan African countries in the past but has recently been associated with outbreaks in all six WHO regions [6].

Although a single dose of the measles vaccination can prevent approximately 92 % of infections [7], two doses can prevent >99 % [8], which illustrates the insufficiency of a single-dose measles vaccination. The measles vaccine is a live vaccine and should not be administered to pregnant women; thus, women of childbearing age should be assessed for measles immunity. Moreover, pregnant women with measles are at increased risk of morbidity and mortality [9]. In Japan, a two-dose measles vaccination schedule for children at 1 and 5–6 years of age has been implemented since 2006, and a 5-year second-dose catch-up program was initiated for children 13–16-years-old in April 2008 [10]. Therefore, the majority of people born before 1990, such as our patient, do not have the opportunity to receive the second dose. Catch-up vaccination should be offered to people in this age group.

In this case, the baby’s rash developed on the 13th day of life, so it did not fulfill the classical definition of congenital measles, which is defined by the appearance of a skin rash within 10 days of birth⁸. However, the shortest time between the appearance of a rash in the index measles patient and that in the exposed person is now considered to be 7 days [11]. In the present case, the time of appearance of a rash between the mother and the baby was only 4 days, which theoretically suggests congenital measles rather than postnatally acquired measles.

Despite the large number of exposed individuals, the fact that no secondary infections occurred other than the neonate may be related to the single dose of measles vaccine that the index patient had previously received and the appropriate postexposure prophylaxis. A previous report showed that patients with measles who had received a single measles vaccination dose were approximately four times less infectious than unvaccinated patients with measles [12].

In conclusion, we encountered cases of postpartum and neonatal measles despite postexposure prophylaxis. Administering two doses of measles vaccination in advance to women of childbearing age is crucial to protect newborns from measles.

Conflicts of interest

The authors report no declarations of interest.

Sources of funding

None.

Consent

Written informed consent was obtained from the patient for publication of this case report and accompanying images. A copy of the written consent is available for review by the Editor-in-Chief of this journal on request.

Ethical approval

Not applicable.

Author contribution

Haruki Mito: Writing - original draft, Patient care.
 Ryota Hase: Writing - review & editing, Patient care, Supervision.
 Nozomu Oshima: Writing - review, Patient care.
 Hiroyuki Ikeda: Writing - review, Patient care.
 All authors approved the final manuscript.

References

- [1] Global measles mortality, 2000–2008. *MMWR Morb Mortal Wkly Rep* 2009;58 (December (47)):1321–6.
- [2] WHO. Brunei Darussalam, Cambodia, Japan verified as achieving measles elimination. [Internet] [cited 8 Mar 2021]. Available from: <https://www.who.int/westernpacific/news/detail/27-03-2015-brunei-darussalam-cambodia-japan-verified-as-achieving-measles-elimination>.
- [3] NIID. National epidemiological surveillance of infectious disease annual surveillance data. [Internet] [cited 8 Mar 2021]. Available from. 2016. <https://www.niid.go.jp/niid/ja/hassei/1838-measles-sokuhou-rireki.html>.
- [4] WHO. Regional Office for the Western Pacific. Measles elimination field guide. Manila: WHO Regional Office for the Western Pacific; 2013. <https://apps.who.int/iris/handle/10665/207664>.
- [5] NIID. Measles in Japan, as of March 2015. *Infect Agents Surveill Rep* 2015;36 (April):51–3.
- [6] Rota PA, Moss WJ, Takeda M, de Swart RL, Thompson KM, Goodson JL. Measles. *Nat Rev Dis Primers* 2016;14(July (2)):16049.
- [7] Uzicanin A, Zimmerman L. Field effectiveness of live attenuated measles-containing vaccines: a review of published literature. *J Infect Dis* 2011;204(July (1)):S133–48.
- [8] Yeung LF, Lurie P, Dayan G, et al. A limited measles outbreak in a highly vaccinated US boarding school. *Pediatrics* 2005;116(December (6)):1287–91.
- [9] Ogbuanu S, Zeko S, Chu CM, et al. Maternal, fetal, and neonatal outcomes associated with measles during pregnancy: Namibia, 2009–2010. *Clin Infect Dis* 2014;58(April (8)):1086–92.
- [10] Inaida S, Matsuno S, Kobune F. Measles elimination and immunization: national surveillance trends in Japan, 2008–2015. *Epidemiol Infect* 2017;145 (August (11)):2374–81.
- [11] Gershon AA, Marin M, Seward JF. Varicella, measles, and mumps. In: Wilson CB, editor. *Remington and Klein’s infectious diseases of the fetus and newborn infant*. 8th ed. Philadelphia: Elsevier Inc.; 2016. p. 675–723.
- [12] Gastanaduy PA, Funk S, Lopman BA, et al. Factors associated with measles transmission in the United States during the postelimination era. *JAMA Pediatr* 2020;174(January (1)):56–62.