



Disseminated *Neisseria gonorrhoea* of the wrist

Steven Douedi^{a,*}, Jaraad Dattadeen^a, Arda Akoluk^a, Edward Liu^b

^a Department of Medicine, Jersey Shore University Medical Center, Hackensack Meridian Health, Neptune, NJ 07753, United States

^b Department of Infectious Disease, Jersey Shore University Medical Center, Hackensack Meridian Health, Neptune, NJ 07753, United States



ARTICLE INFO

Article history:

Received 2 April 2020

Received in revised form 2 April 2020

Accepted 2 April 2020

Keywords:

Neisseria gonorrhoeae

Disseminated

Infection

Septic arthritis

Joint pain

Bacteremia

ABSTRACT

Disseminated gonococcal infection (DGI) is seen in about 0.5–3% of patients with *Neisseria gonorrhoeae*. Patients with DGI present with mucosal involvement, septic arthritis and sometimes bacteremia. We present a case of a 62-year-old female with a history of HIV and rheumatoid arthritis admitted with DGI and septic arthritis of the wrist without mucosal involvement or systemic symptoms. The patient underwent incision and drainage with arthrotomy of the right wrist by hand surgery and received a 2-week course of intravenous ceftriaxone. After surgery and initiation of antibiotic treatment, there was marked improvement of her symptoms and she remains asymptomatic at follow-up.

© 2020 The Author(s). Published by Elsevier Ltd. This is an open access article under the CC BY-NC-ND license (<http://creativecommons.org/licenses/by-nc-nd/4.0/>).

Introduction

Neisseria gonorrhoeae is a gram negative, diplococci commonly infecting mucosal surfaces including the endocervix, urethra, and pharynx [1]. *N. gonorrhoeae* is the second most common cause of sexually transmitted diseases in North America especially seen in sexually active young adults [2]. According to the Center for Disease Control (CDC), the incidence of *N. gonorrhoeae* has increased by 63 % from 2014 to 2018 in North America [3]. While *N. gonorrhoeae* usually causes mucosal infections such as pharyngitis, urethritis or cervicitis, it can cause severe infections such as salpingitis and pelvic inflammatory disease in women and septic arthritis, bacteremia, and even death in both men and women [1]. Disseminated gonococcal infection (DGI) is seen in about 0.5–3% of patients with *N. gonorrhoeae* and skin involvement is present in 40 % of those cases [4].

Case presentation

A 62-year-old female with a medical history of HIV on emtricitabine-rilpivirine-tenofovir 200–25–25 milligrams oral daily (last CD4 count 547 and undetectable viral load one month prior to this visit) and rheumatoid arthritis presents with right hand and wrist pain and swelling for the past 3 days. The patient stated the pain began suddenly and was constant, throbbing and sharp, and graded a 10 out of 10. There were no aggravating or

relieving factors. She went to an urgent care center where she was prescribed pain medications and oral steroids without the relief of her right wrist swelling or pain. The swelling worsened until she could not flex her wrist and had minimal movement of her fingers. The pain progressed and began to radiate up the right forearm which prompted her to go to the emergency department (ED). She denied any urinary frequency, urgency, pain on urination, or vaginal discharge and had no other history of sexually transmitted diseases. She also denied fever or chills, rash, or other joint pain. She is monogamous with her husband of 38 years and has previously tested negative for sexually transmitted infections. Her vital signs were blood pressure of 148/96 mm Hg, heart rate of 90 beats per minute, respiratory rate of 18/min, oxygen saturation of 98 % on room air, and temperature of 98.2 degrees Fahrenheit. A right wrist X-ray was performed showing soft tissue swelling without fracture or dislocation. Laboratory results on admission showed a white blood cell count (WBC) of 18.7 10³/uL (reference range 4.5–11.0 10³/uL), neutrophil count of 89.7 % (reference range 50.0–70.0%), absolute neutrophil count of 16.8 10³/uL (reference range 1.8–8.0 10³/uL), erythrocyte sedimentation rate (ESR) of 12 mm/h (reference range 0–30 mm/h), C-reactive protein (CRP) of 1.53 mg/dL (reference range 0.00 – 0.74 mg/dL), and uric acid level of 5.3 mg/dL (reference range 4.0–8.0 mg/dL). Complete blood count and comprehensive metabolic panel were otherwise unremarkable.

The following day the patient's vitals remained stable however despite pain medications the right wrist pain and swelling continued. She remained afebrile however her WBC count elevated to 24.3 10³/uL. Rheumatology and infectious disease were consulted and suspected possible septic arthritis for which blood

* Corresponding author.

E-mail address: Steven.Douedi@hackensackmeridian.org (S. Douedi).

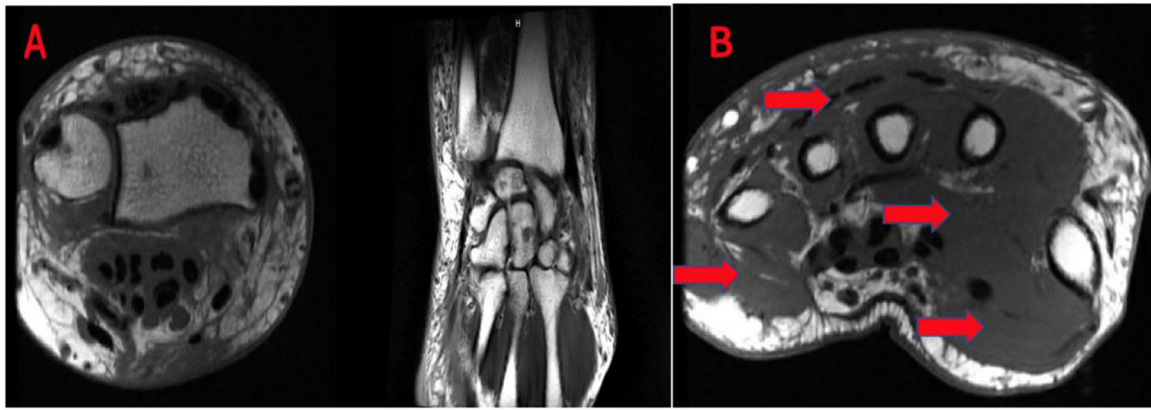


Fig. 1. (A) MRI without contrast of right wrist showing diffuse soft tissue swelling in the saphenous tissues and evidence of edema noted in the deep musculature. There was no evidence of any fluid collection, bony edema, or fractures. (B) MRI of right hand showing diffuse soft tissue swelling.

cultures were drawn and the patient was started on intravenous (IV) vancomycin and IV ceftriaxone. The patient was also started on ibuprofen 800 mg three times daily and colchicine 0.6 mg twice daily by rheumatology. An MRI of the right wrist was also obtained showing diffuse soft tissue swelling in the saphenous tissues and evidence of edema noted in the deep musculature. There was no evidence of any fluid collection, bony edema, or fractures. Tiny subchondral cysts were noted in the scaphoid however the scapholunate and lunotriquetral ligament were intact along with severe degenerative changes (Fig. 1). Blood cultures grew gram negative diplococci and hand surgery was consulted. The patient underwent incision and drainage with arthrotomy and wash out of the right wrist. Blood cultures were positive for *Neisseria gonorrhoeae* and the patient was given oral azithromycin for *Chlamydia* coverage and continued on ceftriaxone for a two-week course. Prior to discharge, repeat blood cultures were negative and urine cultures were negative for both *Neisseria gonorrhoeae* and *Chlamydia trachomatis*. The patient's symptoms significantly improved after surgery and she remained stable and asymptomatic at her 1-week follow-up.

Discussion

Neisseria gonorrhoeae, an infectious obligate human pathogen, has seen a rise in incidence since 2009. In 2018 there were 583,405 cases reported in the US, representing a 5.0 % rise from 2017 alone and further a 18.6 % rise from the previous year [5]. This bacterium is usually spread from person to person via oral, vaginal or anal sex with someone who has the disease. Infected patients can present with urogenital or extra-genital symptoms, though there is a percentage of people who can be asymptomatic [6,7]. The most common presentation in women were dysuria and vaginal discharge, which ranges from white to purulent [6]. Furthermore, a great majority of female patients present with abdominal pain and salpingitis.

Disseminated gonococcal infection (DGI) occurs when the organism enters the bloodstream. It is estimated that about 0.5–3 percent of patients with gonococcal infection present with DGI [8]. The site that is most commonly affected are the joints. DGI can either present as a triad, often referred to as an arthritis-dermatitis syndrome which involves tenosynovitis, skin lesions and migratory polyarthritis, or it can present as a suppurative arthritis, resembling septic arthritis [9]. Blood cultures are positive in less than a third of cases where these symptoms are present [9]. The most common affected joint is the knee although, as seen in our case, the wrist can also be affected [10]. Despite being a classic triad, patient's may not exhibit all

three clinical features to be diagnosed with DGI. As a result, this can lead to misdiagnosis and delay in proper treatment, especially with people who have other diseases that can manifest with joint symptoms, such as rheumatoid arthritis. Fortunately, our patient's blood culture grew the organism and the diagnosis was straight forward.

Treatment of DGI depends on severity of disease and clinical features. Patients with DGI may require longer treatment periods and more aggressive treatment than non-disseminated *Neisseria gonorrhoeae* infections. Treatment is with 1-gram (g) ceftriaxone intravenously daily and should be for at least 1-week duration. Patients who do not improve on antibiotics alone, would likely require surgery and drainage of affected joints [11]. Testing for concomitant *Chlamydia trachomatis* infection should also be performed, negative in the patient presented in this case, as well as coverage for the organism by adding either doxycycline 100 milligrams (mg) twice daily for 1 week or one dose of 1-gram azithromycin [10]. To alleviate pain and avert recurrent joint effusion, the use of nonsteroidal anti-inflammatory drugs can be beneficial.

Conclusion

Gonococcal infection is an uncommon cause of arthritis in sexually active individuals. Absence of mucosal involvement or systemic symptoms should not rule out infectious causes and only one third of patients may have positive cultures. Therefore, it is important that clinicians keep a DGI as a differential in any sexually active person presenting with acute arthritis in the absence of typical symptoms. Early intervention and treatment can help decrease morbidity and mortality in infected individuals.

Author contributions

S.D. and J.D. visualization and writing—original draft, review, and editing. A.A. and E.L. writing—review and editing. All authors have read and agreed to the published version of the manuscript.

Funding statement

This research did not receive any specific grant from funding agencies in the public, commercial, or not-for-profit sectors.

Declaration of Competing Interest

The authors declare no conflict of interest.

Acknowledgments

Not applicable.

References

- [1] Hill SA, Masters TL, Wachter J. Gonorrhea - an evolving disease of the new millennium. *Microb Cell* 2016;3(9):371–89. doi:<http://dx.doi.org/10.15698/mic2016.09.524>.
- [2] Piszczek J, St Jean R, Gonorrhea Khaliq Y. Treatment update for an increasingly resistant organism. *Can Pharm J (Ott)*. 2015;148(2):82–9. doi:<http://dx.doi.org/10.1177/1715163515570111>.
- [3] Centers for Disease Control and Prevention. Sexually transmitted disease surveillance 2010. 2010. . [Accessed March 5, 2020] <http://www.cdc.gov/std/stats10/gonorrhea.htm>.
- [4] Burns JE, Graf EH. The brief case: disseminated *Neisseria gonorrhoeae* in an 18-Year-Old female. *J Clin Microbiol* 2018;56(4). doi:<http://dx.doi.org/10.1128/JCM.00932-17> e00932-e17.
- [5] Sexually transmitted disease surveillance 2018. Atlanta: centers for disease control and prevention. Available: <https://www.cdc.gov/nchhstp/newsroom/2019/2018-STD-surveillance-report.html> [Accessed March 6, 2020].
- [6] McCormack W, Johnson K, Stumacher R, Donner A, Rychwalski R. Clinical spectrum of gonococcal infection in women. *Lancet* 1977;309(8023):1182–5. doi:[http://dx.doi.org/10.1016/s0140-6736\(77\)92720-9](http://dx.doi.org/10.1016/s0140-6736(77)92720-9).
- [7] Barlow D, Phillips I. Gonorrhoea in women. *Lancet* 1978;311(8067):761–4. doi:[http://dx.doi.org/10.1016/s0140-6736\(78\)90870-x](http://dx.doi.org/10.1016/s0140-6736(78)90870-x).
- [8] Barr J, Danielsson D. Septic gonococcal dermatitis. *Br Med J* 1971;1:482. doi:<http://dx.doi.org/10.1136/bmj.1.5747.482>.
- [9] Vidaurrazaga MM, Perlman DC. A case of purulent gonococcal arthritis. *IDCases* 2019;19:e00662. doi:<http://dx.doi.org/10.1016/j.idcr.2019.e00662>.
- [10] Rice PA. Gonococcal arthritis (disseminated gonococcal infection). *Infect Dis Clin North Am* 2005;19(4):853–61. doi:<http://dx.doi.org/10.1016/j.idc.2005.07.003>.
- [11] Lohani S, Nazir S, Tachamo N, Patel N. Disseminated gonococcal infection: an unusual presentation. *J Community Hosp Intern Med Perspect* 2016;6(3):31841. doi:<http://dx.doi.org/10.3402/jchimp.v6.31841>.