

ORAL PRESENTATION

Open Access

Experimental myocarditis in rat can be detected and monitored by cardiac magnetic resonance imaging performed on a clinical 3.0 T scanner

Shunit Rinkevich-Shop^{1*}, Natalie Landa-Rouben¹, Fred Epstein², Tamar Ben-Mordechai¹, Arnon Afek³, Micha S Feinberg¹, Orly Goitein⁴, Eli Konen⁴, Tammar Kushnir⁴, Jonathan Leor¹

From 2011 SCMR/Euro CMR Joint Scientific Sessions
Nice, France. 3-6 February 2011

Background

We aimed to compare cardiac magnetic resonance (CMR) imaging, using a clinical whole body 3T system, with histopathological measurement and 2D echocardiography as a method for the quantitative evaluation of the extent of myocardial involvement and function in a rat model of autoimmune myocarditis.

Methods and results

Male Lewis rats (n=11) were subjected to myosin immunization and developed autoimmune myocarditis. Approximately 3 weeks later, rats with myocarditis

underwent CMR scan and subsequently, histopathological evaluation. Rats with myocarditis showed pericardial thickening, effusion, and LV wall motion abnormalities with septal hypokinesis. Short axis views showed patchy delayed enhancement of epicardial segments, with distribution mainly located within the inferolateral LV wall including the septum. This increased signal/hyperenhancement defines focal areas of myocardial fibrosis/edema and/or necrosis, highly suggestive of inflammation. Additionally, the presence of large pericardial effusion provides supportive evidence for the existence of peri-myocarditis. Indeed, high correlation was found

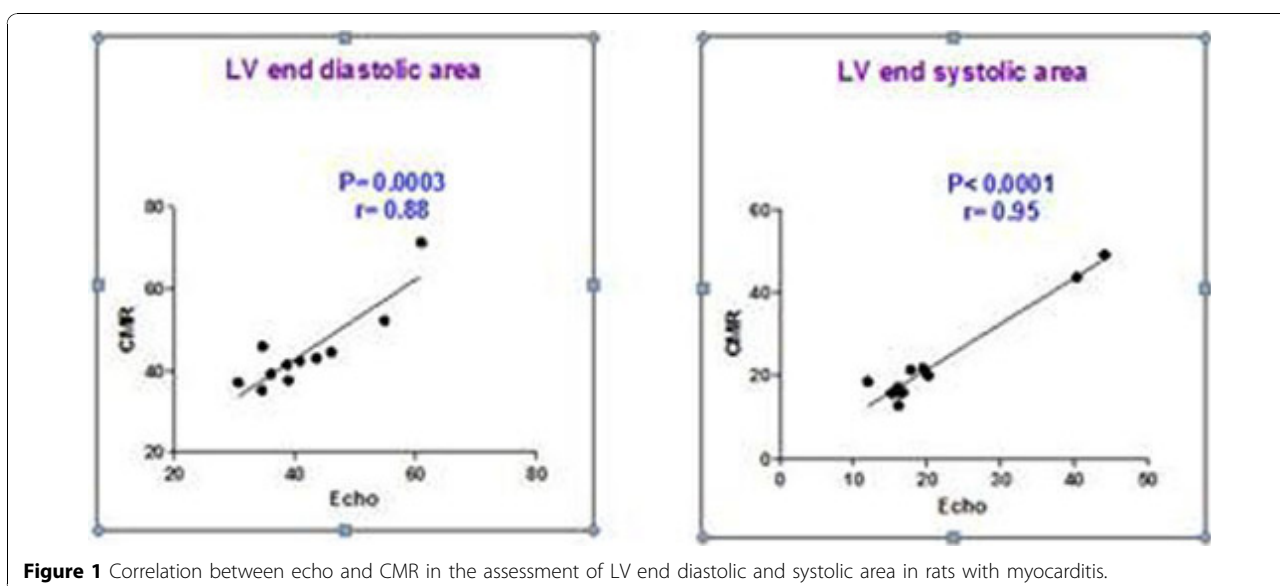


Figure 1 Correlation between echo and CMR in the assessment of LV end diastolic and systolic area in rats with myocarditis.

¹Neufeld Cardiac Research Institute, Tel Aviv University, Tel- Hashomer, Israel
Full list of author information is available at the end of the article

between CMR examination results and histological findings. Furthermore, high correlation was found between CMR examination and echocardiography (Figure 1)

Conclusions

Experimental myocarditis in rat can be detected and monitored by CMR performed on a clinical 3.0 T scanner. The overall advantages of CMR, mostly its high measurement accuracy and reproducibility, make it an ideal technique for monitoring experimental myocarditis and pre-clinical evaluation of novel therapies.

Author details

¹Neufeld Cardiac Research Institute, Tel Aviv University, Tel- Hashomer, Israel.

²Departments of Radiology and Biomedical Engineering, University of Virginia, Virginia, VA, USA. ³Sheba Medical Center, Tel- Hashomer, Israel.

⁴Diagnostic Imaging Department, Sheba Medical Center, Tel- Hashomer, Israel.

Published: 2 February 2011

doi:10.1186/1532-429X-13-S1-O49

Cite this article as: Rinkevich-Shop *et al.*: Experimental myocarditis in rat can be detected and monitored by cardiac magnetic resonance imaging performed on a clinical 3.0 T scanner. *Journal of Cardiovascular Magnetic Resonance* 2011 **13**(Suppl 1):O49.

**Submit your next manuscript to BioMed Central
and take full advantage of:**

- Convenient online submission
- Thorough peer review
- No space constraints or color figure charges
- Immediate publication on acceptance
- Inclusion in PubMed, CAS, Scopus and Google Scholar
- Research which is freely available for redistribution

Submit your manuscript at
www.biomedcentral.com/submit

