

# Percutaneous electrosurgical technique for treatment of subclavian vein occlusion: Application of transcaval techniques



Jason R. Foerst, MD, David Kim, MD, Terrence P. May, MD

*From the Section of Cardiology, Virginia Tech–Carilion School of Medicine, Roanoke, Virginia.*

## Introduction

Occlusion of the subclavian vein is a relatively common complication following permanent pacemaker implants, with an incidence of up to 10%.<sup>1,2</sup> This rarely manifests clinically, but it becomes a problem when upgrading pacemakers with additional leads. As the population ages the need to reaccess the occluded veins for cardiac resynchronization therapy or defibrillator leads is increasing. These occlusions can be frequently crossed with hydrophilic wires; however, there is no standard for treatment of wire-resistant lesions. Many of these patients will undergo contralateral device implants and risky laser lead extractions or epicardial leads. We present a safe, novel strategy for crossing chronically occluded subclavian veins with existing pacemaker leads using an angled stiff-tipped 0.014-in wire charged with electrocautery, enabling successful coronary sinus lead implant.

## Case report

### Case 1

A 63-year-old man with history of ischemic cardiomyopathy with ejection fraction 15%, chronically occluded right coronary artery and left anterior descending artery without revascularization, paroxysmal atrial fibrillation, new left bundle branch block with QRS duration 158 ms, and NYHA class III dyspnea presented for elective biventricular pacemaker upgrade. He had a prior attempt at a biventricular pacemaker upgrade that was unsuccessful owing to a totally occluded left subclavian vein. He was considered for an epicardial lead but was not an ideal candidate owing to his body habitus. A venogram was performed demonstrating a 1.6-cm occlusion of the left subclavian vein. Following opening of the left subclavian pocket, a 5F sheath was advanced to near the occlusion

---

**KEYWORDS** Electrosurgery; Subclavian vein occlusion; Biventricular pacemaker; Vascular; Pacemaker  
(Heart Rhythm Case Reports 2017;3:551–554)

---

Dr Foerst is a consultant for Medtronic and on the speaker's bureau for Edwards. **Address reprint requests and correspondence:** Dr Jason Foerst, Virginia Tech–Carilion School of Medicine, 2001 Crystal Springs Ave, Roanoke, VA 24014. E-mail address: [JRFoerst@CarilionClinic.org](mailto:JRFoerst@CarilionClinic.org).

and used as a platform. In a mother-daughter fashion an Atrato XS20 (Asahi, Aichi, Japan) 0.014-in wire was advanced to the occlusion through a 0.035-in PiggyBack converter wire (Vascular Solutions, Minneapolis, MN) through a 4F angled glide catheter (Figure 1). Next, the most proximal end of the wire was connected to an electrocautery pencil (Medtronic, Minneapolis, MN) with a hemostat and the wire was advanced through the occlusion along the existing lead while activating the cut mode on the pencil at 30 W. The wire initially looked like it may have traveled extravascularly, so it was pulled back to the occlusion and readvanced into the inferior vena cava (IVC). There was no contrast extravasation or hemodynamic consequence. The PiggyBack converter wire and subsequently the angled glide catheter were advanced over the Atrato across the occlusion. The PiggyBack wire was then exchanged for a Worley wire (Merit Medical, South Jordan, UT), which advanced easily to the IVC, and a venoplasty of the occlusion was performed with a Maverick 5.0 × 40-mm balloon (Boston Scientific, Minneapolis, MN) at a pressure of 10 atm for 60 seconds. Finally, a Worley sheath (Merit Medical, South Jordan, UT) was easily advanced into the right atrium and a coronary sinus lead was implanted, with successful upgrade (Figure 2).


### Case 2

An 88-year-old man with an ischemic cardiomyopathy status post coronary artery bypass grafting, complete atrioventricular block treated with dual-chamber pacemaker implant, permanent atrial fibrillation, and NYHA class III dyspnea presented for elective biventricular pacemaker upgrade. He previously had an attempt at biventricular pacemaker upgrade that was stopped owing to an occlusion of the left subclavian vein. He was considered for an epicardial lead but was felt to be too high risk. The percutaneous implant was reconsidered. A venogram was performed demonstrating a 2-cm occlusion of the left subclavian vein with a very large collateral vein arising just proximal to the occlusion (Figure 3A). Numerous unsuccessful attempts were made to open the occlusion using wire escalation with a Whisper wire,

## KEY TEACHING POINTS

- Subclavian venous occlusion is relatively common following permanent pacemaker implant (10%–12%).
- Several techniques for crossing these occlusions have been described but are limited by requiring either surgical back-up or expensive devices and may require extensive training.
- Crossing of the chronically occluded vein for device upgrades can be done safely with standard equipment utilizing a simple percutaneous, electrosurgical strategy with a 0.014-in stiff-tipped wire and venoplasty.

Pilot 50, Pilot 150 (Abbott Vascular, Santa Clara, CA), and a stiff angled glide wire, all of which were supported by an angled glide catheter (Terumo, Somerset, NJ). Finally, we even failed crossing using the back end of the stiff angled glide supported by an angled glide catheter. At this point an 0.014-in Astato XS20 wire supported by a 4F angled glide catheter was advanced to the occlusion and angled parallel to the previously implanted pacemaker wires. Next, the proximal end of the wire was connected to an electrocautery pencil with a hemostat. The wire was advanced while activating cut mode on the pencil at 50 W for about 1 second. The first push allowed the wire to penetrate the proximal cap, though it became lodged in the fibrotic occlusion. Then a second 1-second activation of cut mode and wire pressure allowed the wire to traverse the remainder of the occlusion and freely pass into the superior vena cava and right heart. An 0.35-in PiggyBack wire converter was then advanced over the Astato wire and the glide catheter was removed. Next, a 5.0 × 40-mm Mustang balloon



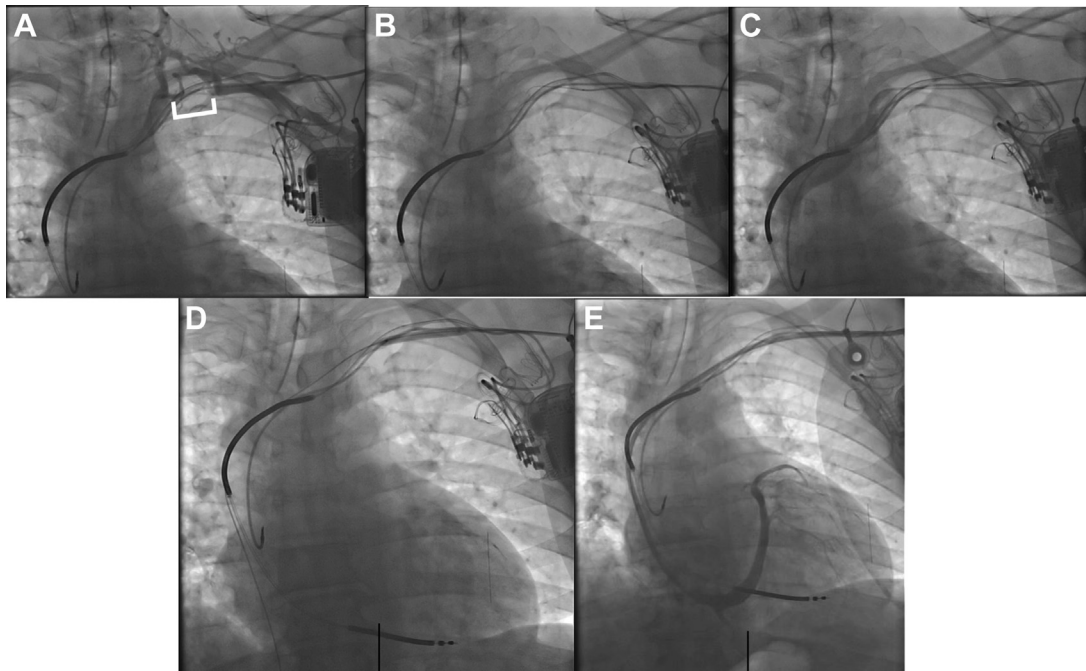
**Figure 1** Percutaneous electrosurgical technique for crossing the subclavian vein chronic total occlusion. An Astato XS 20 0.014-in (Asahi, Aichi, Japan) wire is inserted through a 4F angled glide wire to the occlusion; it is important to be sure only the tip of the wire is exposed (*white arrow*). In preparation it is imperative to clamp the electrocautery pencil to the proximal-most end of the wire (*red circle*) and keep all metal and wet gauze off the wire to prevent dispersion of charge. The wire is advanced while applying 30–50 W of “cut” energy.

(Boston Scientific, Minneapolis, MN) was easily advanced across the chronic total occlusion and venoplasty performed at 10 atm. Finally, a 9F Worley sheath (Merit Medical, South Jordan, UT) was easily advanced across the previous occluded segment and a coronary sinus lead was implanted, with successful pacemaker upgrade (*Figure 3B and C*).

## Discussion

Subclavian vein occlusion is commonly discovered during pacemaker upgrades and poses unique challenges when standard wiring techniques fail. Most of the time these lesions can be negotiated with a hydrophilic wire; however, occasionally these lesions are refractory to standard wiring techniques.<sup>3</sup> Techniques for dealing with wire-refractory occluded subclavian veins in patients with ipsilateral pacemaker devices have been described, including accessing proximal to the occlusion, puncturing with a 75-cm 21 gauge needle, and use of an excimer laser.<sup>4–6</sup>

We describe a novel technique utilizing an electrosurgical technique similar to standard transcaval crossing for accessing the aorta from the IVC to deliver large sheaths for transcatheter aortic valves or left ventricular support devices.<sup>7</sup> This technique is simple, is cost-effective, and does not require surgical back-up. The Astato XS20 0.014-in wire is normally used in the peripheral space and was chosen due to the 20-g tip stiffness, though other stiff-tipped wires used for chronic total occlusions in the coronary space could be used as well. In order to advance the electrified guidewire, we use the continuous duty cycle electrosurgery setting (“cut mode”) to vaporize tissue rather than the interrupted duty cycle (“coagulate mode”) to heat tissue. The key to success is to insulate the 0.014-in stiff wire to deliver the bulk of the electrocautery charge to the tip of the wire using short bursts of cut mode energy under steady pressure with the tip of the wire angled parallel to the existing pacemaker leads. In preparation, it is imperative to clamp the electrocautery pencil to the proximal-most end of the wire (*Figure 2*) and keep all metal and wet gauze off the wire to prevent dispersion of charge. In these cases, the occluded segments were about 2 cm and it took 2 bursts of 50 W on cut mode to penetrate all the way through on 1 case. We chose the 50 W setting based on the success of the transcaval technique; however, we were also able to cross with a lower 30 W setting in 1 case. Crossing longer lesions may be limited by buildup of char on the wire. Of note, the original transcaval technique utilizes the PiggyBack converter wire to insulate the 0.014-in wire during cut mode; however, we accomplished similar insulation with the 4 F angled glide catheter in 1 case. There certainly exists some risk for the wire to perforate the vessel; however, the wire is small and unlikely to result in any harm in the venous system. Confirming wire position in orthogonal angles is useful. The electrical current is preferentially delivered to tissue, so the insulated leads should remain intact. Once the wire has negotiated



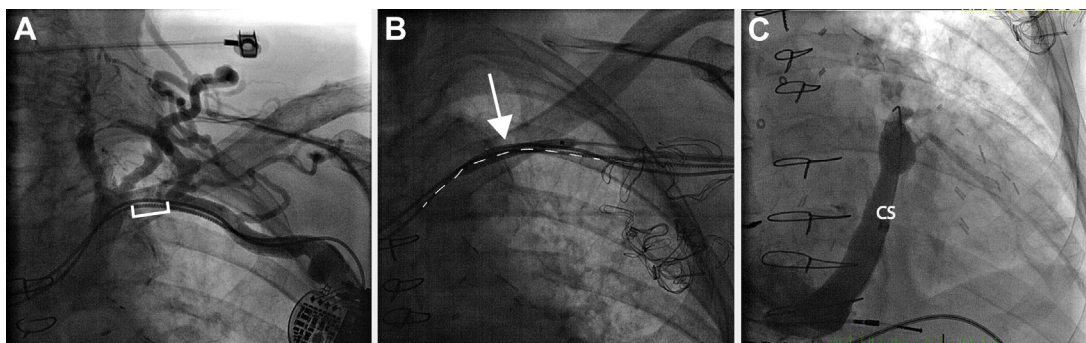
**Figure 2** Case 1. **A:** Chronic total occlusion (*white bars*) of the left subclavian vein at pacemaker lead site with prominent collaterals. **B:** Atrato XS 20 wire advanced across occlusion angled along the existing leads. **C:** Glide catheter advanced across lesion with contrast injection confirming flow into superior vena cava. **D:** Venoplasty (*white arrow*) of the subclavian vein occlusion over a Worley wire directed into the inferior vena cava. **E:** Easy traversal of sheath, allowing coronary sinus access and coronary sinus lead implant.

the occlusion, it should easily pass into the right heart, confirming a “true lumen.” Once the 0.014-in wire has crossed, a 0.035-in PiggyBack converter wire is a useful tool that slides over the 0.014-in wire and allows for delivery of a peripheral balloon for venoplasty. If the balloon will not cross, then a 0.035-in microcatheter (eg, Navicross; Terumo, Somerset, NJ) can be used to cross and upgrade to a stiffer wire or can try to pre-dilate with smaller coronary balloons.

When compared to the largest published series for treatment of wire-resistant venous occlusions using the excimer laser, this technique offers a more cost-effective solution. The excimer laser requires special training and expertise, whereas the electrosurgical technique utilizes the

electrocautery pencil already on the table for a pacemaker upgrade. A similar strategy has been reported using the PowerWire (Baylis Medical, Montreal, Quebec) for opening central vein occlusions; however, the cost of the 0.035-in wire is \$1500, not accounting for the generator, and there are potential safety concerns of crossing with a 0.035-in wire.<sup>8,9</sup>

There are several descriptions of using the “inside-out” technique for crossing chronically occluded veins; however, these strategies are more complicated and have limitations based on the patient’s vascular anatomy and body habitus; carry the risk of pneumothorax and puncture of surrounding structures; and have limited data for lead revisions.<sup>10,11</sup>



**Figure 3** Case 2. **A:** Chronic total occlusion (*white bars*) of the left subclavian vein at pacemaker lead site with a prominent collateral. **B:** Balloon venoplasty (*white arrow*) following percutaneous electrosurgical traversal of the chronic total occlusion using the existing pacemaker leads to guide the wire trajectory (*white dotted lines*). **C:** Easy traversal of sheath, allowing coronary sinus (CS) access and subsequent CS lead implant.

## Conclusion

Percutaneous electrosurgical crossing with a stiff-tipped 0.014-in wire is a useful strategy for negotiating wire-resistant subclavian vein occlusions for patients undergoing ipsilateral device upgrades.

## References

1. Haghjoo M, Nikoo MH, Fazelifar AF, Alizadeh A, Emkanjoo Z, Sadr-Ameli MA. Predictors of venous obstruction following pacemaker or implantable cardioverter-defibrillator implantation: a contrast venographic study on 100 patients admitted for generator change, lead revision, or device upgrade. *Europace* 2007;9:328–332.
2. Rozmus G, Daubert JP, Huang DT, Rosero S, Hall B, Francis C. Venous thrombosis and stenosis after implantation of pacemakers and defibrillators. *J Interv Card Electrophysiol* 2005;13:9–19.
3. Worley SJ, Gohn DC, Pulliam RW, Raifsnider MA, Ebersole BI, Tuzi J. Subclavian venoplasty by the implanting physicians in 373 patients over 11 years. *Heart Rhythm* 2011;8:526–533.
4. Bernstein NE, Aizer A, Chinitz LA. Use of a lateral infraclavicular puncture to obtain proximal venous access with occluded subclavian/axillary venous systems for cardiac rhythm devices. *Pacing Clin Electrophysiol* 2014;37:1017–1022.
5. Miyayama S, Minami T, Kozaka K, Ushiogi Y. Small needle puncture of a central venous occlusion in a hemodialysis patient that could not be traversed by a conventional technique. *Cardiovasc Interv Ther* 2014;29:261–265.
6. Worley SJ, Gohn DC, Pulliam RW. Excimer laser to open refractory subclavian occlusion in 12 consecutive patients. *Heart Rhythm* 2010;7:634–638.
7. Greenbaum AB, Babaliaros VC, Chen MY, et al. Transcaval access and closure for transcatheter aortic valve replacement: a prospective investigation. *J Am Coll Cardiol* 2017;69:511–521.
8. Baerlocher MO, Asch MR, Myers A. Successful recanalization of a longstanding complete left subclavian vein occlusion by radiofrequency perforation with use of a radiofrequency guide wire. *J Vasc Interv Radiol* 2006;17:1703–1706.
9. Guimaraes M, Schonholz C, Hannegan C, Anderson MB, Shi J, Selby B Jr. Radiofrequency wire for the recanalization of central vein occlusions that have failed conventional endovascular techniques. *J Vasc Interv Radiol* 2012;23:1016–1021.
10. Burri H. Overcoming the challenge of venous occlusion for lead implantation. *Indian Pacing Electrophysiol J* 2015;15:110–112.
11. Elayi CS, Allen CL, Leung S, et al. Inside-out access: a new method of lead placement for patients with central venous occlusions. *Heart Rhythm* 2011;8:851–857.