



# Osteonecrosis of the Femoral Head: Update Article

## Osteonecrose da cabeça femoral: Artigo de atualização

Helder de Souza Miyahara<sup>1</sup> Lucas Verissimo Ranzoni<sup>1</sup> Leandro Ejnisman<sup>1</sup>   
 José Ricardo Negreiros Vicente<sup>1</sup> Alberto Tesconi Croci<sup>1</sup> Henrique Melo de Campos Gurgel<sup>1</sup>

<sup>1</sup>Hip Group, Instituto de Ortopedia e Traumatologia, Hospital das Clínicas, Faculdade de Medicina, Universidade de São Paulo (HCFMUSP), São Paulo, SP, Brazil

Rev Bras Ortop 2022;57(3):351–359.

Address for correspondence Helder de Souza Miyahara, Assistant Physician, Instituto de Ortopedia e Traumatologia, Hospital das Clínicas, Faculdade de Medicina, Universidade de São Paulo (HCFMUSP), Rua Ovídio Pires de Campos, 333, São Paulo, SP, 05403-010, Brazil (e-mail: helder\_miyahara@hotmail.com).

### Abstract

Among the pathologies that affect the hip joint, osteonecrosis of the femoral head (ONFH) is probably the most intriguing and challenging. It consists of a multifactorial disease with a highly-variable spectrum in its clinical presentation. It has a devastating effect, due to disabling painful conditions, both for usual activities and sports. Given the huge range of risk factors, such as prolonged use of corticosteroids (especially in cases of rheumatologic diseases), trauma sequelae, sickle cell anemia, HIV, alcoholism, smoking, blood dyscrasias, and several other diseases that compromise the blood supply to the femoral head, ONFH has a varied clinical presentation and prognosis, which makes it difficult to determine a specific treatment, especially in cases in which chondral involvement has not yet occurred and the hip joint is still preserved. These are the main factors found in the literature that determine the classifications of this pathology. The range of treatments includes several options for cases in which an attempt is made to save the joint: conservative treatment, traditional decompression and/or combined with some type of adjuvant treatment (homologous grafting, synthetic grafting, vascularized grafts, tantalum screws, and bone marrow aspirate injection), and, for cases in which there is already a subchondral fracture and/or collapse of the femoral head and/or a reduction in the joint space, femoral osteotomies or total hip arthroplasty are commonly performed.

### Keywords

- ▶ femur head/abnormalities
- ▶ osteonecrosis
- ▶ hip decompression
- ▶ hip prosthesis
- ▶ graft

### Resumo

Entre as patologias que acometem a articulação coxofemoral, a osteonecrose da cabeça femoral (ONCF) é provavelmente a mais intrigante e desafiadora. Consiste em uma doença multifatorial, com um espectro muito variável em sua apresentação clínica. Tem efeito devastador, devido a quadros dolorosos incapacitantes tanto para atividades habituais quanto esportivas. Dada a gama enorme de fatores de risco, tais como uso prolongado de corticoides (principalmente em casos de doenças reumatológicas), sequelas de trauma, anemia falciforme, HIV, etilismo, tabagismo, discrasias sanguíneas, e várias outras doenças que comprometem a irrigação sanguínea da cabeça femoral, a ONCF tem apresentação

*Work developed in the Instituto de Ortopedia e Traumatologia, Hospital das Clínicas, Faculdade de Medicina, Universidade de São Paulo (HCFMUSP), São Paulo, SP, Brazil.*

received  
November 27, 2020  
accepted after revision  
May 18, 2021

DOI <https://doi.org/10.1055/s-0041-1736308>.  
ISSN 0102-3616.

© 2022. Sociedade Brasileira de Ortopedia e Traumatologia. All rights reserved.  
This is an open access article published by Thieme under the terms of the Creative Commons Attribution-NonDerivative-NonCommercial-License, permitting copying and reproduction so long as the original work is given appropriate credit. Contents may not be used for commercial purposes, or adapted, remixed, transformed or built upon. (<https://creativecommons.org/licenses/by-nc-nd/4.0/>)  
Thieme Revinter Publicações Ltda., Rua do Matoso 170, Rio de Janeiro, RJ, CEP 20270-135, Brazil

**Palavras-chave**

- ▶ cabeça do fêmur/anormalidades
- ▶ osteonecrose
- ▶ descompressão do quadril
- ▶ prótese de quadril
- ▶ enxerto

clínica e prognósticos bem variados, o que dificulta a determinação de um tratamento específico, especialmente em casos nos quais ainda não houve acometimento condral e a articulação do quadril ainda se mantém preservada, sendo estes os principais fatores encontrados na literatura que determinam as classificações desta patologia. No leque de tratamentos, encontramos diversas opções para os casos em que se tenta salvar a articulação: tratamento conservador, descompressão simples e/ou associada a algum tipo de tratamento adjuvante (enxertia homóloga, enxertia sintética, enxertos vascularizados, parafusos de tântalo, e injeção de aspirado de medula óssea), e, para casos nos quais já há fratura subcondral e/ou colapso da cabeça femoral e/ou diminuição do espaço articular, reserva-se, comumente, a realização de osteotomias femorais ou artroplastia total do quadril.

**Introduction**

Osteonecrosis of the femoral head (ONFH) usually affects young patients between the third and fifth decades of life.<sup>1</sup> The initial clinical condition is usually insidious, with the patient reporting a pattern of joint pain (inguinal, in the groin region) associated or not with sports activities, with an occasional sudden increase in pain, probably related to the stage of greater ischemia and increased bone edema of the proximal femur,<sup>2</sup> which may later evolve to a pattern of improvement over a few months. Occasionally, the patient may have complaints unrelated to the hip joint, such as low back pain, pain in the peritrochanteric region, or in the knees. It is noteworthy that, during the anamnesis, it is of paramount importance to assess the history of previous diseases, drug treatments, and habits and addictions that may be related to ONFH.

In some cases, patients are initially asymptomatic, and are diagnosed with ONFH lesion as a finding of an exam due to another complaint. In more advanced cases, in which there are degenerative changes (cartilage damage, flattening of the femoral head, reduced joint space) and secondary arthrosis, complaints of pain and functional limitation are more important, and the clinical presentation resembles a case of primary coxarthrosis.

The etiology of ONFH comprises a vast series of pathologies that lead to impairment of the microvascular circulation of the femoral head,<sup>3,4</sup> either by mechanical vascular interruption, as in femoral head fractures, femoral neck fractures (especially displaced neck fractures – Garden III or IV – whose syntheses are maintained)<sup>5</sup> or dislocation of the hip joint, in which there is injury to the medial circumflex femoral artery;<sup>6</sup> intravascular occlusion, such as in blood dyscrasias (sickle cell anemia – probably the hematological condition with the fastest clinical evolution,<sup>7,8</sup> hemophilia – causing repeated intraosseous hemorrhages, Von Willebrand disease, factor V Leiden mutation, deficiency of proteins C and S, and polycythemia vera)<sup>9</sup>; extravascular compression, due to accumulation of fat in the bone marrow, such as with the use of corticosteroids,<sup>10,11</sup> in which there may be a replacement of pluripotent cells by fat cells, alteration of bone homeostasis, and damage to osteocytes; and alcohol abuse.<sup>12,13</sup> As for the use of corticosteroids and

alcohol abuse, both have been proven to be dose-dependent, with an increase in the risk with the use of more than 20mg a day of corticosteroids and an almost 18-fold increase in the risk with an intake of more than 1,000 mL a week of alcohol.

Other less common pathologies,<sup>14–19</sup> such as Gaucher disease, Caisson disease, dysbarism from deep water diving, as well as HIV, radiation therapy, pregnancy, smoking and gout can also lead to ONFH. A current study has shown that, in idiopathic cases, acetabular alterations with less coverage of the femoral head may be related to ONFH.<sup>20</sup>

The most common pathologies and factors are reported in detail in ▶ **Table 1**.

**Complementary Exams**

The diagnostic investigation of ONFH usually starts with a plain radiograph in anteroposterior and lateral views of the hip, but these exams may be unaltered in the early stages of the disease. Specific incidences such as the Dunn, Lequesne and Ducroquet profiles may be requested, especially if there are other diagnostic hypotheses.<sup>21</sup> On plain radiographs, the findings can range from unaltered images at very early stages, including sclerosis of the femoral head, to the presence of a subchondral fracture (crescent sign – radiolucency in the subchondral area, best seen in lateral view), and eventual late alterations, such as collapse of the femoral head, joint space narrowing, and degenerative acetabular alterations.

In extremely suspicious cases, with a typical clinical picture, previous diseases and factors associated with ONFH, with normal radiographs, it is mandatory to complete the diagnostic investigation. Currently, the most used test, with better accuracy, and 99% of sensitivity and specificity, is hip magnetic resonance imaging (MRI). In addition to being an excellent diagnostic method, it determines the size and location of the lesion, as well as the presence of bone edema in the proximal femur. The typical findings of necrotic lesion are an area with a “geographic” lesion with hyposignal on T1 and hypersignal on T2. In addition, there is a lesion in double line or double contour on T2, which is considered pathognomonic.

**Table 1** Risk factors and most common diseases associated with osteonecrosis of the femoral head

- Trauma: femoral neck fracture, deviated or not, traumatic hip dislocation, occasionally inter- and subtrochanteric fractures, repetitive strain injury, pediatric patients undergoing intramedullary osteosynthesis with piriform entry
- Corticosteroids
- Alcoholism
- Smoking
- Hyperlipidemia
- Diabetes
- Pancreatitis and steatonecrosis
- Hemoglobinopathies and coagulation disorders: sickle cell anemia, hemophilia, Von Willebrand disease, factor V Leiden mutation, deficiency of proteins C and S, polycythemia vera, elevated serum lipoprotein levels, hyperhomocysteinemia
- Myeloproliferative disorders: Gaucher disease, leukemia
- Caisson disease and other decompression illnesses
- Systemic lupus erythematosus and its consequences: use of corticosteroids and other cytotoxic drugs, as well as vasculitis caused by the disease
- Antiphospholipid syndrome
- Disbarism
- Radiotherapy or chemotherapy
- Gout
- Acetabular anatomical changes
- HIV and its treatment: use of protease inhibitors
- Pregnancy
- Malignant tumors
- Inflammatory bowel disease
- Idiopathic

Computed tomography may be requested to diagnose a subchondral fracture not detected on MRI, and to determine the extent of the lesion, but it is less requested than hip MRI scans.

Before the routine use of MRI, bone scintigraphy with technetium was a widely used test. It is very useful as a means of assessing the involvement of other joints, but its current use, as well as that of the positron-emission tomography (PET), is more restricted.

The imaging exams are shown in ► **Figure 1**.

Depending on the patient's risk factors and diseases, a search for the etiology can be carried out in idiopathic cases, with complementary tests such as complete blood count, coagulogram, coagulation factors, erythrocyte sedimentation rate, C-reactive protein, rheumatoid factor, urine analysis, and tests to screen for other systemic diseases (hematological and infectious diseases), as well as evaluations of other medical specialties for a coordinated follow-up and better patient care.

## Classification

There are several classifications for ONFH, and the ones most commonly used are:<sup>22</sup>

- 1- **Ficat and Arlet:** based on the clinical picture, imaging findings on radiographs and scintigraphy, and pathological findings. It does not use MRI in its classification, and the downside is that it does not predict prognosis nor measures lesion size. It is the most used classification, and the one most cited in the literature.<sup>23</sup>
- 2- **Association Research Circulation Osseus (ARCO) classification:** developed in the 1990s based on the classification of the University of Pennsylvania (Steinberg), it includes the location and size of the lesion, with the percentage of collapse and involvement of the femoral head. An updated review of it was recently published.<sup>13,24</sup>
- 3- **Kerboul:** useful to predict the prognosis, as it involves the measurement of the area of the femoral head injury and its location on plain anteroposterior and lateral radiographs. This classification was extended to measurements in MRIs by Ha et al.<sup>25</sup> In radiographs, angles smaller than 180° had a better prognosis, and those greater than 230°, a worse prognosis. On the MRI, these values changed to 190° and 240°.

► **Table 2** shows the description of the most used classifications.

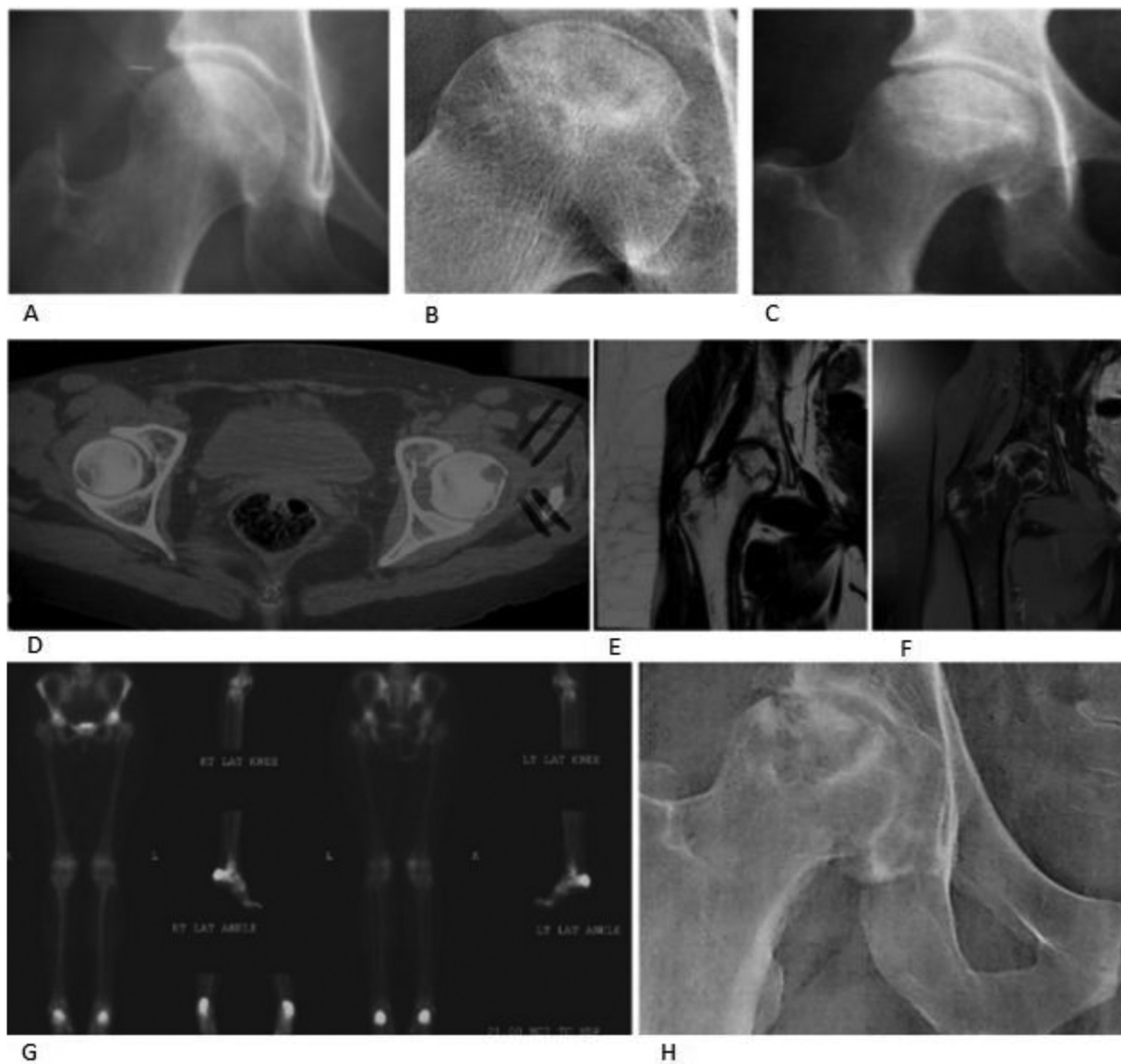
## Treatment

Treatment of ONFH is perhaps the most controversial point involving this pathology.<sup>26,27</sup> Due to numerous peculiarities regarding the etiology and pathophysiology, clinical presentation, and difficulty in defining an exact prognosis, the treatment varies greatly in the literature and, therefore, among hip surgeons, especially in cases in which there is still no involvement of the articular surface and no subchondral fracture in the femoral head.<sup>28-31</sup> In these cases, the following therapeutic options are described:

### 1) Non-surgical treatment

These are measures that encompass conservative treatment, all without significant evidence in the literature regarding prognosis:

- Analgesic medications and use of support for walking and interruption of sports activities according to pain symptoms.
- Physiotherapy activities with muscle strengthening and stretching, as well as treatment with shock waves, electromagnetic stimulation, and hyperbaric oxygen therapy.
  - Shock waves: in early stages, there may be a better response in relation to pain symptoms compared to simple decompression and non-vascularized grafts.<sup>32</sup>
  - Electromagnetic stimulation and hyperbaric chamber: showed encouraging results at early stages, but still without studies with level I of evidence.<sup>33,34</sup>



**Fig. 1** (A) Normal hip radiograph; (B) crescent sign; (C) flattening of the head; (D) tomography with head necrosis; (E, F) resonance with T1- and T2-weighted images with necrosis; (G) bone scintigraphy of the femoral head; (H) secondary degenerative changes.

- Oral medications<sup>35,36</sup> (bisphosphonates, vasodilators, anticoagulants, statins): all with limited statistical support in scientific studies, and none with a recommendation for routine use.
  - Bisphosphonates: in theory, by avoiding bone turnover, they could prevent the collapse of the femoral head. As they have some side effects, such as atypical fracture and osteonecrosis of the jaw, and their use in humans has not been scientifically proven, their use is not routinely indicated.<sup>37,38</sup>
  - Anticoagulants and vasodilators: theoretically, they would be indicated for diseases that cause vascular occlusion and posterior ONFH. There are also no studies that validate its routine use.<sup>39-41</sup>
- Statins: they supposedly have the function of preventing the accumulation of fat in the bone marrow and pre-

venting an increase in intraosseous pressure. However, studies with a higher level of evidence are needed to verify its effectiveness.<sup>42-44</sup>

- Molecular therapy: a recent study<sup>45</sup> with adenovirus associated with anti-mRNA-214, whose importance is to prevent the activation of transcription factor 4, which inhibits the function of the osteoblasts, demonstrated an increase in osteoblastic activity and a decrease in osteoclastic activity, preventing the collapse of the femoral head in mouse models.

## 2) Surgical treatment

- Core decompression: performance of one or multiple perforations of the subchondral bone close to the region of the lesion, in order to provide relief of symptoms and seek an improvement in local blood circulation by

**Table 2** Ficat and Arlet, ARCO and Kerboul classifications

Ficat and Arlet	ARCO	Kerboul
0 - Patient without pain, normal radiograph, scintigraphy with decreased uptake	0 - Biopsy results consistent with osteonecrosis of the femoral head; other tests with normal results	Sum of head necrosis angles in coronal and sagittal views on magnetic resonance imaging: < 190° - low risk of head collapse; 190°-240° - moderate risk; > 240° - high risk
1 - Patient without pain, normal radiograph, cold spot scintigraphy in the head, bone infarction in the weight-bearing areas	1 - Positive findings on scintigraphy or magnetic resonance imaging. A: < 15% of the head compromised; B: 15-30%; C: > 30% of the head compromised	
2 - Mild pain, change in radiological density, cysts and sclerosis, but head with preserved contour, hyperuptake scintigraphy, infarcted areas with spontaneous repair	2 - Head sclerosis, cysts and osteopenia on radiographs; without collapse of the femoral head; positive findings on scintigraphy and magnetic resonance imaging; no changes in the acetabulum A: light, up to 15%; B: moderate, 15-30%; C: severe, > 30%	
3 - Moderate pain, radiograph with loss of sphericity and crescent sign – subchondral fracture, hyperuptake scintigraphy	3 - Crescent sign on anteroposterior and profile radiographs: A: < 15% crescent or < 2 mm of head depression; B: 15-30% increasing, 2-4 mm of depression C: > 30% crescent or > 4 mm of head depression	
4 - Moderate/severe pain, acetabular changes and loss of joint space	4 - Flat joint surface; narrowing of the joint space; acetabular changes, cysts, marginal osteophytes	

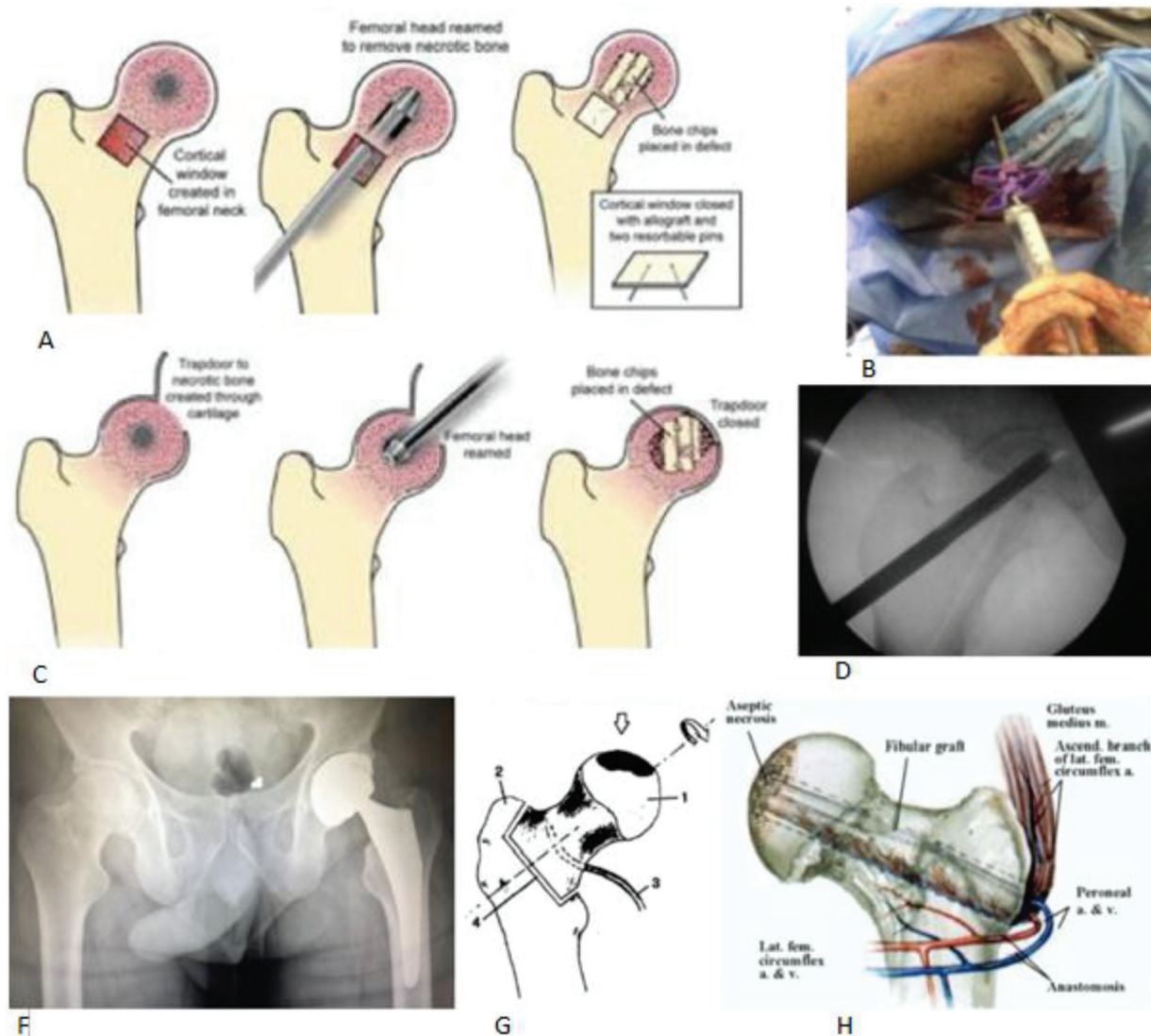
Abbreviation: ARCO, Association Research Circulation Osseus.

reducing intraosseous pressure. It presents best results in small injuries located outside the weight-bearing area. Complications may include intraoperative joint perforation and postoperative subtrochanteric fracture.<sup>46-48</sup>

- Adjuvant therapies associated or not with core decompression, as a way to prevent the collapse of the femoral head<sup>49</sup>:
  - Homologous grafting, using the Phemister technique, or the “light bulb” or “trap door” procedures. Usually indicated for small or medium injuries.
  - Synthetic grafting, called advanced core decompression in the literature.
  - Microsurgical vascularized graft (fibula, iliac crest, and greater trochanter). The complications encountered involve morbidity due to the surgery, including donor site complications, thrombosis and infection.

All grafting modalities aim to promote a structured bone framework to avoid flattening of the femoral head. They are more indicated in young patients.<sup>50-52</sup>

- Injection of mesenchymal stem cells (bone marrow aspirate): an attempt to promote osteogenesis and necrosis repair.<sup>53</sup> In theory, they decrease the percentage of subchondral collapse in short-term studies.<sup>54-56</sup>
- Tantalum implants: results are still imprecise, and further studies are needed for the correct indication and selection of the ideal patient.<sup>57</sup>
- Femoral osteotomies: the most common in the literature is the Sugioka osteotomy; it consists of an attempt to remove the weight-bearing portion of the joint with the lesion and transfer a healthy area as a new weight-bearing area. The results were not reproduced in all orthopedic centers, and a downside is that there is a possible increase in technical difficulty when patients have to undergo hip prosthesis.<sup>58</sup>
- Arthrodesis: a technique described in literature, but not often used, mainly because it is a pathology that is often bilateral.



**Fig. 2** Treatments: (A) “light bulb” procedure; (B) decompression and synthetic grafting; (C) “trap door” procedure; (D) simple core decompression; (E) total hip arthroplasty; (F) Sugioka osteotomy; (G) vascularized graft.

- Arthroplastic resection: as well as arthrodesis and osteotomies, a technique less used nowadays, mainly due to the high success rate of total hip prosthesis.<sup>59</sup>
- Total hip arthroplasty: for cases in which there is already joint involvement, such as the presence of subchondral fracture, flattening of the femoral head and/or joint narrowing, in addition to acetabular changes, the most common treatment is total hip arthroplasty.<sup>60</sup>

– **Figure 2** shows images of the treatments described, and **Figure 3** shows the treatment flowchart.

## Final Remarks

Osteonecrosis of the femoral head is an extremely intriguing pathology, with several associated factors, multifactorial eti-

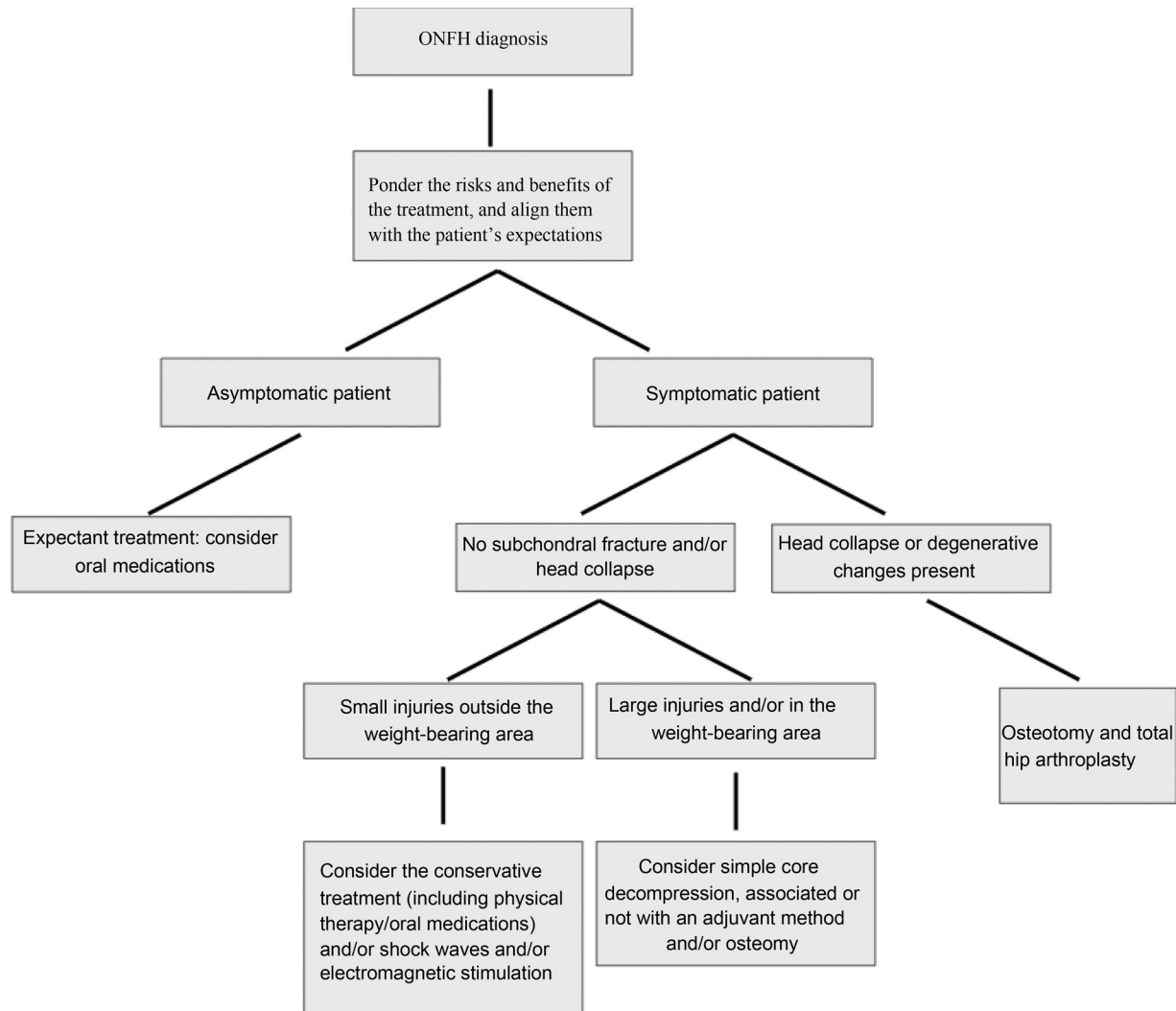
ology, and distinct clinical presentations, and there are still divergences regarding the management of each case. A detailed anamnesis and thorough laboratory investigation are of paramount importance to obtain the correct causal diagnosis.

Osteonecrosis of the femoral head has several therapeutic options in its early stages, all for symptom relief, and in an attempt to preserve the joint. In these cases, it is extremely important to elucidate and explain the treatment in order to meet the patient's expectations.

In advanced cases, osteotomies are an option, and total femoral arthroplasty has excellent results, and the procedure should be individualized for each patient.

## Financial Support

There was no financial support from public, commercial, or non-profit sources.



**Fig. 3** Treatment flowchart.

#### Conflict of interests

The authors have no conflict of interests to declare.

#### References

- 1 Fukushima W, Hirota Y. Alcohol. In: Koo K, Mont M, Jones L editors. Osteonecrosis. Berlin: Springer; 2014:95–99
- 2 Mont M, Zywił M, Marker D, et al. The natural history of untreated osteonecrosis of the femoral head. *J Bone Joint Surg Am* 2010;92(12):2165–2170
- 3 Shah KN, Racine J, Jones LC, Aaron RK. Pathophysiology and risk factors for osteonecrosis. *Curr Rev Musculoskelet Med* 2015;8(03):201–209
- 4 Seamon J, Keller T, Saleh J, Cui Q. The pathogenesis of non-traumatic osteonecrosis. *Arthritis* 2012;2012:601763
- 5 Xu JL, Liang ZR, Xiong BL, Zou QZ, Lin TY, Yang P, Chen D, Zhang QW. Risk factors associated with osteonecrosis of femoral head after internal fixation of femoral neck fracture: a systematic review and meta-analysis. *BMC Musculoskelet Disord* 2019 Dec 29;20(01):632
- 6 Steppacher SD, Haefeli PC, Anwander H, et al. Traumatic avascular necrosis of the femoral head. In: Koo K, Mont M, Jones L editors. Osteonecrosis. Berlin: Springer; 2014:101–112
- 7 Hernigou P, Daltro G. Osteonecrosis in sickle cell disease. In: Koo K, Mont M, Jones L editors. Osteonecrosis. Berlin: Springer; 2014: 125–131
- 8 Hernigou P, Habibi A, Bachir D, Galacteros F. The natural history of asymptomatic osteonecrosis of the femoral head in adults with sickle cell disease. *J Bone Joint Surg Am* 2006;88(12):2565–2572
- 9 Tefferi A, Barbui T. Polycythemia vera and essential thrombocythemia: 2015 update on diagnosis, risk-stratification and management. *Am J Hematol* 2015;90(02):162–173
- 10 Mont MA, Pivec R, Banerjee S, Issa K, Elmallah RK, Jones LC. High-Dose Corticosteroid Use and Risk of Hip Osteonecrosis: Meta-Analysis and Systematic Literature Review. *J Arthroplasty* 2015; 30(09):1506–1512.e5
- 11 Wang GJ, Cui Q, Balian G. The Nicolas Andry award. The pathogenesis and prevention of steroid-induced osteonecrosis. *Clin Orthop Relat Res* 2000;(370):295–310
- 12 Wang Y, Li Y, Mao K, Li J, Cui Q, Wang GJ. Alcohol-induced adipogenesis in bone and marrow: a possible mechanism for osteonecrosis. *Clin Orthop Relat Res* 2003;(410):213–224
- 13 Yoon BH, Mont MA, Koo KH, et al. The 2019 Revised Version of Association Research Circulation Osseous Staging System of Osteonecrosis of the Femoral Head. *J Arthroplasty* 2020;35(04): 933–940

- 14 Gold EW, Cangemi PJ. Incidence and pathogenesis of alcohol-induced osteonecrosis of the femoral head. *Clin Orthop Relat Res* 1979;(143):222–226
- 15 Sella EMC, Carvalho MRP, Sato EI. Osteonecrose em pacientes com lúpus eritematoso sistêmico. *Rev Bras Reumatol* 2005;45(01):1–8
- 16 Yoo JJ. Autoimmune disease and other risk factors. In: Koo K, Mont M, Jones L editors. *Osteonecrosis*. Berlin: Springer;2011:133–139
- 17 Sharareh B, Schwarzkopf R. Dysbaric osteonecrosis: a literature review of pathophysiology, clinical presentation, and management. *Clin J Sport Med* 2015;25(02):153–161
- 18 Borges ÁH, Hoy J, Florence E, et al; for EuroSIDA. Antiretrovirals, fractures, and osteonecrosis in a large international HIV cohort. *Clin Infect Dis* 2017;64(10):1413–1421
- 19 Guyton JL. Hip pain in the young adult and hip preservation surgery. In: Azar FM, Beatty J, Canale ST editors. *Campbell's Operative Orthopaedics*. 13th ed. Philadelphia: Editora Mosby / Elsevier; 2017:378
- 20 Zeng J, Zeng Y, Wu Y, Liu Y, Xie H, Shen B. Acetabular Anatomical Parameters in Patients With Idiopathic Osteonecrosis of the Femoral Head. *J Arthroplasty* 2020;35(02):331–334
- 21 Pierce TP, Jauregui JJ, Cherian JJ, Elmallah RK, Mont MA. Imaging evaluation of patients with osteonecrosis of the femoral head. *Curr Rev Musculoskelet Med* 2015;8(03):221–227
- 22 Mont MA, Marulanda GA, Jones LC, et al. Systematic analysis of classification systems for osteonecrosis of the femoral head. *J Bone Joint Surg Am* 2006;88(Suppl 3):16–26
- 23 Ficat RP. Idiopathic bone necrosis of the femoral head. Early diagnosis and treatment. *J Bone Joint Surg Br* 1985;67(01):3–9
- 24 Steinberg ME, Steinberg DR. Classification systems for osteonecrosis: an overview. *Orthop Clin North Am* 2004;35(03):273–283, vii–viii
- 25 Ha YC, Jung WH, Kim JR, Seong NH, Kim SY, Koo KH. Prediction of collapse in femoral head osteonecrosis: a modified Kerboul method with use of magnetic resonance images. *J Bone Joint Surg Am* 2006;88(Suppl 3):35–40
- 26 Kim-Orden M, Barret K, Khatod M. Algorithm for treatment of hip and knee osteonecrosis: review and Presentation of three examples cases. *J Rheum Dis Treat* 2017;3(03):053 Disponível em: <https://clinmedjournals.org/articles/jrdt/journal-of-rheumatic-diseases-and-treatment-jrdt-3-053.php?jid=jrdt>
- 27 Larson E, Jones LC, Goodman SB, Koo KH, Cui Q. Early-stage osteonecrosis of the femoral head: where are we and where are we going in year 2018? *Int Orthop* 2018;42(07):1723–1728
- 28 Mont MA, Cherian JJ, Sierra RJ, Jones LC, Lieberman JR. Non-traumatic Osteonecrosis of the Femoral Head: Where Do We Stand Today? A Ten-Year Update. *J Bone Joint Surg Am* 2015;97(19):1604–1627
- 29 Choi HR, Steinberg MEY, Y Cheng E. Osteonecrosis of the femoral head: diagnosis and classification systems. *Curr Rev Musculoskelet Med* 2015;8(03):210–220
- 30 Zalavras CG, Lieberman JR. Osteonecrosis of the femoral head: evaluation and treatment. *J Am Acad Orthop Surg* 2014;22(07):455–464
- 31 Banerjee S, Issa K, Pivec R, Kapadia BH, Khanuja HS, Mont MA. Osteonecrosis of the hip: treatment options and outcomes. *Orthop Clin North Am* 2013;44(04):463–476
- 32 Wang CJ, Wang FS, Huang CC, Yang KD, Weng LH, Huang HY. Treatment for osteonecrosis of the femoral head: comparison of extracorporeal shock waves with core decompression and bone-grafting. *J Bone Joint Surg Am* 2005;87(11):2380–2387
- 33 Al-Jabri T, Tan JYQ, Tong GY, et al. The role of electrical stimulation in the management of avascular necrosis of the femoral head in adults: a systematic review. *BMC Musculoskelet Disord* 2017;18(01):319
- 34 Li W, Ye Z, Wang W, Wang K, Li L, Zhao D. Clinical effect of hyperbaric oxygen therapy in the treatment of femoral head necrosis : A systematic review and meta-analysis. *Orthopade* 2017;46(05):440–446
- 35 Kaneshiro Y, Oda Y, Iwakiri K, et al. Low hepatic cytochrome P450 3A activity is a risk for corticosteroid-induced osteonecrosis. *Clin Pharmacol Ther* 2006;80(04):396–402
- 36 Wang Y, Yin L, Li Y, Liu P, Cui Q. Preventive effects of puerarin on alcohol-induced osteonecrosis. *Clin Orthop Relat Res* 2008;466(05):1059–1067
- 37 Yuan HF, Guo CA, Yan ZQ. The use of bisphosphonate in the treatment of osteonecrosis of the femoral head: a meta-analysis of randomized control trials. *Osteoporos Int* 2016;27(01):295–299
- 38 Li D, Yang Z, Wei Z, Kang P. Efficacy of bisphosphonates in the treatment of femoral head osteonecrosis: A PRISMA-compliant meta-analysis of animal studies and clinical trials. *Sci Rep* 2018;8(01):1450
- 39 Glueck C, Freiberg R, Wang P. Treatment of osteonecrosis of the hip and knee with enoxaparin. In: Koo K, Mont M, Jones L editors. *Osteonecrosis*. Berlin: Springer; 2014:241–247
- 40 Cao F, Liu G, Wang W, et al. Combined treatment with an anticoagulant and a vasodilator prevents steroid-associated osteonecrosis of rabbit femoral heads by improving hypercoagulability. *BioMed Res Int* 2017;2017:1624074
- 41 Song Q, Ni J, Jiang H, Shi Z. Sildenafil improves blood perfusion in steroid-induced avascular necrosis of femoral head in rabbits via a protein kinase G-dependent mechanism. *Acta Orthop Traumatol Turc* 2017;51(05):398–403
- 42 Kandil A, Cui Q. Lipid-lowering agents and their effects on osteonecrosis: pros and cons. In: Koo K, Mont M, Jones L editors. *Osteonecrosis*. Berlin: Springer; 2014:255–259
- 43 Cui Q, Wang GJ, Su CC, Balian G. The Otto Aufranc Award. Lovastatin prevents steroid induced adipogenesis and osteonecrosis. *Clin Orthop Relat Res* 1997;(344):8–19
- 44 Pritchett JW. Statin therapy decreases the risk of osteonecrosis in patients receiving steroids. *Clin Orthop Relat Res* 2001;(386):173–178
- 45 Wang C, Sun W, Ling S, et al. AAV-Anti-miR-214 Prevents Collapse of the Femoral Head in Osteonecrosis by Regulating Osteoblast and Osteoclast Activities. *Mol Ther Nucleic Acids* 2019;18:841–850
- 46 Miyahara HS, Rosa BB, Hirata FY, Gurgel HMC, Ejnisman L, Vicente JRN. What is the role of core decompression in the early stages of osteonecrosis of the femoral head? Evaluation of the surgical result by functional score and radiological follow-up. *Rev Bras Ortop* 2018;53(05):537–542
- 47 Mont MA, Carbone JJ, Fairbank AC. Core decompression versus nonoperative management for osteonecrosis of the hip. *Clin Orthop Relat Res* 1996;(324):169–178
- 48 Pierce TP, Jauregui JJ, Elmallah RK, Lavernia CJ, Mont MA, Nace J. A current review of core decompression in the treatment of osteonecrosis of the femoral head. *Curr Rev Musculoskelet Med* 2015;8(03):228–232
- 49 Hernigou P, Beaujean F. Treatment of osteonecrosis with autologous bone marrow grafting. *Clin Orthop Relat Res* 2002;(405):14–23
- 50 Millikan PD, Karas V, Wellman SS. Treatment of osteonecrosis of the femoral head with vascularized bone grafting. *Curr Rev Musculoskelet Med* 2015;8(03):252–259
- 51 Pierce TP, Elmallah RK, Jauregui JJ, Poola S, Mont MA, Delanois RE. A current review of non-vascularized bone grafting in osteonecrosis of the femoral head. *Curr Rev Musculoskelet Med* 2015;8(03):240–245
- 52 Cao L, Guo C, Chen J, Chen Z, Yan Z. Free Vascularized Fibular Grafting Improves Vascularity Compared With Core Decompression in Femoral Head Osteonecrosis: A Randomized Clinical Trial. *Clin Orthop Relat Res* 2017;475(09):2230–2240
- 53 Cui Q, Botchwey EA. Emerging ideas: treatment of precollapse osteonecrosis using stem cells and growth factors. *Clin Orthop Relat Res* 2011;469(09):2665–2669



- 54 Daltro GC, Fortuna VA, Araújo MAS, Lessa PIF, Batista Sobrinho UA, Borojevic R. Tratamento da Osteonecrose da Cabeça Femoral com células progenitoras autólogas em anemia falciforme. *Acta Ortop Bras* 2008;16(01):23–27
- 55 Houdek MT, Wyles CC, Collins MS, et al. Stem cells combined with platelet-rich plasma effectively treat corticosteroid-induced osteonecrosis of the hip: a prospective study. *Clin Orthop Relat Res* 2018;476(02):388–397
- 56 Xu S, Zhang L, Jin H, et al. Autologous stem cells combined core decompression for treatment of avascular necrosis of the femoral head: a systematic review. *BioMed Res Int* 2017;2017:6136205
- 57 Onggo JR, Nambiar M, Onggo JD, Tay G, Singh PJ, Babazadeh S. Outcome of tantalum rod insertion in the treatment of osteonecrosis of the femoral head with minimum follow-up of 1 year: a meta-analysis and systematic review. *J Hip Preserv Surg* 2020;7(02):329–339
- 58 Utsunomiya T, Motomura G, Ikemura S, Hamai S, Fukushi JJ, Nakashima Y. The Results of Total Hip Arthroplasty After Sugioka Transtrochanteric Anterior Rotational Osteotomy for Osteonecrosis. *J Arthroplasty* 2017;32(09):2768–2773
- 59 Maguire N, Robertson B, Henman P. Girdlestone procedure for avascular necrosis of the hip in an intravenous drug user. *J Surg Case Rep* 2014;2014(08):rju039
- 60 Pierce TP, Elmallah RK, Jauregui JJ, Verna DF, Mont MA. Outcomes of total hip arthroplasty in patients with osteonecrosis of the femoral head—a current review. *Curr Rev Musculoskelet Med* 2015;8(03):246–251