

## Case Report

# Brain abscess of odontogenic origin in patients with malignant tumors: A report of two cases

Teishiki Shibata<sup>1</sup>, Nobukazu Hashimoto<sup>1</sup>, Atsuhiko Okura<sup>1</sup>, Mitsuhiro Mase<sup>2</sup>

<sup>1</sup>Department of Neurosurgery, Nagoya City University West Medical Center, Nagoya, Japan, <sup>2</sup>Department of Neurosurgery, Nagoya City University Graduate School of Medical Sciences and Medical School, Nagoya, Japan.

E-mail: \*Teishiki Shibata - tteishiki@gmail.com, Nobukazu Hashimoto - nbzhashimoto@icloud.com, Atsuhiko Okura - a-okura.28@west.med.jp, Mitsuhiro Mase - mitmase@med.nagoya-cu.ac.jp



### \*Corresponding author:

Teishiki Shibata,  
Department of Neurosurgery,  
Nagoya City University West  
Medical Center, Nagoya, Japan.  
tteishiki@gmail.com

Received : 01 June 2021

Accepted : 20 July 2021

Published : 16 August 2021

### DOI

10.25259/SNI\_541\_2021

### Quick Response Code:



## ABSTRACT

**Background:** Oral infection and dental manipulations can lead to the development of brain abscesses, a rare but potentially life-threatening condition. Herein, we report patients undergoing cancer treatment who developed brain abscesses of odontogenic origin at our hospital.

**Case Description:** Two patients developed brain abscesses during cancer treatment. Both underwent neurosurgical aspiration, and the causative microorganism was identified as *Streptococcus intermedius* of the *Streptococcus anginosus* group, which is a part of the normal bacterial flora in the oral cavity. There was clinical and radiographic evidence of dental infection in one of the patients diagnosed with a brain abscess of odontogenic origin. No infectious foci were found in the other patient during hospitalization for the abscess. However, the patient had undergone extraction of an infected tooth approximately 3 months before admission for the abscess, suggesting origination from an oral infection or dental manipulation. The patients' cancers rapidly worsened because cancer treatment in both patients was interrupted for several months to treat the brain abscess.

**Conclusion:** Oral infections can cause severe infections, such as brain abscesses, particularly during the treatment of malignant tumors. Improving the oral environment or treating oral infections before initiating treatment for malignant tumors is highly recommended. In addition, the possibility of odontogenic origin should always be considered as a potential etiology of brain abscesses.

**Keywords:** Brain abscess, Malignant tumor, Odontogenic infection

## INTRODUCTION

Brain abscess, a focal pyogenic infection of the brain, can be caused by bacteria, mycobacteria, fungi, or parasites (protozoa and helminths).<sup>[3,4]</sup> The estimated incidence of brain abscess is 0.4–0.9 cases per 100,000 population.<sup>[4]</sup> The causative agent gains access to the brain primarily through contiguous spread or hematogenous dissemination and sometimes by direct inoculation (such as head trauma or a neurosurgical procedure).<sup>[4]</sup> The most frequent causative microorganisms belong to *Streptococcus* species, specifically the *Streptococcus anginosus* group (SAG), according to recent studies.<sup>[6,11]</sup> SAG, which is part of the normal flora in various mucosal sites, is commonly associated with pyogenic infections.<sup>[9,13,17,21,22]</sup> Here, we describe the cases of two patients who developed brain abscesses during cancer treatment. The causative microorganism was identified to be *Streptococcus intermedius*, a member of the SAG, with the causes including oral infection and dental manipulation during cancer treatment.

This is an open-access article distributed under the terms of the Creative Commons Attribution-Non Commercial-Share Alike 4.0 License, which allows others to remix, tweak, and build upon the work non-commercially, as long as the author is credited and the new creations are licensed under the identical terms.

©2021 Published by Scientific Scholar on behalf of Surgical Neurology International

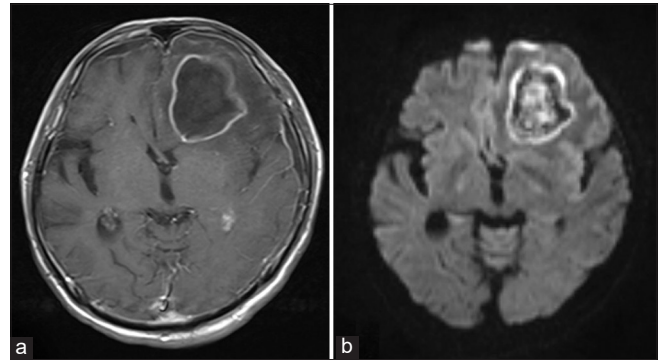
## CASE REPORTS

### Case 1

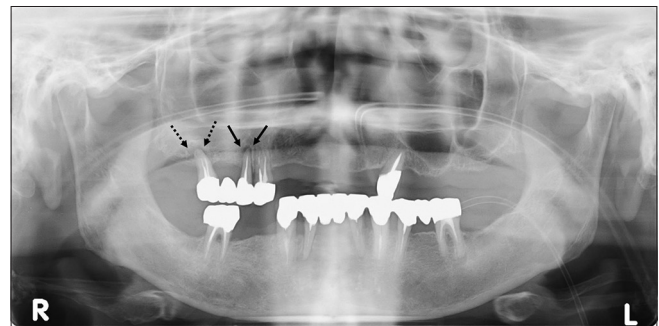
A 62-year-old man presented to the emergency department of our hospital with headache and fever for 3 days; he had a history of esophageal cancer and type 2 diabetes mellitus. Approximately 4 weeks before the visit to the emergency department, he had received one cycle of preoperative high-dose chemotherapy with 5-fluorouracil (700 mg/m<sup>2</sup> on days 1–4) and cisplatin (70 mg/m<sup>2</sup> on day 1). Neurological examination revealed motor aphasia and right hemiparesis. Cranial computed tomography (CT) showed a left frontal mass-like lesion with surrounding vasogenic edema. Subsequent cranial magnetic resonance imaging (MRI) showed a 5.0-cm large left frontal mass lesion, which appeared as a ring-enhancing lesion on gadolinium-enhanced T1-weighted imaging [Figure 1a]. In addition, diffusion-weighted MRI showed hyperintensity in the lesion rim and part of the lesion interior [Figure 1b]. Based on these findings, brain abscess was the primary consideration, although other possibilities, including metastatic brain tumor, glioblastoma, and lymphoma, were also considered.

After obtaining blood cultures, empirical treatment with intravenous meropenem and vancomycin was initiated, and levetiracetam was administered to prevent seizures; the patient then underwent stereotactic biopsy the next day to definitively diagnose and treat the abscess. During surgery, CT-guided needle aspiration of the lesion yielded purulent discharge, leading to the confirmation of brain abscess. A drainage tube was placed in the abscess cavity after complete abscess evacuation. The blood and purulent fluid were cultured, and *S. intermedius* growth was observed only in the purulent fluid culture, not in the blood cultures. Antibiotics were de-escalated to intravenous ceftriaxone based on antibiotic-sensitivity test results, and early postoperative MRI revealed a marked shrinkage in the abscess size. Intraoral examination and panoramic radiography revealed that the right maxillary second premolar and second molar had chronic suppurative apical periodontitis [Figure 2]. No other infectious foci were found during several examinations, leading to the conclusion that these teeth were most likely the cause of the brain abscess. Furthermore, the teeth were extracted approximately 5 weeks after operation.

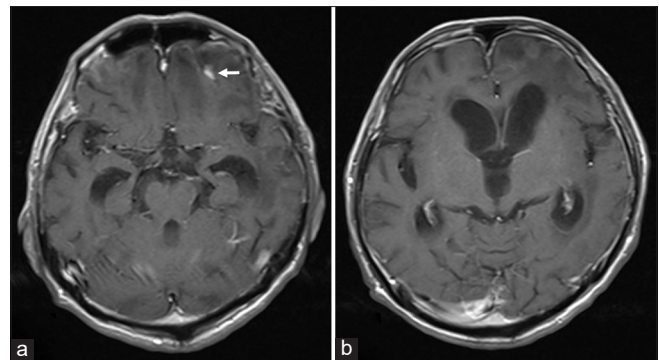
At 1 month after the surgery, the right hemiparesis had disappeared and the motor aphasia had almost completely disappeared. Gadolinium-enhanced T1-weighted MRI approximately 4 months after the surgery showed shrinking of the lesion with only a very small area of high signal intensity and hydrocephalus secondary to central nervous system infection [Figure 3a and b]. This patient had to discontinue cancer treatment for several months due to the



**Figure 1:** Magnetic resonance imaging showing a left frontal mass lesion measuring 5.0 cm in size, which exhibits ring enhancement on gadolinium-enhanced T1-weighted imaging (a) and hyperintensity in the lesion rim and part of the lesion interior on diffusion-weighted imaging (b).



**Figure 2:** Panoramic radiograph showing widening of the periodontal ligament space around the right maxillary second premolar (arrow) and second molar (dotted arrow) due to apical periodontitis.



**Figure 3:** (a and b) Gadolinium-enhanced T1-weighted magnetic resonance imaging (MRI) approximately 4 months after the surgery showing shrinking of the lesion with only a very small area of high signal intensity (arrow) and hydrocephalus secondary to central nervous system infection. Hyperintensity in the lesion disappeared completely on diffusion-weighted MRI (not shown).

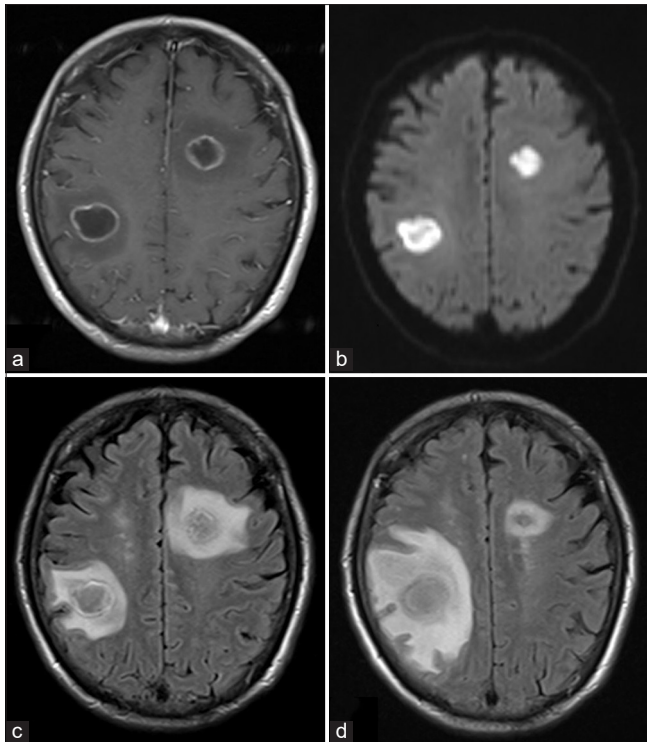
presence of the brain abscess, and his medical condition worsened rapidly due to cancer progression. Therefore, shunt surgery for hydrocephalus was not performed. He

was subsequently transitioned to palliative care and died 6 months after the surgery.

## Case 2

A 68-year-old man presented to the emergency department of our hospital with a 6-day history of left hemiparesis and 1-day history of fever. The patient had a history of advanced non-small-cell lung cancer and was receiving 3-week cycles of pembrolizumab (200 mg) for approximately 4 months before admission. Initial cranial CT and MRI showed two lesions in the left frontal and right parietal lobes. Both lesions were <2 cm in size and exhibited homogeneous hyperintensity on diffusion-weighted MRI [Figure 4a-c]. The primary consideration in this case was brain abscess. Due to the small size of the lesion, neurosurgical aspiration was planned in case the causative pathogen could not be identified by blood culture or treated by antibiotics.

After blood cultures were obtained, empirical treatment with intravenous meropenem administration was initiated. Levetiracetam was started for seizure prophylaxis. Although

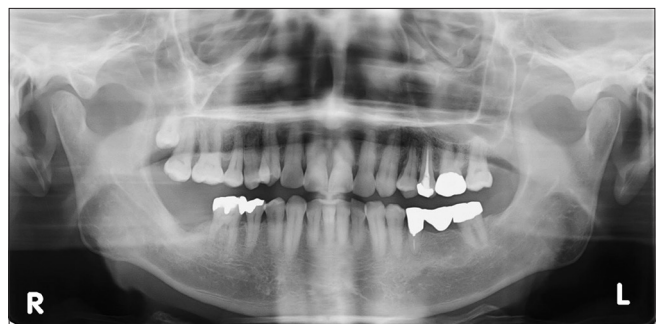

**Figure 4:** Magnetic resonance imaging (MRI) showing two mass lesions of <2 cm in the left frontal and right parietal lobes. Both lesions exhibited ring enhancement on gadolinium-enhanced T1-weighted imaging (a) and homogeneous hyperintensity on diffusion-weighted imaging (b), with vasogenic edema surrounding the lesions on fluid-attenuated inversion recovery (FLAIR) imaging (c). (d) FLAIR MRI obtained 7 weeks later showing slight enlargement of the mass lesion in the right frontal lobe with worsening vasogenic edema.

the causative pathogen was not identified by blood culture, the lesion sizes reduced remarkably following antibiotic treatment, and left hemiparesis was improved. Therefore, neurosurgical aspiration was not performed. However, his left hemiparesis worsened 7 weeks after treatment initiation. Cranial MRI revealed that the mass lesion in the right frontal lobe was slightly enlarged and the surrounding vasogenic edema was exacerbated [Figure 4d]. Blood cultures were taken again, and then neurosurgical aspiration was performed. Stereotactic needle aspiration of the lesion in the right frontal lobe yielded purulent discharge, leading to a confirmed diagnosis of brain abscesses for both lesions. *S. intermedius* growth was detected only in the purulent fluid culture and not in the blood cultures. There was a considerable reduction in the lesion sizes after surgical drainage and antibiotic treatment based on antibiotic-sensitivity test results. The origin of the brain abscesses could not be identified even after several examinations, including intraoral examination and panoramic radiography [Figure 5]. However, during treatment for lung cancer, the patient had undergone tooth extraction of the right mandibular second molar harboring apical periodontitis approximately 3 months before admission. Because *S. intermedius*, an indigenous oral bacterial species, was detected by the purulent fluid culture, oral infection or dental manipulation was considered as the possible cause of brain abscesses.

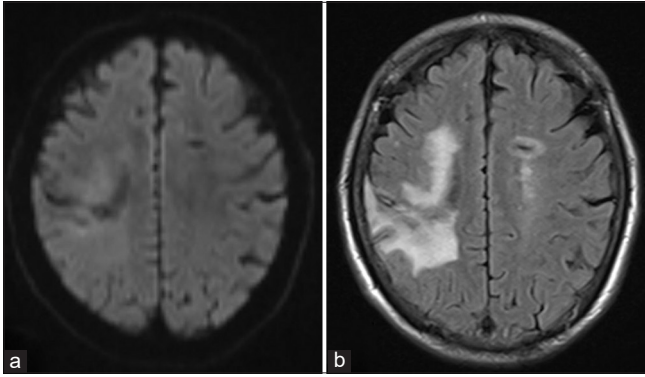
At 2 months after the surgery, the left hemiparesis had disappeared. Approximately 4 months after the surgery, the lesions had disappeared and the surrounding vasogenic edema had partially improved on the non-contrast MRI [Figure 6a and b]. Cancer treatment had to be interrupted for several months to treat the brain abscesses, and the patient's medical condition worsened rapidly due to cancer progression. Approximately 8 months after the surgery, pembrolizumab was administered for 2 months, followed by chemotherapy for 1 month due to a temporary improvement in his medical condition. However, he died 14 months after the surgery, unable to control the lung cancer that had grown rapidly when cancer treatment was interrupted.

None of the two patients had sinusitis, ear infection, or recent head trauma or surgery. Echocardiography was negative for



**Figure 5:** Panoramic radiograph showing no apparent abnormalities.





**Figure 6:** Approximately 4 months after the surgery, the lesions disappeared on diffusion-weighted magnetic resonance imaging (MRI) (a) and the surrounding vasogenic edema partially improved on FLAIR MRI (b). Postoperative gadolinium-enhanced MRI was not performed because the gadolinium-enhanced MRI was refused.

cardiac diseases, including endocarditis and congenital heart defects. In addition, no infectious foci were found on the CT of the chest, abdomen, and pelvis.

## DISCUSSION

Despite advances in imaging techniques, laboratory diagnostics, surgical interventions, and antimicrobial treatment, brain abscess remains a serious and potentially life-threatening condition.<sup>[4,11]</sup> Brain abscesses are usually caused by contiguous infections following sinusitis or middle ear infection or by hematogenous dissemination as a result of cardiac disease, pulmonary disease, or distant foci of infection.<sup>[4]</sup> In addition, a brain abscess can develop after neurosurgery or head trauma. Contiguous spread and hematogenous dissemination account for approximately half and one third of the sources in all cases, respectively.<sup>[4]</sup> Although few cases of brain abscess with odontogenic origin have been reported, hematogenous dissemination is considered as the most important pathophysiological mechanism of brain abscess of odontogenic origin.<sup>[18]</sup>

In both cases presented herein, the likely cause of brain abscess was hematogenous dissemination of odontogenic bacteremia. Ewald *et al.*<sup>[8]</sup> proposed that the following three criteria must be satisfied to establish the diagnosis of brain abscess with odontogenic origin: absence of other sources of bacteremia, microbiological spectrum consistent with oral microflora, and clinical or radiographic evidence of dental infection.<sup>[2]</sup> Case 1 satisfied all three criteria, thereby confirming the diagnosis of brain abscess with odontogenic origin. In Case 2, dental infection was not found by oral examination during hospitalization; however, the patient had undergone the extraction of a tooth with apical periodontitis approximately 3 months before admission for brain abscess. Despite the time interval of several months between the

tooth extraction and brain abscess formation, indigenous oral bacteria were detected in the abscess. The previous studies have reported *S. intermedius* abscess formation 6–12 weeks after dental manipulation and *S. intermedius* subacute bacterial endocarditis 12 weeks after dental manipulation;<sup>[1,5,10,14]</sup> this supports the hypothesis that brain abscess can develop approximately 3 months after dental manipulation. In Case 2, brain abscess caused by *S. intermedius* was potentially due to an oral infection or the tooth extraction performed approximately 3 months earlier during lung cancer treatment.

*S. intermedius*, together with *Streptococcus constellatus* and *S. anginosus*, is a member of the SAG, also referred to as the *Streptococcus milleri* group.<sup>[9,17]</sup> Members of the SAG are found in the normal flora of various mucosal sites, including oral cavity, gastrointestinal tract, and genitourinary system, but are commonly reported to form abscesses.<sup>[9,13,17,21,22]</sup> *S. intermedius* tends to be isolated primarily from abscesses in the brain and liver, whereas both *S. constellatus* and *S. anginosus* have been isolated from a wider range of sites and infections.<sup>[22]</sup> Darlow *et al.*<sup>[6]</sup> reported that members of the SAG were present in 74% of brain abscesses with available clinical data and that *S. intermedius* accounted for 66% of brain abscesses caused by the SAG. The most commonly reported diseases underlying SAG infections are malignant tumors and diabetes mellitus.<sup>[13]</sup> In addition, the most important underlying risk factors for brain abscess caused by *S. intermedius* are dental manipulation and sinusitis.<sup>[12]</sup>

In the present cases, both patients had malignant tumors as the underlying disease and had oral infection or a history of dental manipulation. In Case 1, the presence of diabetes mellitus, chronic suppurative apical periodontitis, and chemotherapy-induced immunosuppression might have contributed to the brain abscess formation. In Case 2, an immunocompromised state has not been reported as an adverse event of pembrolizumab, a checkpoint inhibitor. However, oral infection or dental manipulation during cancer treatment might have contributed to the development of brain abscess.

Skallsjö *et al.*<sup>[19]</sup> reported that chronic apical periodontitis was not associated with serious medical complications in patients treated with chemotherapy for lymphoma. However, dental treatment before starting cytoreductive therapy reportedly reduced the risk of severe oral infections by a considerable degree.<sup>[15,16,20]</sup> Oral cavity infections can lead to infections in various other sites throughout the body, especially during treatment for malignant tumors.<sup>[7]</sup> Moreover, patients with malignant tumors who develop brain abscesses have to interrupt treatment for malignant tumors for several months, which may lead to the worsening of the clinical condition of the patient due to the consequent progression of the malignant tumor. Lopez *et al.*<sup>[15]</sup> reported

that nonviable teeth and those with poor prognosis should be removed at least 2 weeks before chemotherapy and that major surgical procedures should be performed 4–6 weeks before chemotherapy. Chemotherapy should be initiated after dental treatment if possible. At the minimum, oral care and improvement of the oral environment should be implemented. In addition, in the absence of other sites of origin, the possibility of an odontogenic origin should always be considered in patients with brain abscess formation during cancer treatment.

## CONCLUSION

In this report, we described cases of two patients undergoing cancer treatment who developed brain abscesses of odontogenic origin. In these patients, cancer treatment had to be interrupted for several months. Their cancers rapidly deteriorated during cancer treatment interruption. During treatment for malignant tumor, oral infections can lead to serious infections, such as brain abscess formation. Therefore, improving the oral environment or treating oral infections is recommended before initiating treatment for malignant tumor.

## Declaration of patient consent

The authors certify that they have obtained all appropriate patient consent.

## Financial support and sponsorship

Nil.

## Conflicts of interest

There are no conflicts of interest.

## REFERENCES

- Al Moussawi H, Krzyzak M, Awada Z, Chalhoub JM. *Streptococcus intermedius* brain and diverticular abscesses after dental manipulation: A case report. *Cureus* 2018;10:e2061.
- Basyuni S, Sharma V, Santhanam V, Ferro A. Fatal thalamic abscess secondary to dental infection. *BMJ Case Rep* 2015;2015:bcr2015212589.
- Brouwer MC, Coutinho JM, van de Beek D. Clinical characteristics and outcome of brain abscess: Systematic review and meta-analysis. *Neurology* 2014;82:806-13.
- Brouwer MC, Tunkel AR, McKhann GM 2<sup>nd</sup>, van de Beek D. Brain abscess. *N Engl J Med* 2014;371:447-56.
- Cunha BA, D'Elia AA, Pawar N, Schoch P. Viridans streptococcal (*Streptococcus intermedius*) mitral valve subacute bacterial endocarditis (SBE) in a patient with mitral valve prolapse after a dental procedure: The importance of antibiotic prophylaxis. *Heart Lung* 2010;39:64-72.
- Darlow CA, McGlashan N, Kerr R, Oakley S, Pretorius P, Jones N, et al. Microbial aetiology of brain abscess in a UK cohort: Prominent role of *Streptococcus intermedius*. *J Infect* 2020;80:623-9.
- Epstein JB, Stevenson-Moore P. Periodontal disease and periodontal management in patients with cancer. *Oral Oncol* 2001;37:613-9.
- Ewald C, Kuhn S, Kalf R. Pyogenic infections of the central nervous system secondary to dental affections—a report of six cases. *Neurosurg Rev* 2006;29:163-6; discussion 166-7.
- Facklam R. What happened to the streptococci: Overview of taxonomic and nomenclature changes. *Clin Microbiol Rev* 2002;15:613-30.
- Hanna A, Imam Z, Odish F, Dalal B. Multiple liver abscesses caused by *Streptococcus intermedius* bacteremia in the setting of a routine dental cleaning. *BMJ Case Rep* 2020;13:e233097.
- Helweg-Larsen J, Astradsson A, Richhall H, Erdal J, Laursen A, Brennum J. Pyogenic brain abscess, a 15 year survey. *BMC Infect Dis* 2012;12:332.
- Issa E, Salloum T, Tokajian S. From normal flora to brain abscesses: A review of *Streptococcus intermedius*. *Front Microbiol* 2020;11:826.
- Jiang S, Li M, Fu T, Shan F, Jiang L, Shao Z. Clinical characteristics of infections caused by *Streptococcus anginosus* group. *Sci Rep* 2020;10:9032.
- Livingston LV, Perez-Colon E. *Streptococcus intermedius* bacteremia and liver abscess following a routine dental cleaning. *Case Rep Infect Dis* 2014;2014:954046.
- Lopez BC, Esteve CG, Perez MG. Dental treatment considerations in the chemotherapy patient. *J Clin Exp Dent* 2011;3:e31-42.
- López-Galindo MP, Bagán JV, Jiménez-Soriano Y, Alpiste F, Camps C. Clinical evaluation of dental and periodontal status in a group of oncological patients before chemotherapy. *Med Oral Patol Oral Cir Bucal* 2006;11:E17-21.
- Mishra AK, Fournier PE. The role of *Streptococcus intermedius* in brain abscess. *Eur J Clin Microbiol Infect Dis* 2013;32:477-83.
- Moazzam AA, Rajagopal SM, Sedghizadeh PP, Zada G, Habibian M. Intracranial bacterial infections of oral origin. *J Clin Neurosci* 2015;22:800-6.
- Skallsjö K, Johansson JE, Jonasson P, Hasséus B. Apical periodontitis as potential source of infection in patients with lymphoma treated with chemotherapy. *Clin Oral Investig* 2020;241:133-40.
- Stone R, Flidner MC, Smiet AC. Management of oral mucositis in patients with cancer. *Eur J Oncol Nurs* 2005;9 Suppl 1:S24-32.
- Tran MP, Caldwell-McMillan M, Khalife W, Young VB. *Streptococcus intermedius* causing infective endocarditis and abscesses: A report of three cases and review of the literature. *BMC Infect Dis* 2008;8:154.
- Whiley RA, Beighton D, Winstanley TG, Fraser HY, Hardie JM. *Streptococcus intermedius*, *Streptococcus constellatus*, and *Streptococcus anginosus* (the *Streptococcus milleri* group): Association with different body sites and clinical infections. *J Clin Microbiol* 1992;30:243-4.

**How to cite this article:** Shibata T, Hashimoto N, Okura A, Mase M. Brain abscess of odontogenic origin in patients with malignant tumors: A report of two cases. *Surg Neurol Int* 2021;12:417.