



## Original Article

# Magnetic resonance angiography determined variations in the circle of Willis: Analysis of a large series from a single center

Reddy Ravikanth\*, Babu Philip

Department of Radiology,  
St. John's Medical College,  
Bengaluru, Karnataka, India

## ABSTRACT

**Objective:** The purpose of this study is to evaluate and describe the prevalence and patterns of arterial variants in the circle of Willis (CW) seen in noncontrast three-dimensional time-of-flight magnetic resonance angiography in a series of patients with cerebral vascular accidents (CVAs). **Materials and Methods:** A descriptive study was undertaken in 200 patients who presented for screening for CVA in the Department of Radiodiagnosis and Imaging, St. John's Medical College Hospital, Bengaluru, from September 2014 to September 2016. **Results:** The most common types of CW in a single subject were anterior variant Type A and posterior variant Type E. Type A in the anterior circulation is the normal adult pattern. There is a single anterior communicating artery. The internal carotid artery bifurcates into the precommunicating segment of the anterior cerebral artery and middle cerebral artery. Type E in the posterior circulation is hypoplasia or absence of both posterior communicating arteries and isolation of the anterior and posterior parts of the circle at this level. Overall, CW variants were slightly more common in women than in men. **Conclusion:** Our findings show that the configuration of the CW may vary greatly in the general population. The wide range in the morphology of CW warrants further research on various races and larger populations to confirm the influence of genetic, regional, environmental, and hemodynamic factors or their combination.

**KEYWORDS:** Anatomical variants, Cerebrovascular disease, Circle of Willis, Magnetic resonance angiography

Received : 25-Oct-2017  
Revised : 27-Dec-2017  
Accepted : 05-May-2018

## INTRODUCTION

The circle of Willis (CW) demonstrates considerable morphological variation in the general population. Some anatomical variants might pose different hemodynamic challenges to cerebral blood flow, which may be of some clinical importance in cerebral vascular diseases [1]. The CW is a large arterial anastomotic ring present in the basal cistern of the brain, uniting the internal carotid and the vertebrobasilar system. Branches from this arterial ring are distributed to supply the brain. In 1664, Sir Thomas Willis was the first to describe the importance of the circle in maintaining collateral flow [2]. It was observed that there is very little mixing of blood between the collateral branches of the circle. These collaterals may, however, open up during occlusive episodes in the proximal feeding vessels. The anatomy of the circle is known to vary considerably, and functionally, a complete circle is a rare finding [3]. These types of incomplete or variant forms of the circle may diminish its role as a collateral route. Variations in the CW are not rare and some have clinical implications. Hypoplasia of the component arteries of the CW

has been reported in anatomic studies at rates ranging from 0.7% to 80.6% [4]. The prevalence of the “typical circle,” the “normal” textbook polygon, ranges from 4.6% to 72.2% [5]. Although the relationship between variations in the CW and some vascular diseases has been implicated clinically, these variations have not been compared in various populations. In this regard, magnetic resonance angiography (MRA) is a quite sensitive diagnostic modality in the detection of cerebral arterial pathological lesions or normal variants [6]. MRA is precise, aids in a quick diagnosis of cerebral infarction, and can reveal the presence of tissue at risk, the “ischemic penumbra,” which has further elevated its importance as a diagnostic technique in the intracranial vasculature. The average age of patients with stroke in developing countries is 15 years younger than in developed countries, and so, anatomy of the cerebral arteries in the pathogenesis of cerebrovascular

### \*Address for correspondence:

Dr. Reddy Ravikanth,  
Department of Radiology, St. John's Medical College, Koramangala,  
Bengaluru, Karnataka, India.  
E-mail: ravikanthreddy06@gmail.com

Access this article online	
Quick Response Code:	Website: <a href="http://www.tcmjmed.com">www.tcmjmed.com</a>
	DOI: 10.4103/tcmj.tcmj_167_17

This is an open access journal, and articles are distributed under the terms of the Creative Commons Attribution-NonCommercial-ShareAlike 4.0 License, which allows others to remix, tweak, and build upon the work non-commercially, as long as appropriate credit is given and the new creations are licensed under the identical terms.

For reprints contact: [reprints@medknow.com](mailto:reprints@medknow.com)

**How to cite this article:** Ravikanth R, Philip B. Magnetic resonance angiography determined variations in the circle of Willis: Analysis of a large series from a single center. Tzu Chi Med J 2019;31(1):52-9.

diseases in different ethnic groups is important [7]. This study characterized anatomical variants associated with the CW in a South Indian population presenting to a tertiary care center.

Radiological evaluation and characterization of the variants in the CW detected using three-dimensional time-of-flight MRA (3D-TOF-MRA).

**MATERIALS AND METHODS**

**Patients**

A total of 200 patients were selected for the study between September 2014 and September 2016. They were referred for screening with MRA for cerebrovascular accidents (CVAs) in the Department of Radiodiagnosis of St. John’s Medical College Hospital, Bengaluru, India. Only those patients with subsequently detected variations in the CW were included in the study. Patients who did not consent to imaging, were claustrophobic, or had metallic implants or pacemakers were excluded from the study.

**Data collection**

For evaluation of variants of the CW, MRA was performed using a 1.5 T magnetic resonance imaging (MRI) scanner (Signa, General Electric Medical Systems, Milwaukee, WI, USA) with a commercially available head coil. 3D-TOF-MRA images of all 200 patients were evaluated by a neuroradiologist with 18 years’ experience in neuroradiology.

**Magnetic resonance protocol**

The patients were supine with the neck and head in the neutral position. MRA examination consisted of 3D-TOF-MRA and fast spin-echo T2-weighted axial imaging (repetition time [TR]/effective echo time, 4000/101 ms; matrix, 256 × 256; field of view [FOV], 200 mm; section thickness, 5 mm). Variations in the CW were also classified using 3D-TOF-MRA (TR/echo time, 35/4.7 ms; flip angle, 20°; matrix, 256 × 256; FOV, 200 mm; slab thickness, 52.8 mm; section thickness, 0.8 mm). 3D-TOF-MRA of the CW was obtained with the sequence of spoiled gradient-recalled acquisition. T2-weighted imaging was done to rule out abnormalities or lesions in the brain.

**Statistical analysis**

Descriptive statistics were reported using numbers and percentages for categorical variables in cases of MRA-proven cases variations in the CW. Findings were tabulated using Microsoft Excel 2010 Microsoft Corp., Redmond, WA, USA, and statistical analyses were conducted using SPSS Statistical Package (version 20.0), IBM SPSS Statistics for Windows, V.20.0, IBM Corp., Armonk, New York, USA.

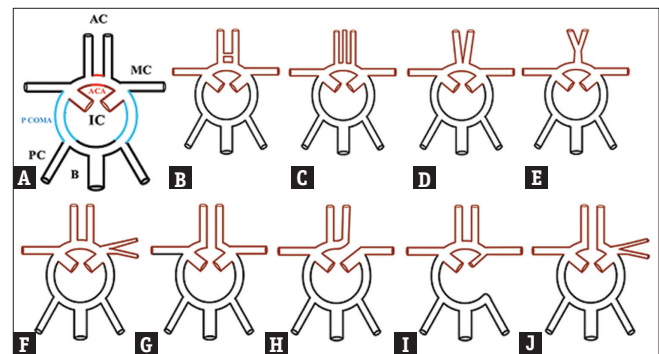
**RESULTS**

The age of the patients studied ranged from 11 to 86 years (mean age 48.5 years).

The 200 participants included 132 males and 68 females. Anterior circulation variations [Figure 1] and posterior circulation variations [Figure 2] were modified from Chen *et al.* [8]. Variant Type A was the most common type in the anterior part of the CW in all age groups and sexes. The anterior CW was

complete in 154 of 200 participants (77.0%) with a Type A configuration in 132 subjects [Table 1].

In one patient, two anterior communicating arteries (AcomAs) were observed. The anterior circle was incomplete in 45 participants who had compromised anterior collateral flow. AcomA was absent in 26 participants, and 19 subjects had A1 hypoplasia or aplasia. The prevalence of unilateral fetal-type posterior communicating artery (FTPcomA, posterior variants B, F, G, and H) was 16% and bilateral FTPcomA (posterior variants C, I, and J) was 7%. A higher percentage of incomplete collaterals were observed in the posterior part of the circle compared with the anterior collaterals. An adult configuration complete posterior circle was observed in 34 participants and transitional variants 6b and c were observed in 19 subjects. An FTP CW was found in 46 (23%) of the 200 participants. Of these 46 participants, 37 (18.5%) were classified as having



**Figure 1 :** Schematic diagrams of anatomic variations in the anterior part of the CW. (A) Normal adult pattern. There is a single AcomA (red). The ICA bifurcates into the precommunicating segment of the ACA and MCA. (B) Two or more AcomAs. (C) The median artery of the corpus callosum arises from the AcomA. (D) Fusion of the ACAs over a short distance. (E) The ACA forms a common trunk and splits distally into two post communicating segments. (F) The MCA originates from the ICA as two separate trunks. (G) Hypoplasia or absence of an AcomA. (H) One precommunicating segment of an ACA is hypoplastic or absent, and the other precommunicating segment gives rise to both postcommunicating segments of the ACAs. (I) Hypoplasia or absence of an ICA. The ACA gives rise to both postcommunicating segments and supplies retrograde flow to the ipsilateral precommunicating segment. (J) Hypoplasia or absence of an anterior communication. The MCA arises as two separate trunks. CW: Circle of Willis, ICA: Internal carotid artery, MCA: Middle cerebral artery, AcomA: Anterior communicating artery, ACA: Anterior cerebral artery

**Table 1: Morphological types of the circle of Willis pertaining to anterior and posterior circulations by gender (%)**

Types*	Anterior circulation (%)			Posterior circulation (%)		
	Total	Male	Female	Total	Male	Female
A	66	42.5	23.5	17	7.5	9.5
B	1	0.5	0.5	4.5	3.5	1
C	2	1	1	4.5	2.5	2
D	7.5	4	3.5	7	5.5	1.5
E	2.5	1.5	1	53	36	17
F	0	0	0	1	0.5	0.5
G	11.5	7.5	4	7	6.5	0.5
H	9.5	7.5	2	3	1.5	1.5
I	0	0	0	0	0	0
J	0	0	0	3	2.5	0.5

\*Types A-J represent anatomic variations in the anterior and posterior parts of the CW (modified from Chen *et al.*)

partial FTP in which a hypoplastic P1 segment was present and 9 (4.5%) were found to have a full FTP in which a P1 segment was absent. The most common type of posterior variation was Type E in which the bilateral PcomAs were absent. Of the 37 participants with a partial FTP, a unilateral FTP was found in 23 participants and bilateral FTPs were seen in 14 participants. There were statistically significant differences among different age groups and genders. A higher prevalence of complete CW was found in the younger group (<50 years, 33.9% of younger subjects versus 6.8% of older subjects) and in females (28.4% of females versus 10.6% of males). In the combined analysis, a complete CW was seen in 33 (16.5%) of the 200 participants [Figure 3]. An incomplete anterior and posterior CW was found in 44 (22%) of the 200 participants. The remaining 123 (61.5%) participants had a partially complete CW configuration. The anterior part of the CW is considered as complete in types A–C, incomplete in types G–J, and partially complete in types D and E. The posterior part of the CW is considered as complete in type A, incomplete in types D–J, and partially complete in types B–C. The most common types of CW in a single participant were anterior variant Type A and posterior variant Type E. Further, three patients had aneurysms, one patient had an arteriovenous malformation (AVM), and two patients had persistent trigeminal and persistent hypoglossal arteries on MRA.

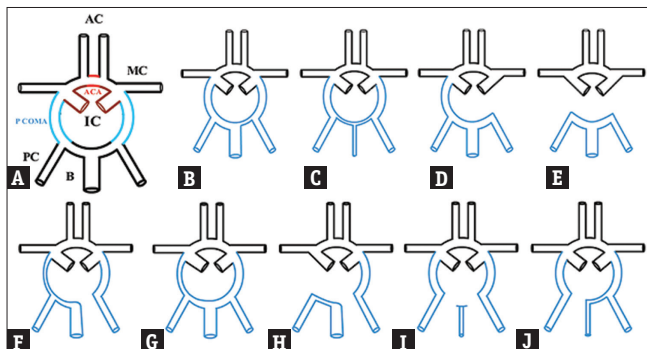
**DISCUSSION**

The brain, though representing only 2% of the total body weight, receives one-fifth of the resting cardiac output [9]. This blood supply is carried by the two internal carotid arteries (ICAs) and the two vertebral arteries that anastomose at the base of the brain to form the CW. The carotid arteries and their branches (referred to as the anterior circulation) supply the anterior portion of the brain, while the vertebrobasilar

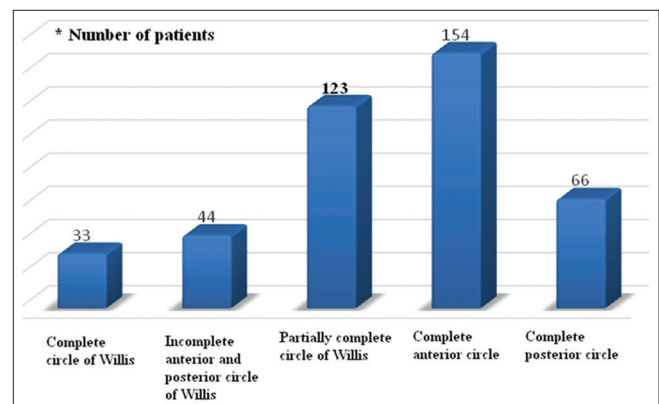
system (referred to as the posterior circulation) supplies the posterior portion of the brain.

The CW consists of a symmetrical arterial circle, with a single AcomA and bilateral PcomA, which usually have smaller diameters than the precommunicating segments of the posterior cerebral artery (PCA). Furthermore, the CW constitutes a key collateral network for preserving satisfactory cerebral perfusion. Therefore, changes in the normal morphology of the CW may lead to different types and degrees of cerebrovascular disorders, including aneurysms, infarctions, and other vascular abnormalities. The CW is the main route for collateral blood flow in severe occlusive diseases of the ICA. Those patients with variants of the circle with efficient collateral circulation have a lower risk of transient ischemic attack and stroke than patients without such collaterals [10]. In addition to different vascular accidents, it is important to identify the status of the CW to determine the capability of the brain circulation before surgery, especially for cerebral aneurysms.

In our study, as in earlier studies, we considered the following vessels as forming part of the CW: the AcomA, the precommunicating segment (A1) of the anterior cerebral artery (ACA), the precommunicating segment (P1) of the PCA (P1-PCA), the PcomA, and the ICA. The CW configuration can be categorized into three different types based on the structure of the P1-PCA and P2-PCA and the PcomA. Configurations are the adult type, transitional type, and fetal type. In previous studies, the prevalence of a complete anterior circle varied from 74% to 90% in different ethnic groups, similar to our observations [11]. Autopsy studies, however, have shown lower incidences of complete circles [12]. One recent cadaveric study reported variation of the CW in 40% with maximum variation in the PcomA (50%) followed by the AcomA (40%) [13]. In the present study, the prevalence of an entirely complete CW was 16.6%, higher in females than in males (28.4 and 10.6%, respectively), and younger than older subjects (33.9 and 6.8%, respectively). Previous studies have shown higher incidences of complete circles in female patients and younger patients [14]. Our observations were similar to earlier studies. In addition, the average age of males was 63 years and that of females was 47 years, which might partly explain the higher visualization in females. The most common



**Figure 2:** Schematic diagrams of anatomical variations of the posterior circle of Willis (A) Bilateral PcomAs are present (blue). (B) The PCA originates predominantly from the ICA. This variant is known as a unilateral fetal type PCA; the PcomA on the other side is patent. (C) Bilateral fetal type PCAs with both precommunicating segments of the PCAs patent. (D) Unilateral PcomA present. (E) Hypoplasia or absence of both PcomAs and isolation of the anterior and posterior parts of the circle at this level. (F) Unilateral fetal type PCA and hypoplasia or absence of the precommunicating segment of the PCA. (G) Unilateral fetal type PCA and hypoplasia or absence of the contralateral PcomA. (H) Unilateral fetal type PCA and hypoplasia or absence of both precommunicating segments of the PCA and the PcomA. (I) Bilateral fetal type PCAs with hypoplasia or absence of both precommunicating segments of the PCAs. (J) Bilateral fetal type PCAs with hypoplasia or absence of the precommunicating segment of either PCA. PCA: Posterior cerebral artery, PcomA: Posterior communicating artery, ICA: Internal carotid artery



**Figure 3:** Morphological spectrum involving the anterior and posterior circle of Willis



variant in the anterior circulation was type A, which a normal pattern in both the sexes. It is common among females ( $n = 71$ , 69.6%) at a slightly higher rate than males ( $n = 127$ , 64.1%). The type E variant in the posterior circulation is most common in both genders. It is also slightly more common in males ( $n = 69$ , 34.8%) than in females ( $n = 29$ , 28.4%).

Qiu *et al.* [15] analyzed cerebral images of 2246 healthy individuals using typical MRI and MRA. The overall incidence of CW integrity was 12.24%, with 7.57% nonvariation integral CW. The incidences of partial integrity and nonintegrity were 70.17% and 17.59%, respectively [16]. The integrity rate of the anterior circulation was 78.58%, with a close correlation with the developmental condition of the A1 segment of the ACA. The nonintegrity rate of posterior circulation was 83.93% with an incidence rate of 15.85% for hypoplasia of PCA-P1 variation.

Various studies have been done to explain the reason of development of fetal-type PCA. Van Overbeeke *et al.* [17] categorized the various configuration of COW in fetus. There is a transitional type in early fetal life, in which diameters of P1-PCA and PcomA are equal; with the growth of the fetus, this would either transform into adult type in which P1 diameter is larger than the PcomA diameter or into fetal type in which diameter of the P1 is smaller than diameter of PcomA. Van Overbeeke *et al.* [17] and Milenković *et al.* [18] concluded that rapid development of occipital lobes occurs during fetal life that increases the demand for vasculature which significantly affects the final form of CW, particularly in the posterior circle, and can lead to the development of either adult or fetal configuration from transitional configuration.

Eftekhar *et al.* [19] dissected 102 brains of recently deceased Iranian males and compared variations of the CW as a whole and segmental variations with previous studies. On the whole, the frequencies of the different variants of the entire cerebral arterial circle and segmental variations were comparable with previous studies. More specifically, variants with uni- and bi-lateral hypoplasia of PcomAs were the most common and were similar to the previous works. In 3% of patients, both right and left PcomAs were absent. They concluded that the anatomical variations found in the cerebral arterial circle of the Iranian males were not significantly different to those of more diverse populations reported in the literature.

Saikia *et al.* [20] retrospectively evaluated gross dissection findings in 70 human cadavers and equal numbers of MRAs in healthy individuals. Only 31 (22.14%) of the total 140 cases presented with a complete CW, of which 14 (20%) were in cadaveric specimens and 17 (24.18%) were in the MRA group. A unilateral hypoplastic PcomA was the most common variation observed in the study (19.28%).

Chen *et al.* [8] retrospectively reviewed results of 507 consecutive healthy subjects (241 males, 266 females, aged 18–89 years) undergoing 3D-TOF-MRA of the CW. Of these, 397 (78.30%) cases had complete anterior parts, 129 (25.44%) cases had complete posterior parts, and 89 (21.30%) cases demonstrated the entire configuration of the CW. Variant A was the most common anterior type all ages and both genders.

Type E was the most common posterior circle variant. The observations in our study were compatible with the findings of this study.

Maaly and Ismail [21] retrospectively evaluated 3D-TOF-MRA in 250 patients. Complete anterior and posterior parts of the CW were seen in 68.3%, and 38.3%, respectively. An entirely complete CW was seen in 46.7%, with a slightly higher prevalence in females and younger subjects than males and older subjects. The anterior part of the CW was complete in 75% of the younger and 65% in older subjects. The most common variations in younger patients were the a and b variants and in older patients were the a and g variants. The posterior part of the CW was complete in 40% of younger and 37.5% of older patients. A unilateral fetal-type PCA was found in 37.8% of cases and bilateral fetal-type PCAs were found in 31.7%. The findings of our study were compatible with those of this study.

Tekale and Ambiyé [22] evaluated the CW in 100 healthy persons with 3D-TOF-MRA of the brain (74 individuals aged 18–60 years and 26 aged over 60 years, of both genders). All component vessels of the circle were assessed by measuring the diameter. Variations were most commonly found in the communicating arteries, less commonly in the cerebral arteries, and very rarely noted in the ICA. The most common variation was hypoplasia and absence of the bilateral PCOMs.

Harizi-Shemsi *et al.* [23] conducted a case-control study in Albania including 60 patients (30 patients with hemorrhagic stroke and 30 with ischemic stroke) and 60 controls (individuals without cerebrovascular pathologies) to compare the prevalence of anomalies of the CW. There were 14 patients with anatomical variations, 6 (42.9%) cases with ACA (A1 segment) anomalies, 4 (28.6%) with AcomA variations, 1 (7.1%) with a PcomA anomaly, and 3 (21.4%) with P1-PCA variations.

Hashemi *et al.* [24] evaluated 169 (84.5%) males and 31 (15.5%) females aged between 16 and 71 years. A total of 69 (34.5%) of the 200 had the typical anatomy of the CW. The remaining 65.5% had variations, most common of which was hypoplasia of the PcomAs.

In a large study of Indian subcontinent patients, Kapoor *et al.* [25] observed that 45.2% conformed to the typical pattern, with variations in the rest of the study group. In other studies, a complete CW was observed in 4.6%–72.2%. In autopsy studies, the incidence of a complete CW ranged from 14.2% to 52.3%, relatively lower than clinical observations [26]. Several reasons could account for this variation. First, differences in subject selection could be a factor. Healthy volunteers were included in some studies with additional subjects without vascular disorders or neurological disease. The second possible reason is differences in observation methods. Phase-contrasted MRA was utilized in addition to TOF in some studies [27].

In a study by Hafez *et al.* [28], an entirely complete CW was seen in 45%. Other studies showed results of 68%–78%, in agreement with our results. The prevalence of the complete

circle in our study was higher in females than males, similar to the results of published studies by Hafez *et al.* [28], Chen *et al.* [8], and Krabbe-Hartkamp *et al.* [29]. All of these studies used 3D-TOF-MRA in examination of the CW. Although 3D-TOF-MRA has a high sensitivity and specificity for depicting the anatomy of the CW, it has some limitations in displaying small collateral channels because of the turbulent flow, saturation effect of slow flow or long in-plane flow, or slower velocity of blood adjacent to the wall due to laminar flow. The sensitivity of 3D-TOF-MRA in detection of small communicating vessels improves when flow through these channels increases, since an increase in flow velocity improves signal intensity. Nonvisualization of vessels on TOF-MRA can be due to very slow or negligible flow within a patent vessel or true absence of the vessel. The lower limit of normal vessel diameters is arbitrary and affects the number of vessel segments classified as hypoplastic, which also affects the prevalence of circles defined as complete [30].

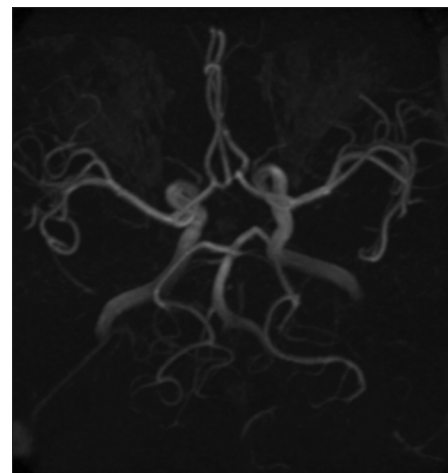
Horikoshi *et al.* [31] used a simplified classification with six types to categorize all variations. It was believed that many subtypes might be obscured and gender differences were not addressed. This classification may be too rough to demonstrate the complexity of the CW. In addition, the definition of hypoplasia was not well documented. Therefore, we decided to classify the anterior and posterior components separately as they are easily assessed with respect to anatomic differences. The results of our MRA findings demonstrated good correlation with similar studies performed in the general population without cerebrovascular diseases by other groups worldwide.

The foundation of the CW lies in vessels which are formed in the early stages of fetal life, some of which succumb to involution, while others are evolving to supply developing structures. The fetal patterns of morphological variants are a result of agenesis or involution during embryonic development. A positive association between anatomical variations in the CW and the presence of aneurysms has been demonstrated in individuals who experienced subarachnoid hemorrhage [32]. Previous international studies have linked anomalies of the CW with the development and severity of symptoms of different CVAs, including infarctions, aneurysms, and several other vascular disorders.

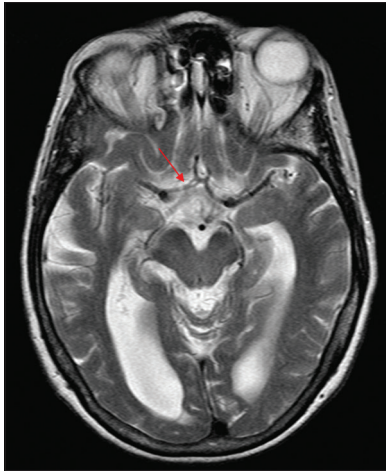
Variations in the anterior and posterior CW in the present study, in other studies, conducted in India, and in those of more diverse populations reported in the literature appear to be similar and are possibly due to embryonic development. There have been no statistically significant differences between the prevalence of the variations in the CW in each segment in our study or observations from other groups. Those reported from Iran are similar regarding the more common occurrence of aplasia of the PcomA arteries versus those reported from Morocco and France [33]. It is suggested that congenital anatomical variation in the CW is not under the influence of race or ethnicity in different populations. It has been reported that in Asians, the incidence of intracranial atherosclerosis in anterior circulation stroke is much higher than in Caucasians [34]. The prevalence of

posterior circulation stroke among Asians has been reported to be much higher than in the West [35]. The average age of patients with stroke in developing countries is 15 years younger than in developed countries [36]. The reasons for these differences are not well understood, and the roles of anatomy and pathology of the cerebral arteries in the pathogenesis of cerebrovascular diseases in different ethnic or racial groups are not very clear.

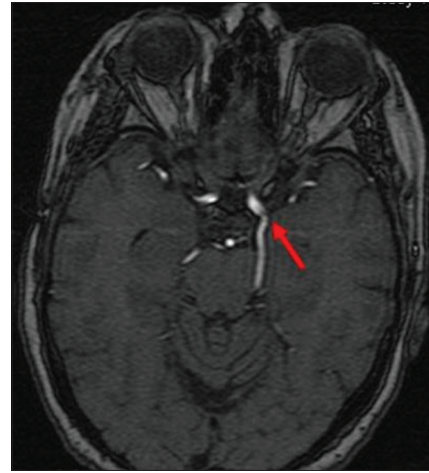Few variants of CW have been briefly outlined here. Trifurcation of the ACA is defined as the occurrence of three A2 segments. The callosomarginal artery (also known as median artery of corpus callosum) is the largest branch of the pericallosal artery [Figure 4]. It runs in or posteriorly to the cingulate sulcus and runs a course parallel to the pericallosal artery where it divides to give two or more cortical branches. Duplicated A1 segment is an infrequent variation. It has been reported to occur in 4% of subjects in cadaveric studies and in aneurysmal surgery [37]. Most clinically reported cases of A1 duplication are angiographically occult variations later identified during AcomA aneurysm surgery usually without consequences [Figure 5]. Fetal posterior cerebral artery with hypoplastic P1 segment is a common variant in the posterior cerebral circulation. The PcomA is larger than the P1-PCA and supplies the bulk of the blood to the PCA [Figure 6]. Among the variation in the anatomy of the CW, a small degree of asymmetry of anterior arteries is commonly found. The variations related with the A1 segment of ACA are agenesis, hypoplasia, and duplication [Figure 7]. Persistent trigeminal artery is the largest of the fetal carotid-basilar anastomotic arteries, and it persists for the longest embryonic period. The artery usually involutes after the development of the PcomA. A thorough understanding of the anatomical and angiographic features of this persistent embryonic arterial channel is of utmost importance when making therapeutic decisions and embarking on surgical or endovascular intervention for any pertinent pathological condition [Figure 8]. Azygos ACA



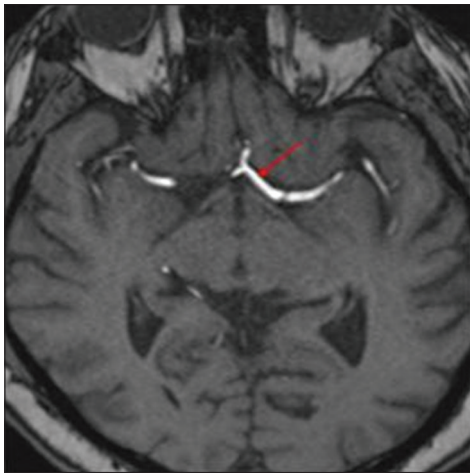
**Figure 4:** Time-of-flight magnetic resonance angiogram maximum intensity projection image showing three A2 segments of the anterior cerebral arteries. Trifurcation of the anterior cerebral artery is defined as the occurrence of three A2 segments. The central (anomalous) artery arises from the anterior communicating artery and is known as a median artery of the corpus callosum



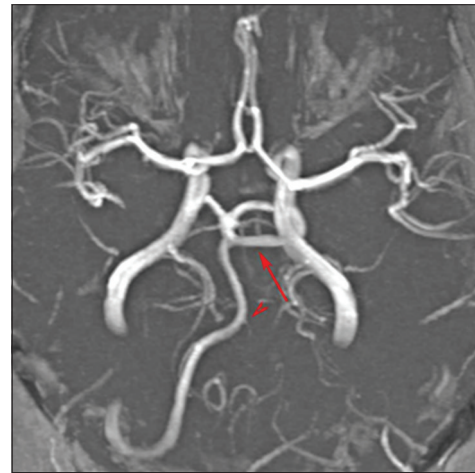**Figure 5:** T2-weighted magnetic resonance imaging showing a right duplicated A1 segment (arrow). Rarely, the optic nerve can go through the fenestration, which implies a very different embryologic pattern from the more common supraoptic fenestration



**Figure 6:** Three-dimensional time-of-flight magnetic resonance angiogram source image showing a left fetal posterior cerebral artery with hypoplastic P1 segment (arrow). Fetal origin of the posterior cerebral artery occurs when the embryonic posterior cerebral artery fails to regress



**Figure 7:** Time-of-flight magnetic resonance angiogram showing a left asymmetric A1 segment (arrow). The asymmetry is due to a dominant A1 segment on one side and a hypoplastic segment on the other side



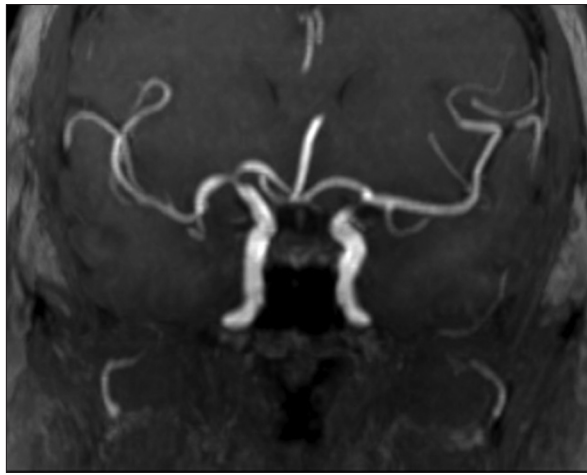
**Figure 8:** Magnetic resonance angiogram maximum intensity projection image demonstrating a lateral persistent trigeminal artery Saltzman type 1 with a hypoplastic vertebral artery. A persistent trigeminal artery is the most common primitive carotid-basilar anastomosis that persists into adulthood

is an uncommon to rare variant seen in which the two A1 segments of the ACA join to form a single trunk [Figure 9]. Persistent hypoglossal artery arises from the ICA between the C1 and C2 vertebral levels and traverses through the hypoglossal canal to join the vertebrobasilar system. The persistent hypoglossal artery is the second most frequent carotid vertebrobasilar arterial anastomoses, after the persistent trigeminal artery, and usually arises from the ICA and rarely from the external carotid artery. Identification of this rare anomaly is important before carotid endarterectomy or skull base surgery as injury to this vessel can lead to ischemia in the posterior circulation territory where it forms the sole arterial supply [Figure 10]. Accessory middle cerebral artery may be important in supplying collateral blood flow to the frontal lobe and basal ganglia through the perforating arteries [Figure 11]. ACA triplication is an anatomic variant of minor clinical significance with prevalence slightly more than the azygous variant [Figure 12].

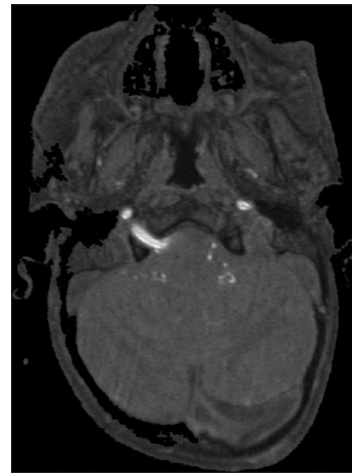## CONCLUSION

The present study is based on MRA analysis of patients with clinical suspicion of CVA. Morphological variations are quite frequent in the CW in humans. Because of the variability, clinical manifestation may vary considerably from one individual to another, and the effectiveness of collateral circulation may be greatly influenced. Whether this is a risk factor for stroke should be subject to further investigation. Our study of MRA in subjects from Southern India gives an indirect correlation between the variations in the CW in this region and published data worldwide. TOF-MRA limitations include dependence on amount and direction of flow as well as the exact technique employed. Therefore, smaller arteries with very little flow might not be detected, leading to interpretation as an aplastic instead of a hypoplastic artery. Our findings show that the configuration of the CW may vary greatly in the general population. The prevalence of a complete configuration of the circle was 16.5% and was slightly

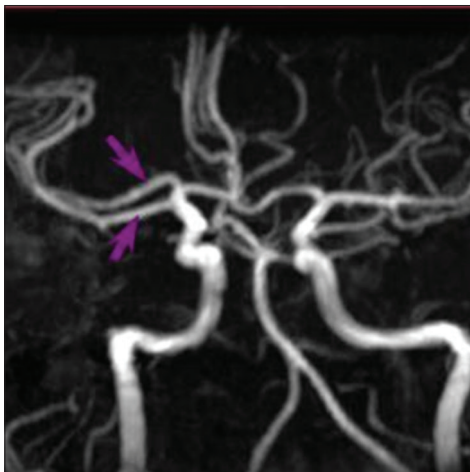




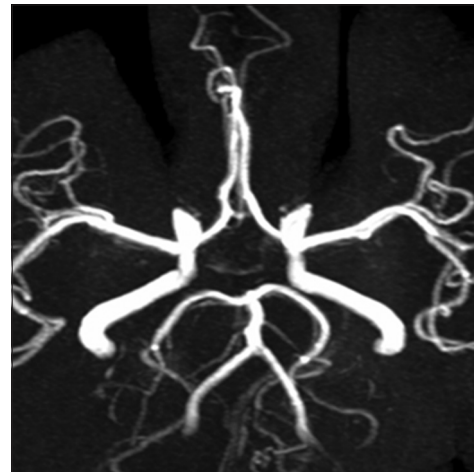**Figure 9:** Magnetic resonance angiogram maximum intensity projection image demonstrating an azygous anterior cerebral artery, which represents persistence of the embryonic median artery of the corpus callosum



**Figure 10:** Axial source image from three-dimensional time-of-flight magnetic resonance angiogram demonstrating an anomalous artery coursing through the right hypoglossal canal to form the basilar artery with hypoplastic vertebral arteries. The persistent hypoglossal artery is the second most common carotid-vertebrobasilar artery anastomosis



**Figure 11:** Three-dimensional time-of-flight maximum intensity projection image demonstrating a right accessory middle cerebral artery (arrows). A smaller middle cerebral artery branch arising from the anterior cerebral artery is designated an accessory middle cerebral artery



**Figure 12:** Three-dimensional source maximum intensity projection image demonstrating anterior cerebral artery triplication with two A2 segments and a smaller frontopolar branch arising from the anterior communicating artery. An accessory/triplicated anterior cerebral artery is an additional vessel arising from the anterior communicating artery and most likely represents a persistent median callosal artery

higher in females than males and younger (below 50 years) than older subjects. In the present study, a complete anterior CW was common in 77% of all patients and complete posterior circle was common in 33% of all patients. The most common anterior circle variant was type A (normal anterior configuration) with a prevalence of 66%. The most common posterior circle variant was type E in 53%. Overall, CW variants were slightly more common among females than males. Incidences of associated anomalies, such as aneurysm or AVM, were comparable to that described in the literature.

**Financial support and sponsorship**

Nil.

**Conflicts of interest**

There are no conflicts of interest.

**REFERENCES**

1. Symonds C. The circle of Willis. *Br Med J* 1955;1:119-24.

2. Meyer A, Hierons R. Observations on the history of the ‘circle of Willis’. *Med Hist* 1962;6:119-30.

3. Battacharji SK, Hutchinson EC, McCall AJ. The circle of Willis – The incidence of developmental abnormalities in normal and infarcted brains. *Brain* 1967;90:747-58.

4. Hendrikse J, van Raamt AF, van der Graaf Y, Mali WP, van der Grond J. Distribution of cerebral blood flow in the circle of Willis. *Radiology* 2005;235:184-9.

5. Fisher CM. The circle of Willis: Anatomical variations. *Vasc Dis* 1965;2:99-105.

6. Ghazali RM, Shuaib IL. Comparison between 3D TOF magnetic resonance angiography and intraarterial digital subtraction angiography in imaging the circle of Willis. *Malays J Med Sci* 2003;10:37-42.

7. Tan KS, Navarro JC, Wong KS, Huang YN, Chiu HC, Pongvarin N, et al. Clinical profile, risk factors and aetiology of young ischaemic stroke patients in Asia: A prospective, multicentre, observational, hospital-based study in eight cities. *Neurol Asia* 2014;19:117-27.

8. Chen HW, Yen PS, Lee CC. Magnetic resonance angiographic evaluation of circle of Willis in general population: A morphologic study in 507 cases. *Chin J Radiol* 2004;29:223-9.
9. Prince EA, Ahn SH. Basic vascular neuroanatomy of the brain and spine: What the general interventional radiologist needs to know. *Semin Intervent Radiol* 2013;30:234-9.
10. Wong KS. Risk factors for early death in acute ischemic stroke and intracerebral hemorrhage: A prospective hospital-based study in Asia. Asian acute stroke advisory panel. *Stroke* 1999;30:2326-30.
11. van Seeters T, Hendrikse J, Biessels GJ, Velthuis BK, Mali WP, Kappelle LJ, et al. Completeness of the circle of Willis and risk of ischemic stroke in patients without cerebrovascular disease. *Neuroradiology* 2015;57:1247-51.
12. Gunnal SA, Farooqui MS, Wabale RN. Anatomical variations of the circulus arteriosus in cadaveric human brains. *Neurol Res Int* 2014;2014:687281.
13. Iqbal S. A comprehensive study of the anatomical variations of the circle of Willis in adult human brains. *J Clin Diagn Res* 2013;7:2423-7.
14. Cui Y, Xu T, Chen J, Tian H, Cao H. Anatomic variations in the anterior circulation of the circle of Willis in cadaveric human brains. *Int J Clin Exp Med* 2015;8:15005-10.
15. Qiu C, Zhang Y, Xue C, Jiang S, Zhang W. MRA study on variation of the circle of Willis in healthy Chinese male adults. *Biomed Res Int* 2015;2015:976340.
16. Kluytmans M, van der Grond J, van Everdingen KJ, Klijn CJ, Kappelle LJ, Viergever MA. Cerebral hemodynamics in relation to patterns of collateral flow. *Stroke* 1999;30:1432-9.
17. Van Overbeeke JJ, Hillen B, Tulleken CA. A comparative study of the circle of Willis in fetal and adult life. The configuration of the posterior bifurcation of the posterior communicating artery. *J Anat* 1991;176:45-54.
18. Milenković Z, Vucetić R, Puzić M. Asymmetry and anomalies of the circle of Willis in fetal brain. Microsurgical study and functional remarks. *Surg Neurol* 1985;24:563-70.
19. Eftekhari B, Dadmehr M, Ansari S, Ghodsi M, Nazparvar B, Ketabchi E, et al. Are the distributions of variations of circle of Willis different in different populations? – Results of an anatomical study and review of literature. *BMC Neurol* 2006;6:22.
20. Saikia B, Handique A, Phukan P, Lynser D, Sarma A. Circle of Willis: Variant forms and their embryology using gross dissection and magnetic resonance angiography. *Int J Anat Res* 2014;2:344-53.
21. Maaly MA, Ismail AA. Three dimensional magnetic resonance angiography of the circle of Willis: Anatomical variations in general Egyptian population. *Egypt J Radiol Nucl Med* 2011;42:405-12.
22. Tekale VM, Ambiye MV. A study of circle of Willis by MR angiography. *Int J Anat Res* 2016;4:2542-6.
23. Harizi-Shemsi E, Rroji A, Gabrani S. A short overview of anatomical variations of the circle of Willis in adult human brains. *Alban Med J* 2014;4:111-4.
24. Hashemi SM, Mahmoodi R, Amirjamshidi A. Variations in the anatomy of the Willis' circle: A 3-year cross-sectional study from Iran (2006-2009). Are the distributions of variations of circle of Willis different in different populations? Result of an anatomical study and review of literature. *Surg Neurol Int* 2013;4:65.
25. Kapoor K, Singh B, Dewan LI. Variations in the configuration of the circle of Willis. *Anat Sci Int* 2008;83:96-106.
26. Fawcett E, Blachford JV. The circle of Willis: An examination of 700 specimens. *J Anat Physiol* 1905;40:63.2-70.
27. De Silva KR, Silva R, Gunasekera WS, Jayasekera RW. Prevalence of typical circle of Willis and the variation in the anterior communicating artery: A study of a Sri Lankan population. *Ann Indian Acad Neurol* 2009;12:157-61.
28. Hafez KA, Afifi NM, Saudi FZ. Anatomical variations of the circle of Willis in males and females on 3D MR angiograms. *Egypt J Hosp Med* 2007;26:106-21.
29. Krabbe-Hartkamp MJ, van der Grond J, de Leeuw FE, de Groot JC, Algra A, Hillen B, et al. Circle of Willis: Morphologic variation on three-dimensional time-of-flight MR angiograms. *Radiology* 1998;207:103-11.
30. Kamath S. Observations on the length and diameter of vessels forming the circle of Willis. *J Anat* 1981;133:419-23.
31. Horikoshi T, Akiyama I, Yamagata Z, Sugita M, Nukui H. Magnetic resonance angiographic evidence of sex-linked variations in the circle of Willis and the occurrence of cerebral aneurysms. *J Neurosurg* 2002;96:697-703.
32. Kayembe KN, Sasahara M, Hazama F. Cerebral aneurysms and variations in the circle of Willis. *Stroke* 1984;15:846-50.
33. El Khamlichi A, Derraz S, El Ouahabi A, Aghzadi A, Jamily A, El Azouzi M. Pattern of cerebral aneurysms in Morocco: Review of the concept of their rarity in developing countries: Report of 200 cases. *Neurosurgery* 2001;49:1224-9.
34. White H, Boden-Albala B, Wang C, Elkind MS, Rundek T, Wright CB, et al. Ischemic stroke subtype incidence among Whites, Blacks, and Hispanics: The northern Manhattan study. *Circulation* 2005;111:1327-31.
35. Bang OY. Considerations when subtyping ischemic stroke in Asian patients. *J Clin Neurol* 2016;12:129-36.
36. Kim BJ, Kim JS. Ischemic stroke subtype classification: An Asian viewpoint. *J Stroke* 2014;16:8-17.
37. Weil AG, Bojanowski MW, Scholtes F, Darsaut TE, Signorelli F, Weill A. Angiographic pitfall: Duplicated tapered A1 segment of the anterior cerebral artery mimicking an anterior communicating artery aneurysm. *Interv Neuroradiol* 2011;17:179-82.