



# Anterior Cruciate Ligament Reconstruction With a Partial-Thickness Quadriceps Tendon Graft Secured With a Continuous-Loop Fixation Device

Jonathan D. Hughes, M.D., Ravi Vaswani, M.D., Christopher M. Gibbs, M.D., Robert T. Tisherman, M.D., and Volker Musahl, M.D.

**Abstract:** Anterior cruciate ligament reconstruction using quadriceps tendon (QT) autograft has recently gained popularity because newer techniques allow harvest of a robust graft with little soft-tissue dissection or donor-site morbidity. The QT graft can provide a safe, reproducible, and versatile option for primary and revision anterior cruciate ligament reconstruction with equivalent outcomes and failure rates to those of bone–patellar tendon–bone and hamstring tendon grafts. Therefore, continued improvement in surgical technique may help to further improve patient outcomes. This study introduces a modification of current QT techniques using a partial-thickness graft with continuous-loop EndoButton fixation (Smith & Nephew, Andover, MA).

Anterior cruciate ligament reconstruction (ACLR) is commonly performed to allow return to sports and prevent adverse outcomes associated with nonoperative management of anterior cruciate ligament (ACL) rupture, including symptomatic knee laxity and subsequent meniscal tears.<sup>1</sup> Currently, anatomic single-bundle ACLR is the gold standard for restoring native anterior tibial translation and rotatory knee stability.<sup>2,3</sup> However, debate remains over the ideal graft choice.<sup>4</sup> A variety of autograft options for ACLR exist, including bone–patellar tendon–bone (BPTB), hamstring tendon (HS), and quadriceps tendon (QT).

Interest in the use of QT has increased recently with the development of less invasive harvesting techniques, resulting in outcomes comparable to those of BPTB and HS techniques.<sup>5,6</sup> Current QT techniques provide a reliable and safe alternative in selected patients without compromising graft strength or postoperative outcomes. Therefore, continued improvement in surgical technique may help to further improve patient outcomes. This study introduces a modification of current QT techniques using a partial-thickness graft with continuous-loop EndoButton fixation (Smith & Nephew, Andover, MA) with the goal of improving on an existing method for ACLR.

## Surgical Technique

### Intraoperative Setup

The patient is placed supine, and a tourniquet is placed on the proximal thigh. A leg holder is placed over the tourniquet, with the contralateral leg placed in the lithotomy position. The foot of the bed is dropped, with the operative extremity hanging free. The leg is prepared and draped in a standard manner.

### Graft Harvest

An incision is made starting 5 mm proximal to the patella and extending proximally 20 to 30 mm with a No. 10 blade directly superficial to the QT (Fig 1, Video 1). A periosteal elevator is used to remove adhesions and develop a plane from the proximal pole of the patella to

From the Division of Sports Medicine, Department of Orthopaedic Surgery, University of Pittsburgh, Pittsburgh, Pennsylvania, U.S.A.

The authors report the following potential conflicts of interest or sources of funding: J.D.H. receives educational support from Exactech, Stryker, Synthes, Globus, Zimmer Biomet, Arthrex, DJO, and Pyland Medical. R.T.T. receives educational support from Johnson & Johnson. V.M. receives personal fees from Smith & Nephew; is a board member of ISAKOS; is Editor in Chief of *KSSTA*; receives educational support from Arthrex, DePuy Synthes, and ConMed; and receives royalties from Springer. Full ICMJE author disclosure forms are available for this article online, as [supplementary material](#).

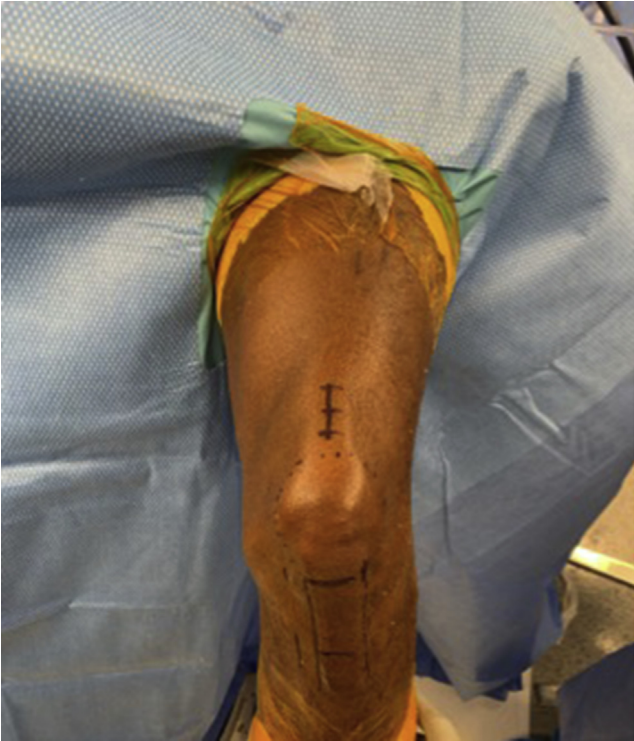Received October 22, 2019; accepted January 3, 2020.

Address correspondence to Volker Musahl, M.D., University of Pittsburgh, UPMC Freddie Fu Sports Medicine Center, 3200 S Water St, Pittsburgh, PA 15203, U.S.A. E-mail: [musahlv@upmc.edu](mailto:musahlv@upmc.edu)

© 2020 by the Arthroscopy Association of North America. Published by Elsevier. This is an open access article under the CC BY-NC-ND license (<http://creativecommons.org/licenses/by-nc-nd/4.0/>).

2212-6287/191296

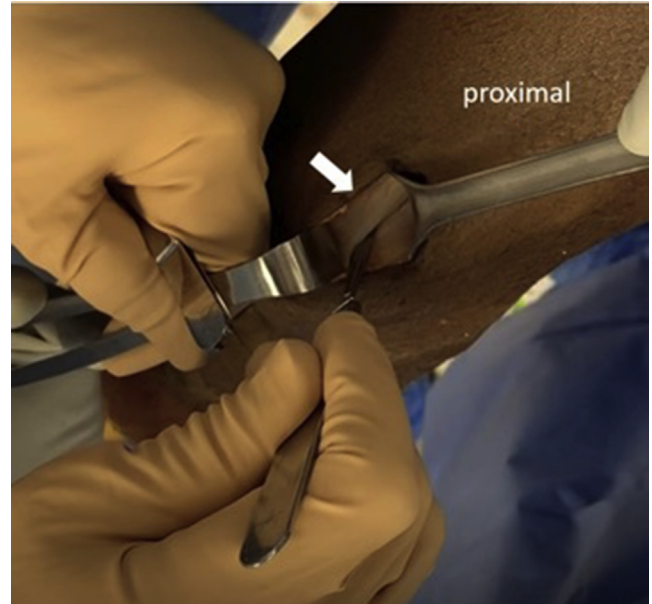<https://doi.org/10.1016/j.eats.2020.01.016>



**Fig 1.** Planned incisions for quadriceps tendon harvest and arthroscopic portals for anterior cruciate ligament reconstruction in a left knee. The incision is marked with a longitudinal line starting 5 mm proximal to the patella, at its midpoint, and extended proximally 20 to 30 mm. The surgeon makes a high anterolateral portal to avoid the fat pad, as well as a far medial portal to allow for femoral drilling with a flexible reamer.

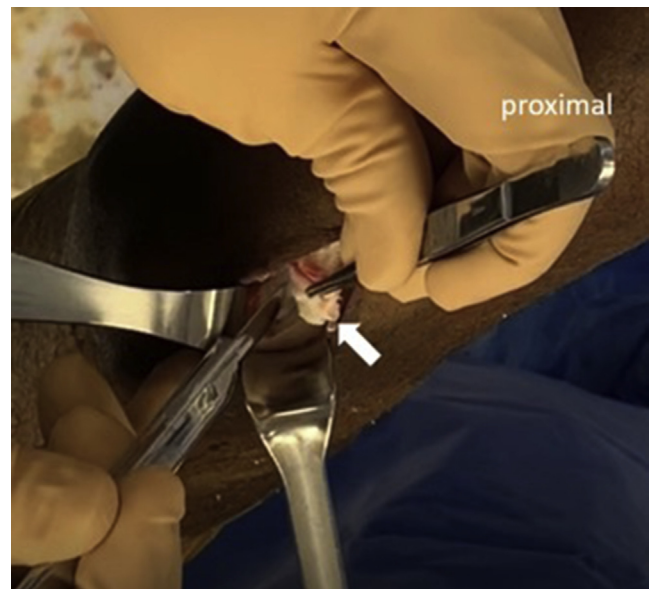
the rectus femoris musculature. Scissors are used to visualize the tendon.

With complete visualization of the QT, 2 parallel cuts are made through the tendon approximately 6 to 7 mm deep and 9 to 10 mm apart from the midportion of the tendon to the patella (Fig 2). The knife is used to elevate the distal end of the QT from the patella. Once a depth of 6 to 7 mm is achieved, the knife should be turned horizontal and the partial-thickness tendon dissected proximally, without violating the capsule (Fig 3). Once the natural plane between the rectus femoris and vastus intermedius tendons is encountered 10 mm proximal to the patella, blunt dissection can be used to extend this plane proximally. Braided suture is placed in a Krackow fashion on one side of the graft to serve as a traction suture (Fig 4). The ideal graft length is 65 to 75 mm, which will allow 15 to 20 mm of graft in the femoral tunnel and 20 to 30 mm of graft in the tibial tunnel (Fig 5). The surgeon should ensure that the rectus femoris muscle is not violated or cut because this may cause post-operative quadriceps weakness. The graft can be amputated once the desired length is achieved.



**Fig 2.** Quadriceps tendon harvest in a left knee. Two parallel cuts are made through the tendon approximately 6 to 7 mm deep and 9 to 10 mm apart from the midportion of the tendon to the patella. The arrow points to the medial cut; the knife creates the lateral cut.

The wound is thoroughly irrigated, and rents in the capsule are closed with braided suture. The remaining QT is closed with interrupted, figure-of-8

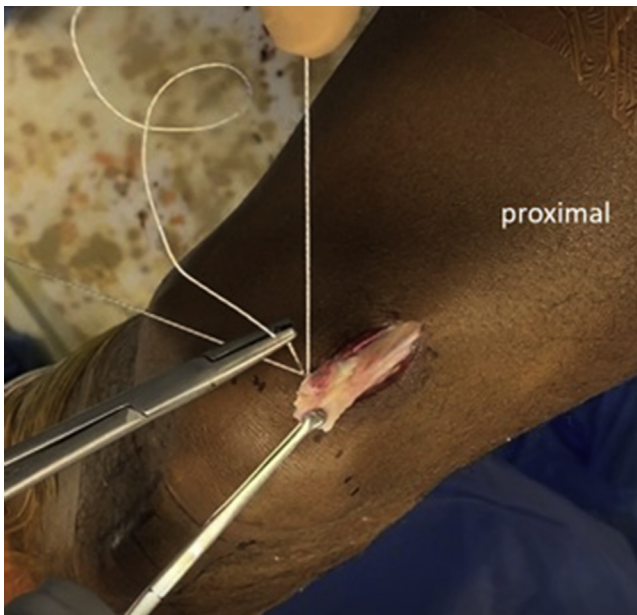


**Fig 3.** Partial-thickness graft harvest in a left knee. Once a depth of 6 to 7 mm is achieved, the knife should be turned horizontal and the partial-thickness tendon (arrow) dissected proximally, without violating the capsule. Once the natural plane between the rectus femoris and vastus intermedius tendons is encountered 10 mm proximal to the patella, blunt dissection can be used to extend this plane proximally.

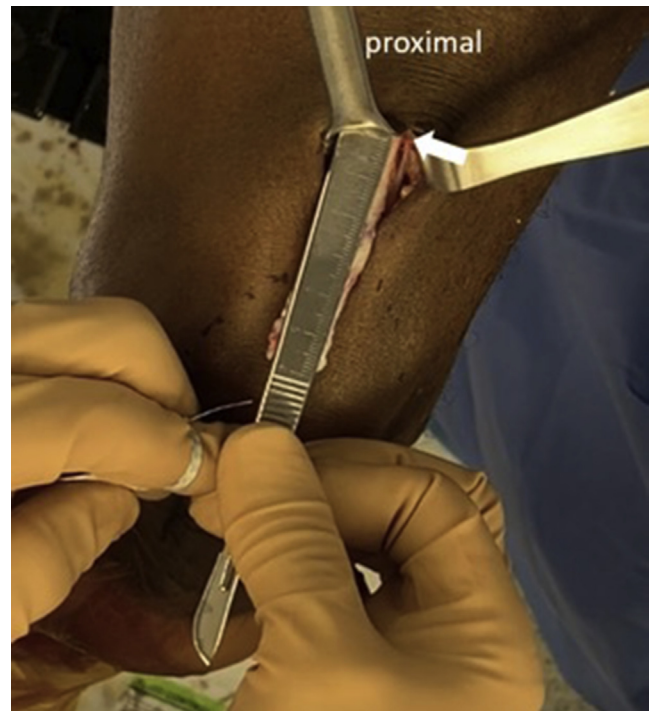
braided sutures, and the wound is closed in a layered fashion.

### Graft Preparation

The graft is taken to the back table ([Video 1](#)). A second braided suture Krackow stitch is placed on the tibial side ([Fig 6](#)). With a ruler, the graft is marked 15 mm from the end of the planned femoral side ([Fig 7](#)). The femoral side will be prepared with a continuous-loop fixation device (EndoButton CL-BTB [ECL-BTB]; Smith & Nephew). The length of the continuous loop will be determined during the tunnel-preparation stage. The long end of the continuous loop is placed through the graft at the 15-mm line ([Fig 7](#)) and passed through the small loop and over the top of the EndoButton ([Fig 8](#)). The button is pulled to tighten the construct ([Fig 8](#)). The length of the loop should be measured to ensure this length correlates with the tunnel length. A rip-stop stitch is placed in the graft with braided suture to secure the loop ([Fig 9](#)). A mark is made on the graft that corresponds to the total length of the tunnel, with a second mark made 6 mm distal to this on the graft ([Fig 10](#)). These marks will be used to ensure 15 mm of the graft enters the tunnel during graft passage. The graft is passed through the sizing block to determine the appropriate tunnel size and can be trimmed as necessary. Both ends should be the same approximate size. The graft is placed on the graft board during tunnel preparation.




**Fig 4.** Once the partial-thickness quadriceps tendon graft has been created in a left knee, a braided suture is placed in a Krackow fashion on one side of the graft to serve as a traction suture for the remainder of the harvest.



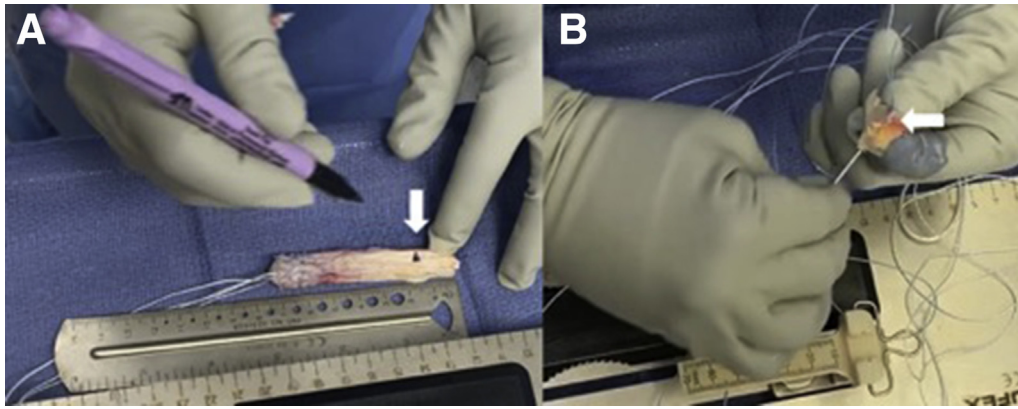
**Fig 5.** Measurement of quadriceps tendon graft length in a left knee. Before the graft is amputated, the length should be measured. The ideal graft length is 65 to 75 mm, which will allow 15 to 20 mm of graft in the femoral tunnel and 20 to 30 mm of graft in the tibial tunnel. The arrow points to the proximal aspect of the harvested tendon, which is 70 mm in length and is short of the rectus femoris musculature.

### Arthroscopy

A standard anterolateral portal is made, and a standard diagnostic arthroscopy is performed. An anteromedial portal is made under direct visualization. The ACL is debrided. The femoral footprint is visualized, and a Steadman awl is used to mark the anatomic center of the footprint. The curved endoscopic femoral guide is introduced through the anteromedial portal, and the flexible pin is manually advanced into the awl hole. With a drill, the flexible pin is advanced 3 to 4 mm into



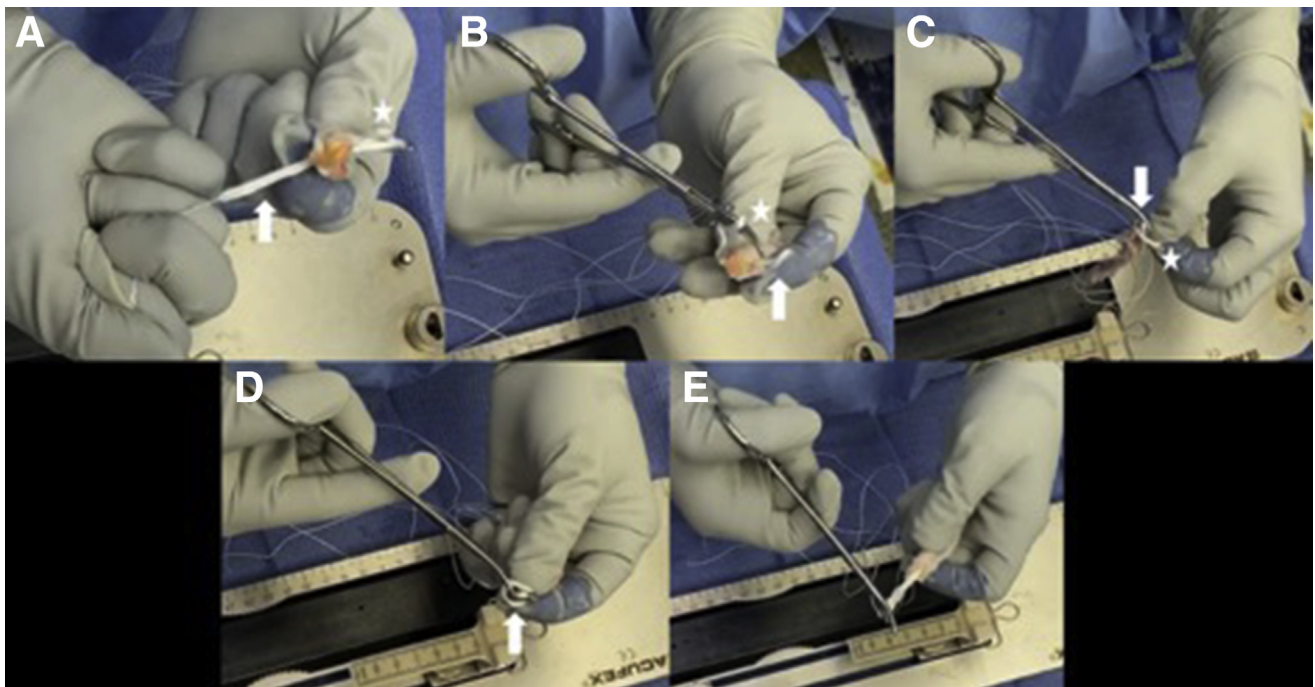
**Fig 6.** Graft preparation on back table. A second braided suture Krackow stitch is placed on the tibial side (arrow), next to the previously placed traction suture.



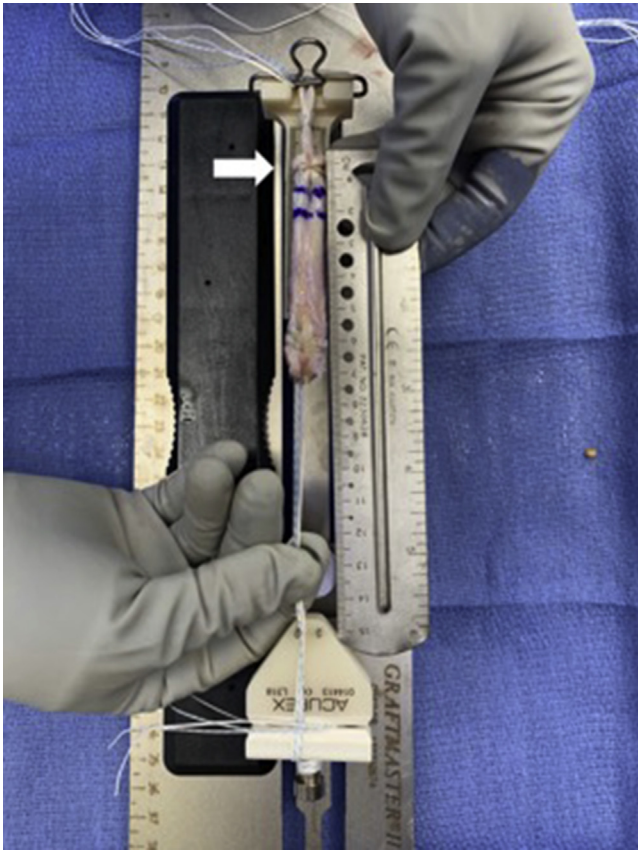
**Fig 7.** Graft measurement and preparation for EndoButton CL-BTB. (A) With a ruler, the graft is marked 15 mm from the end of the planned femoral side (arrow). (B) The long end of the continuous loop is placed through the graft at the 15-mm mark (arrow).

the tunnel, and the knee is flexed past  $120^\circ$ . The pin is advanced through the far cortex and out the skin, until the black line on the pin is flush with the femoral tunnel introitus. The black line, which comes pre-marked on the flexible pin, will allow precise measurement of the tunnel length via a prefabricated measuring device. The pin should exit the anterolateral thigh. The guide is removed. A No. 11 blade is used to make a small nick incision in the skin, and the tunnel length is measured using a tunnel measurement guide. Next, the knee is brought back to  $90^\circ$ , and the

cannulated drill is placed over the flexible pin. Caution should be taken to avoid injuring the medial femoral condyle. The drill is advanced into the bone, avoiding posterior cortex perforation, and is stopped approximately 6 to 8 mm short of the far cortex. The drill is removed, but the pin is left in place. The EndoButton reamer is now advanced through the far cortex. All debris is cleaned out of the tunnel with an arthroscopic shaver. A passing suture is placed into the pin, and one end is pulled through the tunnel, out the skin, and then secured to itself for later use.



**Fig 8.** Passage of EndoButton CL-BTB. (A) The long end of the continuous loop (arrow) is passed through the quadriceps tendon graft as described in Figure 7. The star identifies the short end of the continuous loop, which will be used in later steps. (B) Hemostats are passed through the short loop (star) and grasp the end of the long loop (arrow). (C) The long loop (arrow) is pulled through the short loop (star) and pulled tight. (D) The remainder of the long loop (arrow) is passed around the EndoButton. (E) The EndoButton is pulled taut, securing the EndoButton CL-BTB construct.



**Fig 9.** The partial-thickness quadriceps tendon autograft has been prepared with an EndoButton CL-BTB device on the femoral end and 2 braided sutures on the tibial end and will be secured with an interference screw. The arrow points to the rip-stop stitch placed on the femoral side to secure the loop in place. The ideal graft length is 65 to 75 mm.

For the tibial tunnel, a 2- to 3-cm incision is made along the anteromedial tibia, medial to the tibial tubercle and directly in line with and distal to the anteromedial portal incision. The ACL footprint is visualized, and the center is marked with electrocautery. The tibial ACL guide is introduced into the anteromedial portal and centered over this mark. The guide pin is advanced until it reaches the far cortex, and the guide is removed. The pin can be advanced through the cortex. The reamer is placed over the pin and advanced through the bone.

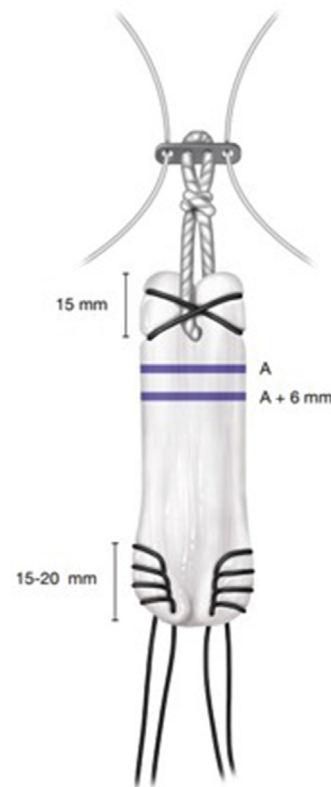
By use of an arthroscopic loop grasper–suture retriever, the free end of the passing suture is retrieved through the tibial tunnel. The graft can now be passed through the tibial tunnel by placing the free sutures of the EndoButton into the passing suture of the tibial tunnel and pulling them through the femoral tunnel. The surgeon should directly visualize the EndoButton as it enters the joint and use an arthroscopic probe to assist with graft passage through the femoral tunnel. In-line tension on the sutures is

maintained until the EndoButton flips on the outer femoral cortex.

The knee is examined to ensure full range of motion without impingement. A 1.2-mm guidewire is placed into the tibial tunnel on the inferior aspect of the graft, and a biointerference screw (BIOSURE HA Interference Screw; Smith & Nephew) is placed over the wire. Tibial fixation is performed at nearly full knee extension with axial tension on the draw sutures while a posterior drawer force is exerted on the knee. A Lachman test is performed, and the graft is probed to ensure adequate tension. The wounds are closed in a layered fashion.

## Discussion

QT is an autograft choice for ACLR that is gaining in popularity because newer techniques allow harvest of a robust graft with significantly less soft-tissue dissection than previously described.<sup>6,7</sup> It is important to note that the use of QT has also resulted in decreased rates of



**Fig 10.** Quadriceps tendon graft. The EndoButton CL-BTB is placed through the graft 15 mm from the proximal edge. A rip-stop stitch is placed through the tendon to ensure the loop does not tear through the tendon. Line A represents the EndoButton-to-tunnel length, and “A + 6 mm” represents the EndoButton-to-tunnel length plus 6 mm. Two braided sutures are placed in a Krackow fashion through the distal end of the graft, approximately 15 to 20 mm in length.

**Table 1.** Pearls and Pitfalls of Partial-Thickness Quadriceps Tendon Autograft Secured With EndoButton CL-BTB

Pearls	Pitfalls
The vastus medialis obliquus should be fully visualized. Partial-thickness tendon should be obtained if possible.	Eccentric graft harvest should not be performed. A graft harvest that is too thin should not be obtained; full-thickness tendon should be used if the quadriceps tendon is small.
The ideal graft length is 65 to 75 mm.	The surgeon must avoid violating the myotendinous junction to obtain a long graft.
A continuous loop is placed 15 mm from the end of the harvested graft on the femoral side.	The continuous loop might pull through the graft if placed too close to the edge or if a rip-stop stitch is not placed.
A rip-stop stitch is placed on the continuous-loop end of the graft. The loop length should measure approximately 15 mm.	Drilling a long tunnel will require a long loop and should be avoided.

complications commonly seen with BPTB or HS, such as postoperative anterior knee pain or hamstring weakness.<sup>5,8-10</sup>

Clinical outcome studies have also shown favorable results for QT. Lund et al.<sup>9</sup> performed a randomized controlled trial comparing QT with BPTB autografts and found similar manual knee laxity by KT-1000 assessment (MEDmetric, San Diego, CA) and clinical outcome scores. Fewer QT patients had a residual positive pivot-shift test finding and anterior knee pain postoperatively. A review of 1,554 QT autografts found a graft failure rate of 2.1% (95% confidence interval, 1.4%-2.8%), with no statistically significant difference in failure rates found between BPTB and HS autografts.<sup>5</sup> However, a recent registry study showed more knee laxity and a higher rate of pivot shift at 2 years postoperatively in the QT group compared with HS and BPTB patients.<sup>11</sup> The potential reasons for the higher failure rate include a small sample size and the fixation methods. The method introduced in this study may help improve fixation methods for QT ACLR in patients.

The ECL-BTB is a device developed for suspensory fixation of BPTB autografts that can be easily fashioned to the graft.<sup>12</sup> Kondo et al.<sup>12</sup> compared the operative time using a standard EndoButton and the ECL-BTB with hamstring autografts for double-bundle ACLR and found significantly a shorter operative time in the ECL-BTB group than the standard EndoButton group.

**Table 2.** Advantages and Disadvantages of Partial-Thickness Quadriceps Tendon Autograft Secured With EndoButton CL-BTB

Advantages	Disadvantages
Decreased complications such as anterior knee pain and hamstring weakness	Increased quadriceps weakness postoperatively
Efficiency of graft preparation	Tunnel length needed before preparation of continuous-loop fixation device
Improved graft fixation	Theoretical risk of continuous-loop pullout from harvested graft

They found no significant difference between groups in relation to measures of postoperative knee laxity. Their results show that the ECL-BTB can be applied to soft-tissue autografts and improve the speed and efficiency of graft preparation. However, an important consideration with this technique is graft length and resultant tape length. Höher et al.,<sup>13</sup> in a biomechanical study, concluded that a shorter tape length (15 mm) within the tunnel resulted in significantly less motion than a longer tape length (35 mm).

This technique is not without risks or complications (Tables 1 and 2). During graft harvest, the vastus medialis obliquus must be carefully visualized and respected because the medial border of the QT graft runs adjacent to it. Failure to identify this relation can lead to an eccentric QT graft harvest. The harvest should not extend proximally into the myotendinous junction because this may lead to hematoma formation and postoperative quadriceps weakness. During graft preparation, it is important to place a rip-stop stitch along the continuous-loop portion of the graft. Although not described, there is a theoretical risk of the loop ripping through the soft-tissue graft.

This article describes the use of the ECL-BTB with QT autograft. By using this device, surgeons may be able to improve the efficiency of graft preparation in ACLR and improve graft fixation.

## References

- Sanders TL, Pareek A, Kremers HM, et al. Long-term follow-up of isolated ACL tears treated without ligament reconstruction. *Knee Surg Sports Traumatol Arthrosc* 2017;25:493-500.
- Fu FH, van Eck CF, Tashman S, Irrgang JJ, Moreland MS. Anatomic anterior cruciate ligament reconstruction: A changing paradigm. *Knee Surg Sports Traumatol Arthrosc* 2015;23:640-648.
- Zaffagnini S, Signorelli C, Grassi A, et al. Anatomic anterior cruciate ligament reconstruction using hamstring tendons restores quantitative pivot shift. *Orthop J Sports Med* 2018;6:2325967118812364.

4. Kaeding CC, Pedroza AD, Reinke EK, et al. Change in anterior cruciate ligament graft choice and outcomes over time. *Arthroscopy* 2017;33:2007-2014.
5. Mouarbes D, Menetrey J, Marot V, Courtot L, Berard E, Cavaignac E. Anterior cruciate ligament reconstruction: A systematic review and meta-analysis of outcomes for quadriceps tendon autograft versus bone-patellar tendon-bone and hamstring-tendon autografts. *Am J Sports Med* 2019;47:3531-3540.
6. Sheehan AJ, Musahl V, Slone HS, et al. Quadriceps tendon autograft for arthroscopic knee ligament reconstruction: Use it now, use it often. *Br J Sports Med* 2018;52:698-701.
7. Mehran N, Damodar D, Yang JS. Quadriceps tendon autograft in anterior cruciate ligament reconstruction. *J Am Acad Orthop Surg* 2020;28:45-52.
8. Han HS, Seon SC, Lee S, Lee MC. Anterior cruciate ligament reconstruction: Quadriceps versus patellar autograft. *Clin Orthop Relat Res* 2008;466:198-204.
9. Lund B, Nielsen T, Fauno P, Christiansen SE, Lind M. Is quadriceps tendon a better graft choice than patellar tendon? A prospective randomized study. *Arthroscopy* 2014;30:593-598.
10. Slone HS, Romine SE, Premkumar A, Xerogeanes JW. Quadriceps tendon autograft for anterior cruciate ligament reconstruction: A comprehensive review of current literature and systematic review of clinical results. *Arthroscopy* 2015;31:541-554.
11. Lind M, Strauss MJ, Nielson TG. Quadriceps tendon graft has higher revision rates than hamstring and patella tendon grafts for ACL reconstruction: Results from the Danish Knee Ligament Reconstruction Registry. *Knee Surg Sports Traumatol Arthrosc* 2019;22:1-7.
12. Kondo E, Yasuda K, Miyatake S, Kitamura N, Tohyama H, Yagi T. Clinical comparison of two suspensory fixation devices for anatomic double-bundle anterior cruciate ligament reconstruction. *Knee Surg Sports Traumatol Arthrosc* 2012;20:1261-1267.
13. Höher J, Livesay GA, Ma CB, Withrow JD, Fu FH, Woo SLY. Hamstring graft motion in the femoral bone tunnel when using titanium button/polyester tape fixation. *Knee Surg Sports Traumatol Arthrosc* 1999;7:215-219.