



## Case Letter

## Dermoscopy of onychodystrophy in a patient with connective tissue disease

Claire Stewart BA<sup>a</sup>, Shari R. Lipner MD, PhD<sup>b,\*</sup><sup>a</sup>Shari Lipner to Weill Cornell Medicine, New York, NY, United States<sup>b</sup>Department of Dermatology, Weill Cornell Medical College, New York, NY, United States

Dear Editor,

A 51-year-old woman with systemic sclerosis (SSc) and Raynaud's phenomenon with Scl70 antibodies presented with discomfort and bleeding when clipping her right third fingernail. Symptoms developed after ulceration of that digit >20 years ago. She reported hand stiffness and numbness. Other medical conditions included chronic paronychia, interstitial lung disease, and gastroesophageal reflux disease. Medications included nystatin-triamcinolone ointment, mycophenolate mofetil, omeprazole, amlodipine, aspirin, and norethindrone.

Clinical examination of the right third fingernail was significant for parallel bands of leukonychia, nail fold erythema, and a non-tender flesh-colored plaque along the undersurface of the nail plate, partially obliterating the distal nail groove. Contact dermoscopy showed obliteration of the distal nail groove and adherence of the distal nail bed to the nail plate ventral surface, consistent with ventral pterygium or pterygium inversum unguis (Figs. 1 and 2). Histopathology testing of a nail clipping was positive for numerous yeast forms.

Ventral pterygium was first described and differentiated from dorsal pterygium, or pterygium unguis, in 1973 (Caputo and Prandi, 1973). With ventral pterygium, the hyponychium projects forward and attaches to the ventral nail surface. By comparison, the proximal nail fold gradually extends over the nail plate, leading to separate lateral segments in a dorsal pterygium.

Patients with ventral pterygium typically present with pain and bleeding associated with nail trimming. Upon examination, a sub-ungual keratotic thickening is seen between the ventral nail plate and the hyponychium, which may obliterate the distal nail groove. Fingernails are involved more frequently than toenails (Richert et al., 2000). With dermoscopy, adherence and overgrowth of the hyponychium along the undersurface of the nail is more clearly appreciated.

Acquired ventral pterygium secondary to scarring of the distal nail groove is much more common than congenital cases (Marie et al., 2017). Connective tissue diseases, including SSc, systemic

lupus erythematosus, and Raynaud's phenomenon, are among the most frequent etiologies (Marie et al., 2017). Microangiopathy and vasospasm are hypothesized to compromise blood flow, causing distal ischemia, ulceration, and scarring (Marie et al., 2017). In a review of 129 patients with SSc, 19.4% of patients with SSc for >3 years presented with ventral pterygium and fingernail changes correlated with more severe disease (Marie et al., 2017).

Ventral pterygium is also associated with subungual exostosis, neurofibromatosis, leprosy, and hemiparesis secondary to stroke (Richert et al., 2000). Formaldehyde-containing nail hardeners, acrylic nails, and ultraviolet/light emitting diode gel polish manicures have similarly been implicated (Cervantes et al., 2018). Women are affected more commonly than men, possibly due to a higher incidence of connective tissue diseases and more frequent manicuring (Baek et al., 2014).

The mainstay of management involves treatment of the underlying cause to prevent scarring and involvement of other nails. Surgery involves the removal of a portion of the distal nail plate to resect the distal nail bed and hyponychium. Our patient's lack of functional impact and minimal concern led us to manage conservatively with education about her condition and close follow-up with dermatology and rheumatology for management of her connective tissue disease.

**Conflict of Interest**

None.

**Funding**

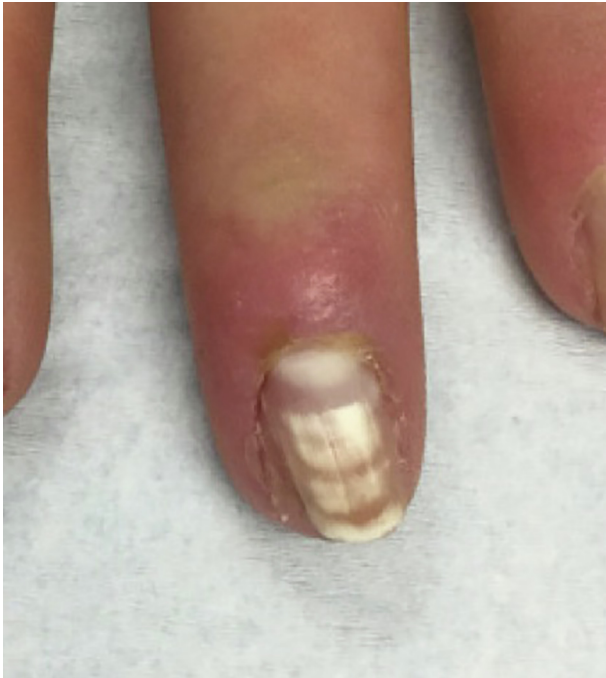None.

**Study Approval**

The author(s) confirm that any aspect of the work covered in this manuscript that has involved human patients has been conducted with the ethical approval of all relevant bodies.

\* Corresponding author.

E-mail address: sh19032@med.cornell.edu (S.R. Lipner).



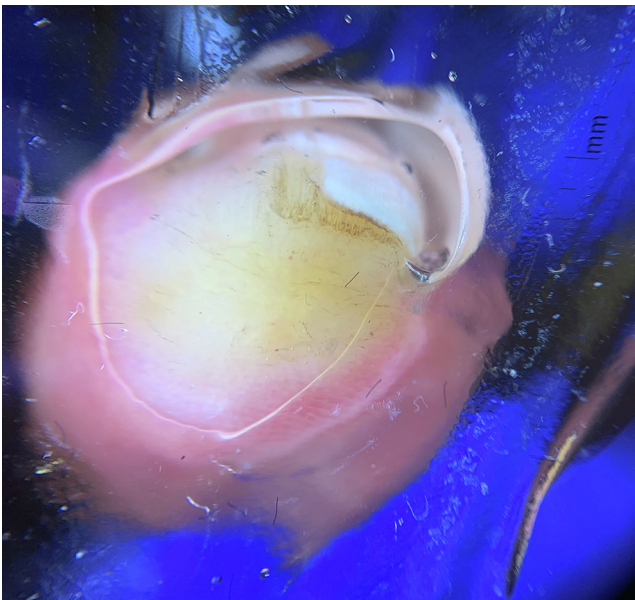
**Fig. 1.** Clinical photograph of the right third fingernail with parallel bands of leukonychia and erythema involving the nail folds.

### Financial Disclosures

None.

### References

- Baek JH, Kim HS, Park YM, Kim HO, Cho BK, Lee JY. A case of acquired idiopathic pterygium inversum unguis. *Ann Dermatol* 2014;26(3):374–6.
- Caputo R, Prandi G. Pterygium inversum unguis. *Arch Dermatol* 1973;108(6):817–8.
- Cervantes J, Sanches M, Eber AE, Perper M, Tosti A. Pterygium inversum unguis secondary to gel polish. *J Eur Acad Dermatol Venereol* 2018;32:160–3.
- Marie I, Gremain V, Nasseradjji K, Richard L, Joly P, Menard JF, et al. Nail involvement in systemic sclerosis. *J Am Acad Dermatol* 2017;76(6):1115–23.
- Richert BJ, Patki A, Baran RL. Pterygium of the nail. *Cutis* 2000;66(5):343–6.



**Fig. 2.** Contact dermoscopy of the hyponychium and free edge of the nail revealing absence of the distal nail groove and adherence of the distal part of the nail bed to the ventral surface of the nail plate.