

This article is licensed under the Creative Commons Attribution-NonCommercial 4.0 International License (CC BY-NC) (<http://www.karger.com/Services/OpenAccessLicense>). Usage and distribution for commercial purposes requires written permission.

Single Case

Drug-Induced Liver Injury Associated with Complementary and Alternative Medicines

Koji Takahashi^a Tatsuo Kanda^a Shin Yasui^a Yuki Haga^a
Junichiro Kumagai^a Reina Sasaki^a Shuang Wu^a Shingo Nakamoto^{a, b}
Masato Nakamura^a Makoto Arai^a Osamu Yokosuka^a

^aDepartment of Gastroenterology and Nephrology, Chiba University, Graduate School of Medicine, Chiba, Japan; ^bDepartment of Molecular Virology, Chiba University, Graduate School of Medicine, Chiba, Japan

Keywords

Alternative medicine · Complementary medicine · Drug-induced liver injury

Abstract

A 24-year-old man was admitted due to acute hepatitis with unknown etiology. After his condition and laboratory data gradually improved with conservative therapy, he was discharged 1 month later. Two months after his discharge, however, liver dysfunction reappeared. After his mother accidentally revealed that he took complementary and alternative medicine, discontinuation of the therapy caused his condition to improve. Finally, he was diagnosed with a recurrent drug-induced liver injury associated with Japanese complementary and alternative medicine. It is important to take the medical history in detail and consider complementary and alternative medicine as a cause of liver disease.

© 2016 The Author(s)
Published by S. Karger AG, Basel

Introduction

Acute liver failure (ALF) is often a life-threatening disease [1] and, in some cases of ALF, the etiology is not clear. Because it is difficult to specifically treat those patients with an unknown etiology, their prognosis seems poor compared with patients with a known etiology such as hepatitis A virus, hepatitis B virus, or an autoimmune mechanism. It is possible that drug-induced liver injury (DILI) could occur with the use of any drug. DILI could cause ALF, occasionally leading to death [2–4]. Moreover, it is difficult to identify the drug causing the liver injury, and so there is a lack of reliable markers to facilitate and establish the diagnosis of DILI [5, 6].

Due to an increase in health consciousness and internet use, complementary and alternative medicine is readily available. Complementary and alternative medicine also occasionally causes liver injury [7–10]. Recent reports of DILI by complementary and alternative medicine are increasing in the United States [7] and Japan [10]. We describe a 24-year-old male patient who had DILI associated with complementary and alternative medicine.

Case Report

A 24-year-old Japanese man visited our hospital after several days of fatigue and signs of jaundice. He had no previous history of liver diseases, rheumatic diseases, surgeries, transfusions, abuse of illegal drugs, or drug allergies. He was a social drinker of alcohol. He had no family history of liver diseases or rheumatic diseases. He was a graduate student and did not work. At the end of August 2015, he was first admitted to our hospital for a careful examination of his liver disease (Fig. 1). On admission, his body length, body weight, and body mass index were 1.75 m, 60.0 kg, and 20.0, respectively. On physical examination, no ascites or leg edema was observed. His liver and spleen were not swollen. His consciousness was alert. Laboratory findings on his first admission are shown in Table 1. Neither viral hepatitis markers nor autoantibodies were positive. An abdominal ultrasound on the first admission demonstrated no chronic liver disease or ascites. A first liver biopsy specimen showed that the hepatic architecture was preserved and the histology was compatible to that of acute hepatitis. There were no signs of chronic liver disease (Fig. 2). We diagnosed him with acute hepatitis of unknown etiology at this admission. Because conservative treatment made his transaminases lower, he was discharged from our hospital 1 month after the first admission (aspartate aminotransferase [AST] 23 IU/L, alanine transaminase [ALT] 33 IU/L, and γ -glutamyltransferase [γ -GTP] 111 IU/L) (Fig. 1). Two months after the first admission, his laboratory data were almost normal (AST 20 IU/L, ALT 14 IU/L, and γ -GTP 49 IU/L). At an outcome clinic 3 months after his first admission, his liver function tests were abnormal (AST 70 IU/L, ALT 65 IU/L, and γ -GTP 30 IU/L). At an outcome clinic 4 months after his first admission, his liver function tests were worse (AST 133 IU/L, ALT 294 IU/L, and γ -GTP 46 IU/L). At this time, we suspected a chronic active hepatitis such as autoimmune hepatitis and introduced prednisolone 15 mg daily and ursodeoxycholic acid 600 mg daily; however, his liver tests were not improved at 1 week (AST 438 IU/L, ALT 1104 IU/L, and γ -GTP 119 IU/L).

In January 2016, he was admitted to our hospital for a second time for further examination of his liver disease (Fig. 1). On admission, his body length, body weight, and body mass index were 1.75 m, 59.0 kg, and 19.3, respectively. Laboratory findings on his second admission are shown in Table 2. During the medical interview, his mother accidentally told us that he took complementary and alternative medicine (LEVERCOL[®], Nippo-Yakuhin, Tokyo, Japan, and Jacko[®], Nippo-Yakuhin) temporarily for a single use before the first admission. However, before finding out his liver dysfunction at an outcome clinic and before his second admission, interestingly, this patient did not admit to use of the drugs. A liver biopsy was re-performed, and the results were compatible with acute hepatitis due to a drug (Fig. 3). Discontinuation of LEVERCOL[®] and Jacko[®] led to improvement in his condition and liver dysfunction. We diagnosed him as DILI with complementary and alternative medicine (LEVERCOL[®] and Jacko[®]). His condition gradually improved with the use of temporary corticosteroids and he was discharged 2 months after the second admission (AST 15 IU/L, ALT 32 IU/L, and γ -GTP 131 IU/L). Six months after the second admission, his liver function tests had completely returned to normal ranges without any medication (AST 20 IU/L, ALT 21 IU/L, and γ -GTP 15 IU/L).

Discussion

The presented case took complementary and alternative medicine (LEVERCOL[®] and Jacko[®]) before every appearance of his liver dysfunction. Discontinuation of LEVERCOL[®] and Jacko[®] could have led to improvement of his condition and liver dysfunction. This patient did not admit the use of these medicines as drugs, but his mother told us about them, resulting in the accurate diagnosis.

LEVERCOL[®] is an herbal preparation containing fish liver extract that is available only in Japan and used for analeptics, weak constitution, and nutritional supplementation [11, 12]. It is reported that an 84-year-old male patient who developed subacute fulminant hepatitis was taking LEVERCOL[®] with other drugs [11]. Jacko[®] is used for physical exhaustion, weak constitution, and nutritional supplementation [13]. These complementary and alternative medicines are able to be obtained through the internet. We do not know which drugs were responsible for his liver dysfunction.

In Asian communities, the majority (74%) of patients with hepatotoxicity associated with the use of complementary and alternative medicine were above 40 years of age and 49% were male [14], although the present case was a 24-year-old man. Teo et al. [14] also reported that traditional Chinese medicine, health supplements, and other traditional medicines, including Malay Jam and Indian Ayurveda products, caused liver injury in 62, 28, and 11%, respectively. LEVERCOL[®] and Jacko[®] are health supplements [11, 13]. They also report that 60% and 5% of patients developed an acute hepatitis type or cholestatic hepatitis type, respectively [14], corresponding with the present report that LEVERCOL[®] and Jacko[®] induced acute hepatitis. In the United States, out of 647 adults with liver disease, 41% reported using complementary and alternative medicine, compared with 33% in adults without liver disease [15]. The majority of users believe that complementary and alternative medicine could improve their health [15].

Of interest, in the present case, the use of complementary and alternative medicine caused liver dysfunction, such as chronic active hepatitis, although we excluded autoimmune hepatitis by liver biopsy. Clinicians should consider DILI in patients with repeated liver dysfunction. Our report suggests that it is important to perform a medical interview with the patients, as well as their family, even if the patient is an adult.

Many factors cause liver dysfunction, including fatty changes, drugs, viruses, and autoimmune mechanisms. Often, the cause is unclear early in the course. If the cause is unclear, ultrasound-guided liver biopsy should be performed. In spite of its limitations, the liver biopsy still remains invaluable and can provide important information for diagnosis and management. In the present patient, both liver biopsy specimens were compatible with acute hepatitis due to drugs.

In Japan, the Digestive Disease Week Japan (DDW-J) 2004 score is widely used for confirmation of the causality of DILI [16]. It classifies the possibility by the point total. Less than 2 points is a low possibility, 3–4 points is possible, and more than 5 points is potentially high. This score is highly sensitive and specific [16]. LEVERCOL® and Jacko® both had 10 points, but it is difficult to identify which one of them was the cause. Additionally, they consist of many ingredients and additives [11, 13].

It has been reported that complementary and alternative medicine-induced DILI is at least as severe in presentation as that observed in prescription medicine-induced DILI, with higher rates of transplantation and lower transplant-free survival in those who progress to ALF [17]. In general, it is possible that patients may not report taking complementary or alternative medicine as a drug. It may be difficult to determine the cause of liver dysfunction in these patients. In conclusion, attention should be paid to complementary and alternative medicines in patients possessing liver dysfunction with an unknown etiology. A medical interview should be performed with the patients, as well as with their family, to lead to the accurate diagnosis.

Acknowledgements

The authors thank all Chiba University Hospital's staff for the patient's care.

Statement of Ethics

There are no ethical conflicts to declare.

Disclosure Statement

Tatsuo Kanda received a research grant from Chugai Pharmaceutical and MSD; Osamu Yokosuka received a research grant from Chugai Pharmaceutical, Bayer, MSD, Daiichi-Sankyo, Tanabe-Mitsubishi, Bristol-Myers Squibb, Taiho Pharmaceutical, and Gilead Sciences; Koji Takahashi, Shin Yasui, Yuki Haga, Junichiro Kumagai, Reina Sasaki, Shuang Wu, Shingo Nakamoto, Masato Nakamura, and Makoto Arai declare that they have no conflict of interest.

References

- 1 Mochida S, Takikawa Y, Nakayama N, Oketani M, Naiki T, Yamagishi Y, Fujiwara K, Ichida T, Tsubouchi H: Classification of the etiologies of acute liver failure in Japan: a report by the Intractable Hepato-Biliary Diseases Study Group of Japan. *Hepatol Res* 2014;44:365–367.
- 2 Ostapowicz G, Fontana RJ, Schiødt FV, Larson A, Davern TJ, Han SH, McCashland TM, Shakil AO, Hay JE, Hynan L, Crippin JS, Blei AT, Samuel G, Reisch J, Lee WM; U.S. Acute Liver Failure Study Group: Results of a prospective study of acute liver failure at 17 tertiary care centers in the United States. *Ann Intern Med* 2002;137:947–954.
- 3 Fontana RJ, Seeff LB, Andrade RJ, Björnsson E, Day CP, Serrano J, Hoofnagle JH: Standardization of nomenclature and causality assessment in drug-induced liver injury: summary of a clinical research workshop. *Hepatology* 2010;52:730–742.
- 4 Kanda T, Yokosuka O, Fujiwara K, Saisho H, Shiga H, Oda S, Okuda K, Sugawara Y, Makuuchi M, Hirasawa H: Fulminant hepatic failure associated with triazolam. *Dig Dis Sci* 2002;47:1111–1114.
- 5 Chalasani N, Björnsson E: Risk factors for idiosyncratic drug-induced liver injury. *Gastroenterology* 2010;138:2246–2259.
- 6 Lucena MI, García-Cortés M, Cueto R, Lopez-Duran J, Andrade RJ: Assessment of drug-induced liver injury in clinical practice. *Fundam Clin Pharmacol* 2008;22:141–158.
- 7 Navarro VJ, Barnhart H, Bonkovsky HL, Davern T, Fontana RJ, Grant L, Reddy KR, Seeff LB, Serrano J, Sherker AH, Stolz A, Talwalkar J, Vega M, Vuppalanchi R: Liver injury from herbals and dietary supplements in the U.S. Drug-Induced Liver Injury Network. *Hepatology* 2014;60:1399–1408.
- 8 Kanda T, Yokosuka O, Okada O, Suzuki Y, Saisho H: Severe hepatotoxicity associated with Chinese diet product 'Onshidou-Genbi-Kounou'. *J Gastroenterol Hepatol* 2003;18:354–355.
- 9 Adachi M, Saito H, Kobayashi H, Horie Y, Kato S, Yoshioka M, Ishii H: Hepatic injury in 12 patients taking the herbal weight loss AIDS Chaso or Onshido. *Ann Intern Med* 2003;139:488–492.
- 10 Hisamochi A, Kage M, Ide T, Arinaga-Hino T, Amano K, Kuwahara R, Ogata K, Miyajima I, Kumashiro R, Sata M, Torimura T: An analysis of drug-induced liver injury, which showed histological findings similar to autoimmune hepatitis. *J Gastroenterol* 2016;51:597–607.
- 11 Nippo-yakuhin: http://www.nippo-yakuhin.jp/hinmoku_detail/01210.html. Accessed on 2016/8/8 (in Japanese).
- 12 FDA U.S. Food and Drug Administration: http://www.accessdata.fda.gov/drugsatfda_docs/nda/2008/022206s000_MedR_P2.pdf. Accessed on 2016/8/8.
- 13 Nippo-yakuhin: <http://www.nippo-yakuhin.jp/jacko/element>. Accessed on 2016/8/8 (in Japanese).
- 14 Teo DC, Ng PS, Tan SH, Lim AT, Toh DS, Chan SY, Cheong HH: Drug-induced liver injury associated with Complementary and Alternative Medicine: a review of adverse event reports in an Asian community from 2009 to 2014. *BMC Complement Altern Med* 2016;16:192.
- 15 Henson JB, Brown CL, Chow SC, Muir AJ: Complementary and alternative medicine use in United States adults with liver disease. *J Clin Gastroenterol* 2016, Epub ahead of print.
- 16 Takikawa H, Onji M, Takamori Y, Murata Y, Taniguchi H, Ito T, Watanabe M, Ayada M, Maeda N, Nomoto M, Murata H, Ohmori S, Hisamochi A, Sumida T: Proposal of diagnostic criteria for drug-induced hepatic injury revised by the DDW-J2004 Workshop (in Japanese). *Kanzo* 2005;46:85–90.
- 17 Hillman L, Gottfried M, Whitsett M, Rakela J, Schilsky M, Lee WM, Ganger D: Clinical features and outcomes of complementary and alternative medicine induced acute liver failure and injury. *Am J Gastroenterol* 2016;111:958–965.

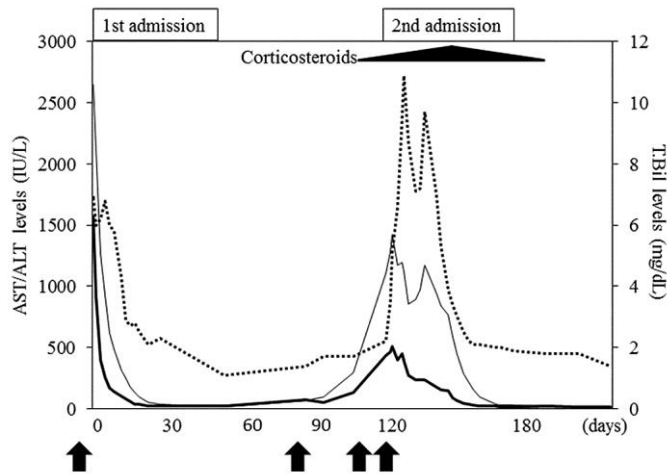


Fig. 1. Time course of liver function in relation to taking complementary and alternative medicines (LEVERCOL® and Jacko®) (black arrows). Aspartate aminotransferase (AST), alanine transaminase (ALT) and total bilirubin (T.Bil) levels are shown by the bold line, black line, and dotted line, respectively. Liver dysfunction occurred after taking these medicines.

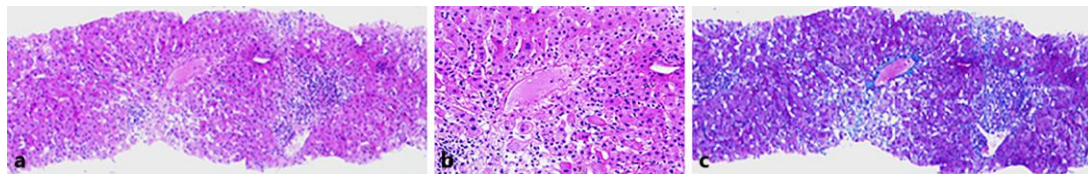


Fig. 2. The ultrasound-guided liver biopsy on the first admission revealed hepatic inflammation around the central vein with a ceroid granule (a, hematoxylin and eosin staining, ×40; b, hematoxylin and eosin staining, ×100). The hepatic architecture was preserved and findings of cirrhosis were not observed (c, Azan staining, ×40).

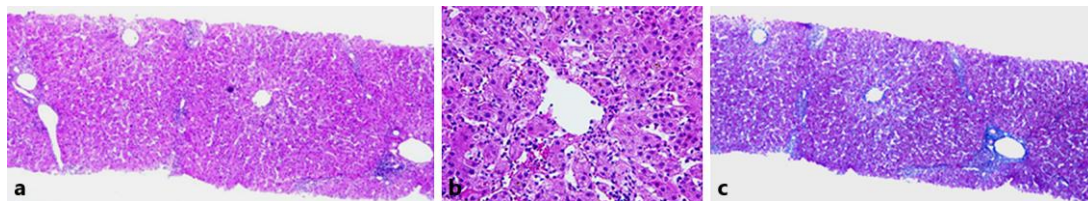


Fig. 3. The ultrasound-guided liver biopsy on the second admission showed similar findings to the first one. The hepatic architecture was preserved and findings of cirrhosis were not observed. The biopsy specimens were compatible with acute hepatitis caused by drugs (a, hematoxylin and eosin staining, ×40; b, hematoxylin and eosin staining, ×100; c, Azan staining, ×40).

Table 1. The laboratory data of the patient on the first admission

Item	Value	Item	Value	Item	Value
WBC	4,500/ μ L	TP	7.6 g/dL	IgM anti-HAV	negative
RBC	533×10^4 / μ L	Alb	4.9 g/dL	HBsAg	negative
Hemoglobin	15.8 g/dL	UN	11 mg/dL	anti-HBs	negative
Hematocrit	46.7%	Cre	0.76 mg/dL	anti-HBc	negative
Platelets	20.0×10^4 / μ L	ESR	2 mm/1 h	IgM anti-HBc	negative
PT	73%	CRP	0.1 mg/dL	HBV DNA	negative
PT-INR	1.18	AFP	2.9 ng/mL	anti-HCV	negative
AST	1,570 IU/L	IgG	1,452 mg/dL	HCV RNA	negative
ALT	2,650 IU/L	IgM	92 mg/dL	IgA anti-HEV	negative
LDH	524 IU/L	IgA	235 mg/dL	IgG anti-EBV EBNA	positive
ALP	640 IU/L	anti-nuclear antibody	negative	IgM anti-EBV VCA	negative
γ -GTP	195 IU/L	anti-mitochondria M2	negative	IgG anti-EBV VCA	negative
T.BIL	6.9 mg/dL	anti-smooth muscle	negative	IgM anti-CMV	negative
D.BIL	4.5 mg/dL	PR3-ANCA	negative	IgM anti-VZV	negative
T.CHO	105 mg/dL	IgM anti-HSV	negative	anti-HIV	negative

AST, aspartate aminotransferase; ALT, alanine transaminase; LDH, lactate dehydrogenase; ALP, alkaline phosphatase; γ -GTP, γ -glutamyltransferase; T.BIL, total bilirubin; D.BIL, direct bilirubin; TP, total protein; Alb, albumin; T.CHO, total cholesterol; UN, urea nitrogen; Cre, creatinine; WBC, white blood cell count; RBC, red blood cell count; PT, prothrombin time; PT-INR, PT international normalized ratio; AFP, α -fetoprotein; ESR, erythrocyte sedimentation rate; CRP, C-reactive protein; anti-HAV, anti-hepatitis A virus antibody; HBsAg, hepatitis B virus surface antigen; anti-HBs, anti-hepatitis B virus surface antibody; anti-HBc, anti-hepatitis B virus core antibody; anti-HCV, anti-hepatitis C virus antibody; anti-HEV, anti-hepatitis E virus antibody; anti-EBV EBNA, anti-Epstein-Barr nuclear antigen antibody; anti-EBV VCA, anti-Epstein-Barr viral capsid antigen antibody; anti-CMV, anti-cytomegalovirus antibody; anti-VZV, anti-varicella-zoster virus antibody; anti-HIV, anti-human immunodeficiency virus antibody; PR3-ANCA, proteinase-3-anti-neutrophil cytoplasmic antibody; anti-HSV, anti-herpes simplex antibody.

Table 2. The laboratory data of the patient on the second admission

Item	Value	Item	Value	Item	Value
WBC	5,200/ μ L	TP	7.7 g/dL	IgM anti-HAV	negative
RBC	467 \times 10 ⁴ / μ L	Alb	5.0 g/dL	HBsAg	negative
Hemoglobin	15.5 g/dL	UN	13 mg/dL	anti-HBs	negative
Hematocrit	44.7%	Cre	0.75 mg/dL	anti-HBc	negative
Platelets	11.6 \times 10 ⁴ / μ L	ESR	2 mm/1 h	IgM anti-HBc	negative
PT	73%	CRP	0.1 mg/dL	HBV DNA	negative
PT-INR	1.17	AFP	2.5 ng/mL	anti-HCV	negative
AST	438 IU/L	IgG	1,219 mg/dL	HCV RNA	negative
ALT	1,104 IU/L	IgM	63 mg/dL	IgA anti-HEV	negative
LDH	238 IU/L	IgA	193 mg/dL	IgG anti-EBV EBNA	positive
ALP	488 IU/L	anti-nuclear antibody	negative	IgM anti-EBV VCA	negative
γ -GTP	119 IU/L	anti-mitochondria M2	negative	IgG anti-EBV VCA	negative
T.BIL	2.2 mg/dL	anti-smooth muscle	negative	IgM anti-CMV	negative
D.BIL	0.5 mg/dL	TSH	1.749 μ IU/mL	IgM anti-VZV	negative
T.CHO	152 mg/dL	anti-HIV	negative	IgM anti-HSV	negative

AST, aspartate aminotransferase; ALT, alanine transaminase; LDH, lactate dehydrogenase; ALP, alkaline phosphatase; γ -GTP, γ -glutamyltransferase; T.BIL, total bilirubin; D.BIL, direct bilirubin; TP, total protein; Alb, albumin; T.CHO, total cholesterol; UN, urea nitrogen; Cre, creatinine; WBC, white blood cell count; RBC, red blood cell count; PT, prothrombin time; PT-INR, PT international normalized ratio; AFP, α -fetoprotein; ESR, erythrocyte sedimentation rate; CRP, C-reactive protein; anti-HAV, anti-hepatitis A virus antibody; HBsAg, hepatitis B virus surface antigen; anti-HBs, anti-hepatitis B virus surface antibody; anti-HBc, anti-hepatitis B virus core antibody; anti-HCV, anti-hepatitis C virus antibody; anti-HEV, anti-hepatitis E virus antibody; anti-EBV EBNA, anti-Epstein-Barr nuclear antigen antibody; anti-EBV VCA, anti-Epstein-Barr viral capsid antigen antibody; anti-CMV, anti-cytomegalovirus antibody; anti-VZV, anti-varicella-zoster virus antibody; anti-HIV, anti-human immunodeficiency virus antibody; TSH, thyroid stimulating hormone; anti-HSV, anti-herpes simplex antibody.