

Beware! A simple renal cyst could be a hydatid cyst

Nidhi Sehgal, Vinod Priyadarshi¹

Departments of Radiology and ¹Urology, The Mission Hospital, Durgapur, West Bengal, India

Abstract

Kidney is one of the most common sites for the cyst formation in the body, and the management of simple cysts is required entirely for its symptoms and complications. Surgical decortication is an established treatment for a large and symptomatic simple renal cyst. On the other hand, hydatid cysts of the kidney are usually multiloculated complex or calcified cysts and are quite rare. Their surgical treatment also differs and requires complete excision with pericystectomy or partial/complete nephrectomy depending upon residual functional parenchyma, using extreme caution to avoid spillage, recurrence or development of severe anaphylactic shock. A simple cyst harboring a hydatid cyst is highly uncommon and quite dangerous; as if not diagnosed preoperatively, it can create huge trouble for both the patient and the operating surgeon which happened in the present case.

Keywords: Hydatid cyst, imaging, renal, simple renal cyst

Address for correspondence:

Dr. Nidhi Sehgal, Department of Radiology, The Mission Hospital, Durgapur - 713 212, West Bengal, India. E-mail: nidhinikki2005@yahoo.com

Received: 24.10.2016, Accepted: 21.12.2016

INTRODUCTION

Kidney is one of the most common sites for the cyst formation in the body, and the management of simple cysts is required entirely for its symptoms and complications. Surgical decortication is an established treatment for a large and symptomatic simple renal cyst.^[1] On the other hand, hydatid cysts of the kidney are usually multiloculated complex or calcified cysts and are quite rare.^[2] Their surgical treatment also differs and requires complete excision with pericystectomy or partial/complete nephrectomy depending upon residual functional parenchyma, using extreme caution to avoid spillage, recurrence or development of severe anaphylactic shock.^[3] A simple cyst harboring a hydatid cyst is highly uncommon and quite dangerous; as if not diagnosed preoperatively, it can create huge trouble for both the patient and the operating surgeon which happened in the present case.

CASE REPORT

A 50-year-old homemaker presented with constant dull aching pain in the left flank for 9 months with occasional nausea. She had no history of associated fever, hematuria, or lower urinary tract symptoms and had attended menopause 5 years back. General examination was essentially normal. On abdominal examination, there was no palpable organomegaly, but left renal angle was found tender. Hematology and urine and biochemical investigations were normal. Ultrasonography (USG) suggested a large simple cortical cyst at upper pole of the left kidney [Figure I]. Contrast-enhanced computed tomography (CT) of the kidney, ureter, and bladder equally suggested a single large thin-walled simple cyst measuring 79.3 mm × 63.6 mm × 62.8 mm at upper pole of the left kidney. Cyst fluid did not show any contrast enhancement [Figure 2a and b]. Transperitoneal laparoscopic

Access this article online

Quick Response Code:



Website:

www.urologyannals.com

DOI:

10.4103/0974-7796.210028

This is an open access article distributed under the terms of the Creative Commons Attribution-NonCommercial-ShareAlike 3.0 License, which allows others to remix, tweak, and build upon the work non-commercially, as long as the author is credited and the new creations are licensed under the identical terms.

For reprints contact: reprints@medknow.com

How to cite this article: Sehgal N, Priyadarshi V. Beware! A simple renal cyst could be a hydatid cyst. Urol Ann 2017;9:281-4.

decortication and marsupialization of the cyst were planned. Retrograde left ureteric catheterization and pyelography were done to rule out any communication of cyst with pelvicalyceal system. In the right lateral position and 60° tilt, with standard transperitoneal laparoscopic renal approach, left renal cyst was exposed which was extending from upper pole to hilum. As the cyst was just punctured, with utter surprise, hydatid fluid came out along with peppering daughter cysts. Keeping the cyst opening closed with Maryland forceps, the leaked hydatid fluid sucked instantly. Entire operation theater (OT) was alerted about the diagnosis and 100 mg hydrocortisone was given intravenously (IV). With keeping an eye on vitals, through the same opening, sucker was introduced inside the cyst, but it got stuck with daughter cysts. In such unprecedented and unpredicted condition, decision of opening the abdomen in the same position through left subcostal flank incision was taken with keeping sucker in cyst itself and clamping the opening with Maryland forceps. On opening the abdomen, the area around the cyst was carefully isolated by gauze packs soaked with 10% povidone-iodine. Initially, cyst aspirated along with all daughter cysts and hydatid sand that was followed by pericystectomy [Figure 3]. Incidental opening of the pelvicalyceal system was ruled out by instillation of methylene blue through preoperatively placed ureteric catheter. Retroperitoneum and peritoneal cavity were lavaged with 3% hypertonic saline and 1% povidone-iodine solution available in OT. Abdomen was closed after keeping a peritoneal drain. The patient had hypotension in early postoperative period which was managed with IV fluids. The patient remained febrile with leukocytosis for first 48 h but responded to empirical antimicrobial treatment. IV hydrocortisone repeated at 12 and 24 h. Oral albendazole 400 mg/day was started from the 2nd postoperative day. Drain removed on the 3rd postoperative day and patient discharged on the 7th postoperative day.

Albendazole treatment was continued for 3 months. 3- and 6-month follow-up USG and CT scan did not reveal any new or residual hydatidosis. The patient is planned for repeat CT scan at 1 year. Although there was no pet in her house, on repeated questioning, she confirmed that she visited her brother's house 1 year back where was a pet dog.

DISCUSSION

Hydatid disease is a zoonosis characterized by the cystic stage of infestation by the larvae of tapeworm *Echinococcus granulosus*.^[2] Human is the intermediate host and gets the disease by ingesting vegetables and water contaminated by the dog excretes containing *Echinococcus* eggs. The embryos hatch in the duodenum and migrate into the small bowel wall to enter the mesenteric circulation and

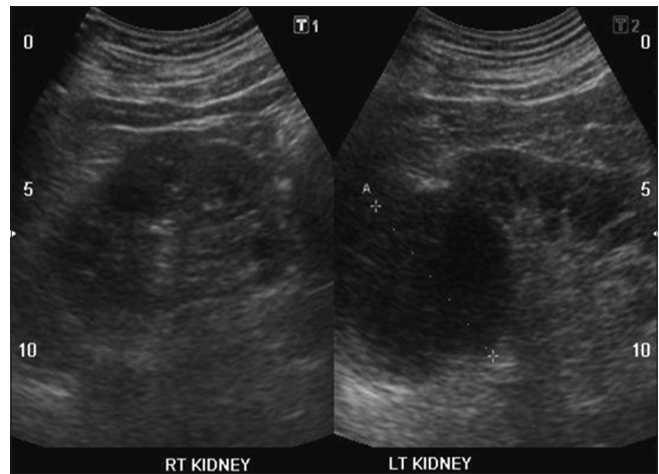


Figure 1: Ultrasonography of the kidney, ureter, and bladder showing a 6 cm × 7 cm simple cortical cyst at upper pole of left kidney

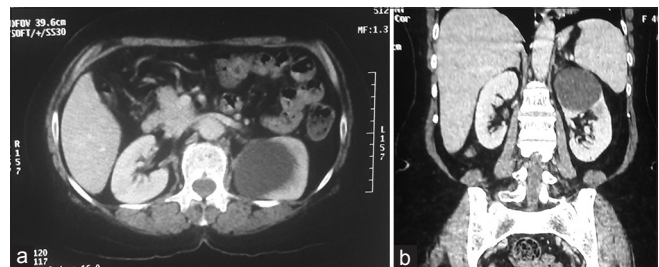


Figure 2: Contrast-enhanced computed tomography kidney, ureter, and bladder equally showing a single large simple cyst (79.3 mm × 63.6 mm × 62.8 mm) at upper pole of the left kidney. (a) Axial plane. (b) Coronal plane

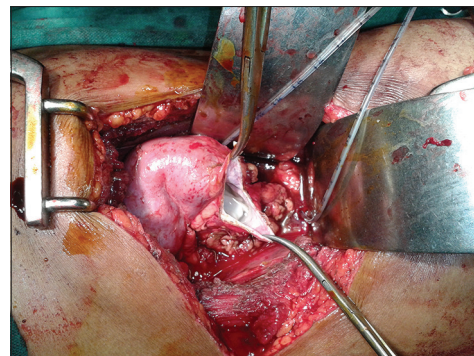


Figure 3: Pericystectomy in process after hydatid cyst aspiration

are filtered in the liver or the lungs or the kidney, where the embryo becomes a small vesicle with an inner germinal epithelium called the lamellated membrane that produces secondary or daughter brood cysts containing scolices. Hydatid cyst formation is an insidious process and many years may elapse before a significant size is reached.^[4] From the secretions of germinal layer of endocyst itself, an outer nonnucleated ectocyst layer of innumerable delicate laminations develops. In old cysts, due to the inflammatory reaction from the surrounding host tissue, a third layer

containing fibroblasts, giant cells, and mononuclear and eosinophilic infiltrates forms a thick fibrous capsule and is called a pericyst.^[2] Hence, in very early stage, hydatid cyst may contain clear transudate fluid that is later tainted with differentiating laminated membranes, sprouting daughter cysts, and shedding scolices.^[5]

Hydatid cysts can be seen in virtually every organ of the body; however, they predominantly (about 90%) found in the liver and lungs. Renal hydatid cysts are rare and comprise only 2%–3% of all cases of hydatid disease.^[6] These cysts in the kidney are considered closed if all three layers of the cyst are intact. When the cyst is no longer protected by the third layer, i.e., pericyst, or by the lining of collecting system, it is considered to be an exposed cyst. If all the three layers of the cyst have ruptured resulting in free communication with the calyces and pelvis, it is called an open or communicating cyst.^[7] Like simple renal cysts, renal hydatid cyst remains asymptomatic for many years^[7] unless large enough to stretch renal capsule. An exposed or enlarged cyst presents with chronic dull flank pain while a ruptured, disseminated, or communicating cyst can present with hydatiduria and acute colic or obstruction, but this is uncommon (in only 10%–20% of renal hydatidosis) and usually microscopic in nature.^[8] Serological tests in primary renal hydatidosis are usually negative and imaging techniques remain the mainstay of diagnosis. The sonographic finding that is observed in most of the cases is multiloculated cystic appearance, containing internal floating echoes, and curvilinear internal septa.^[2] Similarly, typical CT findings for renal hydatidosis include a cyst with a thick or calcified wall or a unilocular cyst with a detached membrane or a multiloculated cyst with mixed internal density due to daughter cysts with lower density than the maternal matrix.^[9] Moreover, therefore, sometimes, problems in differentiating such lesions from cystic renal tumors and other complicated renal cysts and abscess exist with both sonography and CT scan.^[2] However, the diagnostic dilemma does not end here. In the early stages, before the development of daughter cysts, a hydatid cyst can present as simple anechoic lesions, and even if the walls of parasitic cysts are slightly thicker than those of simple serous cysts, a prospective diagnosis of hydatid renal cyst may be difficult when a completely anechoic lesion is detected^[2] that happened in the present case. Magnetic resonance (MR) imaging features are also similar to those of simple cysts that include hypointensity on T1-weighted images and marked hyperintensity on T2-weighted images. A low-signal-intensity rim (“rim sign”), which is more evident on T2-weighted MR images and represents the parasitic membranes and pericyst, has been described as characteristic of hydatidosis as opposed to nonparasitic cysts. However, this can also be seen in abscess.^[5,9] Conversely, thin septa and calcifications

of the wall can be encountered also in simple serous renal cysts.^[2] Clue lies in such cases with a double-contour thick wall which is better delineated with contrast-enhanced CT compared with sonography or with the presence of “falling snowflakes” created by dispersal of the hydatid sand, by rolling the patient during sonographic evaluation.^[2,9] To achieve it, a high index of suspicion is required if the patient is living in endemic zone or multiple small simple cysts are seen at different locations in the same patient. The present case is unique as it was a solitary large simple renal cyst and a possibility of dealing with a hydatid cyst was never suspected.

Due to variety of radiological presentation, hydatid cysts were classified by Gharbi *et al.*^[10] in 1981 and later on by Polat *et al.* in 2002.^[5] Although there is no separate classification for renal hydatidosis, Turgut *et al.* discussed a thorough adaptation of Gharbi’s classification in context with renal hydatid cysts.^[9] Classical hydatid cyst are mostly type 2 and type 3 multiloculated cysts that have a racemose or spoke wheel pattern due to floating membranes and daughter cyst. The present case was type 1 hydatid cyst according to both classifications.

Renal cysts are further characterized based on Bosniak classification with respect to risk of malignancy or other effects on the kidney. Laparoscopic cyst decortication is an established treatment for large symptomatic simple cysts, which is highly efficacious with minimal morbidity.^[1] However, the scenario changes if such simple cyst came out to be a hydatid cyst. Two main challenges for laparoscopy in such condition are to avoid the spillage of contents and to minimize incision for delivering the specimen.^[3] Risk of spillage is most problematic which may lead to anaphylactic shock and increases the risk of recurrence. The other problem faced in laparoscopic treatment of hydatid cysts is the difficulty in evacuating the particulate contents of the cyst, daughter cysts, and laminated membranes as they may block the suction cannula which happened in the present case. A double-lumen beveled cannula^[11] or a Palanivelu hydatid trocar cannula system (HTCS)^[12] has been described to deal with such problem that not only prevents any spillage of hydatid fluid but also assists in complete evacuation of the cyst content and allows intracystic magnified visualization to check complete removal of scolices.^[3] In addition, a retroperitoneal approach is preferred over a transperitoneal approach to avoid spillage or contamination of virgin peritoneal cavity.^[1] In the present case, we were neither ready nor prepared for laparoscopic aspiration and excision of a hydatid cyst as we were completely bluffed by its radiological character that appeared as a simple renal cyst. Therefore, it was swiftly converted into open surgery and pericystectomy done after aspiration of the cyst. Again most commonly used scolicidal such as 20% hypertonic saline, chlorhexidine, 80% ethanol,

0.5% cetrimide, 3% H₂O₂, or 0.5% silver nitrate^[3,6] were not available in OT in anticipation of a hydatid cyst; still, we managed with the prudent use of povidone-iodine and 3% hypertonic saline.^[6]

CONCLUSION

A simple renal cyst could be a type I hydatid cyst in disguise. Establishing a preoperative diagnosis in these cases and choosing the right treatment option are a real challenge for a clinician. A very vigilant history for any such patient inhabiting in an endemic zone and a careful USG in search of hydatid sand are required while dealing with simple renal cysts and multiple cysts. A Palanivelu HTCS should be a must in laparoscopic armamentarium before operating for any simple renal cyst. A laparoscopic cyst decortications should be done in a manner as it may dealt with a hydatid cyst.

Financial support and sponsorship

Nil.

Conflicts of interest

There are no conflicts of interest.

REFERENCES

1. Agarwal MM, Hemal AK. Surgical management of renal cystic disease. *Curr Urol Rep* 2011;12:3-10.
2. Migaleddu V, Conti M, Canalis GC, Senarega R, Pretolesi F, Martinoli C, *et al.* Imaging of renal hydatid cysts. *Am J Radiol* 1997;169:1339-42.
3. Chipde SS, Yadav A, Ranjan P, Prakash A, Kapoor R. Total laparoscopic management of a large renal hydatid cyst by using hydatid trocar cannula system. *J Surg Tech Case Rep* 2012;4:32-5.
4. Shukla A, Garge S, Verma P. A case of large renal hydatid cyst. *Saudi J Kidney Dis Transpl* 2011;22:538-40.
5. Polat P, Kantarci M, Alper F, Suma S, Koruyucu MB, Okur A. Hydatid disease from head to toe. *Radiographics* 2003;23:475-94.
6. Aggarwal S, Bansal A. Laparoscopic management of renal hydatid cyst. *JLS* 2014;18:361-6.
7. Mongha R, Narayan S, Kundu AK. Primary hydatid cyst of kidney and ureter with gross hydatiduria: A case report and evaluation of radiological features. *Indian J Urol* 2008;24:116-7.
8. Priyadarshi V, Singh JP, Awasthi NK, Hazra SP, Vijay MK, Pal DK. Isolated renal *Echinococcosis* with hydatiduria in a girl. *APSP J Case Rep* 2013;4:31.
9. Turgut AT, Ödev K, Kabaalioğlu A, Bhatt S, Dogra VS. Multitechnique evaluation of renal hydatid disease. *Am J Radiol* 2009;192:462-7.
10. Gharbi HA, Hassine W, Brauner MW, Dupuch K. Ultrasound examination of the hydatid liver. *Radiology* 1981;139:459-63.
11. Bickel A, Eitan A. The use of a large, transparent cannula, with a beveled tip, for safe laparoscopic management of hydatid cysts of liver. *Surg Endosc* 1995;9:1304-5.
12. Palanivelu C, Jani K, Malladi V, Senthilkumar R, Rajan PS, Senthilkumar K, *et al.* Laparoscopic management of hepatic hydatid disease. *JLS* 2006;10:56-62.