

# Case Report

## Four-Year Follow-up of Increased Vertical Dimension of Occlusion using Resin Composites

Cendrella Assaf, Jean Claude Fahd, Joseph Sabbagh

Department of Restorative Dentistry, Lebanese University, Beirut, Lebanon

Received : 03-07-18.  
Accepted : 25-07-18.  
Published : 08-10-18.

### ABSTRACT

The objectives of this case report were to treat a severe loss of the vertical dimension of occlusion with indirect composite and to evaluate the durability of the restorations. A 55-year-old male complains from severe wear of teeth, leading to a change in normal occlusal plane. Two major treatment modalities were proposed to this patient; a conventional invasive crown placement with root canal treatments or a minimally invasive approach relying on adhesion. The latter was adopted and used to treat this patient. This paper describes a step-by-step approach of the different treatment phases starting with teeth preparation, then provisional prostheses, and ending with the placement of indirect anterior veneers and posterior onlays, all made with laboratory resin composite. Satisfactory clinical results were observed over the 4-year follow-up, with minimum failures limited to one partial fracture of inlay treated with direct adhesive repair.

**KEYWORDS:** *Bruxism, full arch rehabilitation, vertical dimension of occlusion*

### INTRODUCTION

Awake and sleep bruxism, associated with functional disorders, became a widespread disease nowadays.<sup>[1]</sup> Its intensity varies from mild to severe, and its impact on teeth may present different clinical signs varying from asymptomatic cracks, to severe erosion and teeth wear leading to a loss of the vertical dimension of occlusion (VDO).

VDO is an important factor in facial esthetics and symmetry. It is defined as the relationship of the mandible and maxilla when the jaw is closed, and the teeth are in contact.<sup>[2]</sup>

The idea of increasing VDO was described by Dhal,<sup>[3,4]</sup> since dental treatment improves the patient's oral hygiene, reduces thermal hypersensitivity, and prevents pulpal involvements and further abrasion.<sup>[5]</sup> In case of severe tooth wear, Dahl proposed to use only indirect restorations (veneers and crowns) to restore the lost dental tissues.<sup>[3,4]</sup>

Patients with excessive teeth abrasion require an exact estimation of the VDO to achieve an accurate replacement of lost dimension while reestablishing anatomy and function and to adapt the patient to the change of

occlusion. Tolerance to vertical dimension changes is confirmed by the absence of clinical symptoms, during the temporary phase corresponding to the placement of provisional prosthesis.<sup>[6]</sup>

Traditionally, a full mouth rehabilitation based on full-crown coverage was recommended due to their good mechanical properties and sustainability. Nowadays, adhesive techniques improved while indications for metal-ceramic crowns decreased, consequently a more conservative approach is preferred.<sup>[7]</sup>

This paper presents a case report of exclusive conservative rehabilitation in a patient with a generalized tooth wear.

### CASE REPORT

A 55-year-old patient presented with two chief complaints: deterioration of dental function and

**Address for correspondence:** Dr. Cendrella Assaf, Department of Restorative and Aesthetic Dentistry, School of Dentistry, Hadath Campus, Lebanese University, Beirut, Lebanon.  
E-mail: cendrellaassaf@yahoo.fr

This is an open access journal, and articles are distributed under the terms of the Creative Commons Attribution-NonCommercial-ShareAlike 4.0 License, which allows others to remix, tweak, and build upon the work non-commercially, as long as appropriate credit is given and the new creations are licensed under the identical terms.

**For reprints contact:** reprints@medknow.com

**How to cite this article:** Assaf C, Fahd JC, Sabbagh J. Four-year follow-up of increased vertical dimension of occlusion using resin composites. J Int Soc Prevent Communit Dent 2018;8:469-74.

Access this article online	
<b>Quick Response Code:</b> 	<b>Website:</b> www.jispcd.org
	<b>DOI:</b> 10.4103/jispcd.JISPCD_233_18

esthetics. Clinical examination revealed a loss of the vertical dimension and the presence of severe bruxism placing him in Category 1 according to Turner and Missirlian; Category 2 describes individuals with excessive tooth wear without loss of VDO but with enough space for restorative materials, whereas Category 3 describes individuals with excessive wear without loss of VDO but with limited space for restorative materials.<sup>[8]</sup>

Before establishing a treatment plan, various examinations and analysis were undertaken including extra- and intra-oral photographs, as well as periodontal and radiographic examinations.

Pictures taken using a reflex camera, to evaluate the profile of the patient, showed a deformation of the bite and a collapse of his upper and lower lips.

The patient had no signs of pain or tenderness in the head or neck area, neither clicking nor tenderness in the temporomandibular joint (TMJ).

Intraoral examination showed attrition and erosion of most of the teeth. There were four interproximal caries due to the loss of the contact points and five other teeth restored with amalgam and resin composite. All the teeth revealed hypercalcified dentin [Figures 1 and 2].

A radiographic examination was undertaken, neither periapical nor periodontal lesions were present. Pulp chambers and root canals were retracted as a result of chronic tooth wear [Figure 3].

After thorough explanations given to the patient about the different treatment modalities, he agreed to restore his teeth using a minimally invasive procedure, and a written consent was obtained from him.

Before starting the treatment, he was informed of the possibility of wear of the material, fracture, or

debonding of the composite which are liable to occur in such a treatment.

During the first clinical session, alginate impressions were taken, and the models were mounted on a semi-adjustable articulator reproducing patient's VDO.

A new VDO was decided on the articulator, taking into consideration both the posterior and anterior teeth, with the goal of retaining as much tooth structure as possible and to reestablish fair anterior contacts and adequate related anterior guidance.<sup>[7]</sup> A full mouth wax-up was made. In one session, all the anterior teeth were prepared for veneers and all the posteriors for onlays, in a conservative way, using cylindrical round tip burs with different diamond grids (to prepare and finish the surfaces). Afterward, temporaries were made using acrylic resin powder and liquid (Alike GC, Japan) and cemented using Temp-Bond NE (Kerr, Orange, USA).

During several sessions, the vertical dimension was gradually increased up to 3–4 mm by adding resin-based paste on the occlusal surfaces of the temporary crowns, to ensure painless and harmless transitional phase. There were no signs of discomfort were reported by the patient during his rehabilitation process.

The achieved increase of the vertical dimension by the end of the occlusal treatment was about 6 mm [Figure 4].

The case was stabilized and assessed for 2 months to control the patient's parafunctions and the well-being of his TMJ. By the end of this period, impressions were taken and sent to the laboratory.

The permanent restorations were made using indirect laboratory composite (Premise Indirect, Kerr, Orange, USA).

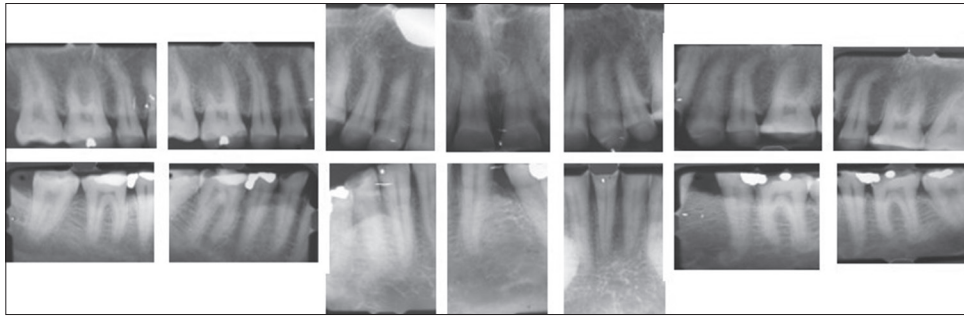
Luting of the restorations was made in two stages: teeth preparation and prostheses treatment.

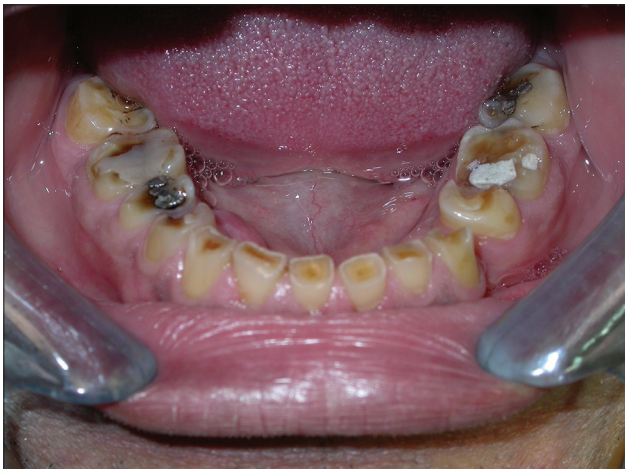

Figure 1: Lingual view of the tooth wear

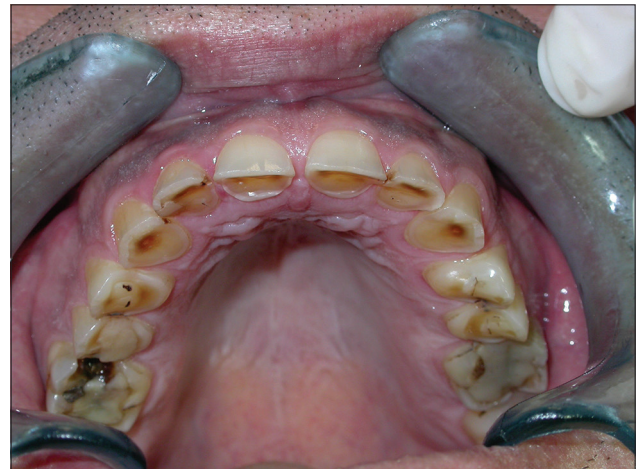

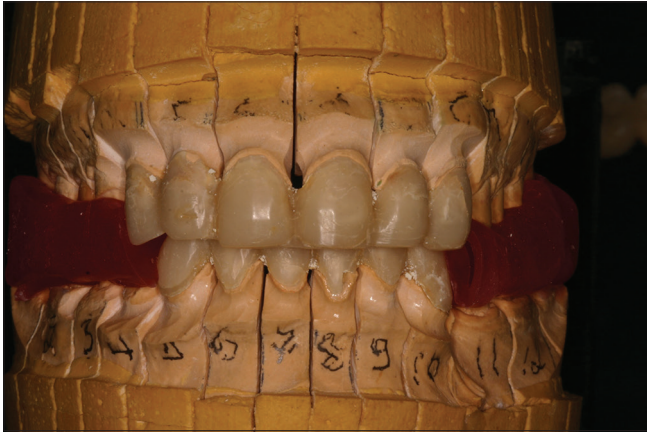Figure 2: Palatal view of the tooth wear



**Figure 3:** Full mouth preoperative X-rays



**Figure 4:** Model showing the increase of the vertical dimension

Teeth preparation consisted in cleaning temporary cement, etching using phosphoric acid (37%), and applying a fifth-generation adhesive system, single bond (3M-ESPE, St Paul, USA) on teeth surfaces.

The internal surfaces of the veneers and onlays were treated with hydrofluoric acid (6%) for 1 min and then rinsed and dried. Two layers of silane were applied to the internal surfaces to enhance the organo-mineral adhesion.

A dual-cure resin cement (Calibra, DENTSPLY, Konstanz, Germany) was used for luting the restorations. Finally, the occlusion was checked to get a group bilateral contact as mentioned.

Figures 5-9 show the final result compared to the initial situation.

One week later, a lower impression was taken to prepare a night guard (made of 2 mm thickness silicone) as prevention from any subsequent fractures due to bruxism [Figure 10].

Patient was followed up for 4 years.

One year later, no failure was detected except a gingival redness on his lower anterior quadrant due to plaque accumulation as well as a light composite wear. The patient did not report any specific complaint.

A photography was taken [Figure 11] to record his dental conditions and compare them to the initial situation.

Four years later, the patient is still satisfied from the results. The VDO remained constant [Figures 12 and 13].

Only one cohesive fracture in tooth number 25 (2<sup>nd</sup> upper left premolar) was recorded. It was repaired by adding some microhybrid universal composite [Figure 14].

## DISCUSSION

All reconstructive procedure must start with a determined treatment plan and a goal to achieve.

VDO affects greatly facial esthetics and symmetry; it is defined as the height of the lower part of the face between the infranasal point and the gnathion where the arches are in occlusion in maximal intercuspation position.<sup>[9]</sup>

Individuals with collapsed facial appearance, improper lip support, changes in phonetics, nasolabial fold prominence, and reduction in muscle tone often demonstrate an advanced loss in VDO combined to severe teeth abrasion.<sup>[10]</sup> Some studies revealed an increase in lower facial height by 0.63 mm for every 1.0 mm increase in VDO.<sup>[10]</sup> In addition to facial benefits, increasing VDO aims to recreate enough space between the arches allowing for sufficient materials' thickness and resistance.<sup>[11]</sup> VDO could be increased gradually without causing harm or pain as long as the change is combined with simultaneous equal intensity contacts in centric relation.<sup>[11]</sup> Temporary restorations help to improve and maintain a proper vertical dimension and the patient's mental well-being.<sup>[12]</sup>

In severe teeth wear, reestablishing anatomy and function can be achieved either with conventional full crowns or with adhesive techniques using resin composites.

Since the 1980s, indirect resin composites (IRCs) were introduced in dentistry.<sup>[13]</sup> Later, in 1990, second-generation indirect composite resins were developed with differences in structure, composition, polymerization technique, and filler reinforcement to optimize their mechanical and esthetical properties.<sup>[13]</sup>



Composite restorations have a number of distinct advantages over metal ceramic crowns that can be summarized as follows:

- Minimally invasive<sup>[14-17]</sup>
- Patient acceptance and adaptation is good on medium term<sup>[18,19]</sup>
- Reduced costs and treatment time<sup>[14,18,20]</sup>
- Better stress distribution<sup>[13,21]</sup>
- Amelioration in the esthetics with reduced sensitivity<sup>[22]</sup>
- Kinder to the opposing dentition compared to ceramics<sup>[23,24]</sup>

- Reparability in case of marginal breakage or chipping.<sup>[13,20,22,25,26]</sup>

Composite restorations often fail due to fracture of the material itself, while metal ceramic crowns from complete loss.<sup>[27-30]</sup>

Moreover, the color stability of indirect composite commonly criticized as unpredictable and proved to be acceptable in several *in vitro* trials.<sup>[13,31-34]</sup>

The adhesive technologies currently available allow bonding of veneer or onlay restorations to the remaining tooth structures even if the remaining structure

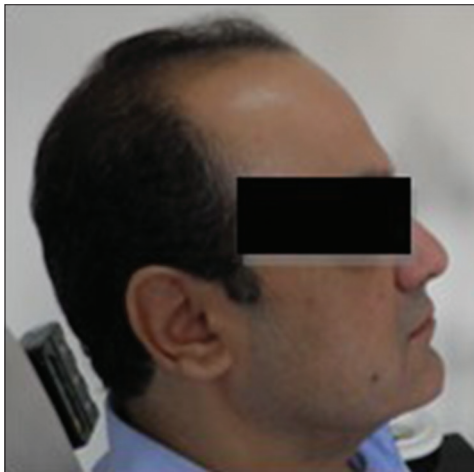

Figure 5: Patient's preoperative profile picture

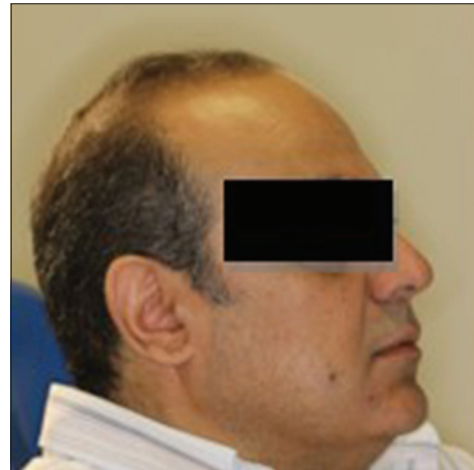

Figure 6: Patient's postoperative profile picture

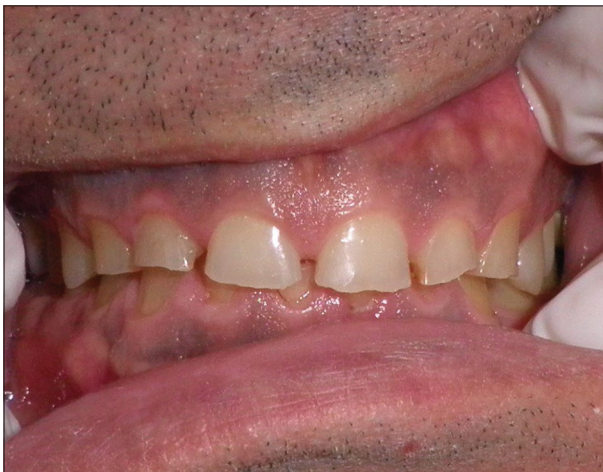

Figure 7: Preoperative status

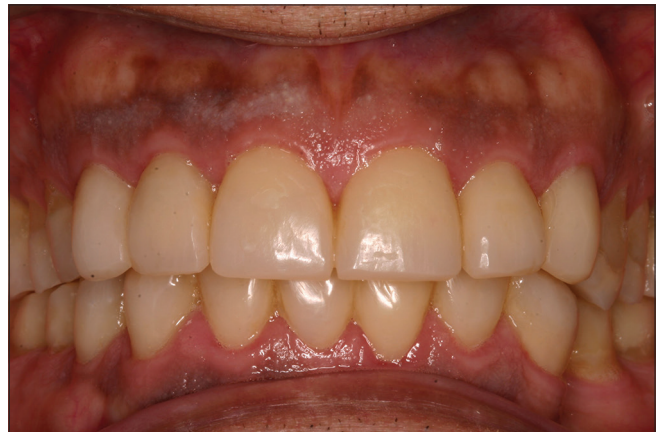

Figure 8: Postoperative result

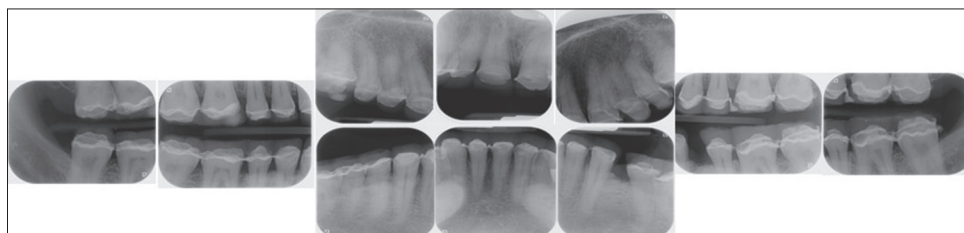


Figure 9: Full mouth postoperative X-rays

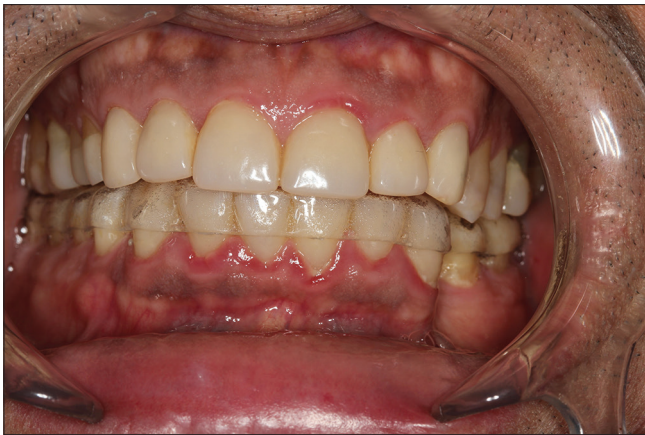

Figure 10: Night guard applied on the lower arch

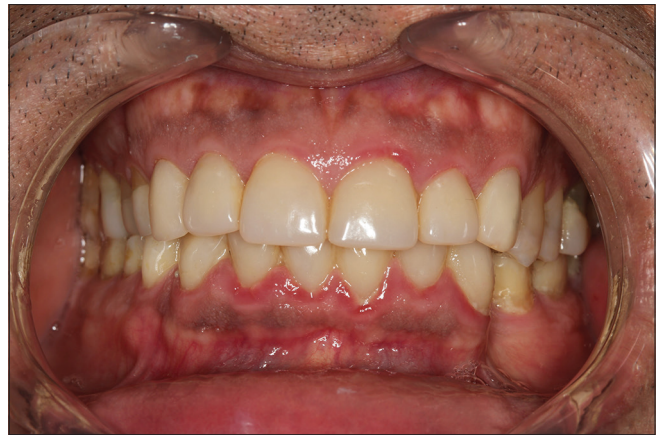

Figure 11: Picture of the restorations at 1 year

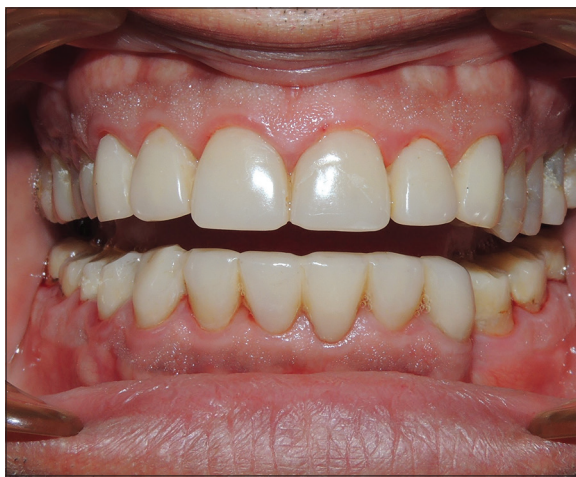

Figure 12: Restorations at 4 years (opened occlusion)

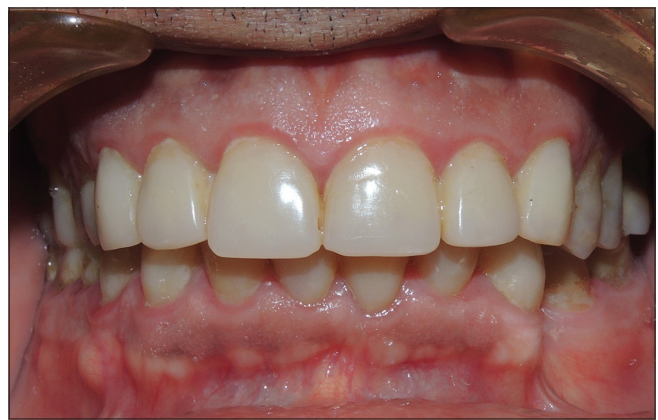

Figure 13: Restorations at 4 years (closed occlusion)

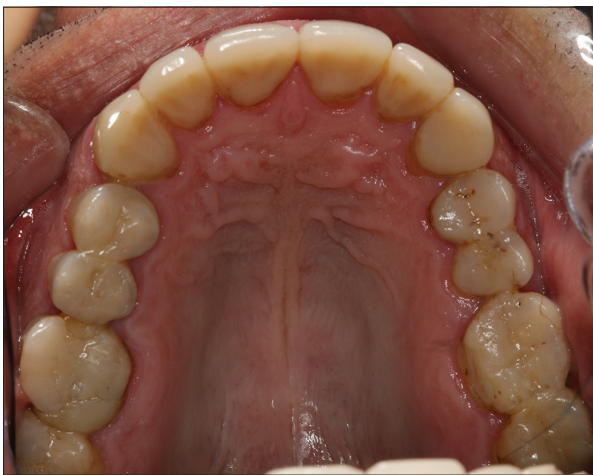

Figure 14: Direct composite repair at tooth 25

is <3 mm. Although adhesive restorations offer several advantages, significant care must be taken while bonding the restoration to dentin.<sup>[35,36]</sup>

Managing mutilated teeth presents a substantial challenge to dentists. By being aware of the different

etiologies, the factors relative to the occlusal vertical dimension, and the various modalities of treatments, the practitioner can set a proper diagnosis and decide of the ultimate treatment plan that respects the esthetics, the well-functioning, the patient's comfort, and the longevity of the rehabilitation.

Since bonding with composite material is a conservative concept to restore a worn dentition, the goal of this case study is to have the reader consider using adhesive approaches as an acceptable medium-term solution in treating severely worn teeth.

Nevertheless, more *in vitro* and especially clinical trials are needed to verify the longevity of IRCs.

#### DECLARATION OF PATIENT CONSENT

The authors certify that they have obtained necessary institutional approval and patient consent forms (Lebanese Uni/Dentistry/03/460556). In the form, the patient has given his consent for his images and other clinical information to be reported in the journal. The patient understands that name and initial will not be published, and due efforts will be made to conceal identity, but anonymity cannot be guaranteed.



**FINANCIAL SUPPORT AND SPONSORSHIP**

Nil.

**CONFLICTS OF INTEREST**

There are no conflicts of interest.

**REFERENCES**

- Dietschi D, Argente A. A comprehensive and conservative approach for the restoration of abrasion and erosion. Part I: Concepts and clinical rationale for early intervention using adhesive techniques. *Eur J Esthet Dent* 2011;6:20-33.
- The glossary of prosthodontic terms. *J Prosthet Dent* 2005;94:10-92.
- Dietschi D, Argente A. A global and conservative approach for the restoration of abrasions and erosions. Part II: clinical procedures and a case presentation. *Eur J Esthet Dent* 2011;6:144-61.
- Dahl BL, Krogstad O. The effect of a partial bite raising splint on the occlusal face height. An X-ray cephalometric study in human adults. *Acta Odontol Scand* 1982;40:17-24.
- Reis A, Higashi C, Loguercio AD. Re-anatomization of anterior eroded teeth by stratification with direct composite resin. *J Esthet Restor Dent* 2009;21:304-16.
- Song MY, Park JM, Park EJ. Full mouth rehabilitation of the patient with severely worn dentition: A case report. *J Adv Prosthodont* 2010;2:106-10.
- Vailati F, Belsler UC. Full-mouth adhesive rehabilitation of a severely eroded dentition: The three-step technique. Part 2. *Eur J Esthet Dent* 2008;3:128-46.
- Turner KA, Missirlian DM. Restoration of the extremely worn dentition. *J Prosthet Dent* 1984;52:467-74.
- Rebibo M, Darmouni L, Jouvin J, Orthlieb JD. Vertical dimension of occlusion: The keys to decision. We may play with the VDO if we know some game's rules. *J Stomatol Occup Med* 2009;2:147-59.
- Orenstein NP. Changes in Facial Esthetics and Lower Facial Height with Increases in Occlusal Vertical Dimension in Dentate Models. University of Connecticut Graduate School Master's Theses; 2013.
- Dawson PE. *Functional Occlusion – From TMJ to Smile Design*. 1<sup>st</sup> ed. New York: Elsevier Inc; 2008. p. 430-52.
- Chidambaram R, Grover M, Veeravalli PT. Full mouth rehabilitation of a worn out dentition using multidisciplinary approach. *J Orofac Res* 2001;3:54-6.
- Petropoulou A, Pantzari F, Nomikos N, Chronopoulos V, Kourtis S. The use of indirect resin composites in clinical practice: A case series. *Dentistry* 2013;3:173.
- Robinson S, Nixon PJ, Gahan MJ, Chan MF. Techniques for restoring worn anterior teeth with direct composite resin. *Dent Update* 2008;35:551-2, 555-8.
- Milosevic A. Clinical guidance and an evidence-based approach for restoration of worn dentition by direct composite resin. *Br Dent J* 2018;224:301-10.
- Veneziani M. Posterior indirect adhesive restorations: Updated indications and the morphology driven Preparation technique. *Int J Esthet Dent* 2017;12:204-30.
- Milosevic A. Direct placement composite: The treatment modality of choice to restore the worn or eroded dentition in primary dental care. *Prim Dent J* 2016;5:25-9.
- Smithson J, Newsome P, Reaney D, Owen S. Direct or indirect restorations. *Int Dent Afr Ed* 2011;1:70-80.
- Cone MR. Rethinking the traditional full-mouth rehabilitation by applying minimal prosthetic dentistry for maximum patient benefit. *Gen Dent* 2016;64:46-53.
- Shah K. Complex restoration of failing dentition with direct composites. *Int J Dent Med Res* 2015;1:102-5.
- Yang H, Park C, Shin JH, Yun KD, Lim HP, Park SW, *et al.* Stress distribution in premolars restored with inlays or onlays: 3D finite element analysis. *J Adv Prosthodont* 2018;10:184-90.
- Gulamali AB, Hemmings KW, Tredwin CJ, Petrie A. Survival analysis of composite Dahl restorations provided to manage localised anterior tooth wear (ten year follow-up). *Br Dent J* 2011;211:E9.
- Magne P, Belsler UC. Porcelain versus composite inlays/onlays: Effects of mechanical loads on stress distribution, adhesion, and crown flexure. *Int J Periodontics Restorative Dent* 2003;23:543-55.
- Rashid H, Sheikh Z, Misbahuddin S, Kazmi MR, Qureshi S, Uddin MZ, *et al.* Advancements in all-ceramics for dental restorations and their effect on the wear of opposing dentition. *Eur J Dent* 2016;10:583-8.
- Patel M. Treating tooth surface loss: Adhesive restoration of the worn anterior dentition. *Prim Dent J* 2016;5:43-57.
- Brunton PA, Ghazali A, Tarif ZH, Loch C, Lynch C, Wilson N, *et al.* Repair vs replacement of direct composite restorations: A survey of teaching and operative techniques in Oceania. *J Dent* 2017;59:62-7.
- Smales RJ, Berekally TL. Long-term survival of direct and indirect restorations placed for the treatment of advanced tooth wear. *Eur J Prosthodont Restor Dent* 2007;15:2-6.
- Milosevic A, Burnside G. The survival of direct composite restorations in the management of severe tooth wear including attrition and erosion: A prospective 8-year study. *J Dent* 2016;44:13-9.
- Dhadwal AS, Hurst D. No difference in the long-term clinical performance of direct and indirect inlay/onlay composite restorations in posterior teeth. *Evid Based Dent* 2017;18:121-2.
- Angeletaki F, Gkogkos A, Papazoglou E, Kloukos D. Direct versus indirect inlay/onlay composite restorations in posterior teeth. A systematic review and meta-analysis. *J Dent* 2016;53:12-21.
- Douglas RD. Color stability of new-generation indirect resins for prosthodontic application. *J Prosthet Dent* 2000;83:166-70.
- Stawarczyk B, Egli R, Roos M, Ozcan M, Hammerle CH. The impact of *in vitro* aging on the mechanical and optical properties of indirect veneering composite resins. *J Prosthet Dent* 2011;106:386-398.
- Haralur SB, Alfaifi M, Almuaddi A, Al-Yazeedi M, Al-Ahmari A. The effect of accelerated aging on the colour stability of composite resin luting cements using different bonding techniques. *J Clin Diagn Res* 2017;11:ZC57-60.
- El Gezawi M, Kaisarly D, Al-Saleh H, ArRejaie A, Al-Harbi F, Kunzelmann KH, *et al.* Degradation potential of bulk versus incrementally applied and indirect composites: Color, microhardness, and surface deterioration. *Oper Dent* 2016;41:e195-208.
- Abduo J, Lyons K. Increasing occlusal vertical dimension. *Dent Abstr* 2013;58:81-3.
- Hardy CM, Bebelman S, Leloup G, Hadis MA, Palin WM, Leprince JG, *et al.* Investigating the limits of resin-based luting composite photopolymerization through various thicknesses of indirect restorative materials. *Dent Mater* 2018. pii: S0109-5641(17) 31368-4.