


# First Lung Transplantation in Jehovah's Witness Patient in Latin America

Liliana Fernandez-Trujillo<sup>1,2</sup> , Fernando Sanabria<sup>2,3</sup>,  
Diego F Bautista<sup>2,4</sup>, Mauricio Velazquez<sup>2,5</sup>, Indira Cujíño<sup>2,6</sup>,  
Eric Tafur<sup>2</sup>, Daniel Arboleda<sup>2</sup>, Valeria Zuñiga-Restrepo<sup>7</sup>  
and Willian Martinez<sup>2,3</sup>

<sup>1</sup>Department of Internal Medicine, Pulmonology Service, Interventional Pulmonology, Fundación Valle del Lili, Cali, Colombia. <sup>2</sup>Faculty of Health Sciences, Universidad Icesi, Cali, Colombia. <sup>3</sup>Department of Internal Medicine, Pulmonology Service, Fundación Valle del Lili, Cali, Colombia. <sup>4</sup>Department of Critical Care Medicine, Fundación Valle del Lili, Cali, Colombia. <sup>5</sup>Department of Surgery, Thoracic Surgery Service, Fundación Valle del Lili, Cali, Colombia. <sup>6</sup>Department of Anesthesiology, Fundación Valle del Lili, Cali, Colombia. <sup>7</sup>Clinical Research Center, Fundación Valle del Lili, Cali, Colombia.

Clinical Medicine Insights: Case Reports  
Volume 13: 1–5  
© The Author(s) 2020  
Article reuse guidelines:  
sagepub.com/journals-permissions  
DOI: 10.1177/1179547620940737



**ABSTRACT:** Lung transplantation is a life-saving alternative for patients with end-stage lung disease. The procedure itself has a high risk of bleeding. Jehovah's Witness patients refuse to accept blood products due to religious beliefs. A 48-year-old Jehovah's Witness woman presented with an 8-year history of cough, dyspnea along with progressive worsening of her functional class and quality of life. A diagnosis of autoimmune interstitial lung disease was made, for which cyclophosphamide was administered without improvement of symptoms, and the patient was accepted as a transplant candidate. Transplantation was performed without complications, nor blood products requirement, intraoperative cell salvage was performed, and pharmacological agents were used preoperatively for bleeding prevention. The patient only developed anemia after administration of immunosuppressor therapy, which was treated with erythropoietin in the outpatient setting.

**KEYWORDS:** Anemia, blood transfusion, Jehovah's Witness, interstitial lung disease, lung transplantation

**RECEIVED:** November 5, 2019. **ACCEPTED:** May 28, 2020.

**TYPE:** Case Report

**FUNDING:** The author(s) received no financial support for the research, authorship, and/or publication of this article.

**DECLARATION OF CONFLICTING INTEREST:** The author(s) declared no potential conflicts of interest with respect to the research, authorship, and/or publication of this article.

**CORRESPONDING AUTHOR:** Liliana Fernández-Trujillo, Department of Internal Medicine, Pulmonology Service, Interventional Pulmonology, Fundación Valle del Lili, Av. Simón Bolívar. Cra 98 # 18-49, Torre 6, 4th Office 446, Cali 760032, Colombia. Emails: liliana.fernandez@fvl.org.co; lilianafernandeztrujillo@gmail.com

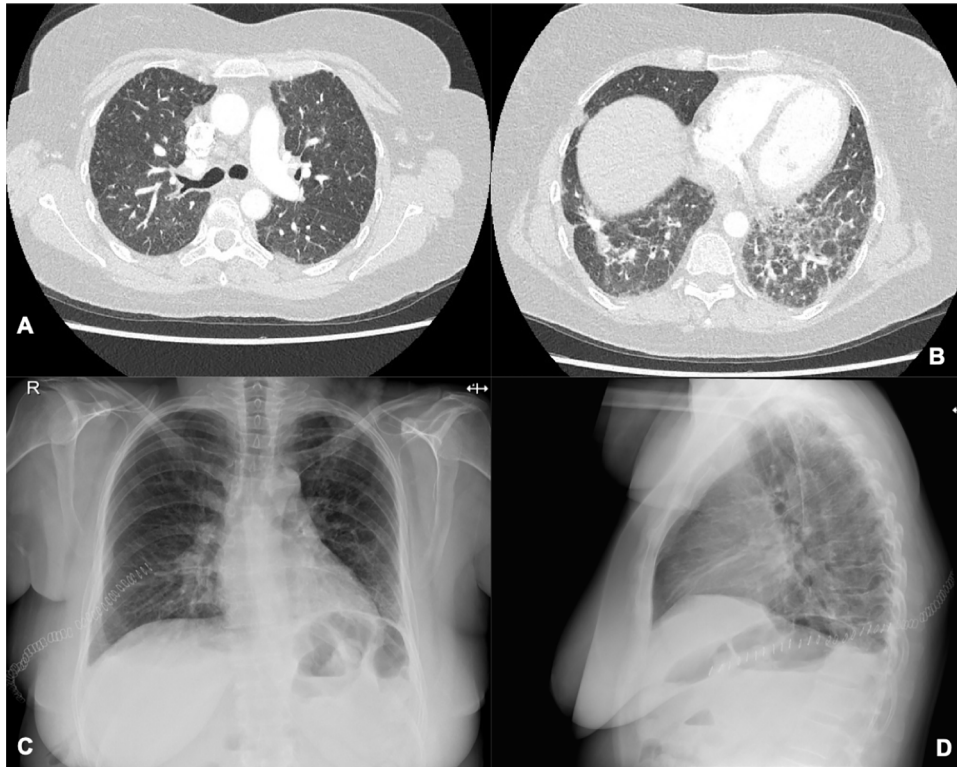
## Introduction

Lung disease is currently the third cause of death worldwide.<sup>1</sup> Lung transplantation (LT) is frequently used as a life-saving option for patients with end-stage lung disease.<sup>2</sup> The first successful report of LT was performed in Toronto (1983) in a group in 5 patients with pulmonary fibrosis.<sup>3</sup> However, it was not until 1997 that the first LT was performed in Colombia on a female patient with pulmonary hypertension.<sup>4</sup> According to the United Network for Organ Sharing of the United States, 2449 lung transplantations were performed during 2017.<sup>5</sup> Bleeding remains as a common complication of this procedure. A retrospective study of 224 patients undergoing LT identified bleeding in 25.3% of the patients.<sup>6</sup>

Bleeding during LT is usually associated to one or more of the following: surgical complexity or difficulties during native lung explant (due to pleural adhesions), or vascular complications derived from hilum manipulation at any time during transplantation. Less frequently, blood loss may be related to use of extracorporeal membrane oxygenation (ECMO) and coagulopathy. Another retrospective study of 15 patients undergoing LT requiring ECMO support reported bleeding as a complication in 33% of patients.<sup>7</sup>

Jehovah's Witnesses refuse to accept blood and blood products due to their religious beliefs, representing an ethical, medical, and legal challenge for both clinicians and surgeons. However, their refusal to accept blood products does not mean refusal of medical treatment. Patient autonomy is a key principle of current bioethical paradigms. Several measures are used to reduce or avoid the need of blood transfusions. The term "Bloodless surgery" refers to a surgery in which the need of allogeneic blood transfusions is avoided.<sup>8</sup> Denton Cooley performed 542 open-heart surgeries in Jehovah's Witness patients with an early mortality within 30 days after operation of 9.4%.<sup>9</sup> In recent years, the term "Patient Blood Management" has emerged, which denotes all the preventive measures undertaken to reduce or eliminate the need for blood transfusions.<sup>10</sup> Normovolemic hemodilution, cell salvage, and administration of antifibrinolytic drugs such as recombinant factor VIIa and tranexamic acid are some of the strategies used.<sup>11</sup> Few cases have been published regarding LT in Jehovah's Witness patients.<sup>12-15</sup> In our hospital, a tertiary care center in Latin America, a recently established multidisciplinary transplantation work team, performs between 6 and 8 lung transplants each year, obtaining satisfactory outcomes similar to that of





**Figure 1.** (A and B) Chest CT, axial view. Chest CT before single-lung transplantation revealed interlobular septal thickening associated with bi-basal ground-glass opacities. (C and D) Chest radiograph, posteroanterior and lateral views. Chest X-ray 8 days after right single-lung transplantation, showing perihilar infiltrates that suggested grade 1 primary graft dysfunction. CT indicates computed tomography.

international reports. This case report represents the first successful LT in a Jehovah's Witness in Latin America.

### Case Report

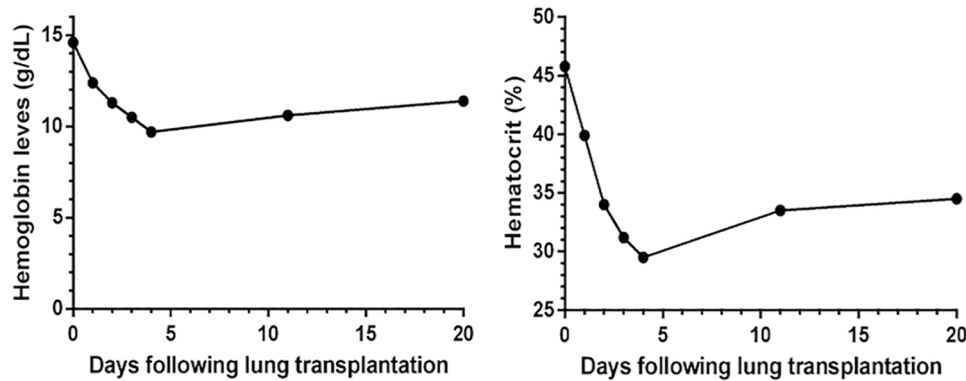
A 48-year-old woman, Jehovah's Witness, presents to the outpatient of pulmonology service, with 8-year history of chronic cough and dyspnea, along with a progressive deterioration of her functional class (NYHA IV), along with permanent requirement of oxygen therapy and decline in the quality of life. Computed tomography scan of the chest revealed interstitial lung disease (see Figure 1A and B). Rheumatoid factor was positive and anticardiolipin antibodies were in indeterminate range; rest of autoimmune profile was negative. The patient did not present with clinical features of autoimmune disease. A diagnosis of autoimmune featured interstitial lung disease was made; cyclophosphamide cycle was administered without improvement of symptoms. Lung biopsy was taken via video-assisted pulmonary wedge resection, under general anesthesia. Pathology showed a histologic pattern consistent with usual interstitial pneumonia. Due to failure of medical therapy, the patient was accepted as a transplant candidate. However, due to religious beliefs, the patient stated that she does not accept blood products. Pulmonary function tests revealed a forced vital capacity (FCV) of 1.33 (44%), a forced expiratory volume in one second ( $FEV_1$ ) of 1.10 (44%),  $FEV_1/FVC$  ratio of 83%, partial pressure of oxygen ( $PO_2$ ) of 91.3 mmHg and partial pressure of carbon dioxide ( $PCO_2$ ) of 55.1 mmHg, diffusing

capacity for carbon monoxide (DLCO) 8.1 mL/mmHg/min (31%), 6-minute walk distance of 422 meters (73%), and a minimal oxygen saturation of 76 % without oxygen therapy.

Several months later, and after meticulous case review held by the lung transplant board (anesthesia, thoracic surgery, pulmonology), abdominal organ transplant board, and ethics committee, the patient was admitted for single-lung transplantation. She signed an informed consent declining transfusion of blood components, however agreeing to continuous cell-saver use. In the case of major perioperative bleeding, the patient also accepted the use of a prothrombin complex concentrate (which has advantages over fresh frozen plasma as it allows rapid correction of coagulation factor deficits with less volume infusion) and desmopressin. Blood loss during surgery was planned to be restored with 5% lactalbumin, in order to reduce the use of crystalloids in the event of significant bleeding.

The patient's anthropometrics were 71 kg weight and 160 cm height. Regarding general procedure information, length of the procedure was 135 minutes. Cold Ischemia time was 230 minutes; there was no need for ECMO support. Bleeding during the procedure was estimated at 300 mL. Pulmonary artery pressure (PAP) was continuously measured, achieving a mean PAP of 18 mmHg in average during surgery.

Regarding hemostatic perioperative management for this patient, recommendations established in the current literature within the "Patient Blood Management" at the time were taken into account. Since preoperative hemoglobin was within



**Figure 2.** Hemoglobin levels during postoperative period. Hemoglobin levels decreased during the late ICU phase but remained stable at the end of hospitalization. ICU indicates intensive care unit.

normal values (14.6 g/dL), no additional measures were taken to optimize erythropoiesis. To minimize bleeding in the intraoperative setting, blood preservation methods were used: prophylactic use of antifibrinolytics was planned preoperatively, using an initial bolus of tranexamic acid 1 g, followed by continuous infusion during surgery. Fluids were adjusted at 2 to 4 cc/kg/h and readjusted according to intraoperative hemodynamic and metabolic variables. Insensible fluid loss was restored infusing a total of 870 cc of Ringer's lactate. Normothermia was maintained with the use of Blanketrol heating system, and electrocautery scalpels were used to obtain a thorough surgical hemostasis with the help of topical hemostatic agents (tissue sealant/Surgicel). The patient agreed to intraoperative closed-system cell salvage, as it did not represent a conflict with her religious beliefs. Bleeding during surgery was calculated as of 300 cc, from which 120 cc were reinfused postoperatively. Finally, during the postoperative period, a drainage thoracotomy was positioned for a better quantification of postoperative bleeding and adequate blood evacuation from the lung. Erythropoietin was initiated during hospitalization.

After surgery, the patient was admitted to the intensive care unit, early extubation was successfully achieved, and there was no need of vasopressors or inotropes. PaO<sub>2</sub>/FiO<sub>2</sub> ratio of 480 mmHg. Chest radiography revealed right perihilar infiltrates. The previous findings suggested a primary graft dysfunction grade 1 (see Figure 1C and D). Intensive care unit length of stay was 4 days, and total hospitalization length of stay was 13 days. Hemoglobin levels decreased at the end of hospitalization (see Figure 2). The patient was discharged without further complications with hemoglobin levels of 10.6 g/dL, which was treated in the outpatient setting with subcutaneous erythropoietin 2000 IU 3 times per week as ordered by internal medicine and pulmonology physicians. Hemoglobin levels increased to 11.4 g/dL at 1-week follow-up.

Pulmonary function tests after LT revealed FVC of 1.88 (53%), FEV<sub>1</sub> of 1.73 (59%), FEV<sub>1</sub>/FVC of 92%, 6-minute walk distance of 353 meters (67%), and a minimal oxygen saturation of 94% without oxygen therapy. The patient final hemoglobin level was 11.4 g/dL.

## Discussion

Although many years have passed since the development of LT, bleeding remains a common complication in this procedure. However, predictors of blood loss during LT remain to be investigated. Studies have shown that cardiopulmonary bypass, double-lung transplantations, re-sternotomy, Eisenmenger's syndrome, vascularized adhesions, and cystic fibrosis tend to be related to higher perioperative blood products requirements.<sup>6,16,17</sup> On the other hand, single-lung transplantations have been found to be related with less requirement of platelets, packed red blood cells, and fresh frozen plasma.<sup>18</sup>

Blood transfusion has been related with intrinsic and irreversible adverse effects such as infections, transfusion reactions, volume overload, and graft-versus-host disease.<sup>19</sup> Jehovah's Witness patients refuse to accept blood and blood products due to religious beliefs. Following a shared decision making, and taking into account the patient's will, several measures are used to avoid or reduce the need of transfusions. However, these measures are not standardized, and their choice depends on the clinician's preference and experience. In this case, parameters from the Blood Patient Management were followed, obtaining satisfactory results.

Most of the case reports published regarding LT in Jehovah's Witness are middle-aged patients with idiopathic pulmonary fibrosis, all of them are cases of single-lung transplantations (see Table 1).<sup>11-14</sup> Despite the lack of evidence, recent studies support bilateral lung transplantation in terms of long-term survival.<sup>20</sup> Therefore, single-lung transplantation has been indicated in special circumstances in which the surgical risk is high such as in older patients with chronic obstructive pulmonary disease (COPD) or interstitial lung disease.<sup>21</sup> Even though our patient would have theoretically benefited from bilateral lung transplantation, we decided to perform single-lung transplantation, taking into consideration the high risk for ECMO support in case of complications and, therefore, higher risk of use of blood products.

In this case, there was no need for imminent blood transfusion. Protocols to minimize bleeding were applied and worked successfully. It is important to mention that additionally to

**Table 1.** Previously published cases of lung transplantation in Jehovah's Witnesses.

AUTHOR	CONTE AND ORENS <sup>12</sup>	GRANDE ET AL <sup>13</sup>	MADUEÑO ET AL <sup>14</sup>	PARTOVI ET AL <sup>15</sup>
Age	48	38	56	65 69
Sex	Female	Female	Male	Male
Pathology	IPF	IPF	COPD	IPF
Secondary pulmonary hypertension	Yes	No	No	No
Type of transplant	Left single-lung	Right single-lung	Right single-lung	Left single-lung
Survival	Unknown	14 months	25 months	4 months of following

Abbreviations: COPD, chronic obstructive pulmonary disease; IPF, idiopathic pulmonary fibrosis; UIP, usual interstitial pneumonia.

patient's informed consent and approval of nontransfusion (only maneuvers mentioned in the case report), medical staff was also ethically prepared for this decision, after meeting the ethics committee and thoroughly discussing all possible approaches for this case. Therefore, if the patient had had the need for transfusion, despite all measures adopted, her wishes would have prevailed, and it would have not been performed.

Nearly all of the cases reported do not describe the measures taken to prevent or treat anemia. Madueño et al reported a 56-year-old man with terminal emphysema-type COPD with single-lung transplantation. No cell salvage or antifibrinolytic agents were used intraoperatively; the patient developed anemia in the early intensive care unit phase. In the case described here, tranexamic acid and cell salvage were used intraoperatively, in addition to multiple strategies described above regarding the anesthetic and surgical approach. The patient developed anemia during the late intensive care unit phase. It is known that immunosuppressive therapy, especially mycophenolate and tacrolimus, may lead to hematologic toxicity,<sup>22,23</sup> which may have been responsible for the patient's anemia. Also, prophylactic agents such as valganciclovir and trimethoprim/sulfamethoxazole have been reported to generate adverse effects which may result in hemolytic anemia.<sup>24,25</sup>

LT in Jehovah's Witness patients is a complex medical situation, mainly because of the high risk of bleeding of procedure itself and the refusal of Jehovah's Witness patients to accept blood products. However, multidisciplinary approach with a proper medical support will result in a better outcome for these patients, as shown in this particular case, where at least 3 specialties worked as a team, which resulted in a systematic and organized preoperative plan and approach based on Patient Blood Management, in order to perform a successful bloodless single-lung transplantation, and eventually prevent anemia and further complications derived from surgery and medical therapy.

### Author Contributions

All authors have significantly contributed to the article: L.F.-T.: Conception and design, literature review, manuscript

writing and correction, and final approval of manuscript. F.S., D.F.B., M.V., I.C., E.T., and D.A.: Literature review, manuscript writing and correction, and final approval of manuscript. V.Z.-R.: Manuscript writing and correction and final approval of manuscript. W.M.: Conception and design, literature review, manuscript writing and correction, and final approval of manuscript.

### Consent for Publication

Written informed consent was obtained from the patient for publication of this case report and any accompanying images. A copy of the written consent is available for review by the Editor-in-Chief of this journal.

### Ethical Approval and Consent to Participate

This report was prepared in accordance with the ethical standards of the institutional ethics committee and with the 1964 Helsinki Declaration. We have approval letter of Ethics Committee in biomedical research IRB /EC No. 207 - 2019 of the Fundación Valle del Lili to publish this article.

### ORCID iD

Liliana Fernandez-Trujillo  <https://orcid.org/0000-0003-0789-9154>

### Data Availability

All data and material are available for sharing if needed.

### REFERENCES

- World Health Organization. The top 10 causes of death. <http://www.who.int/news-room/fact-sheets/detail/the-top-10-causes-of-death>. Accessed November 2, 2018.
- Yeung JC, Keshavjee S. Overview of clinical lung transplantation. *Cold Spring Harb Perspect Med*. 2014;4:a015628.
- Dalton ML. The first lung transplantation. *Ann Thorac Surg*. 1995;60:1437-1438.
- Olaya L, Olaya C, Martinez S, et al. Historia del primer trasplante de pulmón en Colombia. *Rev Colomb Cardiol*. 1999;7:443-449.
- UNOS. Transplant trends. <https://unos.org/data/transplant-trends/>. Published October 29, 2018. Accessed November 26, 2018.
- Paradela M, González D, Parente I, et al. Surgical risk factors associated with lung transplantation. *Transplant Proc*. 2009;41:2218-2220.

7. Cottini SR, Wenger U, Sailer S, et al. Extracorporeal membrane oxygenation: beneficial strategy for lung transplant recipients. *J Extra Corpor Technol.* 2013;45:16-20.
8. Afshar A, Kyle RA, Steensma DP. Adolf Lorenz—the bloodless surgeon of Vienna. *Mayo Clin Proc.* 2017;92:e105-e106.
9. Ott DA, Cooley DA. Cardiovascular surgery in Jehovah's Witnesses. *JAMA.* 1977;238:1256.
10. Shander A, Javidrooz M, Perelman S, Puzio T, Lobel G. From bloodless surgery to patient blood management. *Mt Sinai J Med.* 2012;79:56-65.
11. Chand N, Subramanya H, Rao G. Management of patients who refuse blood transfusion. *Indian J Anaesth.* 2014;58:658-664.
12. Conte JV, Orens JB. Lung transplantation in a Jehovah's Witness. *J Heart Lung Transplant.* 1999;18:796-800.
13. Grande AM, Rinaldi M, D'Armini AM, Pellegrini C, Viganò M. Lung transplantation in a Jehovah's witness. Case report in a twinning procedure. *J Cardiovasc Surg (Torino).* 2003;44:131-134.
14. Cerezo Madueño F, Arango Tomás E, Salvatierra Velázquez Á. Lung transplant in Jehovah's Witness patient. *J Thorac Cardiovasc Surg.* 2013;145:e65-e67.
15. Partovi S, Bruckner BA, Staub D, et al. Bloodless lung transplantation in Jehovah's Witnesses: impact on perioperative parameters and outcome compared with a matched control group. *Transplant Proc.* 2013;45:335-341.
16. Triulzi DJ, Griffith BP. Blood usage in lung transplantation. *Transfusion.* 1998;38:12-15. doi:10.1046/j.1537-2995.1998.38198141492.x.
17. Vivacqua A, Koch CG, Yousuf AM, et al. Morbidity of bleeding after cardiac surgery: is it blood transfusion, reoperation for bleeding, or both? *Ann Thorac Surg.* 2011;91:1780-1790. doi:10.1016/j.athoracsur.2011.03.105.
18. Wang Y, Kurichi JE, Blumenthal NP, et al. Multiple variables affecting blood usage in lung transplantation. *J Heart Lung Transplant.* 2006;25:533-538. doi:10.1016/j.healun.2005.12.004.
19. Rawn J. The silent risks of blood transfusion. *Curr Opin Anaesthesiol.* 2008;21:664-668.
20. Aryal S, Nathan SD. Single vs. bilateral lung transplantation. *Curr Opin Organ Transplant.* 2018;23:316-323.
21. Puri V, Patterson GA, Meyers BF. Single versus bilateral lung transplantation. *Thorac Surg Clin.* 2015;25:47-54.
22. Danesi R, Del Tacca M. Hematologic toxicity of immunosuppressive treatment. *Transplant Proc.* 2004;36:703-704. doi:10.1016/j.transproceed.2004.03.016.
23. Jacobson PA, Schladt D, Oetting WS, et al; and DeKAF investigators. Genetic determinants of mycophenolate-related anemia and leukopenia after transplantation. *Transplantation.* 2011;91:309-316. doi:10.1097/TP.0b013e318200e971.
24. Perrotet N, Decosterd LA, Meylan P, Pascual M, Biollaz J, Buclin T. Valganciclovir in adult solid organ transplant recipients: pharmacokinetic and pharmacodynamic characteristics and clinical interpretation of plasma concentration measurements. *Clin Pharmacokinet.* 2009;48:399-418. doi:10.2165/00003088-200948060-00006.
25. Linnik YA, Tsui EW, Martin IW, et al. The first reported case of concurrent trimethoprim-sulfamethoxazole-induced immune hemolytic anemia and thrombocytopenia. *Transfusion.* 2017;57:2937-2941. doi:10.1111/trf.14315.