

A comparative study of the deviation of the menton on posteroanterior cephalograms and three-dimensional computed tomography

Hee Jin Lee¹, Sungeun Lee¹, Eun Joo Lee², In Ja Song³, Byung-Cheol Kang⁴, Jae-Seo Lee⁴,
Hoi-Jeong Lim⁵, Suk-Ja Yoon^{4,*}

¹School of Dentistry, Dental Science Research Institute, Chonnam National University, Gwangju, Korea

²Department of Oral Anatomy, School of Dentistry, Dental Science Research Institute, Chonnam National University, Gwangju, Korea

³Department of Nursing, Kwangju Women's University, Gwangju, Korea

⁴Department of Oral and Maxillofacial Radiology, School of Dentistry, Dental Science Research Institute, Chonnam National University, Gwangju, Korea

⁵Department of Orthodontics, School of Dentistry, Dental Science Research Institute, Chonnam National University, Gwangju, Korea

ABSTRACT

Purpose: Facial asymmetry has been measured by the severity of deviation of the menton (Me) on posteroanterior (PA) cephalograms and three-dimensional (3D) computed tomography (CT). This study aimed to compare PA cephalograms and 3D CT regarding the severity of Me deviation and the direction of the Me.

Materials and Methods: PA cephalograms and 3D CT images of 35 patients who underwent orthognathic surgery (19 males and 16 females, with an average age of 22.1 ± 3.3 years) were retrospectively reviewed in this study. By measuring the distance and direction of the Me from the midfacial reference line and the midsagittal plane in the cephalograms and 3D CT, respectively, the x-coordinates (x_1 and x_2) of the Me were obtained in each image. The difference between the x-coordinates was calculated and statistical analysis was performed to compare the severity of Me deviation and the direction of the Me in the two imaging modalities.

Results: A statistically significant difference in the severity of Me deviation was found between the two imaging modalities ($\Delta x = 2.45 \pm 2.03$ mm, $p < 0.05$) using the one-sample t-test. Statistically significant agreement was observed in the presence of deviation ($k = 0.64$, $p < 0.05$) and in the severity of Me deviation ($k = 0.27$, $p < 0.05$). A difference in the direction of the Me was detected in three patients (8.6%). The severity of the Me deviation was found to vary according to the imaging modality in 16 patients (45.7%).

Conclusion: The measurement of Me deviation may be different between PA cephalograms and 3D CT in some patients. (*Imaging Sci Dent* 2016; 46: 33-8)

KEY WORDS: Facial Asymmetry; Anatomic Landmarks; Tomography, X-Ray Computed

Introduction

Cephalograms have played an important role in diagnosis and treatment planning in orthodontics.¹⁻³ Posteroanterior (PA) cephalograms have traditionally been used for the evaluation of facial asymmetry, and making a diagnosis using this imaging modality requires the accurate

establishment of the facial midline and correct measurements of the distances and angles of landmarks.¹⁻³ The menton (Me) is the landmark that is most commonly used to determine the severity of facial asymmetry.¹⁻⁴ Two methods of determining Me deviation on cephalograms have been introduced. One measures the perpendicular distance of the Me from the facial midline.² The other measures the angle between the facial line and the anterior nasal spine (ANS)-Me line or the crista galli (Cg)-Me line.^{1,3,5}

Cephalograms have limitations in analyzing three-dimensional (3D) human facial structure because they offer

Received October 16, 2015; Revised December 2, 2015; Accepted December 17, 2015

*Correspondence to : Prof. Suk-Ja Yoon

Department of Oral and Maxillofacial Radiology, School of Dentistry, Chonnam National University, 77 Yongbong-ro, Buk-gu, Gwangju 61186, Korea
Tel) 82-62-530-5680, Fax) 82-62-530-5810, E-mail) yoonfr@chonnam.ac.kr

Copyright © 2016 by Korean Academy of Oral and Maxillofacial Radiology

This is an Open Access article distributed under the terms of the Creative Commons Attribution Non-Commercial License (<http://creativecommons.org/licenses/by-nc/3.0>) which permits unrestricted non-commercial use, distribution, and reproduction in any medium, provided the original work is properly cited.

Imaging Science in Dentistry · pISSN 2233-7822 eISSN 2233-7830

a two-dimensional (2D) depiction of the anatomy that inherently produces image distortion, magnification, and superimposition.^{5,6} Meanwhile, 3D computed tomography (CT) has no image superimposition, magnification, or distortion, providing accurate 3D measurements of linear and curvilinear distances and angles. Thus, 3D CT leads to high reproducibility and accuracy.^{6,9} Image reconstruction software also provides 3D volumetric images, free angle viewing, and selective views of soft and hard tissues.^{5,10} Previous studies have shown 3D CT to be more effective than cephalograms in facial asymmetry analysis.^{5,10,11} However, 3D CT involves a higher dose of radiation, and it cannot be used for regular, periodic examinations, whereas cephalograms use a lower dose and thus can be used regularly.

The severity of facial asymmetry determined on cephalograms has been used in 3D CT analyses of facial asymmetry to classify subjects as asymmetric and symmetric.^{5,12-16} The severity of facial asymmetry is determined by the deviation of the Me from the facial midline. However, no research has been conducted on whether the severity of Me deviation and the severity of facial asymmetry measured on cephalograms are the same as those measured using 3D CT. This study aimed to compare the severity of Me deviation and direction in PA cephalograms and 3D CT.

Materials and Methods

Study subjects

This study included 35 orthodontic patients who underwent orthognathic surgery between 2000 and 2007. The average A point-nasion-B point angle (ANB) of the pa-

tients was $-3.63^\circ \pm 2.65^\circ$. Among them, 15 (seven males and females; average age, 22.3 ± 3.3 years) had a normal range of Me deviation ($0 \text{ mm} \leq \text{Me} < 2 \text{ mm}$), and 20 (12 males and eight females; average age, 21.9 ± 3.4 years) had moderate asymmetry ($4 \text{ mm} \leq \text{Me} \leq 8 \text{ mm}$) on PA cephalograms.² The average ANB of these patients was $-3.63^\circ \pm 2.65^\circ$.

Measurement of the deviation of the Me on PA cephalograms

Cephalograms were taken using a cephalometric radiograph machine (Cranex 3+, Soredex, Helsinki, Finland) with a focal spot-object distance of 150 cm, a focal spot-film distance of 15 cm, a current of 7-8 mA, a voltage of 80 kVp, and an exposure time of 1.2-1.7 seconds. The mid-facial line was drawn as a line perpendicular to the line connecting Lo-Lo' through Nc, where Lo and Lo' correspond to the bilateral intersection of the oblique orbital line with the lateral contour of the right and left side orbits, and Nc is the neck of the Cg. The distance of the Me from the midfacial line was determined as the deviation of the Me (x_1) on a PA cephalogram film, using tracing paper and a view box (Fig. 1A).²

Measurement of the deviation of the Me on 3D CT

CT scans were obtained from a spiral CT scanner (Light Speed QX/I, GE Medical Systems, Milwaukee, WI, USA). The patient was placed on the table, positioning the head with the Frankfurt horizontal line perpendicular to the floor and positioning the middle of the dentition parallel to the long axis of the machine. The imaging parameters were set at 120 kV, 200 mA, a 512×512 matrix, and a gantry

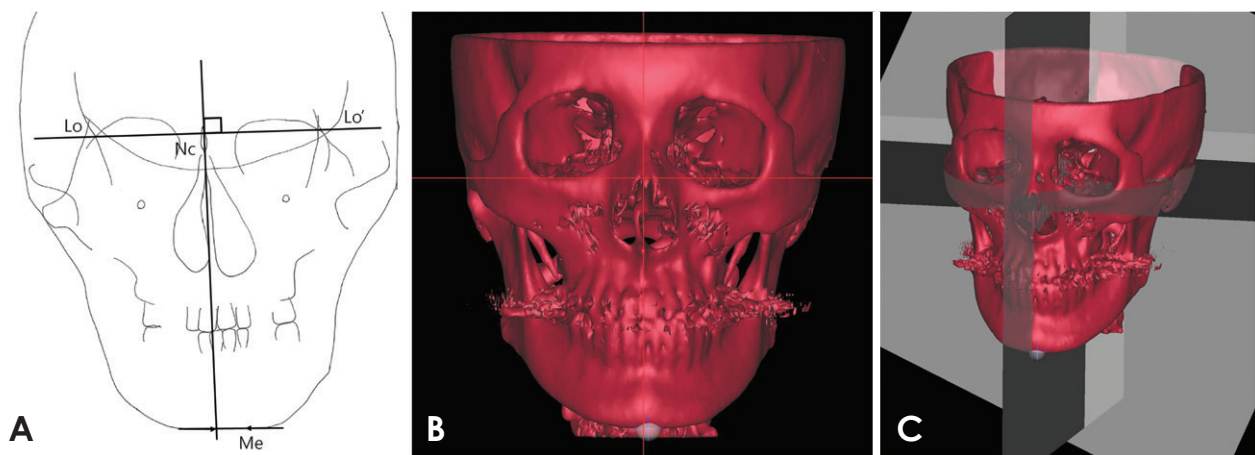


Fig. 1. Menton deviation as measured on the posteror anterior (PA) cephalogram (x_1) and three-dimensional computed tomography (3D CT) (x_2) of one patient. A. Menton deviation (x_1) was measured from the midfacial line on the PA cephalogram. B. Menton deviation (x_2) is measured from the midsagittal reference plane on 3D CT. C. Three orthogonal planes are established on 3D CT.

angle of zero. The axial image slice was 2.5 mm, the table speed was 3 mm/s, and the scanning time was 0.8 s. The field of view was 18 cm, covering the superior of the orbit and the entire mandible. Digital Imaging and Communication in Medicine (DICOM) images were created at a slice thickness of 1.0 mm. The acquired data from these images were transferred to a personal computer, and the CT data were used to construct 3D images with the software Vworks + Vsurgery (Cybermed, Seoul, Korea). The surface shaded display was obtained at a threshold value of 126. Landmarks were identified, confirming the location on the axial, sagittal, and coronal planes. On each CT scan, the midsagittal reference plane (MRP) was made with the following three landmarks: opisthion, Cg, and ANS.^{5,16} The horizontal reference plane (HRP) was made with right orbitale and left porion and was perpendicular to the midsagittal reference plane. The coronal reference plane was made perpendicular to the midsagittal and horizontal reference planes, passing through the opisthion.^{17,18}

The Me was identified by defining its axial, midsagittal, and coronal position on the multiplanar reformation mode, and the deviation of the Me (x_2) was determined as the distance of the Me from the midsagittal reference plane (Figs. 1B and C).¹⁷⁻¹⁹

The extent of Me deviation was considered to be normal when the distance of the Me from the MRP (x) was less than 2 mm ($0 \text{ mm} \leq x < 2 \text{ mm}$), mild when less than 4 mm ($2 \text{ mm} \leq x < 4 \text{ mm}$), moderate when less than 8 mm ($4 \text{ mm} \leq x < 8 \text{ mm}$), and severe at values of 8 mm or higher ($8 \text{ mm} \leq x$).²

Statistical analysis

The difference in the location of the Me determined by the two imaging modalities ($|x_1 - x_2| = \Delta x$) was statistically analyzed using the one-sample t-test. The agreement of the deviation of the Me between the imaging modalities was evaluated through Bland-Altman plot. The correlation between x_1 and x_2 was analyzed by Pearson's correlation coefficient. Cohen's kappa coefficient was obtained to determine whether the two imaging modalities agreed with each other in the determination of the severity of facial asymmetry and the direction of the deviation of the Me. Statistical analysis was performed using IBM SPSS (IBM Corp., Armonk, NY, USA).

Results

The deviation of the Me was measured on PA cephalograms and 3D CT, respectively, and the results were ana-

lyzed to identify statistically significant differences between these imaging modalities in the severity of Me deviation and direction of Me.

The severity of Me deviation

A statistically significant difference was found between x_1 and x_2 using the one-sample t-test ($\Delta x = 2.45 \pm 2.03 \text{ mm}$, $p < 0.05$) (Table 1). A Bland-Altman plot showed that the differences ($x_1 - x_2$) were scattered around the mean (minimum mean = -14.48 mm , maximum mean = 11.82 mm). The slope of the regression line was 0.08, but no statistically significant difference from 0 was found (with a confidence of 95% with a width of 12.58 mm). Systematic errors were observed between the two imaging modalities, but those errors had no relationship with the deviation of the Me (Fig. 2). The Pearson correlation coefficient of the deviation of the Me (x_1 and x_2) of both imaging modalities was 0.86, which was statistically significant ($p < 0.05$).

The kappa coefficient of the severity of Me deviation

Table 1. Comparison of menton deviation between posteroanterior (PA) cephalograms and three-dimensional computed tomography (3D CT) based on mean \pm standard deviation values

PA cephalogram (x_1)	3D CT (x_2)	Difference (Δx)
0.82 ± 6.21	0.87 ± 5.78	$2.45 \pm 2.03^*$

*Statistically significant by the one-sample t-test ($p < 0.05$)

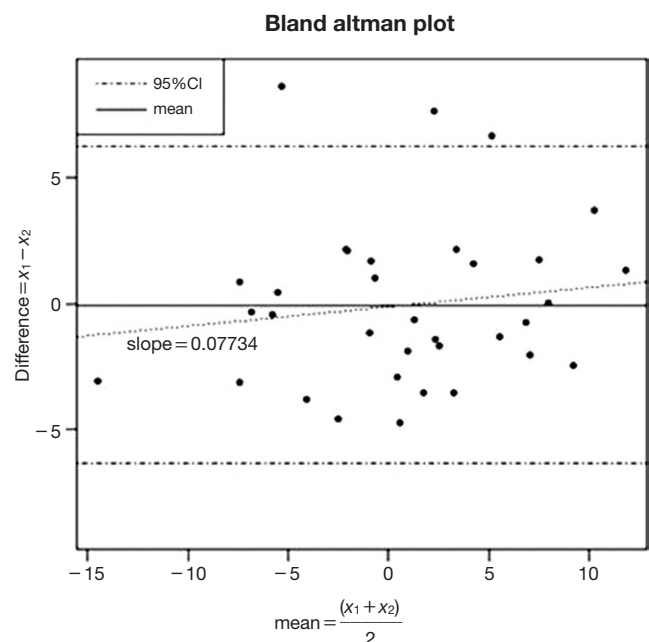


Fig. 2. Bland-Altman difference plot for analyzing the agreement between posteroanterior cephalograms and computed tomography.

Table 2. Correlation analysis for the severity of menton deviation between cephalograms and computed tomography (CT) (n)

Cephalograms	CT	Normal (0-2 mm)	Mild (2-4 mm)	Moderate (4-8 mm)	Severe (≥ 8 mm)	Total
Normal (0-2 mm)		7	6	1	1	15 (42.9%)
Mild (2-4 mm)		0	0	0	0	0 (0.0%)
Moderate (4-8 mm)		2	3	5	1	11 (31.4%)
Severe (≥ 8 mm)		1	0	4	4	9 (25.7%)
Total		10 (28.6%)	9 (25.7%)	10 (28.6%)	6 (17.1%)	35 (100.0%)

Cohen’s kappa coefficient = 0.27 ($p < 0.05$)

Table 3. The direction of the menton in cephalograms and computed tomography.

Cephalogram	CT	Right	0	Left	Total
Right		13	0	2	15
0		1	0	2	3
Left		1	0	16	17
Total		15	0	20	35

Cohen’s kappa coefficient = 0.64 ($p < 0.05$)

on both imaging modalities was 0.27, showing fair agreement. Sixteen patients (45.7%) showed a difference in the severity of facial asymmetry between the two imaging modalities. A two-stage difference was found in five patients (14.3%) (Table 2).

The direction of the Me

The kappa coefficient of the direction of the Me on both imaging modalities was 0.64, indicating substantial agreement. A discrepancy in the direction of the Me was detected in three patients (8.6%) (Table 3).

Discussion

Facial asymmetry is diagnosed when the maxillary or mandibular midline deviates from the craniofacial midline or when a bilateral difference in facial height or width is present.¹⁻⁵ The recently increased interest in esthetic faces has elicited an increase in the number of patients who desire to undergo orthognathic surgery, resulting in a higher utilization rate of 3D CT for diagnostic purposes.^{5,11-16} The Me is the landmark that is most related with the concept of facial asymmetry.^{1,4}

The measurement of Me deviation on PA cephalograms was introduced by Haraguchi et al.² This measurement was applied to the analysis of 3D CT for the classification of patients as asymmetric or symmetric, where those with $0 \text{ mm} \leq \text{Me} < 2 \text{ mm}$ were classified as symmetric and those with a $\text{Me} \geq 4 \text{ mm}$ were classified as asymmetric.^{2,12-15}

However, no research has determined whether the severity of Me deviation and the direction of the Me on PA cephalograms are the same as those obtained in 3D CT images. This study aimed to compare the severity of Me deviation and the direction of the Me on PA cephalograms and on 3D CT.

Previous research has reported that the deviation of maxillary and mandibular midfacial landmarks was inconsistent depending how the midsagittal reference plane was determined.^{17,20} Many methods have been used to establish the MRP,^{5,10-14,16-18,20} but generally the methods can be classified into two groups. One group of methods first identifies the HRP with three landmarks and then establishes the MRP perpendicularly to the HRP, passing through a midfacial landmark.^{12-14,17} The other group of methods establishes the MRP with three midfacial landmarks,^{5,10,11,16,17,20} as was done in this study.

In the method in which the HRP is first identified and MRP is established perpendicularly to the HRP, the MRP is influenced by the HRP.^{12-14,17} Then, if the Cg is not used for the MRP, the MRP has no relationship with the method established by Haraguchi et al.,² who used the Nc (the neck of the Cg) to establish the midfacial line; nevertheless, some studies have still applied the measurement of the Me by Haraguchi et al.² to facial asymmetry analysis utilizing 3D CT.¹⁴ Likewise, the measurement of Me deviation has been uncontroversially used in the analysis of 3D CT as the standard for classifying patient groups.^{5,12-16,21}

Comparing the measurements of the Me between PA cephalograms and 3D CT in 35 patients, the severity of the deviation of the Me was different to a statistically significant extent ($\Delta x = 2.45 \pm 2.03 \text{ mm}$, $p < 0.05$), with 19 patients (54.3%) showing a difference in the severity of the deviation, and three patients (8.6%) showing a discrepancy in the direction of the deviation. Among 15 patients with a normal extent of Me deviation on cephalograms, six had mild deviation, one had moderate deviation, and one had severe deviation on 3D CT. Among 11 patients

with moderate deviation on cephalograms, 3D CT demonstrated that two had a normal extent of deviation, three had mild deviation, and one had severe deviation. Among the nine patients with severe deviation on cephalograms, one had normal deviation and four had moderate deviation on 3D CT. Two patients with Me deviation to the right on their cephalogram showed deviation to the left on 3D CT, and one patient with Me deviation to the left on the cephalogram had deviation to the right on 3D CT (Tables 1-3). These differences between the imaging modalities were caused by several factors. Firstly, the landmarks Lo and Lo' that were used for the midfacial line on PA cephalograms are not actually present on the human skull. Lo is the intersection between the oblique orbital line and the lateral contour of the orbit. The oblique orbital line is the radiopaque image of the greater wing of the sphenoid bone, projected onto the orbit when a conventional cephalogram is taken.^{22,23} The Nc is a point on PA cephalograms, but it is not a point on the 3D anatomy and it does not really exist. The midfacial line was drawn on the PA cephalograms using Lo, Lo', and the Nc as landmarks, all of which are anatomically absent on the human skull, making it impossible to identify Lo, Lo', and the Nc on 3D CT. Secondly, the distortion and magnification of 3D anatomic structures are an unavoidable and inherent problem of 2D conventional radiographs. The location of the Me could also be distorted on PA cephalograms, making its location different from that observed on 3D CT. Therefore, the midfacial line on PA cephalograms is different from the MRP on 3D CT.

The Me is an important landmark in determining the amount of facial asymmetry. The Me also determines the deviated and opposite side of the face for the analysis of bilateral differences.^{2,3,5,10,13-19} This study showed that applying the deviation of the Me measured on PA cephalograms to 3D CT may decrease the validity of facial asymmetry analysis. The direction of the deviation of the Me showed substantial agreement ($k=0.64$, $p<0.05$), but the discrepancy in the direction observed in three patients (8.6%) should not be neglected. The severity of facial asymmetry showed fair agreement ($k=0.27$, $p<0.05$), with a discrepancy in severity in 16 patients (45.7%) and a discrepancy of two stages in five patients (14.3%) (Tables 1 and 3). The severity of Me deviation and the direction of Me deviation were different between PA cephalograms and 3D CT in some patients. This study suggests that in a facial asymmetry analysis using 3D CT, the definition of facial asymmetry should be based on Me deviation on 3D CT, not on the cephalogram.

References

1. Grummons DC, Kappeyne van de Coppello MA. A frontal asymmetry analysis. *J Clin Orthod* 1987; 21: 448-65.
2. Haraguchi S, Takada K, Yasuda Y. Facial asymmetry in subjects with skeletal Class III deformity. *Angle Orthod* 2002; 72: 28-35.
3. Ferguson JW. Cephalometric interpretation and assessment of facial asymmetry secondary to congenital torticollis. The significance of cranial base reference lines. *Int J Oral Maxillofac Surg* 1993; 22: 7-10.
4. Ahn JS, Hwang HS. Relationship between perception of facial asymmetry and posteroanterior cephalometric measurements. *Korean J Orthod* 2001; 31: 489-98.
5. Hwang HS, Hwang CH, Lee KH, Kang BC. Maxillofacial 3-dimensional image analysis for the diagnosis of facial asymmetry. *Am J Orthod Dentofacial Orthop* 2006; 130: 779-85.
6. Matteson SR, Bechtold W, Phillips C, Staab EV. A method for three-dimensional image reformation for quantitative cephalometric analysis. *J Oral Maxillofac Surg* 1989; 47: 1053-61.
7. Kragsskov J, Bosch C, Gyldensted C, Sindet-Pedersen S. Comparison of the reliability of craniofacial anatomic landmarks based on cephalometric radiographs and three-dimensional CT scans. *Cleft Palate Craniofac J* 1997; 34: 111-6.
8. Cavalcanti MG, Vannier MW. Quantitative analysis of spiral computed tomography for craniofacial clinical applications. *Dentomaxillofac Radiol* 1998; 27: 344-50.
9. Jeon KJ, Park H, Lee HC, Kim KD, Park CS. Reproducibilities of cephalometric measurements of three-dimensional CT images reconstructed in the personal computer. *Korean J Oral Maxillofac Radiol* 2003; 33: 171-8.
10. Katsumata A, Fujishita M, Maeda M, Ariji Y, Ariji E, Langlais RP. 3D-CT evaluation of facial asymmetry. *Oral Surg Oral Med Oral Pathol Oral Radiol Endod* 2005; 99: 212-20.
11. Maeda M, Katsumata A, Ariji Y, Muramatsu A, Yoshida K, Goto S, et al. 3D-CT evaluation of facial asymmetry in patients with maxillofacial deformities. *Oral Surg Oral Med Oral Pathol Oral Radiol Endod* 2006; 102: 382-90.
12. Kwon TG, Park HS, Ryoo HM, Lee SH. A comparison of craniofacial morphology in patients with and without facial asymmetry - a three-dimensional analysis with computed tomography. *Int J Oral Maxillofac Surg* 2006; 35: 43-8.
13. Baek SH, Cho IS, Chang YI, Kim MJ. Skeletodental factors affecting chin point deviation in female patients with class III malocclusion and facial asymmetry: a three-dimensional analysis using computed tomography. *Oral Surg Oral Med Oral Pathol Oral Radiol Endod* 2007; 104: 628-39.
14. Jung YJ, Kim MJ, Baek SH. Hard and soft tissue changes after correction of mandibular prognathism and facial asymmetry by mandibular setback surgery: three-dimensional analysis using computerized tomography. *Oral Surg Oral Med Oral Pathol Oral Radiol Endod* 2009; 107: 763-71.
15. You KH, Lee KJ, Lee SH, Baik HS. Three-dimensional computed tomography analysis of mandibular morphology in patients with facial asymmetry and mandibular prognathism. *Am J Orthod Dentofacial Orthop* 2010; 138: 540.e1-8.
16. Kim EJ, Palomo JM, Kim SS, Lim HJ, Lee KM, Hwang HS.

- Maxillofacial characteristics affecting chin deviation between mandibular retrusion and prognathism patients. *Angle Orthod* 2011; 81: 988-93.
17. Yoon KW, Yoon SJ, Kang BC, Kim YH, Kook MS, Lee JS, et al. Deviation of landmarks in accordance with methods of establishing reference planes in three-dimensional facial CT evaluation. *Imaging Sci Dent* 2014; 44: 207-12.
 18. Yoon SJ, Wang RF, Hwang HS, Kang BC, Lee JS, Palomo JM. Application of spherical coordinate system to facial asymmetry analysis in mandibular prognathism patients. *Imaging Sci Dent* 2011; 41: 95-100.
 19. Baek C, Paeng JY, Lee JS, Hong J. Morphologic evaluation and classification of facial asymmetry using 3-dimensional computed tomography. *J Oral Maxillofac Surg* 2012; 70: 1161-9.
 20. Kim TY, Baik JS, Park JY, Chae HS, Huh KH, Choi SC. Determination of midsagittal plane for evaluation of facial asymmetry using three-dimensional computed tomography. *Imaging Sci Dent* 2011; 41: 79-84.
 21. Kim SJ, Lee KJ, Lee SH, Baik HS. Morphologic relationship between the cranial base and the mandible in patients with facial asymmetry and mandibular prognathism. *Am J Orthod Dentofacial Orthop* 2013; 144: 330-40.
 22. Jensen SR, Kirby J. Absent innominate (oblique orbital) line as a normal variant. *J Comput Assist Tomogr* 1980; 4: 553-4.
 23. Chong VF, Fan YF, Tng CH. Pictorial review: radiology of the sphenoid bone. *Clin Radiol* 1998; 53: 882-93.