

# Fusobacterium Septicemia with Liver and Lung Abscesses Due to Diverticulitis

Akshay Sharma, MD<sup>1</sup>, Sachin Goyal, MD<sup>2</sup>, Camelia Arsene, MD, PhD, MHS<sup>1</sup>,  
Geetha Krishnamoorthy, MD<sup>1</sup>, and Murray Ehrinpreis, MD<sup>2</sup>

<sup>1</sup>Department of Internal Medicine, Sinai Grace Hospital, Detroit Medical Center/Wayne State University, Detroit, MI

<sup>2</sup>Department of Internal Medicine, Division of Gastroenterology, Detroit Medical Center/Wayne State University, Detroit, MI

## ABSTRACT

The *Fusobacterium* species is known for its association with septic thrombophlebitis of the internal jugular vein (Lemierre's syndrome). Lemierre's syndrome is associated with septic emboli to the liver and lungs, often causing multiple abscesses. We present a unique case of *Fusobacterium* septicemia in which the bacteria invaded the portal vein through the gastrointestinal mucosa due to diverticulitis and spread hematogenously to the liver and lungs, causing abscesses. It was treated successfully with 6 weeks of antibiotics. Physicians should be aware of this rare pathogen and suspect its presence in severe pharyngitis or culture-negative liver abscess.

## INTRODUCTION

*Fusobacterium* species is an obligate anaerobe residing in the oropharyngeal and gastrointestinal (GI) mucosa. Until recently, it was thought to be a rare cause of serious infections in humans.<sup>1</sup> It is known to cause Lemierre's syndrome, which is characterized by an oropharyngeal infection followed by septic thrombophlebitis of the internal jugular vein with embolization to different organs, including lungs and liver.<sup>2</sup> Although *Fusobacterium* infection originating in the GI tract is rare and seldom reported, it can invade the GI mucosa and cause bacteremia with fatal complications.<sup>3-5</sup>

## CASE REPORT

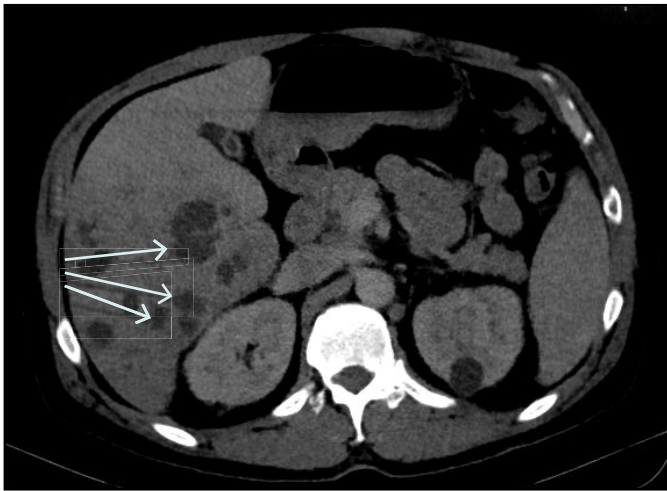
A 52-year-old man with a past medical history of hypertension and hidradenitis suppurativa presented with productive cough, chills, diarrhea, and decreased appetite for 1 week. Physical exam was significant for blood pressure 99/58 mm Hg, heart rate 100 beats/min, respiratory rate 20 breaths/min, and temperature 39.1°C. His head, neck, and throat examination was completely benign, with no lymphadenopathy, neck swelling/tenderness, tonsillar enlargement, or exudates. Abdominal examination revealed mild tenderness in the right upper quadrant without any peritoneal signs. Murphy's sign was negative. He had normal bowel sounds in all quadrants. Auscultation of the lungs revealed coarse crackles over the right lung base that did not disappear with deep breaths. Skin examination revealed purulent drainage from 2 tender, fluctuant masses 2-3 cm in diameter in the left and right axillary regions. His laboratory tests revealed neutrophilic leukocytosis  $17.2 \times 10^9/L$  with 12% bands. Lactic acid level was 3.5 mg/dL. Chest radiograph was normal. Blood cultures were obtained, and the patient was started on intravenous ceftriaxone, doxycycline, and metronidazole to address the possible right lower lobe pneumonia as well as the axillary abscesses. Incision and drainage of the abscesses was performed, but anaerobic culture and Gram stain were negative. Streptococcal pneumonia antigen, legionella urine antigen, mycoplasma antibody IgM, polymerase chain reaction for influenza A, B, and RSV, and DNA amplification for *Clostridium difficile* came back negative. Blood cultures were positive for *Fusobacterium* species on day 5 of admission. The patient was

ACG Case Rep J 2018;5:e99. doi:10.14309/crj.2018.99. Published online: December 19, 2018.

Correspondence: Akshay Sharma, MD, 4201 Antoine St, Ste 2E, Detroit, MI 48201 (g.akshaysharma@gmail.com).

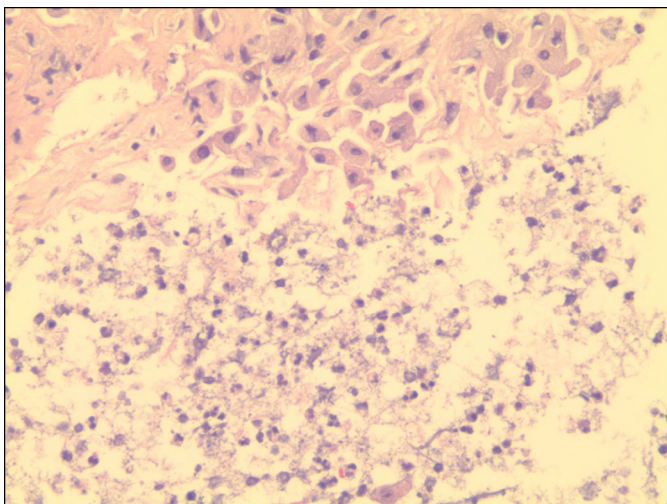


Copyright: © 2018 Sharma et al. This work is licensed under a Creative Commons Attribution-NonCommercial-NoDerivatives 4.0 International License. To view a copy of this license, visit <http://creativecommons.org/licenses/by-nc-nd/4.0>.

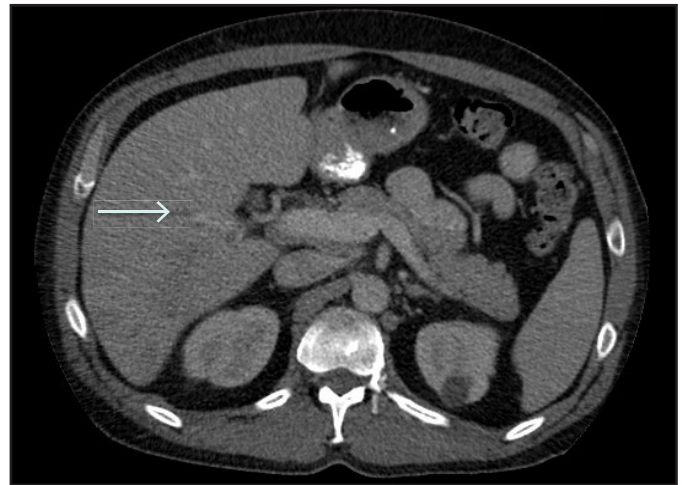


**Figure 1.** Contrast-enhanced abdominal computed tomography (CT) showing multiple liver abscesses.

switched to ceftriaxone and clindamycin, but he continued to have persistent fever and tachycardia. Due to the persistent mild right upper quadrant abdominal pain, he underwent abdominal ultrasound, which showed a liver with heterogeneous texture suspicious for abscesses. Abdominal computed tomography (CT) demonstrated diverticulitis involving the distal descending and proximal sigmoid colon along with multiple liver abscesses and a lung abscess (Figure 1). A CT-guided liver fine-needle aspiration core biopsy showed portal triaditis and findings consistent with liver abscess with a negative culture (Figure 2). It showed no signs of malignancy. The patient was switched to ampicillin-sulbactam, which was continued for 6 weeks as he showed clinical improvement. Repeat CT of abdomen in 3 weeks showed that the abscesses were nearly resolved (Figure 3).



**Figure 2.** Hematoxylin and eosin stain of a cell block section of a liver abscess showing benign hepatocytes, associated numerous neutrophils, and degenerated hepatocytes (200 $\times$ ).



**Figure 3.** Contrast-enhanced abdominal CT after 3 weeks of treatment with ampicillin-sulbactam showing resolution of liver abscesses.

The patient underwent a follow-up colonoscopy, which was negative for polyps or malignancy.

## DISCUSSION

Fusobacteria are anaerobic, nonsporulating, Gram-negative bacilli that exhibit pleomorphism as well as irregular staining.<sup>6</sup> *F. nucleatum* is the most common source of infection, while *F. necrophorum* is the most virulent species.<sup>7</sup> In one study, the incidence of such infections was estimated to be as low as 5.5 cases per million population per annum.<sup>8</sup> It has, however, recently been found to cause pharyngitis more commonly than streptococcus in young adults.<sup>9</sup> Its prevalence had declined considerably since the advent of antibiotics, but it has been on the rise again for the past 20 years.<sup>10</sup> One of the proposed explanations for this is the conservative use of antibiotics in the last 2 decades, during which time multiple cases of Lemierre's syndrome have been reported. This disease has several complications, such as osteomyelitis, meningitis, and acute respiratory distress syndrome.<sup>11</sup> Mortality was extremely high (90-100%) in the preantibiotic era but has diminished with the advent of antibiotics.<sup>11</sup>

Even though *Fusobacterium* most commonly causes bacteremia through the oropharynx and internal jugular vein, recent literature has shown that it can readily invade the GI mucosa as well and cause suppurative thrombophlebitis of the portal vein (pylphlebitis) in the setting of an inflammatory process in the gut.<sup>3</sup> Our case adds to this evidence and demonstrates how it can also cause septic emboli in the liver and lungs through the portal vein, similar to conventional Lemierre's syndrome, in which the site of infection is typically the oropharynx and involves the internal jugular vein. Antibiotics have improved survival from *Fusobacterium* infection.

However, mortality is still quite high (10–15%), as presented in other recent case reports.<sup>3</sup>

Another case of *Fusobacterium* septicemia and liver abscess was recently reported in which the source was found to be colorectal cancer.<sup>4</sup> Recent literature has also shown an increased risk of colorectal cancer in patients with bacteremia from *Fusobacterium nucleatum*.<sup>12</sup> *Fusobacterium* infection is difficult to diagnose because it is a fastidious organism that is difficult to culture and lacks pathognomonic symptoms. *Fusobacterium* may be resistant to penicillin, and there is widespread resistance to erythromycin and other macrolides.<sup>11</sup> It is treated with ampicillin-sulbactam, piperacillin tazobactam, metronidazole, or clindamycin.<sup>11</sup>

*Fusobacterium* can invade the GI mucosa due to an underlying pathology and cause sepsis with potentially fatal complications like liver and lung abscess. However, it can be successfully treated with early recognition and appropriate antibiotic treatment as illustrated by our case. *Fusobacterium* is a rare cause of liver abscess, and infection can occur by hematogenous seeding not only from the internal jugular vein secondary to tonsillar abscess, but also through the portal vein secondary to an underlying pathology of the gut. It is difficult to culture and therefore should be considered as an etiology in culture-negative liver abscess. *Fusobacterium* infection should be suspected in patients with severe exudative pharyngitis and culture-negative abscesses of the liver or lung. In cases of *Fusobacterium* septicemia in which the source of infection is unclear, a thorough investigation for an intra-abdominal pathology should be done, including a colonoscopy to rule out colorectal cancer as the cause of bacteremia.

## DISCLOSURES

Author contributions: All authors contributed equally to the writing and editing of the manuscript. G. Krishnamoorthy is the article guarantor.

Financial disclosure: None.

Informed consent was obtained for this case report.

Received March 8, 2018; Accepted October 29, 2018

## REFERENCES

1. Huggan PJ, Murdoch DR. Fusobacterial infections: clinical spectrum and incidence of invasive disease. *J Infection*. 2008;57(4):283–89.
2. Ianniello F, Ferri E, Pinzani A. [Septic thrombophlebitis of the internal jugular vein due to *Fusobacterium necrophorum* (Lemierre's syndrome): Case report and review of literature]. *Acta Otorhinolaryngol Ital*. 1998;18(5):332–37.
3. Mellor TE, Mitchell N, Logan J. Lemierre's syndrome variant of the gut. *BMJ Case Rep*. 2017;20:2017.
4. Garcia Carretero R, Lopez-Lomba M, Vazquez-Gomez O, Rodriguez-Maya B. Bacteraemia and liver abscess due to *Fusobacterium necrophorum*. *BMJ Case Rep*. 2017;27:2017.
5. Yamamoto E, Fukae T, Kawai Y, et al. Case of *Fusobacterium necrophorum* sepsis (Lemierre's syndrome) with pulmonary septic emboli and liver abscess. *Nihon Rinsho Meneki Gakkai Kaishi*. 2011;34(5):431–37.
6. Langworth BF. *Fusobacterium necrophorum*: Its characteristics and role as an animal pathogen. *Bacteriol Rev*. 1977;41(2):373–90.
7. Cheung WY, Bellas J. *Fusobacterium*: Elusive cause of life-threatening septic thromboembolism. *Can Fam Physician*. 2007;53(9):1451–53.
8. Afra K, Laupland K, Leal J, Lloyd T, Gregson D. Incidence, risk factors, and outcomes of *Fusobacterium* species bacteremia. *BMC Infect Dis*. 2013;13:264.
9. Centor RM, Atkinson TP, Ratliff AE, et al. The clinical presentation of *Fusobacterium*-positive and streptococcal-positive pharyngitis in a university health clinic: A cross-sectional study. *Ann Internal Med*. 2015;162(4):241–47.
10. Karkos PD, Asrani S, Karkos CD, et al. Lemierre's syndrome: A systematic review. *Laryngoscope*. 2009;119(8):1552–59.
11. Johannesen KM, Bodtger U. Lemierre's syndrome: current perspectives on diagnosis and management. *Infect Drug Resist*. 2016;9:221–7.
12. Kwong TNY, Wang X, Nakatsu G, et al. Association between bacteremia from specific microbes and subsequent diagnosis of colorectal cancer. *Gastroenterology*. 2018;155(2):383–90.