



# Unusual Hybrid Closure of Ventricular Septal Defects

World Journal for Pediatric and  
Congenital Heart Surgery  
2020, Vol. 11(4) NP158-NP160  
© The Author(s) 2018  
Article reuse guidelines:  
sagepub.com/journals-permissions  
DOI: 10.1177/2150135118768724  
journals.sagepub.com/home/pch



Thomas Krasemann, MD(D)<sup>1</sup>, Ingrid van Beynum, MD<sup>1</sup>,  
and Pieter van de Woestijne, MD<sup>2</sup>

## Abstract

A planned combined perventricular and “open heart” surgical closure of multiple ventricular septal defects had to be modified intraoperatively due to a technical fault disabling echocardiographic guidance. Through an atriotomy, device closure of a muscular defect and patch closure of a perimembranous ventricular septal defect were performed. In unusual situations, collaboration of the surgical and interventional team is crucial.

## Keywords

ventricular septal defect, device, congenital heart surgery, cardiac catheterization/intervention

Submitted January 08, 2018; Accepted March 07, 2018.

## Introduction

Perventricular closure of ventricular septal defects has been described for muscular ventricular septal defects.<sup>1</sup> For perimembranous ventricular septal defects, perventricular closure has been associated with a relatively high risk of heart block.<sup>2</sup> We describe a case of concomitant patch closure of a perimembranous ventricular septal defect and device closure of a muscular ventricular septal defect, both through an atriotomy. We had originally planned to first accomplish perventricular device closure of the muscular defect and then approach the perimembranous defect via the right atrium. But due to a technical fault in the echocardiography equipment, we had to change our approach intraoperatively.

## Case Report

A five-year-old boy with multiple ventricular septal defects underwent initial pulmonary arterial banding at the age of two months. Over time, the ventricular septal defects showed no tendency to reduce in size. There was one large perimembranous ventricular septal defect and a large muscular ventricular septal defect (8-9 mm) situated apically with respect to the moderator band (Figure 1). In addition, a smaller muscular ventricular septal defect of approximately 2 mm was seen more apically. We had planned to close the muscular ventricular septal defects perventricularly under epicardial echocardiographic guidance and then, during the same anesthesia, to go on bypass to close the perimembranous ventricular septal defect and perform debanding of the pulmonary artery. We

considered the risk of heart block to be too high to attempt device closure of the perimembranous ventricular septal defect.

A repeat median sternotomy was performed and epicardial echocardiography started, as the optimal puncture site on the right ventricular surface can be determined more easily by epicardial echocardiography than by transesophageal echocardiography. Epicardial echocardiography failed due to a technical problem, which could not be resolved. Imaging did not provide any gray scales, and hence, the image quality was less than adequate. All other echo machines were in use in other theaters. We decided to continue the procedure by commencing cardiopulmonary bypass support and anticipated inspection of the entire interventricular septum through the tricuspid valve.

Cardiopulmonary bypass was started with mild hypothermia and cardioplegic arrest. Through a right atriotomy, part of a large ventricular septal defect could be seen under the moderator band (Figure 2). A 7F Terumo sheath, in which a 12-mm Amplatzer muscular VSD occluder (AGA Medical Corporation, Golden Valley, Minnesota) was preloaded, was carefully advanced through the ventricular septal defect under direct

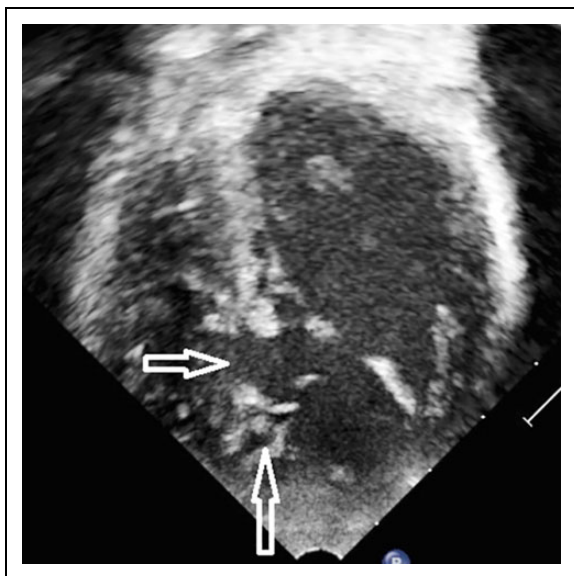
<sup>1</sup> Department of Paediatric Cardiology, Sophia Kinderziekenhuis, Erasmus Medical Centre Rotterdam, Rotterdam, the Netherlands

<sup>2</sup> Department of Cardiothoracic Surgery, Erasmus Medical Centre Rotterdam, Rotterdam, the Netherlands

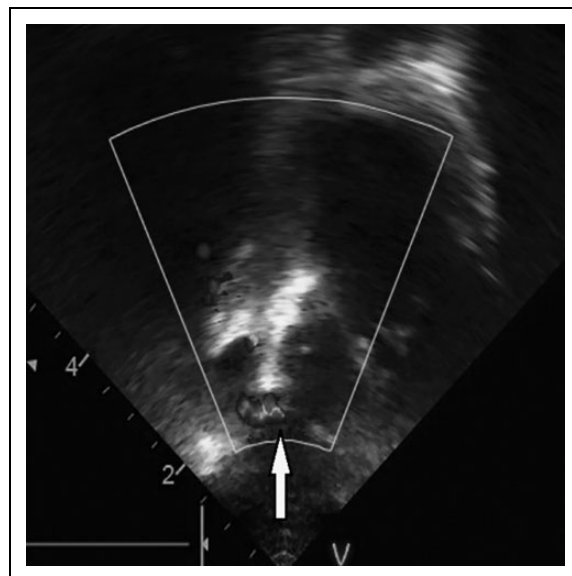
## Corresponding Author:

Thomas Krasemann, Department of Paediatric Cardiology, Sophia Kinderziekenhuis, Erasmus Medical Centre Rotterdam, Wytemaweg 80, 3015 CN Rotterdam, the Netherlands.

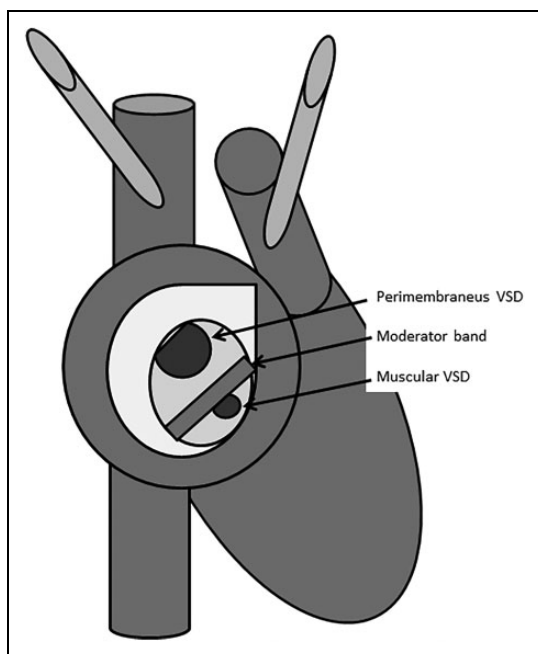
Email: t.krasemann@erasmusmc.nl



**Figure 1.** Echocardiography, modified apical four-chamber view: Anteriorly positioned muscular ventricular septal defect located apically in relation to the moderator band and measuring 8.5 mm (horizontal arrow) and small apical ventricular septal defect (vertical arrow).



**Figure 3.** Postoperative echocardiography (modified apical four-chamber view): Device in situ, on color Doppler, small more apical ventricular septal defect visible (arrow).



**Figure 2.** Sketch of intraoperative view of ventricular septal defect position.

vision. The left ventricular disk was then deployed and the whole system carefully withdrawn until resistance was felt. The remainder of the device was deployed. A wiggle maneuver confirmed secure position. With a single stitch, the device was further secured within the interventricular septum. The smaller more apical ventricular septal defect could not be visualized within the trabeculations of the right ventricle. It was felt safe to leave this alone. The perimembranous ventricular septal

defect was then closed with a polytetrafluoroethylene (PTFE) patch. After debanding of the pulmonary artery, the main pulmonary trunk was closed with patch augmentation. Weaning from bypass was uneventful, and the heart was in sinus rhythm.

Transesophageal and transthoracic echocardiography postoperatively in the intensive care unit (with a different echo machine) confirmed complete closure of the perimembranous ventricular septal defect and good device position with complete occlusion of the large muscular ventricular septal defect. On discharge echocardiography four days after the procedure, the smaller muscular ventricular septal defect could still be seen, with color flow Doppler imaging (Figure 3). After a further uneventful postoperative course, the child was sent home on the sixth postoperative day on aspirin.

**Comment**

Changes in the approach during an operation may become necessary. In our case, a technical fault led to a bailout strategy with intraoperative device closure of a muscular ventricular septal defect under direct vision instead of the planned perventricular approach. Collaboration of the surgical and interventional team in such situations is crucial. As an alternative strategy, we had considered closure of the perimembranous defect operatively and percutaneous closure of the muscular ventricular septal defects in a separate procedure. But the combined team conferred and arrived at a decision to close both defects operatively, relying on direct vision for device placement and deployment.

While surgical management after unsuccessful or complicated device treatment has been described,<sup>1,3</sup> our case demonstrates that primary device closure can be performed intraoperatively. Visualization of some important intracardiac

structures, such as mitral valve chordae, was not possible through the right atrial approach, even with the heart emptied on bypass. Without echocardiographic guidance, there may be a risk of mitral valve damage. From the preoperatively acquired images, we considered it safe to proceed, as the chordae inserted more laterally.

Our approach allowed us to spare the child from requiring more than one episode of general anesthesia. The small residual apical ventricular septal defect did not have hemodynamic significance and was left alone.

## Conclusion

In selected cases, intraoperative “direct vision” device closure of muscular ventricular septal defects can be considered.


## Declaration of Conflicting Interests

The author(s) declared no potential conflicts of interest with respect to the research, authorship, and/or publication of this article.

## Funding

The author(s) received no financial support for the research, authorship, and/or publication of this article.

## ORCID iD

Thomas Krasemann  <https://orcid.org/0000-0003-4900-1576>

## References

1. Holzer RJ, Sallehuddin A, Hijazi ZM. Surgical strategies and novel alternatives for the closure of ventricular septal defects. *Expert Rev Cardiovasc Ther.* 2016;14(7): 831-841.
2. Ou-Yang WB, Wang SZ, Hu SS, et al. Periventricular device closure of perimembranous ventricular septal defect: effectiveness of symmetric and asymmetric occluders. *Eur J Cardiothorac Surg.* 2017;51(3): 478-482.
3. Karimi M, Hulsebus E, Murdison K, Wiles H. A case of hybrid closure of a muscular ventricular septal defect: anatomical complexity and surgical management. *Cardiol Young.* 2012;22(3): 356-359.