

Fatal Empyema Thoracis Caused by *Nocardia otitidiscaviarum*

Qianqian Gu*, Lingren Zhou*, Xiaofei Shen, Le Xu, Guixian Wu, Weijia Pan, Wenxia Lin, Dongqing Lv, Ling Lin, Shuangquan Yan

Department of Respiratory Medicine, Taizhou Hospital of Zhejiang Province Affiliated to Wenzhou Medical University, Taizhou, 317000, People's Republic of China

*These authors contributed equally to this work

Correspondence: Ling Lin; Shuangquan Yan, Hospital of Zhejiang Province affiliated to Wenzhou Medical University, 150 Ximen Street, Taizhou, 317000, People's Republic of China, Email Linling@enzemed.com; ysq25908712@163.com

Abstract: Nocardiosis caused by *Nocardia otitidiscaviarum* is exceptionally rare and characterized by a high mortality rate. It typically affects immunocompromised patients, resulting in severe pulmonary or disseminated infections, and is notorious for abscess formation. Empyema resulting from nocardiosis is even less common. Early clinical signs and imaging findings lack specificity, culture growth is sluggish, and the absence of an effective serological detection method can delay treatment. We report an 81-year-old patient with chronic obstructive pulmonary disease treated by long-term inhalation of high-dose salmeterol fluticasone. The initial empirical anti-infection treatment proved ineffective, resulting in rapid disease progression before the confirmation of nocardiosis with empyema through cultures of pleural fluid and sputum. Despite active treatment measures, the patient succumbed to severe pulmonary infection, sepsis, and multiple organ failure. A review of the literature, together with clinical experience, indicates that conventional empirical treatment for *Nocardia otitidiscaviarum* infection may not always be effective due to the escalating rate of drug resistance. Therefore, the primary step in the management of the infection is timely diagnosis using different methods. Furthermore, the identification of the responsible strain followed by conducting drug sensitivity tests is paramount for the successful treatment of this disease.

Keywords: severe nocardia pneumonia, empyema, drug resistance rate, drug sensitivity test

Introduction

Nocardia species are Gram-positive bacteria belonging to the aerobic actinomycetes. It is positive on acid-fast staining and is commonly found in dust, sand, soil, and stagnant water. Nocardiosis can occur either after the inhalation of pathogen-containing aerosols into the respiratory tract or through traumatic infection. This condition usually affects the lungs of immunocompromised patients, resulting in opportunistic or disseminated infections,¹ although cases have also been reported in individuals with normal immune function.^{2,3} While pulmonary nocardiosis accounts for 70% of all nocardiosis cases,⁴ other organs, such as the abdominal organs and the central nervous system, can also be affected.⁵ The brain is frequently involved, where infection results in conditions such as brain abscesses and cerebral aneurysm, usually the consequence of hematogenous dissemination. A rarer manifestation is the subcutaneous disease known as actinomycetoma, caused by direct inoculation of the skin.⁶

It has been reported that the annual incidence of *Nocardia* infection in the USA ranges from about 500 to 1000 cases.⁷ A Canadian study reported a significant annual growth trend in the disease, which escalated from 0.33 cases per 100000 residents during 1997–1998 to 0.87 cases during 2007–2008 ($P < 0.001$).⁸ This increase may be due to both increasing numbers of immunocompromised individuals and improved detection and identification of *Nocardia* species by clinical microbiology laboratories. Despite the annual surge in infections by *Nocardia* species, nocardiosis resulting from infection with *N. otitidiscaviarum* is relatively uncommon.⁶ This pathogen was first identified in the ears of infected Sumatran guinea pigs by Snijders in 1924,⁹ and the first human infection was reported in 1974.^{10,11} *Nocardia*

otitidiscaviarum is responsible for approximately 3–5% of all *Nocardia* infections.^{11,12} A study conducted in the USA revealed that only 2.9% (10 out of 347) of *Nocardia* infections in guinea pigs were caused by *N. otitidiscaviarum*.⁹ Similarly, a multicenter study conducted in Taiwan between 1998 and 2009 found that 5.7% of the 138 clinical isolates of *Nocardia* species were positive for *N. otitidiscaviarum*.¹³ This low incidence is likely due to its reduced pathogenicity or low prevalence in the soil¹⁴. The mortality rate associated with *N. otitidiscaviarum* is approximately 50%.¹⁵

Case Description

The patient, an 81-year-old male Chinese farmer, had a 20-year history of chronic obstructive pulmonary disease (COPD). In the past, he had smoked 1.5 packs of cigarettes for 37 years but had been a non-smoker for the previous 30 years. Over the previous three years, he had been hospitalized at our facility for acute exacerbations of COPD (AECOPD), averaging 1–3 hospitalizations per year. The patient had been on a regimen of salmeterol fluticasone 50 µg/500 µg, 1 inhalation twice daily, and tiotropium bromide inhalation once daily for an extended period, with his symptoms remaining manageable.

The patient had experienced cough, expectoration, chest tightness, and shortness of breath for about four days before admission but reported no chills, fever, chest pain, or hemoptysis. He had received anti-infection treatment at a local clinic (specifics of the diagnosis and treatment are unknown), but after four days of medication, his symptoms showed minimal improvement, leading to his admission to our hospital.

There was no evidence of fever during his hospitalization. Lung auscultation revealed scattered wet rales, and there was mild edema in both lower extremities. Laboratory results (detailed in Table 1) included a blood gas analysis indicating an oxygenation index of 372 mmHg. Blood tests showed elevated white blood cell (WBC) and neutrophil counts ($11.6 \times 10^9/L$), with an absolute lymphocyte value of $0.3 \times 10^9/L$ and a C-reactive protein (CRP) level of 123.11 mg/L. Blood biochemistry highlighted hypoproteinemia (25.9 g/L), IgE at 209.4 IU/mL, and reduced cortisol levels. Chest computed tomography (CT) scan shows a small amount of pleural effusion on both sides (Figure 1), multiple nodules in the upper lobe of the left lung (Figure 1A and B), and the middle lobe of the right lung (Figure 1C).

The patient received successive piperacillin tazobactam, fluconazole, and methylprednisolone injections but his cough and expectoration persisted. His condition improved after switching to oral itraconazole capsules for fungal treatment, leading to his discharge. However, three days after discharge, he presented with bloody sputum, worsened chest tightness, shortness of breath, and left chest and rib pain, necessitating readmission.

Table 1 Results of Laboratory Examinations

		Upon Admission	Second Hospitalization	When The Disease Progresses
Blood gas analysis	pH	7.44	7.48	7.32
	PaO ₂	108 mmHg	72 mmHg	83 mmHg
	PaCO ₂	47 mmHg	45 mmHg	49 mmHg
	Oxygen concentration	29	29	50
	Oxygenation index	372 mmHg	248 mmHg	166 mmHg
Routine blood test	WBC	$12.0 \times 10^9/L$	$21.4 \times 10^9/L$	$21.8 \times 10^9/L$
	Absolute neutrophil count	$11.6 \times 10^9/L$	$20.9 \times 10^9/L$	$21.6 \times 10^9/L$
	Neutrophil ratio	96.80%	97.8%	99%
	Absolute lymphocyte count	$0.3 \times 10^9/L$	$0.2 \times 10^9/L$	$0.1 \times 10^9/L$
	PLT	$263 \times 10^9/L$	$146 \times 10^9/L$	$102 \times 10^9/L$
	CRP	123.11 mg/L	198.3 mg/L	290.9 mg/L
	PCT	–	1.74 ng/mL	11.22 ng/mL
Blood biochemistry	albumin	25.9 g/l	22.3 g/l	20.5 g/l
	K	2.9 mmol/L	4.38 mmol/l	5.32 mmol/l
	Cr	61 µmol/l	63 µmol/l	191 µmol/l
	Nt-proBNP	579 pg/mL	958 pg/mL	2884 pg/mL

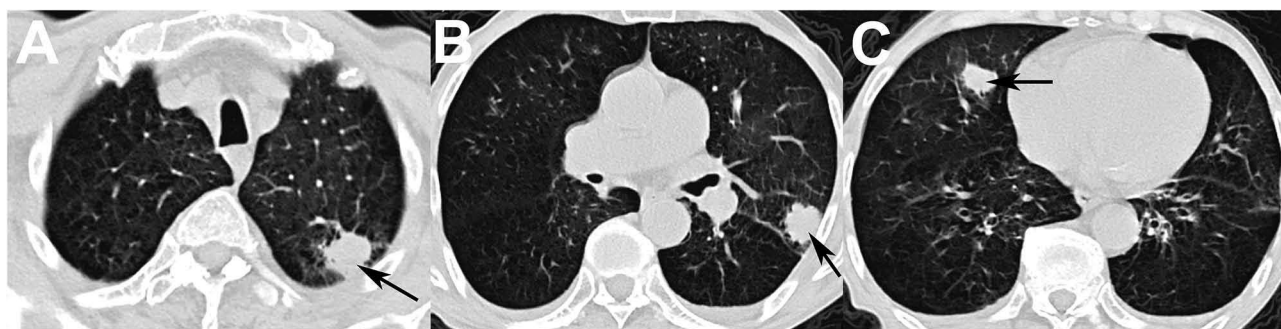

Figure 1 (A): Nodule in the upper lobe of the left lung (black arrow), showing blurred boundaries with slight pleural effusion on the left side. (B): Left upper lung subpleural nodule (black arrow), diameter 2.2 cm, with visible lobulation and limited pleural effusion on both sides. (C): Nodule in the middle lobe of the right lung (black arrow), with small amount of pleural effusion on both sides and bronchiectasis in both lower lungs.

His body temperature was normal on admission, with scattered dry and wet rales audible in both lungs. Laboratory tests revealed a reduced oxygenation index (248 mmHg), elevated WBC and neutrophil counts ($20.9 \times 10^9/L$), a reduced lymphocyte count ($0.2 \times 10^9/L$), a CRP level of 198.3 mg/L, a procalcitonin (PCT) level of 1.74 ng/mL, and hypoproteinemia (22.3 g/l). He was then treated with cefoperazone sulbactam and voriconazole injections.

Four weeks later, enhanced chest CT scans indicated worsening of the lung lesions and a significant increase in the pleural effusion in the left lung (Figure 2), together with multiple patchy high-density shadows in both lungs (Figure 2) and partial cavity formation (Figure 2A–C). A thoracic drain was placed in the patient, yielding a purulent reddish-brown fluid (Figure 3), later confirmed as empyema. Sputum cultures isolated *Pseudomonas aeruginosa*.

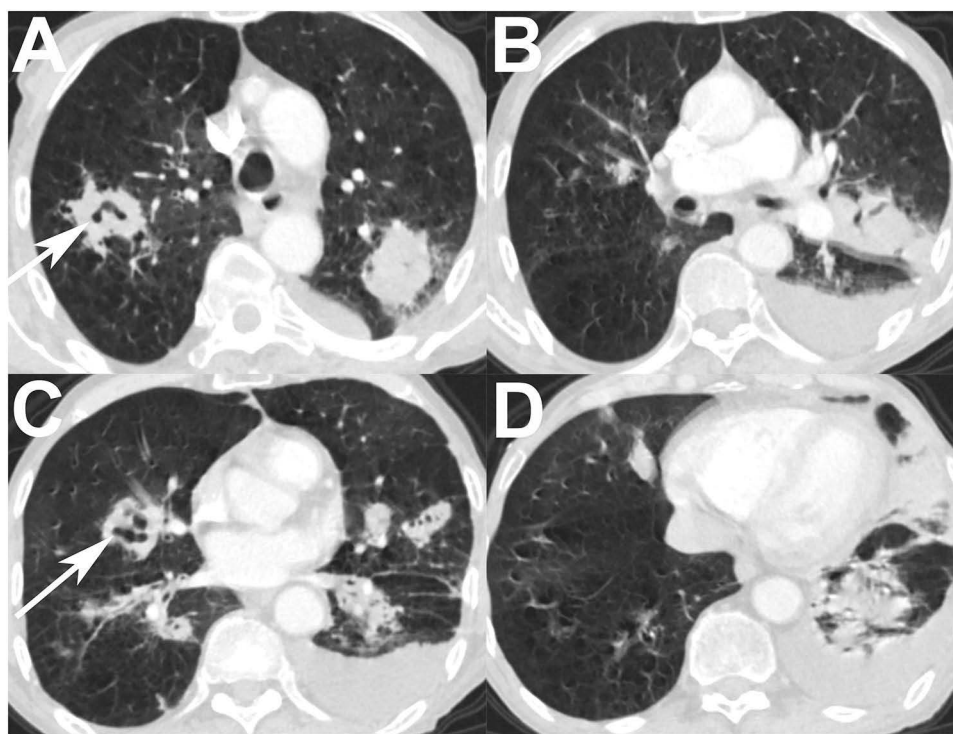


Figure 2 (A): CT image of the lung window shows patchy high-density shadows in both upper lobes, the formation of a thick-walled cavity in the upper right lobe (white arrow), and pleural effusion on the left side. (B): CT image of the lung window shows an increase in the mass shadow adjacent to the left pulmonary hilum relative to the previous scan, accompanied by an increase in the left pleural effusion, relative to the previous scan. (C): CT image of the lung window shows multiple patchy high-density shadows in both lungs, with some cavity formation (white arrows) and uneven thickening of the walls. (D): CT image of the lung window shows consolidation in the left lingual lobe and lower left lobe, together with an increase in pleural effusion on the left side relative to the previous scan.

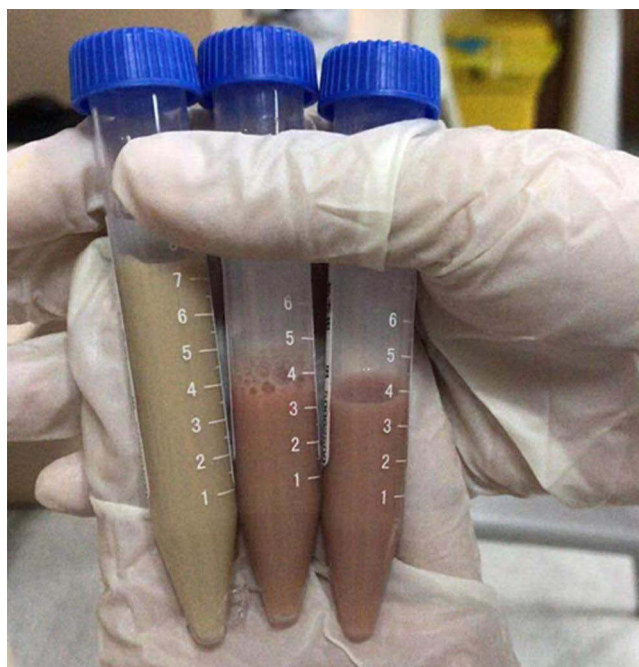

Figure 3 Appearance of the pleural effusion, showing purulence and a reddish-brown color.

The patient's condition deteriorated over the next few days, with increased chest tightness, shortness of breath, and fatigue. Despite the addition of methylprednisolone and meropenem, together with noninvasive ventilator support, his condition continued to decline. The laboratory results indicated further deterioration, with a reduced oxygenation index (166 mmHg), worsening blood counts, and signs of multi-organ dysfunction. Gram staining of sputum smears showed positive bacilli (Figure 4A) and acid-fast-bacterial staining showed weak positivity (Figure 4B). Finally, after culture on Columbia blood agar medium, the VITEK test[®] and mass spectrometry identified the *Nocardia otitidiscaviarum* (Figure 4C). The pleural fluid also tested positive for *N. otitidiscaviarum*. The patient was thus diagnosed with severe *N. otitidiscaviarum* infection and sepsis, and was treated with linezolid, ciprofloxacin, Sulfamethoxazole, and nutritional support. Despite these measures, his condition deteriorated rapidly.

Three days later, the patient's dyspnea had worsened, and a bedside chest X-ray revealed a left hydropneumothorax, compressing approximately 30% of the left lung. He was transferred to the ICU suffering from multiple organ failure, including respiratory, cardiac, hepatic, and renal failure, together with disseminated intravascular coagulation, septic shock, and secondary thrombocytopenia. Despite aggressive treatments including mechanical ventilation, continuous renal replacement therapy (CRRT), fluid resuscitation, and multiple drug therapies, the patient, unfortunately, succumbed to the illness two weeks after diagnosis.

Discussion

Nocardia is an opportunistic pathogen that typically infects individuals with compromised immune systems. These include patients with malignant tumors and hematological malignancies, HIV infections, those undergoing long-term corticosteroid therapy, organ transplant recipients, and hematopoietic stem cell transplant recipients.^{9,16} A study from Pakistan reported the diagnosis of 55 cases of pneumonia caused by *Nocardia* species infection at a tertiary hospital over the past decade, 23.6% of whom (13 out of 55) suffered from COPD.¹⁷ The primary risk factor identified was prolonged steroid therapy.

The patient in the current report had a history of COPD, together with prolonged use of inhaled hormones and a 37-year history of smoking. These factors may have reduced his immune defenses, rendering him vulnerable to *N. otitidiscaviarum* infection. As a farmer with frequent contact with the soil, his risk of infection may have been further elevated. Furthermore, *Nocardia* can colonize the lungs, particularly in individuals with alterations in the lung

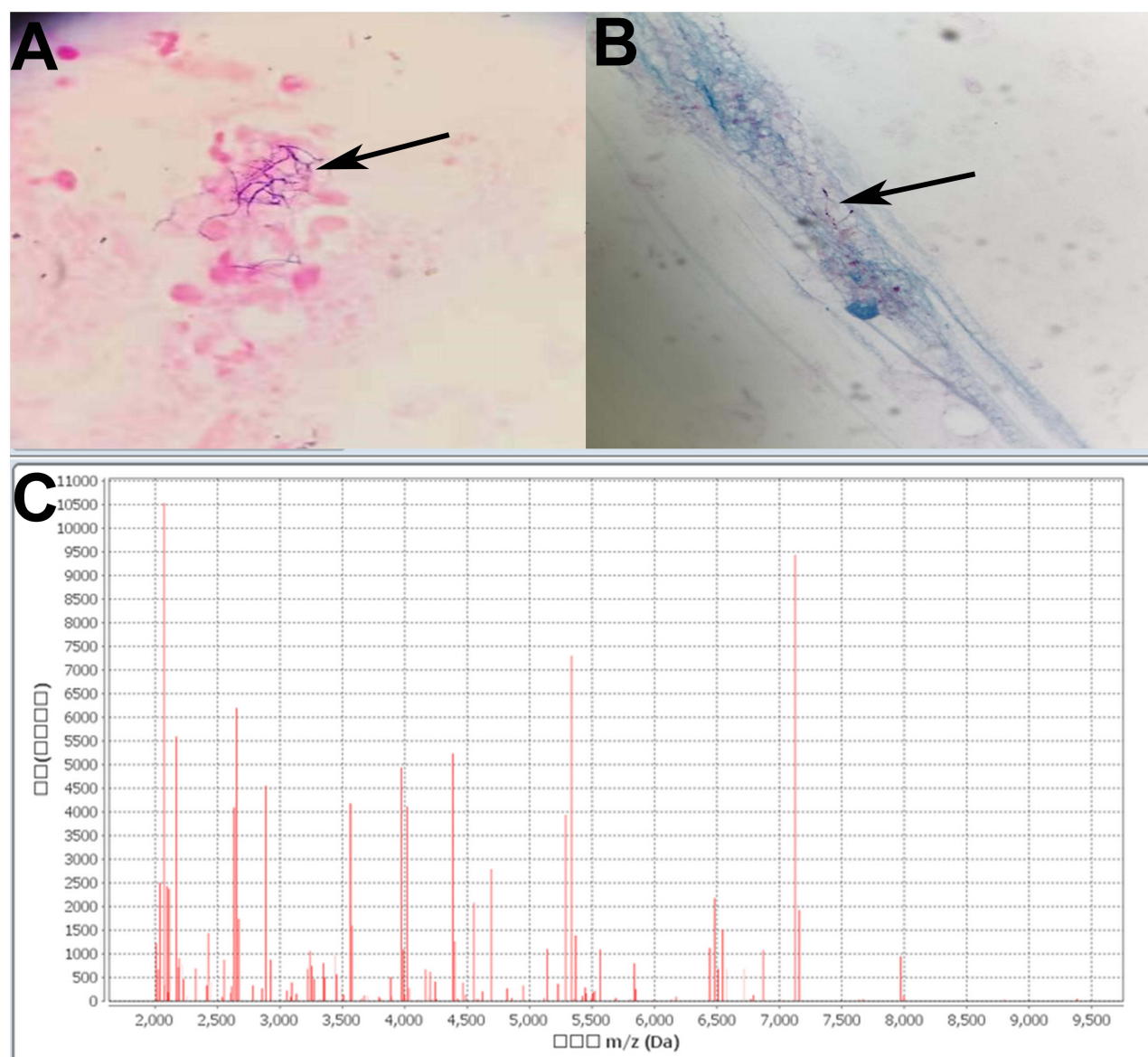


Figure 4 (A): Smear cultures of sputum specimens, showing their appearance as clusters of filamentous Gram-positive bacteria (indicated by arrows) with bead-like bacterial cells under oil microscopy (10 * 100x). (B): Weak acid-fast-bacteria positivity of the sputum specimen with filamentous bacteria (indicated by the arrow) under oil microscopy (10 * 100x). (C): Identification of the pathogen as *Nocardia otitidiscaviarum* by mass spectrometry using a VITEK® system.

structure due to COPD and bronchiectasis.^{18,19} Such colonization is frequently reported in the literature. Structural alterations in the lungs, together with reduced bronchial defense ability,²⁰ and genetic susceptibility, contribute to *Nocardia* infections even in immunocompetent individuals. Studies by Casanova et al indicated an association between disease susceptibility and the genetic background of the host, shown by consistent infection rates between identical and fraternal twins. These findings underscore the complex interplay between human and environmental factors in determining immunity to infection.^{21,22}

A search of the PubMed database identified only six cases of *Nocardia otitidiscaviarum* empyema/empyema thoracis published between January 2004 and January 2024 (Table 2), thus confirming the rarity of *N. otitidiscaviarum* infection with pleural effusion. Including the present case, the ages of the patients ranged from 38 to 86 years, with an average age of 66 ± 18.43 years. Two patients were female and five were male. Among the patients, two had a history of COPD complicated by hypertension (one of these patients also had coronary heart disease), one suffered from rheumatoid vasculitis and steroid-induced diabetes, two had chronic liver disease (one with inflammatory arthritis and one with

Table 2 Details of Six Cases of Empyema Caused by Infection with *Nocardia Otitidiscaviarum* Reported in the Literature from January 2004 to January 2024

Author, Year	Age (Years)	Gender	Underlying Disease	Other Site Involved	Clinical Classification ^a	Imaging Feature	Drug Sensitivity Results	Treatment	Treatment Time	Steroid Use ^b	Clinical Outcome
Yoshida et al ²³ 2004	69	M	Rheumatoid vasculitis, SDM	None	Acute	Pleural effusion	R: AMP, PIP, CZ, CTM, CMZ, Flomoxef, IPM, MINO, VA I: EM, TMP-SMX S: GM, LVFX	IPM/CS, MINO, TMP-SMX→LVFX, GM, TMP-SMX	6M	Long term	Survived
Pelaez et al ²⁴ 2009	85	F	COPD, hypertension, coronary disease	Brain	Acute	Multiple pulmonary nodules, pleural effusion	R: PG, AM, VA, EM S: IPM, LND, TMP/SMX, GM, AMK, CIP	TMP/SMZ, IPM→LND +TMP/SMZ	1M	Long term	Died
Chen et al ²⁵ 2013	61	M	CLD, DM	None	Acute	NA	NA	NA	NA	NA	Died
Chung-Hao Huang ¹⁵ 2015	42	M	CLD inflammatory arthritis of bilateral knees	None	Subacute	Infiltration changes, pleural effusion	ND	PTZ, VA→CIP→Meropenem, TMP-SMZ, AMK→TMP-SMZ	>5M	Long term	Survived
Rahul Ranjan ²⁶ 2024	38	M	HLH/ITP, HIV	Sepsis	Acute	Cavity, consolidation, pleural effusion	S: AMK, LND, LVFXR: AMP, CRO, IPM, TMP-SMZ, EM, TC	PTZ, CD, fluconazole →TMP-SMZ, LVFX, AMK	40D	Long term	Died
I S Pérez Ramos ²⁷ 2024	86	F	Arterial hypertension and chronic thromboembolism secondary to severe pulmonary hypertension	None	Acute	Cavity, solid mass, pleural effusion	S: TMP/SMZ, AMK, LND R: IPM, AMC, CRO	TMP/SMZ, LND→Tedizolid	1Y	NO	Survived
Present case	81	M	COPD, hypertension	Sepsis	Subacute	Cavity, solid mass, pleural effusion	ND	PTZ, fluconazole →Itraconazole→CFP/SU, Voriconazole→MP, LND, CIP, TMP-SMZ	1.5M	NO	Died

Notes: ^a Acute (less than 2 weeks), subacute (2 weeks to 3 months), chronic (exceeding 3 months).^{9,28} ^b Long term: steroid use for at least 2 weeks.

diabetes), one had HIV coinfecting with hemophagocytic lymphohistiocytosis (HLH)/thrombotic thrombocytopenic purpura (TTP), and one had arterial hypertension with chronic thromboembolism resulting from severe pulmonary hypertension. Notably, all four patients who received glucocorticoid treatment had compromised immune function. One patient, despite being healthy, had a history of long-term inhaled hormone therapy. Another case exhibited disseminated infection with brain abscess, while two cases involved mixed bacterial infections. The outcomes varied, with three patients surviving and four succumbing, a mortality rate of 57%, consistent with previous reports. In terms of onset, five cases were acute and two were subacute. The prognosis for patients with acute or subacute disease is typically poor. Acute infections caused by *Nocardia* species usually affect individuals with severe immune dysfunction and are often associated with an unfavorable prognosis.

The clinical symptoms of nocardiosis caused by *N. otitidiscaviarum* tend to be non-specific, mirroring those of a wide range of pulmonary infectious diseases, and including fever, cough, yellow sputum, shortness of breath, dyspnea, and chest pain. The lung imaging manifestations are diverse, and include solid mass-like lesions resembling tumors and infiltrative shadows similar to those caused by tuberculosis. In immunosuppressed patients, cavitary lesions may form.^{2,29} Pleural lesions can manifest as pleural effusion, pleural thickening, and erosion of the chest wall. The incidence of pleural effusion ranges from 10–36%,^{6,30,31} although this incidence is lower for empyema resulting from *N. otitidiscaviarum* infection.

As shown in Table 2, all six published cases presented with pleural effusion, with one case showing effusion, another exhibiting multiple nodules in both lungs, and three featuring consolidation accompanied by cavities and masses. The imaging features may change over the course of the disease in the same patient, necessitating differentiation from bacterial pneumonia, invasive pulmonary fungal disease, pulmonary tuberculosis, non-tuberculous mycobacterial infection, actinomycosis, vascular inflammatory lesions, tumors, and other conditions.

The present case showed multiple clumps in the middle lobe of the right lung, the upper lobe of the left lung, and the left hilar region during the early stage of the disease. The initial empirical anti-infection treatment proved ineffective. The clumps increased in volume as the disease progressed, presenting as solid masses with exudation at the lesion edges, some cavities, and pleural effusion. These imaging findings align with those of the published reports. Hence, when nocardiosis is suspected, culture of the pleural effusion is of utmost importance.

Apart from the nonspecific and relatively rare clinical and imaging manifestations associated with *N. otitidiscaviarum* infection, culture of the pathogen is slow, taking anywhere from two days to several weeks, and requiring up to 2–3 weeks of culture in Petri dishes.³² This poses a significant challenge to early diagnosis and can lead to delayed or missed diagnoses. In the present case, during the first hospitalization, the symptoms and imaging manifestations were atypical, leading to a missed diagnosis. Misdiagnosis, delayed diagnosis, or inappropriate treatment of nocardiosis can have potentially fatal outcomes.³³

As shown in the retrospective analysis in Table 2, among the seven patients, four underwent drug sensitivity tests. The results indicated that two cases were sensitive to sulfamethoxazole (SMZ), while one case showed intermediate sensitivity and one case was resistant. Three cases were resistant to imipenem while one was sensitive, four cases were resistant to penicillin but sensitive to aminoglycosides, and three cases were sensitive to linezolid while resistant to cephalosporins. Previous reports have suggested that *N. otitidiscaviarum* has low sensitivity to β -lactam antibiotics,³⁴ which aligns with the findings shown in the table. This may explain the initial failure of the empirical anti-infection treatment in the present case. However, given *Nocardia*'s slow growth rate, waiting for the results of drug sensitivity tests may not be feasible for severely ill patients. The key to effective drug selection lies in the identification of the *Nocardia* species and strain. According to the literature report,³⁵ *Nocardia otitidiscaviarum* is sensitive to SMZ up to 87% and linezolid up to 100%. In this case of an elderly patient infected with *N. otitidiscaviarum*, it was believed, based on experience, that the strain would be sensitive to SMZ, linezolid, and ciprofloxacin. However, the patient was already at the stage of severe sepsis at the time of treatment and unfortunately could not be saved, which is indeed regrettable. Factors such as the patient's age, disease severity, comorbidities, and delays in initiating effective antimicrobial therapy can all contribute to adverse outcomes. According to the available literature, resistance to trimethoprim-sulfamethoxazole has been observed,^{36,37} with notably high resistance to trimethoprim (TMP)-SMZ in the USA (42%).³⁸ Despite confirmation of *N. otitidiscaviarum* infection in the present case, the disease progressed rapidly even with conventional

antibiotic treatment. This underscores the importance of analyzing strain-specific drug sensitivity, in addition to confirmation of the diagnosis. In the absence of drug sensitivity data, clinicians should consider the severity of the disease, the epidemiological likelihood of a specific species as the responsible pathogen, and potential drug resistance when selecting antibiotics. Once the species and susceptibilities are known, the treatment approach can be more targeted. The unfortunate aspect of the present case was the failure to conduct timely drug sensitivity testing to guide clinical decision-making.

Conclusions

The case presented here underscores the rapid progression of *Nocardia otitidiscaviarum* infection in patients with COPD and compromised lung function. Early identification of this disease is paramount; otherwise, treatment options may become unviable. The CT imaging findings of multiple plaques, masses, consolidations, and cavity shadows, especially together with pleural effusion and blood biochemistry suggestive of hypoalbuminemia, indicate the possibility of infection by *Nocardia* species. To facilitate diagnosis and significantly expedite the treatment process, the prompt acquisition of sufficient culture samples, including sputum, pleural fluid, cerebrospinal fluid, lung puncture samples, and bronchoalveolar lung fluid, etc, is imperative. Additionally, metagenomic next-generation sequencing (mNGS) of the body fluids of critically ill patients can assist significantly in the diagnosis of these diseases. Given the slow growth rate of *Nocardia*, often leading to its being overlooked in standard cultures, laboratories should maintain Petri dishes for extended cultivation. Furthermore, bacterial identification and drug sensitivity testing are essential to guide the selection of suitable antibiotics and ensure effective patient treatment.

Data Sharing Statement

The datasets used and analyzed during the current study available from the corresponding author on reasonable request.

Ethics Approval and Informed Consent

The study obtained the approval of the ethics committee of Taizhou Hospital of Zhejiang Province affiliated to Wenzhou Medical University (approval number: K20240831 (EZ)). The ethics committee approved the waiver in this case report, based on the ethical standards to publish the case details. Written consent to participate was provided by the patient's son for the present research.

Consent for Publication

Written informed consent was obtained from the legal guardian/next of kin for the publication without any potentially identifiable images or data included in this article.

Funding

This work was supported by the Medical and Health Plan Project of Zhejiang Province of China (2022KY445), the Basic Public Welfare Project of Zhejiang Province of China (LTGY23H010007), the Scientific Research Fund Project of Taizhou Enze Medical Center (Group) (2021EZZDC01) and the Scientific Research Fund of Taizhou Science and Technology Agency (24ywb71).

Disclosure

The authors report no conflicts of interest in this work.

References

1. Provost F, Laurent F, Uzcategui LR, Boiron P. Molecular study of persistence of *Nocardia asteroides* and *Nocardia otitidiscaviarum* strains in patients with long-term nocardiosis. *J Clin Microbiol.* 1997;35(5):1157–1160. doi:10.1128/jcm.35.5.1157-1160.1997
2. Yanwen J, Aiben H, Qihong F. Disseminated nocardiosis caused by *Nocardia otitidiscaviarum* in an immunocompetent host: a case report and literature review. *Exp Ther Med.* 2016;12(5):3339–3346. doi:10.3892/etm.2016.3755
3. Ramamoorthi K, Pruthvi BC, Rao NR, Belle J, Chawla K. Pulmonary nocardiosis due to *Nocardia otitidiscaviarum* in an immunocompetent host—a rare case report. *Asian Pac J Trop Med.* 2011;4(5):414–416. doi:10.1016/S1995-7645(11)60116-8

4. Das AK, Nandy S, Dudeja M, Tiwari R, Alam S. The incidence of nocardiosis at pulmonary and extra - pulmonary sites. *J Clin Diagn Res.* 2013;7(7):1427–1429. doi:10.7860/JCDR/2013/5177.3152
5. Shahapur PR, Peerapur BV, Shahapur RP, Honnutagi RM, Biradar MS. Lymphocutaneous nocardiosis caused by *Nocardia otitidiscaviarum*: a case report and review of literature. *J Nat Sci Biol Med.* 2014;5(1):197–201. doi:10.4103/0976-9668.127328
6. Hui CH, Au VW, Rowland K, Slavotinek JP, Gordon DL. Pulmonary nocardiosis re-visited: experience of 35 patients at diagnosis. *Respir Med.* 2003;97(6):709–717. doi:10.1053/rmed.2003.1505
7. Aidê M, Lourenço S, Marchiori E, Zanetti G, Mondino P. Nocardiose pulmonar em portador de doença pulmonar obstrutiva crônica e bronquiectasias. *J Bras Pneumol.* 2008;34(11):985–988. doi:10.1590/S1806-37132008001100016
8. Tremblay J, Thibert L, Alarie I, Valiquette L, Pépin J. Nocardiosis in Quebec, Canada, 1988–2008. *Clin Microbiol Infect.* 2011;17(5):690–696. doi:10.1111/j.1469-0691.2010.03306.x
9. Brown-Elliott BA, Brown JM, Conville PS, Wallace RJ Jr. Clinical and laboratory features of the *Nocardia* spp. based on current molecular taxonomy. *Clin Microbiol Rev.* 2006;19(2):259–282. doi:10.1128/CMR.19.2.259-282.2006
10. Causey WA, Arnell P, Brinker J. Systemic *Nocardia caviae* infection. *Chest.* 1974;65(3):360–362. doi:10.1378/chest.65.3.360
11. Beaman BL, Burnside J, Edwards B, Causey W. Nocardial infections in the United States, 1972–1974. *J Infect Dis.* 1976;134(3):286–289. doi:10.1093/infdis/134.3.286
12. Saubolle MA, Sussland D. Nocardiosis: review of clinical and laboratory experience. *J Clin Microbiol.* 2003;41(10):4497–4501. doi:10.1128/JCM.41.10.4497-4501.2003
13. Lai CC, Liu WL, Ko WC, et al. Antimicrobial-resistant nocardia isolates, Taiwan, 1998–2009. *Clin Infect Dis.* 2011;52(6):833–835. doi:10.1093/cid/ciq255
14. Durán E, López L, Martínez A, Comuñas F, Boiron P, Rubio MC. Primary brain abscess with *Nocardia otitidiscaviarum* in an intravenous drug abuser. *J Med Microbiol.* 2001;50(1):101–103. doi:10.1099/0022-1317-50-1-101
15. Huang CH, Hsueh PR, Chen YH. Empyema thoracis due to *Nocardia otitidiscaviarum*. *J Microbiol Immunol Infect.* 2015;48(5):580–581. doi:10.1016/j.jmii.2014.05.004
16. Hémar V, Danjean MP, Imbert Y, Rispal P. Retrospective analysis of nocardiosis in a general hospital from 1998 to 2017. *Med Mal Infect.* 2018;48(8):516–525. doi:10.1016/j.medmal.2018.06.004
17. Zia K, Nafees T, Faizan M, et al. Ten year review of pulmonary nocardiosis: a series of 55 cases. *Cureus.* 2019;11(5):e4759. doi:10.7759/cureus.4759
18. Minero MV, Marín M, Cercenado E, Rabadán PM, Bouza E, Muñoz P. Nocardiosis at the turn of the century. *Medicine.* 2009;88(4):250–261. doi:10.1097/MD.0b013e3181afa1c8
19. Rodríguez-Nava V, Zoropoguy A, Laurent F, et al. La nocardiose, une maladie en expansion Nocardiosis, an expanding disease. *Antibiotiques.* 2008;10(3):115–127. doi:10.1016/j.antib.2008.06.002
20. Ader F, Nseir S, Le Berre R, et al. Invasive pulmonary aspergillosis in chronic obstructive pulmonary disease: an emerging fungal pathogen. *Clin Microbiol Infect.* 2005;11:427–429. doi:10.1111/j.1469-0691.2005.01143.x
21. Picard C, Casanova JL, Abel L. Mendelian traits that confer predisposition or resistance to specific infections in humans. *Curr Opin Immunol.* 2006;18(4):383–390. doi:10.1016/j.coi.2006.05.005
22. Casanova JL, Abel L. Inborn errors of immunity to infection: the rule rather than the exception. *J Exp Med.* 2005;202(2):197–201. doi:10.1084/jem.20050854
23. Yoshida K, Bandoh S, Fujita J, Tokuda M, Negayama K, Ishida T. Pyothorax caused by *Nocardia otitidiscaviarum* in a patient with rheumatoid vasculitis. *Intern Med.* 2004;43(7):615–619. doi:10.2169/internalmedicine.43.615
24. Peláez AI, García-Suárez Mdel M, Manteca A, et al. A fatal case of *Nocardia otitidiscaviarum* pulmonary infection and brain abscess: taxonomic characterization by molecular techniques. *Ann Clin Microbiol Antimicrob.* 2009;8(1):11. doi:10.1186/1476-0711-8-11
25. Chen YC, Lee CH, Chien CC, Chao TL, Lin WC, Liu JW. Pulmonary nocardiosis in southern Taiwan. *J Microbiol Immunol Infect.* 2013;46(6):441–447. doi:10.1016/j.jmii.2012.07.017
26. Ranjan R, Bir R, Gunasekaran J, Yadav VS, Gupta RM. A fatal case of multidrug-resistant pleural nocardiosis by *Nocardia otitidiscaviarum* in an immunosuppressed patient: a case report and literature review. *Cureus.* 2024;16(1):e52071. doi:10.7759/cureus.52071
27. Pérez Ramos IS, Gurruchaga Yanes ML, Fernández Vecilla D, Oiarzabal Elorriaga U, Unzaga Barañano MJ, Díaz de Tuesta Del Arco JL. Cavitory pneumonia and empyema thoracis caused by multidrug resistant *Nocardia otitidiscaviarum* in an elderly patient. *Rev Esp Quimioter.* 2024;37(1):97–99. doi:10.37201/req/042.2023
28. Lerner PI. Nocardiosis. *Clin Infect Dis.* 1996;22(6):891–903. doi:10.1093/clinids/22.6.891
29. Mahgoub A, Gumaa SA, Joseph MR, et al. Pulmonary nocardiosis caused by *Nocardia otitidiscaviarum* in an adult asthmatic female patient: the presence of acid-fast branching filaments is always significant. *S Afr Med J.* 2016;107(1):43–45. doi:10.7196/SAMJ.2017.v107i1.12006
30. Blackmon KN, Ravenel JG, Gomez JM, Ciolino J, Wray DW. Pulmonary nocardiosis: computed tomography features at diagnosis. *J Thorac Imaging.* 2011;26(3):224–229. doi:10.1097/RTI.0b013e3181f45dd5
31. Husain S, McCurry K, Dauber J, Singh N, Kusne S. Nocardia infection in lung transplant recipients. *J Heart Lung Transplant.* 2002;21(3):354–359. doi:10.1016/S1053-2498(01)00394-1
32. Rouzaud C, Rodríguez-Nava V, Catherinot E, et al. Clinical assessment of a *Nocardia* PCR-based assay for diagnosis of nocardiosis. *J Clin Microbiol.* 2018;56(6):e00002–e00018. doi:10.1128/JCM.00002-18
33. Martínez R, Reyes S, Menéndez R. Pulmonary nocardiosis: risk factors, clinical features, diagnosis and prognosis. *Curr Opin Pulm Med.* 2008;14(3):219–227. doi:10.1097/MCP.0b013e3282f85dd3
34. Zhang W, Peng GJ, Liu J, Hu H, Liang H. Identification of rare *Nocardia otitidiscaviarum* and its drug sensitivity analysis. *Int J Lab Med.* 2014;35:1320–1325.
35. Hamdi AM, Fida M, Deml SM, et al. Retrospective analysis of antimicrobial susceptibility profiles of nocardia species from a tertiary hospital and reference laboratory, 2011 to 2017. *Antimicrob Agents Chemother.* 2020;64(3):e01868–19. doi:10.1128/AAC.01868-19
36. Sakkena R, Rynga D, Rajan S, et al. Fatal pulmonary infection by trimethoprim-sulfamethoxazole resistant *Nocardia otitidiscaviarum*: report of two cases and review. *J Infect Dev Ctries.* 2020;29(14):214–222. doi:10.3855/jidc.10169

37. Clark NM, Braun DK, Pasternak A, Chenoweth CE. Primary cutaneous *Nocardia otitidiscaviarum* infection: case report and review. *Clin Infect Dis*. 1995;20(5):1266–1270. doi:10.1093/clinids/20.5.1266
38. Uhde KB, Pathak S, McCullum I Jr, et al. Antimicrobial-resistant *Nocardia* isolates, United States, 1995–2004. *Clin Infect Dis*. 2010;51(12):1445–1448. doi:10.1086/657399

Infection and Drug Resistance

Publish your work in this journal

Infection and Drug Resistance is an international, peer-reviewed open-access journal that focuses on the optimal treatment of infection (bacterial, fungal and viral) and the development and institution of preventive strategies to minimize the development and spread of resistance. The journal is specifically concerned with the epidemiology of antibiotic resistance and the mechanisms of resistance development and diffusion in both hospitals and the community. The manuscript management system is completely online and includes a very quick and fair peer-review system, which is all easy to use. Visit <http://www.dovepress.com/testimonials.php> to read real quotes from published authors.

Submit your manuscript here: <https://www.dovepress.com/infection-and-drug-resistance-journal>

Dovepress

Taylor & Francis Group