

Article

Prognostic Value of Perineural Invasion on Survival and Recurrence in Oral Squamous Cell Carcinoma

Steffen Spoerl ^{1,†}, Silvia Spoerl ^{2,†}, Stephanie Reil ¹, Michael Gerken ³, Nils Ludwig ¹, Juergen Taxis ¹, René Fischer ⁴, Tobias Ettl ¹, Torsten E. Reichert ¹ and Gerrit Spanier ^{1,*}

¹ Department of Cranio-Maxillofacial Surgery, University Hospital Regensburg, 93053 Regensburg, Germany; steffen.spoerl@ukr.de (S.S.); stephi.reil@web.de (S.R.); nils.ludwig@ukr.de (N.L.); juergen.taxis@ukr.de (J.T.); tobias.ettl@ukr.de (T.E.); torsten.reichert@ukr.de (T.E.R.)

² Department of Internal Medicine 5—Hematology/Oncology, Friedrich-Alexander University Erlangen-Nürnberg, 91054 Erlangen, Germany; silvia.spoerl@uk-erlangen.de

³ Tumor Center, Institute for Quality Management and Health Services Research, University of Regensburg, 93053 Regensburg, Germany; michael.gerken@ukr.de

⁴ Department of Otorhinolaryngology, University Hospital Regensburg, 93053 Regensburg, Germany; rene.fischer@ukr.de

* Correspondence: gerrit.spanier@ukr.de

† These authors contributed equally to this work.



Citation: Spoerl, S.; Spoerl, S.; Reil, S.; Gerken, M.; Ludwig, N.; Taxis, J.; Fischer, R.; Ettl, T.; Reichert, T.E.; Spanier, G. Prognostic Value of Perineural Invasion on Survival and Recurrence in Oral Squamous Cell Carcinoma. *Diagnostics* **2022**, *12*, 1062. <https://doi.org/10.3390/diagnostics12051062>

Academic Editors: Maciej Misiolek and Joanna Katarzyna Strzelczyk

Received: 30 March 2022

Accepted: 21 April 2022

Published: 24 April 2022

Publisher's Note: MDPI stays neutral with regard to jurisdictional claims in published maps and institutional affiliations.



Copyright: © 2022 by the authors. Licensee MDPI, Basel, Switzerland. This article is an open access article distributed under the terms and conditions of the Creative Commons Attribution (CC BY) license (<https://creativecommons.org/licenses/by/4.0/>).

Abstract: A diagnosis of perineural invasion (PNI) is widely accepted as an unfavorable prognostic factor in various solid malignancies. Although PNI has been described as a high-risk parameter in oral squamous cell carcinoma (OSCC), its role in the current staging manuals of the American Joint Committee on Cancer (AJCC) is rather subordinate. We analysed the prognostic value of PNI on survival and recurrence in a large, multicenter OSCC cohort and a population-based approach. A total of 493 OSCC patients with primary tumor resection to negative margins and concomitant neck dissection between 2010 and 2017 were enrolled. PNI was evaluated in relation to overall survival (OAS) and recurrence-free survival (RFS) using uni- and multi-variable Cox regression. The median follow-up time was 5.0 years and PNI was diagnosed in 48 patients (9.7%). A pathohistological verification of PNI correlated significantly with a deteriorated OAS in uni- (HR 2.312; 95% CI 2.312–3.493, $p = 0.001$) and multivariable Cox regression (HR 1.820; 95% CI 1.164–2.847, $p = 0.009$). Additionally, a diagnosis of PNI correlated with increased cumulative, as well as distant, metastasis 5-year-recurrence rates ($p = 0.027$ and $p = 0.011$, respectively). The application of adjuvant radiotherapy (RT) or radiochemotherapy (RCT) in patients with PNI did not alter OAS or RFS in survival analysis when compared to patients without PNI. The results underline the adverse impact of PNI on the survival and recurrence of surgically treated OSCC patients. Based on our findings, we highly recommend an emphasis on PNI in the TNM staging concept.

Keywords: oral squamous cell carcinoma; oral cancer; PNI; perineural invasion; survival; recurrence

1. Introduction

Despite the tremendous efforts of the recent decade aiming to ameliorate the outcome of patients suffering from oral squamous cell carcinoma (OSCC), survival rates are still regrettably low [1]. Certainly, the clinical application of immunotherapeutic approaches in the recent years has resulted in promising courses of disease—at least for a selected proportion of OSCC patients [2]. Among the many oncological hallmarks of solid malignancies, and particularly with regards to OSCC, metastasis and invasive growth are major challenges for surgical treatment [3]. Tumor size, anatomical site, and infiltration pattern determine the involvement and invasion of locoregional nerves due to a high anatomical density of these structures in the oral cavity and in the head and neck region, in general. For a tumor entity explicitly characterized as neurotropic [4,5], it is not surprising that

perineural invasion (PNI) is commonly observed in OSCC [3]. When it comes to assessing outcomes in OSCC patients with a pathohistological verification of PNI, survival was fundamentally decreased in comparison to patients with an absence of PNI [6].

Since the first description of PNI by Cruveilhier in 1835 [7], numerous authors have characterized the phenomenon of tumor cells invading adjacent structures. The overall tenor of most studies explicitly considers tumors with pathohistological verified PNI as more aggressive, with a consecutively higher chance of adverse patient outcomes [8,9]. Although the exact molecular and cellular mechanisms of PNI are not entirely clear, recent studies have focused on the microenvironment closely located to neural structures. In the classic concept, PNI was considered as a mainly cancer-driven nerve infiltration directly through the path of least resistance in the perineural space. This process includes a broad orchestra of different cell types and soluble, as well as non-soluble, factors [10–12]. However, more recent findings suggest that PNI requires reciprocal signaling interactions between tumor cells and nerve components, particularly Schwann cells. Specifically, OSCC can express neurotrophins and neurotrophin receptors that may contribute to cancer cell migration towards nerves, PNI, and neuritogenesis towards cancer. Schwann cells may play an important role in promoting PNI by migrating towards cancer cells, intercalating, and dispersing cancer, and facilitating cancer migration towards nerves [12].

Although PNI was correlated with various adverse cancer properties [4], its precise impact on prognosis in OSCC is not entirely clear [4]. Additionally, this topic is particularly relevant for the indication of adjuvant treatment modalities. We therefore evaluated the role of PNI in OSCC patients, focusing on therapeutic implications.

2. Materials and Methods

2.1. Patient Selection

This retrospective, multicenter cohort study comprises patients with newly diagnosed OSCC and surgical treatment between January 2010 and December 2017. All participants were residing in the region of Eastern Bavaria, which represents a German population of around 2.3 million people, and includes the districts of Upper Palatinate and Lower Bavaria. The population-based dataset was kindly provided by the Clinical Cancer Registry of the Tumor Center Regensburg. Diagnostic workup and treatment took place at three different centers: the Department of Cranio-Maxillofacial Surgery, as well as the Department of Otorhinolaryngology, both at the University Hospital Regensburg, and the Department of Otorhinolaryngology at the St. Elisabeth Hospital Straubing.

All included patients received resection of the primary lesion to negative margins based on clinical and radiologic examination. The standard surgical approach was transoral. In cases where this technique did not offer adequate exposure, temporary mandibulotomy and pull-through resection were applied. No robotic surgery was used in the three above-mentioned centers. In addition to the different types of oral defect reconstruction, a diligent elective/selective neck dissection was performed in each patient. Previous neck dissection, primary radio(-chemo)therapy of head and neck squamous cell carcinoma, or neoadjuvant treatment modalities were the exclusion criteria.

Consecutively, 493 patients were included in the present study. Staging was carried out in line with the “TNM classification of malignant tumors” by the *Union Internationale Contre le Cancer* (UICC) in its 7th edition [13]. Adjuvant treatment was based on the recommendation of the multidisciplinary tumor board, and radiotherapy or radio-chemotherapy was used accordingly. Patient-specific demographic, pathohistological, and clinical data were obtained from medical records, and included gender, age at diagnosis, positive anamnesis of nicotine and alcohol abuse, anatomical site, extranodal spread, grading, and application of adjuvant therapies. With consideration of comorbidities and age on survival of OSCC patients, the age-adjusted Charlson Comorbidity Index (ACCI) was calculated as previously described and without taking OSCC into account [14,15]. Recurrent disease was either diagnosed by radiologic evidence with clinical correlation or histologic confirmation by biopsy. Survival follow up data concerning recurrence-free survival (RFS) and overall

survival (OAS) were gathered from medical records, death certificates, registration offices, and the Clinical Cancer Registry of the Tumor Center—Institute for Quality Management and Health Services Research, University of Regensburg. PNI was diagnosed if routine pathohistological examination of primary surgical specimen by an experienced pathologist showed a tumor in ultimate proximity to a nerve which is surrounded by the malignancy by at least one third circumference or penetrates at least one of three connective tissue layers of the nerve [16]. The cut-off date for this study was set at 31 March 2021.

2.2. Statistics

Continuous data are described as means, median, minimum, and maximum values. Categorical data are given as absolute frequencies and relative percentages. Patient characteristics were compared using the two-tailed Student's *t* test for continuous data, in the case of normal distribution; otherwise, the Mann–Whitney *U* test was applied. Pearson's Chi-square test was used for testing independence between categorical variables.

Recurrences were derived from clinical reports and were analyzed in detail, where local, locoregional relapse, as well as formation of distant metastases, were evaluated. Five-year-survival rates for OAS and RFS, as well as cumulative recurrence rates, were analyzed from the date of resection until the first event. Patients' OAS and RFS were calculated with the Kaplan–Meier method. The follow-up period and survival times were right censored using 31 March 2021 as the cut-off date, rendering a median follow-up of 5.0 years (4.7 years for the PNI-group). Differences in survival outcomes were tested for statistical significance by the two-sided log rank test (Mantel–Cox), and the level of significance was set at 0.05. Besides univariable survival analysis, we additionally performed multivariable Cox regression to adjust for covariables.

Before setting up a multivariable model, multicollinearity among prognostic variables was checked by using the variance inflation factor (VIF), which measures the correlation between the predictor variables in a linear regression model. Besides the pathohistological diagnosis of PNI, we additionally adjusted for gender, ACCI, history of smoking and alcohol abuse, distinct tumor localizations, UICC stage, grading, lymph vessel invasion, and vein invasion. The variables were consecutively incorporated in multivariable analyses if *p*-values of univariable analysis were less than 0.100.

ACCI was categorized in three groups, reflecting increased age at diagnosis and comorbidities. Hazard ratios (HR) and corresponding 95% confidence intervals (CI) were estimated and considered statistically significant when the CI excluded 1.0, and a two-sided *p*-value was <0.05. All analyses were performed by using IBM SPSS Statistics, version 26.0 (IBM Corp., SPSS for Windows, Armonk, NY, USA).

3. Results

Here, we report on the results of a retrospective multicenter cohort study on 493 OSCC patients who had resection to negative margins combined with an elective neck dissection. The prevalence of PNI at the time of diagnosis was 9.7% (48 patients). Patient characteristics of the entire retrospective cohort, including demographic and clinical parameters, are provided in Table 1. Most patients were male (70.6%), and most patients had an age of between 50 and 69.9 years at the date of tumor resection (66.9%). Most patients displayed an ACCI of >0 (91.7%), with 240 patients (48.7%) presenting an ACCI of ≥ 3 . The majority of patients additionally presented a history of alcohol abuse (67.7%), as well as nicotine abuse (73.8%). The predominant tumor localizations were the floor of mouth (36.7%), as well as the tongue (30.0%). The majority of tumors were staged as pT1 (38.7%) and pT2 (31.8); however, 190 patients (38.6%) had already presented cervical lymph node metastasis at the day of tumor resection (pN+). In summary, UICC stage IV could be diagnosed in 187 patients (37.9%). In 42.2% of patients, an adjuvant treatment was applied.

Table 1. Clinicopathological characteristics of OSCC patients according to the diagnosis of PNI ($n = 445$).

Category Group		Perineural Invasion						χ^2 <i>p</i>
		Pn0		Pn1		Total		
		N	(%)	N	(%)	N	(%)	
Gender	Female	133	29.9%	12	25.0%	145	29.4%	0.480
	Male	312	70.1%	36	75.0%	348	70.6%	
Age at diagnosis	<50	48	10.8%	5	10.4%	53	10.8%	0.983
	50.0–59.9	156	35.1%	17	35.4%	173	35.1%	
	60.0–69.9	143	32.1%	14	29.2%	157	31.8%	
	70.0–79.9	77	17.3%	9	18.8%	86	17.4%	
	80.0+	21	4.7%	3	6.3%	24	4.9%	
Age-adjusted CCI	0	36	8.1%	5	10.4%	41	8.3%	0.724
	1 and 2	190	42.7%	22	45.8%	212	43.0%	
	3+	219	49.2%	21	43.8%	240	48.7%	
Positive anmnesis smoking	No	119	26.7%	10	20.8%	129	26.2%	0.376
	Yes	326	73.3%	38	79.2%	364	73.8%	
Positive anmnesis alcohol	No	146	32.8%	13	27.1%	159	32.3%	0.420
	Yes	299	67.2%	35	72.9%	334	67.7%	
Anatomical tumor site	Buccal mucosa	33	7.4%	1	2.1%	34	6.9%	0.332
	Upper alveolus and gingiva	19	4.3%	1	2.1%	20	4.1%	
	Lower alveolus and gingiva	71	16.0%	5	10.4%	76	15.4%	
	Hard palate	32	7.2%	2	4.2%	34	6.9%	
	Tongue	132	29.7%	16	33.3%	148	30.0%	
	Floor of mouth	158	35.5%	23	47.9%	181	36.7%	
Tumor size	T1	183	41.1%	8	16.7%	191	38.7%	0.002
	T2	141	31.7%	16	33.3%	157	31.8%	
	T3	37	8.3%	9	18.8%	46	9.3%	
	T4	84	18.9%	15	31.3%	99	20.1%	
Cervical lymph node metastasis	N0	286	64.3%	17	35.4%	303	61.5%	<0.001
	N1	60	13.5%	6	12.5%	66	13.4%	
	N2/3	99	22.2%	25	52.1%	124	25.2%	
Extranodal spread	No	108	24.3%	18	37.5%	126	25.6%	<0.001
	Yes	50	11.2%	13	27.1%	63	12.8%	
Grading	Not applicable	287	64.5%	17	35.4%	304	61.7%	0.192
	G1	35	7.9%	1	2.1%	36	7.3%	
	G2	324	72.8%	34	70.8%	358	72.6%	
	G3/4	86	19.3%	13	27.1%	99	20.1%	
Lymphatic invasion	L0	399	89.7%	27	56.3%	426	86.4%	<0.001
	L1	46	10.3%	21	43.8%	67	13.6%	
Vascular invasion	V0	435	97.8%	44	91.7%	479	97.2%	0.016
	V1	10	2.2%	4	8.3%	14	2.8%	
UICC stage	I	144	32.4%	3	6.3%	147	29.8%	<0.001
	II	78	17.5%	8	16.7%	86	17.4%	
	III	69	15.5%	4	8.3%	73	14.8%	
	IV	154	34.6%	33	68.8%	187	37.9%	
Adjuvant therapy	No	277	62.2%	8	16.7%	285	57.8%	<0.001
	Radiotherapy	109	24.5%	24	50.0%	133	27.0%	
	Radio-chemotherapy	59	13.3%	16	33.3%	75	15.2%	
Life status	Alive	295	66.3%	21	43.8%	316	64.1%	0.002
	Deceased	150	33.7%	27	56.3%	177	35.9%	
Death/recurrence	Alive without recurrence	263	59.1%	21	43.8%	284	57.6%	0.041
	Death or recurrence	182	40.9%	27	56.3%	209	42.4%	
	Total	445	100.0%	48	100.0%	493	100.0%	

Abbreviations: CCI: Charlson Comorbidity Index; UICC: Union Internationale Contre le Cancer.

PNI was significantly associated with higher T-stages ($p = 0.002$), cervical lymph node involvement ($p < 0.001$), and pathohistological verification of extranodal spread ($p < 0.001$). Additionally, lymph vessel invasion ($p < 0.001$), as well as vascular invasion ($p = 0.016$), were

more prevalent in patients with PNI (Pn1). Pearson’s chi-squared test identified increasing UICC stages to be significantly associated with PNI ($p < 0.001$) (Table 1). Univariable survival analysis revealed a significantly reduced OAS, as well as RFS, for patients with pathohistological verified PNI: hereby, a Kaplan–Meier analysis resulted in a five year OAS of 67.0% for patients without PNI (Pn0), whereas in case of PNI, five year survival was reduced to 38.8% ($p < 0.001$) (Figure 1). Similar results were seen for RFS, with a five year RFS of 60.6% (Pn1) and 42.0% (Pn1) ($p = 0.004$) (Figure 1). A cumulative five-year-recurrence rate of 21.6% (Pn0) and 34.2% (Pn1) was observed ($p = 0.027$) (Table 2, Figure 2). When focusing on recurrence in detail, a diagnosis of PNI did not significantly alter local ($p = 0.134$), as well as locoregional, recurrence rates ($p = 0.303$). A five-year distant metastasis recurrence rate, however, was significantly increased for patients diagnosed with PNI (16.6%) when compared to Pn0 patients (6.8%) ($p = 0.011$) (Table 2, Figure 2).

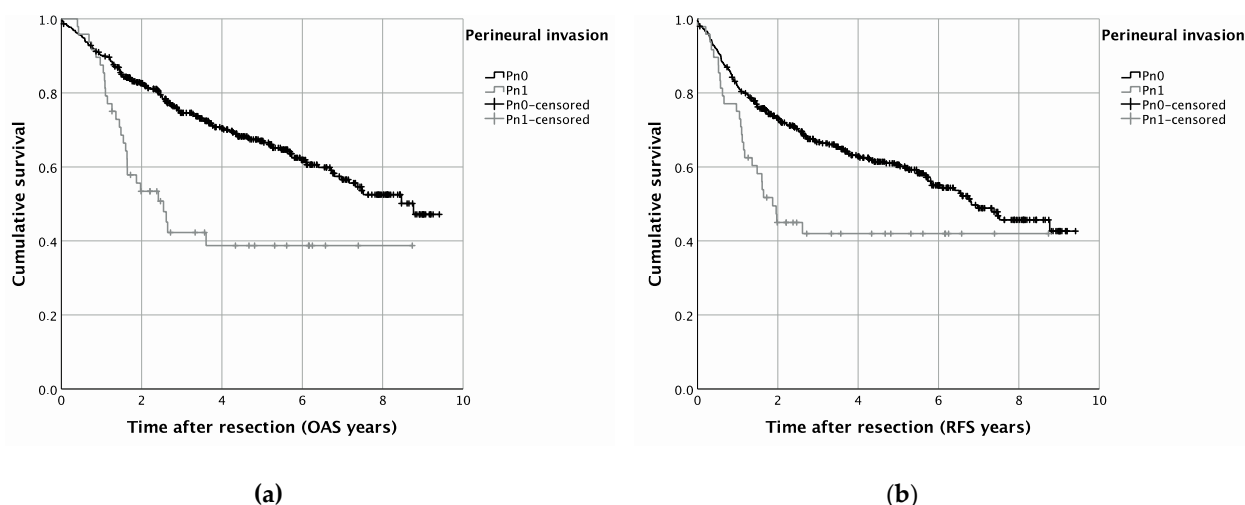


Figure 1. Survival in OSCC patients with or without PNI (Pn1 and Pn0, respectively): Kaplan–Meier curves for OAS (a) ($p = 0.001$) and RFS (b) ($p = 0.002$).

Table 2. Cumulative recurrence rates of as well as detailed forms of recurrence in OSCC patients, depending on PNI.

Category	Group	N (Included Patients)	N (Recurrent Disease)	5-Year-Recurrence Rate	Log-Rank <i>p</i>
Cumulative recurrence rate	Pn0 + Pn1	493	106		
	Pn0	445	91	21.6%	0.027
	Pn1	48	15	34.2%	
Local recurrence rate	Pn0 + Pn1	493	67		
	Pn0	445	58	13.8%	0.134
	Pn1	48	9	21.1%	
Locoregional recurrence rate	Pn0 + Pn1	493	48		
	Pn0	445	42	10.5%	0.303
	Pn1	48	6	17.1%	
Distant metastasis recurrence rate	Pn0 + Pn1	493	33		
	Pn0	445	26	6.8%	0.011
	Pn1	48	7	16.6%	

Multivariable survival analysis was additionally performed to adjust for covariables such as gender, ACCI, smoking and alcohol consumption, anatomical tumor site, UICC stage, grading, and lymphatic and vascular invasion. For OAS, a pathohistological verification of PNI significantly impaired the survival of OSCC patients in the present multicenter cohort study (HR 1.820; 95% CI 1.164–2.847, $p = 0.009$) (Table 3). Additionally, an ACCI of 3+ (HR 1.877; 95% CI 1.028–3.430, $p = 0.040$), as well as advanced tumor stages (HR 2.741; 95% CI 1.954–3.845, $p < 0.001$), were associated with diminished OAS (Table 4). For

RFS, however, merely a trend in impaired multivariable survival was observed for PNI in OSCC patients (HR 1.461; 95% CI 0.934–2.284, $p = 0.097$) (Table 4). In line with the results of the multivariable analysis for OAS, UICC stages III and IV (HR 2.074; 95% CI 1.534–2.805, $p < 0.001$) and an elevated ACCI ($p < 0.001$) were significantly associated with impaired RFS (Table 4).

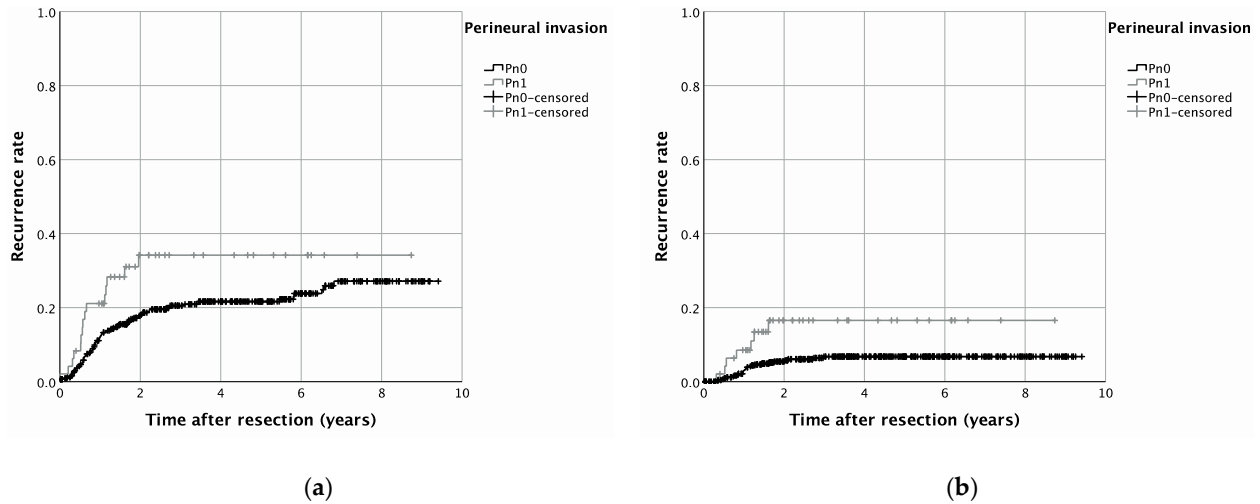


Figure 2. Recurrence rates in OSCC patients with or without PNI (Pn1 and Pn0, respectively) for cumulative recurrence (a) ($p = 0.001$) as well as for recurrence by distant metastasis (b) ($p = 0.002$).

Table 3. Effect of PNI and additional covariables on OAS using uni- as well as multivariable Cox regression.

		Overall Survival (OAS)							
Category	Group	Univariable Cox Regression				Multivariable Cox Regression			
		<i>p</i>	HR	Lower 95%-CI	Upper 95%-CI	<i>p</i>	HR	Lower 95%-CI	Upper 95%-CI
PNI	Pn0		1.000				1.000		
	Pn1	<0.001	2.312	1.530	3.493	0.009	1.820	1.164	2.847
Gender	Female		1.000				1.000		
	Male	0.857	1.030	0.746	1.424	<0.001	1.000		
Age-adjusted CCI	0	<0.001	1.000			<0.001	1.000		
	1 and 2	0.778	0.915	0.491	1.704	0.774	0.912	0.488	1.707
Positive anamnesis smoking	3+	0.043	1.854	1.020	3.369	0.040	1.877	1.028	3.430
	No		1.000				1.000		
Positive anamnesis alcohol	Yes	0.522	1.118	0.795	1.572				
	No		1.000				1.000		
Anatomical tumor site	Yes	0.684	1.068	0.777	1.469				
	Upper alveolus, gingiva and hard palate	0.23	1.000						
	Tongue	0.126	0.665	0.395	1.121				
UICC stage	Lower alveolus, floor of mouth, buccal mucosa	0.499	0.851	0.534	1.358				
	I/II		1.000				1.000		
Grading	III/IV	<0.001	3.015	2.168	4.194	<0.001	2.741	1.954	3.845
	G1/2		1.000				1.000		
Lymphatic invasion	G3/4	0.068	1.395	0.976	1.993	0.124	1.328	0.925	1.906
	L0		1.000				1.000		
Vascular invasion	L1	0.001	1.906	1.297	2.800	0.595	1.122	0.735	1.713
	V0		1.000				1.000		
	V1	0.036	2.055	1.049	4.027	0.185	1.583	0.803	3.119

Abbreviations: CCI: Charlson Comorbidity Index; UICC: Union Internationale Contre le Cancer.

Table 4. Effect of PNI and additional covariables on cumulative RFS using uni- as well as multivariable Cox regression.

Category	Group	Recurrence-Free Survival (RFS)							
		Univariable Cox Regression				Multivariable Cox Regression			
		<i>p</i>	HR	Lower 95%-CI	Upper 95%-CI	<i>p</i>	HR	Lower 95%-CI	Upper 95%-CI
PNI	Pn0		1.000				1.000		
	Pn1	0.005	1.794	1.195	2.692	0.097	1.461	0.934	2.284
Gender	Female		1.000						
	Male	0.894	1.020	0.758	1.373				
Age-adjusted CCI	0	<0.001	1.000			<0.001	1.000		
	1 and 2	0.743	0.911	0.523	1.589	0.578	0.852	0.486	1.496
Positive anamnesis smoking	3+	0.070	1.642	0.960	2.808	0.108	1.561	0.907	2.688
	No		1.000						
Positive anamnesis alcohol	Yes	0.684	1.066	0.782	1.454				
	No		1.000						
Anatomical tumor site	Yes	0.638	1.072	0.801	1.436				
	Upper alveolus, gingiva and hard palate	0.028	1.000			0.290			
	Tongue	0.008	0.535	0.337	0.850	0.130	0.691	0.428	1.115
UICC stage	Lower alveolus, floor of mouth, buccal mucosa	0.099	0.709	0.471	1.067	0.108	1.561	0.907	2.688
	I/II		1.000						
Grading	III/IV	<0.001	2.331	1.745	3.113	<0.001	2.074	1.534	2.805
	G1/2		1.000				1.000		
Lymphatic invasion	G3/4	0.058	1.375	0.989	1.910	0.136	1.289	0.923	1.800
	L0		1.000				1.000		
Vascular invasion	L1	0.001	1.874	1.311	2.679	0.275	1.251	0.837	1.871
	V0		1.000						
	V1	0.161	1.614	0.826	3.152				

Abbreviations: CCI: Charlson Comorbidity Index; UICC: Union Internationale Contre le Cancer.

4. Discussion

PNI is a so-called optional descriptor in the established “TNM Classification of Malignant Tumours, 8th Edition” for OSCC, in addition to lymphatic and vascular invasion. Cancerous invasive growth in adjacent anatomical structures is characteristically linked to an increased risk of local, cervical lymphatic, and distant disease recurrence [17,18]. Nonetheless, it seems like PNI is relatively neglected in existing staging manuals [19]. The importance on OSCC patients’ survival after curative tumor resection is particularly of high clinical relevance.

Among the special features of our study are the large cohort, the population-based approach, the differentiation between types of recurrence, and the focus on patients’ comorbidities. With 9.7% of OSCC patients being diagnosed with PNI in the present study, a comparison with the prevalence of PNI in similar study designs might be of interest: a broad bandwidth (6.1–82%) for prevalence of PNI in OSCC can be found in the literature [20]. It is important to note that the diagnosis of PNI is closely related to different clinical, as well as pathohistological, parameters, including comorbidities, higher UICC stage, and heterogeneity of patient cohorts [21], especially blurring in the definition of PNI, as well as explicit pathohistological examination methods, to determine the evidence of PNI in clinical routine and scientific approaches.

A commonly applied definition of PNI entails the presence of malignant cells within any of the three layers of a neural structure or tumor foci outside of the nerve with involvement of more than one third of the nerve’s circumference [16]. A less precise definition in this regard was given by Batsakis in 1985: PNI can be diagnosed if “tumor cell invasion in, around and through the nerve . . . ” is present [22]. Undoubtedly, the definition of Batsakis leaves a scope for interpretation when it comes to precise definition of PNI. Therefore,

objective, broadly accepted parameters for the diagnosis of PNI are urgently needed [23]. In addition, the establishment of standardized protocols would improve diagnoses of PNI. Certainly, immunohistochemical staining enhances the reliable detection of PNI based on neuronal markers such as S100 and several neurotrophins and their receptors [12,24]. In this regard, Shen et al. conducted a study on 116 previously resected OSCC patients, re-evaluating diagnoses of PNI by pathohistological stainings [25]. The initial PNI rate was increased by 17% through sheer review of hematoxylin and eosin-stained tissue biopsies by experienced pathologists. Additionally, IHC staining was applied using anti-S100 antibodies, which resulted in an overall PNI detection rate of 51% [25].

A major aim of the present study was to evaluate PNI as a prognostic oncological factor of surgically treated OSCC patients. Our results underline the findings of previous cohort studies on OSCC patients, indicating a significantly impaired outcome for Pn1 OSCC patients in uni- as well as multivariable survival analyses [6,26,27]. Moreover, with the present retrospective cohort study, we investigated whether PNI in OSCC patients affects different types of recurrence after tumor resection. Kaplan–Meier analysis clearly indicates a pronounced risk for recurrence, whether in terms of overall recurrence or recurrence by formation of distant metastasis. In this regard, we were able to attribute OSCC patients with PNI a 1.8-fold increased risk to develop distant metastasis, mainly in the lung or liver. This should be considered in follow-up care and assessment of OSCC patients.

However, the significance of PNI with regards to recurrence of malignancy is controversial in the current literature—notably, for the risk of developing distant metastasis, a diverging opinion exists. In this regard, Tarsitano et al. published results of not significantly increased distant metastasis recurrence rates for Pn1 patients compared to Pn0 OSCC cases [27]. In contrast to this, Rahima et al. attributed increased distant metastasis recurrence rates to oral, as well as oropharyngeal, squamous cell carcinoma patients with PNI; however, just 101 patients were included in this retrospective cohort study [28].

The results from our population-based, multicenter cohort study corroborate the findings of Rahima et al. [28], and thereby assign PNI as a clearly detrimental prognostic impact on survival and recurrence in OSCC patients. In terms of predictive implications of PNI, and, chiefly, for adjuvant treatment modalities, we could not derive reliable implications of a potential outcome benefit after adjuvant RT or RCT due to small case numbers. Unsurprisingly, this question is of growing interest in the current literature. A main argument, potentially explaining a lack of effect for application of adjuvant treatment in Pn1 patients, might potentially be based on an already deteriorated outcome of Pn1 patients when compared to Pn0 cases. Particularly with regard to promising *in vitro* findings [11], the current inconsistent data situation regarding the role of adjuvant treatment of OSCC patients with PNI definitely demands further research [29].

5. Conclusions

PNI appears to be a relevant prognostic factor for the survival and recurrence of OSCC patients having received tumor resection to negative margins combined with a cervical lymphadenectomy. When focusing on recurrence in detail, the development of distant metastasis was significantly increased in Pn1 patients. Currently, an indication of adjuvant treatment for verified PNI in OSCC patients is under debate. So far, the present multicenter cohort study could not derive reliable implications of a potential outcome benefit after adjuvant RT or RCT. Additional *in vivo*, as well as *in vitro*, studies are necessary to unveil the molecular basis of PNI in OSCC and to develop targeted therapeutical approaches to address this special tropism of tumor spread. Based on our findings, we highly recommend emphasizing PNI in the TNM staging concept.

Author Contributions: Conceptualization, S.S. (Steffen Spoerl), S.S. (Silvia Spoerl), M.G. and G.S.; data curation, S.S. (Steffen Spoerl), M.G., S.R., R.F. and G.S.; formal analysis, S.S. (Steffen Spoerl), M.G. and G.S.; investigation, J.T., R.F. and G.S.; methodology, S.S. (Silvia Spoerl), S.S. (Steffen Spoerl), S.R. and G.S.; project administration, S.S. (Silvia Spoerl), S.S. (Steffen Spoerl) and G.S.; resources, T.E. and T.E.R.; software, J.T. and N.L.; supervision, S.S. (Steffen Spoerl) and G.S.; validation, N.L., R.F., T.E. and T.E.R.; visualization, S.S. (Silvia Spoerl), J.T. and G.S.; writing—original draft, S.S. (Steffen Spoerl) and G.S.; writing—review and editing, S.S. (Silvia Spoerl), S.S. (Steffen Spoerl), N.L., J.T., R.F. and G.S.; All authors have read and agreed to the published version of the manuscript.

Funding: This work was supported by the Else Kröner-Fresenius-Stiftung, Germany.

Institutional Review Board Statement: The study was conducted according to the guidelines of the Declaration of Helsinki and approved by the Ethics Committee of the University of Regensburg (GeschZ 12-101-0070, date of approval 11 November 2015).

Informed Consent Statement: Based on a retrospective analysis and a fully anonymized set of clinical data, and in agreement with the decision of the Ethics Committee, signing an informed consent form was not required.

Data Availability Statement: Data can be obtained by scientists that conducted the work independently from the industry on request. Data are not stored on publicly available servers.

Acknowledgments: We thank Stefanie Wolf from St. Elisabeth Hospital Straubing for her excellent support. The present work was performed in fulfillment of the requirements for obtaining the degree of “Dr. med. dent.” by Stephanie Reil.

Conflicts of Interest: The authors declare no conflict of interest.

References

- Bonifazi, M.; Malvezzi, M.; Bertuccio, P.; Edefonti, V.; Garavello, W.; Levi, F.; La Vecchia, C.; Negri, E. Age-period-cohort analysis of oral cancer mortality in Europe: The end of an epidemic? *Oral Oncol.* **2011**, *47*, 400–407. [[CrossRef](#)] [[PubMed](#)]
- Burtneß, B.; Harrington, K.J.; Greil, R.; Soulières, D.; Tahara, M.; de Castro, G., Jr.; Psyri, A.; Basté, N.; Neupane, P.; Bratland, Å.; et al. Pembrolizumab alone or with chemotherapy versus cetuximab with chemotherapy for recurrent or metastatic squamous cell carcinoma of the head and neck (KEYNOTE-048): A randomised, open-label, phase 3 study. *Lancet* **2019**, *394*, 1915–1928. [[CrossRef](#)]
- Keerthi, R.; Dutta, A.; Agarwal, S.; Kani, V.; Khatua, A. Perineural Invasion of Oral Squamous Cell Carcinoma: A New Hurdle for Surgeons. *J. Maxillofac. Oral Surg.* **2018**, *17*, 59–63. [[CrossRef](#)] [[PubMed](#)]
- Chatzistefanou, I.; Lubek, J.; Markou, K.; Ord, R.A. The role of perineural invasion in treatment decisions for oral cancer patients: A review of the literature. *J. Cranio-Maxillo-Facial Surg. Off. Publ. Eur. Assoc. Cranio-Maxillo-Facial Surg.* **2017**, *45*, 821–825. [[CrossRef](#)] [[PubMed](#)]
- Kurtz, K.A.; Hoffman, H.T.; Zimmerman, M.B.; Robinson, R.A. Perineural and vascular invasion in oral cavity squamous carcinoma: Increased incidence on re-review of slides and by using immunohistochemical enhancement. *Arch. Pathol. Lab. Med.* **2005**, *129*, 354–359. [[CrossRef](#)] [[PubMed](#)]
- Nair, D.; Mair, M.; Singhvi, H.; Mishra, A.; Nair, S.; Agrawal, J.; Chaturvedi, P. Perineural invasion: Independent prognostic factor in oral cancer that warrants adjuvant treatment. *Head Neck* **2018**, *40*, 1780–1787. [[CrossRef](#)]
- Gaddikeri, S. Perineural Invasion of Skin Cancers in the Head and Neck: An Uncommon Phenomenon Revisited. *Otolaryngology* **2014**, *4*, 2. [[CrossRef](#)]
- Chen, Y.W.; Yu, E.H.; Wu, T.H.; Lo, W.L.; Li, W.Y.; Kao, S.Y. Histopathological factors affecting nodal metastasis in tongue cancer: Analysis of 94 patients in Taiwan. *Int. J. Oral Maxillofac. Surg.* **2008**, *37*, 912–916. [[CrossRef](#)] [[PubMed](#)]
- Woolgar, J.A.; Scott, J. Prediction of cervical lymph node metastasis in squamous cell carcinoma of the tongue/floor of mouth. *Head Neck* **1995**, *17*, 463–472. [[CrossRef](#)]
- Amit, M.; Na’ara, S.; Gil, Z. Mechanisms of cancer dissemination along nerves. *Nat. Rev. Cancer* **2016**, *16*, 399–408. [[CrossRef](#)]
- Bakst, R.L.; Wong, R.J. Mechanisms of Perineural Invasion. *J. Neurol. Surg. Part B Skull Base* **2016**, *77*, 96–106. [[CrossRef](#)] [[PubMed](#)]
- Misztal, C.I.; Green, C.; Mei, C.; Bhatia, R.; Velez Torres, J.M.; Kamrava, B.; Moon, S.; Nicolli, E.; Weed, D.; Sargi, Z.; et al. Molecular and Cellular Mechanisms of Perineural Invasion in Oral Squamous Cell Carcinoma: Potential Targets for Therapeutic Intervention. *Cancers* **2021**, *13*, 6011. [[CrossRef](#)]
- Sobin, L.H.; Gospodarowicz, M.K.; Wittekind, C.; International Union against Cancer. *TNM Classification of Malignant Tumours*, 7th ed.; Sobin, L.H., Gospodarowicz, M.K., Wittekind, C., Eds.; Wiley-Blackwell: Chichester, UK; West Sussex, UK; Hoboken, NJ, USA, 2010.
- Charlson, M.E.; Pompei, P.; Ales, K.L.; MacKenzie, C.R. A new method of classifying prognostic comorbidity in longitudinal studies: Development and validation. *J. Chronic Dis.* **1987**, *40*, 373–383. [[CrossRef](#)]

15. Spanier, G.; Böttcher, J.; Gerken, M.; Fischer, R.; Roth, G.; Lehn, P.; Klingelhöffer, C.; Meier, J.K.; Fraccaroli, A.; Tischer, J.; et al. Prognostic value of perioperative red blood cell transfusion and anemia on survival and recurrence in oral squamous cell carcinoma. *Oral Oncol.* **2020**, *107*, 104773. [[CrossRef](#)] [[PubMed](#)]
16. Liebig, C.; Ayala, G.; Wilks, J.A.; Berger, D.H.; Albo, D. Perineural invasion in cancer: A review of the literature. *Cancer* **2009**, *115*, 3379–3391. [[CrossRef](#)] [[PubMed](#)]
17. Sahoo, A.; Panda, S.; Mohanty, N.; Jena, D.; Mishra, N.; Surabhi; Baisakh, M.R. Perineural, lymphovascular and depths of invasion in extrapulating nodal metastasis in oral cancer. *Clin. Oral. Investig.* **2020**, *24*, 747–755. [[CrossRef](#)] [[PubMed](#)]
18. Spoerl, S.; Gerken, M.; Fischer, R.; Mamilos, A.; Spoerl, S.; Wolf, S.; Pohl, F.; Klingelhoffer, C.; Ettl, T.; Reichert, T.E.; et al. Lymphatic and vascular invasion in oral squamous cell carcinoma: Implications for recurrence and survival in a population-based cohort study. *Oral Oncol.* **2020**, *111*, 105009. [[CrossRef](#)] [[PubMed](#)]
19. Varsha, B.K.; Radhika, M.B.; Makarla, S.; Kuriakose, M.A.; Kiran, G.S.; Padmalatha, G.V. Perineural invasion in oral squamous cell carcinoma: Case series and review of literature. *J. Oral Maxillofac. Pathol.* **2015**, *19*, 335–341. [[CrossRef](#)]
20. Schmitd, L.B.; Scanlon, C.S.; D’Silva, N.J. Perineural Invasion in Head and Neck Cancer. *J. Dent. Res.* **2018**, *97*, 742–750. [[CrossRef](#)]
21. Matsushita, Y.; Yanamoto, S.; Takahashi, H.; Yamada, S.; Naruse, T.; Sakamoto, Y.; Ikeda, H.; Shiraishi, T.; Fujita, S.; Ikeda, T.; et al. A clinicopathological study of perineural invasion and vascular invasion in oral tongue squamous cell carcinoma. *Int. J. Oral Maxillofac. Surg.* **2015**, *44*, 543–548. [[CrossRef](#)]
22. Batsakis, J.G. Nerves and neurotropic carcinomas. *Ann. Otol. Rhinol. Laryngol.* **1985**, *94 Pt 1*, 426–427. [[PubMed](#)]
23. Chi, A.C.; Katabi, N.; Chen, H.S.; Cheng, Y.L. Interobserver Variation Among Pathologists in Evaluating Perineural Invasion for Oral Squamous Cell Carcinoma. *Head Neck Pathol.* **2016**, *10*, 451–464. [[CrossRef](#)] [[PubMed](#)]
24. Conte, G.A.; Qari, O.; Fasano, G.A.; Guinto, R.K.; Palo, L.; Parker, G.S.; Rangwala, A.F.; Minassian, H.; Greenberg, P.J.; Dewan, A.A.; et al. S100 Staining Adds to the Prognostic Significance of the Combination of Perineural Invasion and Lymphovascular Invasion in Colorectal Cancer. *Appl. Immunohistochem. Mol. Morphol. AIMM* **2020**, *28*, 354–359. [[CrossRef](#)]
25. Shen, W.R.; Wang, Y.P.; Chang, J.Y.; Yu, S.Y.; Chen, H.M.; Chiang, C.P. Perineural invasion and expression of nerve growth factor can predict the progression and prognosis of oral tongue squamous cell carcinoma. *J. Oral Pathol. Med. Off. Publ. Int. Assoc. Oral Pathol. Am. Acad. Oral Pathol.* **2014**, *43*, 258–264. [[CrossRef](#)] [[PubMed](#)]
26. Laske, R.D.; Scholz, I.; Ikenberg, K.; Meerwein, C.; Vital, D.G.; Studer, G.; Rössle, M.; Huber, G.F. Perineural Invasion in Squamous Cell Carcinoma of the Oral Cavity: Histology, Tumor Stage, and Outcome. *Laryngoscope Investig. Otolaryngol.* **2016**, *1*, 13–18. [[CrossRef](#)] [[PubMed](#)]
27. Tarsitano, A.; Tardio, M.L.; Marchetti, C. Impact of perineural invasion as independent prognostic factor for local and regional failure in oral squamous cell carcinoma. *Oral Surg. Oral Med. Oral Pathol. Oral Radiol.* **2015**, *119*, 221–228. [[CrossRef](#)] [[PubMed](#)]
28. Rahima, B.; Shingaki, S.; Nagata, M.; Saito, C. Prognostic significance of perineural invasion in oral and oropharyngeal carcinoma. *Oral Surg. Oral Med. Oral Pathol. Oral Radiol. Endod.* **2004**, *97*, 423–431. [[CrossRef](#)]
29. Blackburn, T.K.; Bakhtawar, S.; Brown, J.S.; Lowe, D.; Vaughan, E.D.; Rogers, S.N. A questionnaire survey of current UK practice for adjuvant radiotherapy following surgery for oral and oropharyngeal squamous cell carcinoma. *Oral Oncol.* **2007**, *43*, 143–149. [[CrossRef](#)]