



## Case Report

# Surgical treatment of a rare rosette-forming glioneuronal tumor in the pineal region

Sajjad Muhammad<sup>1,2</sup>, Ahmad Hafez<sup>1</sup>, Atte Karppinen<sup>1</sup>, Mika Niemelä<sup>1</sup>

<sup>1</sup>Department of Neurosurgery, University of Helsinki and Helsinki University Hospital, Helsinki, Finland, <sup>2</sup>Department of Neurosurgery, Heinrich-Heine University Medical Center, Düsseldorf, Germany.

E-mail: \*Sajjad Muhammad - ext-sajjad.muhammad@hus.fi; Ahmad Hafez - ext-ahmad.hafez@hus.fi; Atte Karppinen - atte.karppinen@hus.fi; Mika Niemelä - mika.niemela@hus.fi



### \*Corresponding author:

Sajjad Muhammad,  
Department of Neurosurgery,  
University of Helsinki,  
Topeliuksenkatu 5,  
Helsinki-FI-000, Helsinki,  
Finland.

ext-sajjad.muhammad@hus.fi

Received : 08 May 2019

Accepted : 17 March 2020

Published : 18 April 2020

### DOI

10.25259/SNI\_294\_2019

### Quick Response Code:



## ABSTRACT

**Background:** Rosette-forming glioneuronal tumors (RGNTs) in the pineal region are rare. RGNTs have been described in the fourth ventricle, but rarely reported in other brain regions. Here, we report the radiological findings, surgical treatment, and short-term outcome of an RGNT found in the pineal region.

**Case Description:** We present a case of a 22-year-old medical student with a 4-month history of headaches and diplopia. A previous magnetic resonance imaging scan revealed a mass in the pineal region, with heterogeneous contrast enhancement and hydrocephalus. Three months prior, an endoscopic biopsy and third ventriculocisternostomy were performed elsewhere; the diagnosis was neurocytoma Grade I, and radiotherapy was planned. The patient presented at our hospital for a second opinion, and we suggested surgical treatment. A near-total resection was performed in sitting position using a supracerebellar infratentorial microsurgical approach. The tumor was very soft and not well vascularized. Diplopia was initially worsened after the tumor was removed and relieved completely after 2 weeks. An 8-week follow-up examination revealed that the patient was free of symptoms. Histological analysis confirmed it was an RGNT.

**Conclusion:** Maximal safe resection in pineal region RGNTs is a feasible and recommended treatment option.

**Keywords:** Operative nuances, Pineal region, Rosette-forming glioneuronal tumor

## INTRODUCTION

Rosette-forming glioneuronal tumors (RGNTs) are an unusual variant of mixed neuronal-glia tumors. RGNTs are typically found in the fourth ventricle, with limited extension to the surrounding structures (cerebellar vermis, midbrain, and cerebral aqueduct). They were initially classified as novel “rosette-forming glioneuronal tumors of the fourth ventricle” according to the 2007 WHO classification of central nervous tumors.<sup>[9]</sup> However, an increasing number of case reports have described these tumors in various locations beyond the fourth ventricle, including cerebellar hemispheres, vermis, chiasm, pineal region, third ventricle, hypothalamus, and spinal cord.<sup>[3,5,7,11,13]</sup> Hence, in 2016, the revised version of the WHO classification described these tumors as “rosette-forming glioneuronal tumors” (without reference to the fourth ventricle), histologically Grade I.<sup>[10]</sup> Around 150 cases of RGNTs have been described in the literature. However, less than 10 of these cases (5.3%) have been described in the pineal region.<sup>[14]</sup> Pineal region RGNT may cause similar symptoms as the other pineal region tumors. However, microcalcifications and satellite lesion are

This is an open-access article distributed under the terms of the Creative Commons Attribution-Non Commercial-Share Alike 4.0 License, which allows others to remix, tweak, and build upon the work non-commercially, as long as the author is credited and the new creations are licensed under the identical terms.

©2020 Published by Scientific Scholar on behalf of Surgical Neurology International

commonly found in pineal region RGNTs. Characteristic features of RGNTs have recently been review by Anyanwu *et al.*<sup>[2]</sup> Here, we present another case of an RGNT in the pineal region, which was surgically treated at our hospital.

## CASE HISTORY

A 22-year-old medical student presented with a 4-month history of headache and diplopia. A previous magnetic resonance imaging (MRI) scan revealed a contrast-enhancing lesion in the pineal region. An endoscopic biopsy and third ventriculocisternostomy were performed elsewhere; the diagnosis was neurocytoma Grade I. Radiotherapy was planned elsewhere. The patient presented to our hospital for a second opinion. After oncological consultation, we suggested surgical resection of the tumor. On examination, the patient was alert and oriented. Visual field was intact, and pupil size was normal and reactive to light. The patient's hearing and facial nerve function were normal. A new MRI scan revealed a contrast-enhancing space-occupying lesion of approximately 2 cm in size in the pineal region [Figure 1]. No other pathology and no drop metastasis in the supra or infratentorial region were observed in preoperative workup.

### Surgery of pineal region RGNT

#### Operative findings

Surgery was performed with the patient in sitting position. A supracerebellar infratentorial approach was

used, with an OPMI PENTERO 900 microscope (Carl Zeiss, Germany). The dura was opened in a Y-shaped fashion, preserving the main veins in the tentorial region. The tumor was easily recognized; it was soft, cystic, and pale yellow in color [Figure 2]. The tumor had a well-defined plane and was removed easily using standard microsurgical tools and techniques. The dura was closed in a watertight fashion.

#### Postoperative outcome

Diplopia was initially worse but completely relieved 2 weeks after the surgery, without any new focal neurological deficit. No other complications occurred. The patient was discharged from the hospital 4 days after the surgery. An 8-week follow-up examination revealed that the patient was without symptoms. Histological analysis showed an RGNT. Postoperative MRI scans showed a small remnant in posterior part of thalamus and aqueduct [Figure 3]. After discussion in interdisciplinary tumor board, the patient will be followed up with MRI scans.

## DISCUSSION

An RGNT in the pineal region is a rare affliction. It mainly affects young adults – predominantly females – with a peak incidence among people in their thirties.<sup>[8,14]</sup> However, our case report presents a 22-year-old male patient. The presentation of symptoms depends on where the tumor is located in the ventricular system or brain parenchyma. The

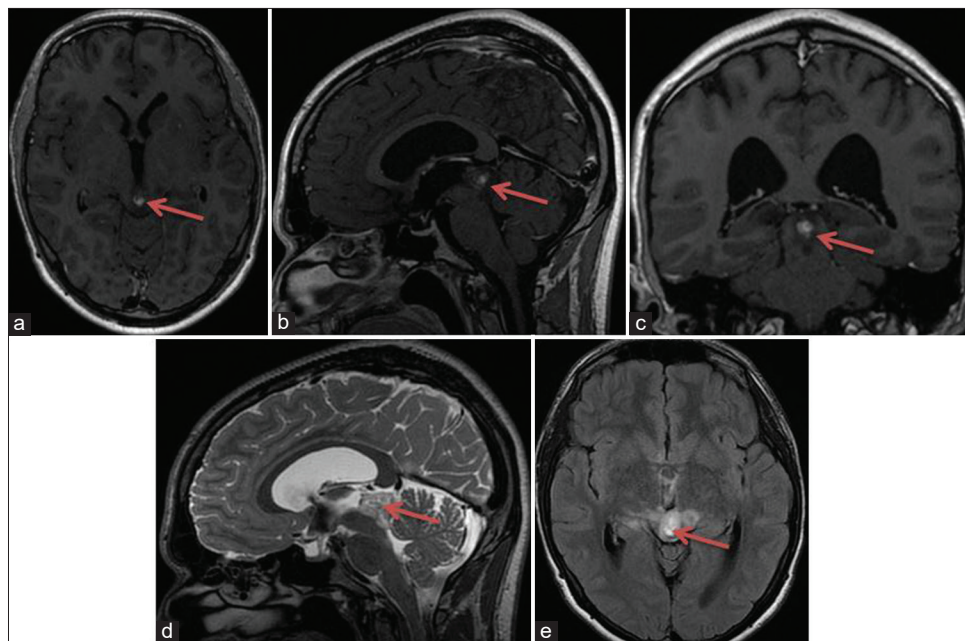


Figure 1: MRI scans (pre-operative) showing tumor location and radiological anatomy of a space-occupying lesion with partially and heterogeneous contrast enhancement in the pineal region (a,b,c). FLAIR and TW2 hyperintensity in and around the pineal region (d, e).

most commonly presented symptoms in RGNT cases are ataxia, vertigo, cranial nerve palsies, complaints of impaired vision, headache, and vomiting. Our patient presented with headache and diplopia. Radiologically, RGNTs can be cystic (35%), cystic solid (18%), or solid (47%). The solid tumor regions display hypointensity on T1W1 and hyperintensity on T2W2 and a variable but mostly heterogeneous pattern of contrast enhancement. In MR spectroscopy, the low-grade nature of these tumors is indicated by

slightly elevated choline, reduced N-acetyl aspartate, and the absence of lactate and lipids.<sup>[4]</sup> Although we did not perform MR spectroscopy, the MRI images showed similar T1W1, T2W2, fluid-attenuated inversion recovery, and contrast enhancement as described in the literature. Multimodal neuroimaging may help to differentiate RGNTs preoperatively. Hydrocephalic symptoms resolved after the surgical resection in most of the cases in literature similar to our case. Histological analysis revealed a biphasic neurocytic and glial pattern with an absence of atypia, mitotic activity, necrosis, and low proliferation index, characteristic of RGNTs.

Due to limited experience with therapeutic treatments such as stereotactic radiosurgery or chemotherapy, surgical resection aimed at achieving gross total resection remains the preferred treatment of RGNTs. RGNTs are Grade I benign tumors, but aggressive progression and ventricular dissemination have been previously described.<sup>[1,6,12]</sup> The risk of recurrence may be increased if resection is inadequate, and/or if purely solid tumors are found in patients of pediatric age. Due to shorter follow-up periods described in the literature and due to few cases of pineal RGNTs, it is difficult to draw a conclusion on the prognosis of RGNTs in pineal region. Hence, a long-term closely monitored follow-up is important. Genetic analysis of mutations, including IDH1 and IDH2, as well as chromosomal codeletion analysis may be useful in further characterization of these tumors.

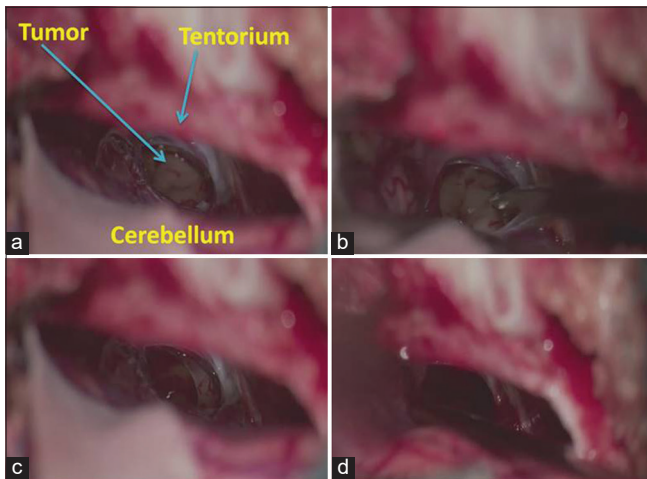


Figure 2: Intraoperative images showing tumor removal and intraoperative surgical anatomy (a-d).

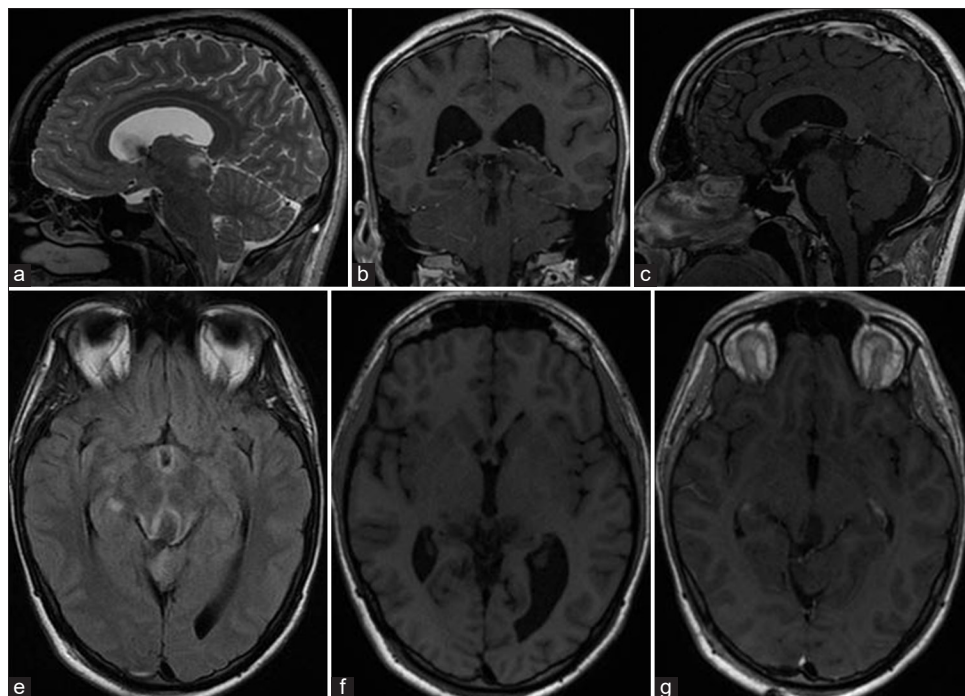


Figure 3: MRI scans (post operative) showing near total tumor removal (a, b, c, e and f). FLAIR (e) and T2W2 (a) show slight signal enhancement (small tumor remnant) in posterior part of thalamus and aqueduct.

## CONCLUSION

Maximal safe resection of RGNTs in the pineal region is a feasible and recommended treatment option.

## Ethical approval

All procedures performed in this study involving human participants were in accordance with the ethical standards of the research committee of University of Helsinki and with the 1964 Declaration of Helsinki and its amendments or comparable ethical standards.

## Declaration of patient consent

Patient's consent not required as patients identity is not disclosed or compromised.

## Financial support and sponsorship

We are thankful to the Ehrnrooth Foundation for providing funding to SM for a clinical vascular and skull base fellowship at the Department of Neurosurgery at the University of Helsinki.

## Conflicts of interest

There are no conflicts of interest.

## REFERENCES

- Allinson KS, O'Donovan DG, Jena R, Cross JJ, Santarius TS. Rosette-forming glioneuronal tumor with dissemination throughout the ventricular system: A case report. *Clin Neuropathol* 2015;34:64-9.
- Anyanwu CT, Robinson TM, Huang JH. Rosette-forming glioneuronal tumor: An update. *Clin Transl Oncol* 2019;2019:1-8.
- Bidinotto LT, Scapulatempo-Neto C, Mackay A, de Almeida GC, Scheithauer BW, Berardinelli GN, *et al.* Molecular profiling of a rare rosette-forming glioneuronal tumor arising in the spinal cord. *PLoS One* 2015;10:e0137690.
- Cachia D, Prado MP, Theeler B, Hamilton J, McCutcheon I, Fuller GN. Synchronous rosette-forming glioneuronal tumor and diffuse astrocytoma with molecular characterization: A case report. *Clin Neuropathol* 2014;33:407-11.
- Chiba K, Aihara Y, Eguchi S, Tanaka M, Komori T, Okada Y. Rosette-forming glioneuronal tumor of the fourth ventricle with neurocytoma component. *Childs Nerv Syst* 2014;30:351-6.
- García Cabezas S, Serrano Blanch R, Sanchez-Sanchez R, Palacios Eito A. Rosette-forming glioneuronal tumour (RGNT) of the fourth ventricle: A highly aggressive case. *Brain Tumor Pathol* 2015;32:124-30.
- Gessi M, Lambert SR, Lauriola L, Waha A, Collins VP, Pietsch T. Absence of KIAA1549-BRAF fusion in rosette-forming glioneuronal tumors of the fourth ventricle (RGNT). *J Neurooncol* 2012;110:21-5.
- Komori T, Scheithauer BW, Hirose T. A rosette-forming glioneuronal tumor of the fourth ventricle: Infratentorial form of dysembryoplastic neuroepithelial tumor? *Am J Surg Pathol* 2002;26:582-91.
- Louis DN, Ohgaki H, Wiestler OD, Cavenee WK, Burger PC, Jouvet A, *et al.* The 2007 WHO classification of tumours of the central nervous system. *Acta Neuropathol* 2007;114:97-109.
- Louis DN, Perry A, Reifenberger G, von Deimling A, Figarella-Branger D, Cavenee WK, *et al.* The 2016 World Health Organization classification of tumors of the central nervous system: A summary. *Acta Neuropathol* 2016;131:803-20.
- Medhi G, Prasad C, Saini J, Pendharkar H, Bhat MD, Pandey P, *et al.* Imaging features of rosette-forming glioneuronal tumours (RGNTs): A series of seven cases. *Eur Radiol* 2016;26:262-70.
- Wang Y, Xiong J, Chu SG, Liu Y, Cheng HX, Wang YF, *et al.* Rosette-forming glioneuronal tumor: Report of an unusual case with intraventricular dissemination. *Acta Neuropathol* 2009;118:813-9.
- Xiong J, Liu Y, Chu SG, Chen H, Chen HX, Mao Y, *et al.* Rosette-forming glioneuronal tumor of the septum pellucidum with extension to the supratentorial ventricles: Rare case with genetic analysis. *Neuropathology* 2012;32:301-5.
- Yang C, Fang J, Li G, Li S, Ha T, Wang J, *et al.* Histopathological, molecular, clinical and radiological characterization of rosette-forming glioneuronal tumor in the central nervous system. *Oncotarget* 2017;8:109175-90.

**How to cite this article:** Muhammad S, Hafez A, Karppinen A, Niemelä M. Surgical treatment of a rare rosette-forming glioneuronal tumor in the pineal region. *Surg Neurol Int* 2020;11:68.