

## Penetrating keratoplasty after complicated small incision lenticule extraction a case report



Julian Langer, Siegfried Priglinger, Elisabeth M. Messmer, Martin Dirisamer, Mehdi Shajari, Wolfgang J. Mayer\*

Department of Ophthalmology, Ludwig-Maximilians-University, Munich, Germany

### ABSTRACT

**Purpose:** We present an interesting case of a 26-year-old woman who underwent penetrating keratoplasty due to complete corneal scarring on the right eye after complicated myopic SMILE.

**Observations:** The spherical equivalent before laser treatment was  $-4.38\text{D}$  on the right eye and  $-4.00\text{D}$  on the left eye and topography showed a with-the-rule astigmatism on both eyes. The documented laser procedure was uneventful but wrong separation of the lenticule made a complete extraction of the lenticule not possible. The postoperative spherical equivalent showed  $-4.125\text{D}$  with an irregular astigmatism due to corneal scarring throughout the complete corneal stroma documented in OCT measurements. Due to serious anatomical changes of the cornea an uneventful penetrating keratoplasty was performed.

**Conclusion and importance:** SMILE procedure should be carefully performed as especially the lenticule separation and extraction can be a surgical challenge. In doubt, separation of the lenticule should not be enforced as it may lead to devastating outcome as presented in this case.

### 1. Introduction

Small incision lenticule extraction (SMILE) is a relatively new corneal ablative procedure. By dissecting and extracting a predefined intrastromal lenticule, the surgeon can correct myopia and myopic astigmatism.<sup>1</sup>

Due to the small corneal incision, flap-related side effects like loss of biomechanical stability, disruption of anterior corneal innervation and corneal dryness following laser-assisted in-situ keratomileusis (LASIK) surgery are reduced.<sup>2,3</sup>

Nevertheless, there is still an intracorneal space between the corneal cap and the intrastromal bed which can cause several complications like interface haze, black spots during the creation of the lenticule, anterior chamber bubbles and cap perforation.<sup>4</sup>

From a surgical point of view, SMILE surgery is more challenging and needs more accurate surgical techniques in comparison to flap-based ablative procedures like LASIK, mainly due to a manually involved lamellar dissection within the cornea and smooth extracting of the corneal lenticule. As a result the initial learning curve of the surgeon is steeper and intraoperative complications during SMILE like unsuccessful lenticule removal or retention of corneal lenticule fragments may occur more often during the initial learning curve.<sup>5</sup>

### 2. Case report

A 26-year old healthy woman underwent SMILE on the right eye with a preoperative refraction of  $-4.5/-0.25 \times 180^\circ$  on the right and of  $-4.25/-0.5 \times 170^\circ$  on the left eye. The procedure was planned and performed in another hospital.

Corrected distance visual acuity (CDVA) on both eyes was 0.00 logMAR. Scheimpflug tomography showed a corneal astigmatism with the rule of 1.8 dpt and central corneal thickness of  $577 \mu\text{m}$  without any signs of predisposition to corneal ectasia (Fig. 1A).

Treatment of the right eye was performed by using the Zeiss VisuMax laser system (Carl Zeiss Meditec, Germany). The Cap Diameter was 7.9 mm with an optical zone of 6.5 mm, pulse energy of 34 nJ, spot size of  $2 \mu\text{m}$  and corneal incision of 4.0 mm. Target was emmetropia.

The laser procedure itself was uneventful on the right eye. The surgeon then failed to separate the lenticule with a blunt spatula, although he tried several times. Therefore, he decided to leave the lenticule in its place. Postoperative corneal tomography of the right eye one day after surgery is shown in Fig. 1B. Temporal corneal flattening and displacement of the thinnest corneal point to the superotemporal quadrant is visible.

Two weeks after the first attempt the surgeon again performed an unsuccessful second attempt to remove the lenticule. This led to further corneal asymmetry and irregularity (Fig. 1C and D). Furthermore, clinical examination revealed scarring of the corneal stroma. As

\* Corresponding author. Department of ophthalmology, Ludwig-Maximilians-University, Mathildenstrasse 8, 80336, München, Germany.  
E-mail address: [wolfgang.j.mayer@med.uni-muenchen.de](mailto:wolfgang.j.mayer@med.uni-muenchen.de) (W.J. Mayer).

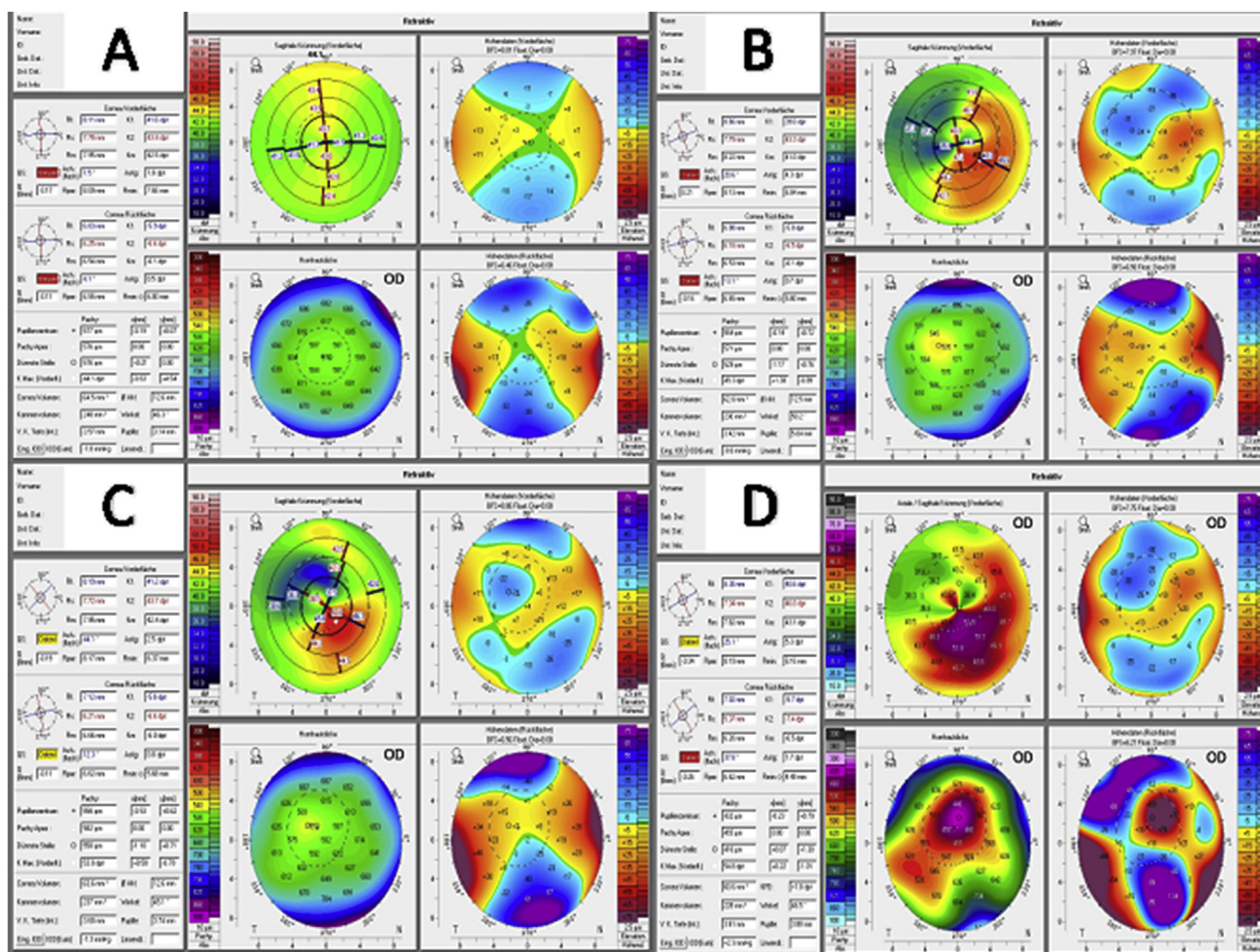


Fig. 1. Scheimpflug tomography of the right eye; A: Pentacam preoperative; B: Pentacam one day after SMILE procedure; C: Pentacam after unsuccessful lenticule extraction 2 weeks after SMILE procedure; D: Pentacam 8 weeks after SMILE procedure with further corneal asymmetry and irregularity due to scarring process.

scarring continued and visual acuity decreased, the patient decided to visit our hospital for a second opinion.

During our examination, we found deep corneal scarring particularly along the lenticule edge (Fig. 2A and B; Fig. 3). As scarring and tissue destruction was visible also at the Descemet membran we decided against a deep anterior lamellar keratoplasty and performed a penetrating keratoplasty.

The surgical procedure was performed without any intraoperative complications. Histological examination of the removed corneal tissue showed several epithelial cysts and diffuse corneal scarring (Fig. 2C and D). Postoperative follow up was uneventful. The transplant healed well into the recipient corneal tissue. The patient achieved an uncorrected distance visual acuity of 0.3 logMAR and corrected distance visual acuity of 0.1 logMAR after three months.

### 3. Discussion

Small incision lenticule extraction is a rather new laser ablative procedure and has, when being compared to Femto-LASIK, the advantages that the whole procedure can be performed using a single laser and only a very small incision is required. To remove the intrastromal lenticule the surgeon has to separate the lenticule manually from the remaining corneal stroma after it has been partially separated by the laser. Low magnitude refractive errors result in a thinner lenticule and are more difficult to separate than a thicker lenticule.<sup>6</sup> Especially for

rather inexperienced surgeons this step can cause complications such as partial extraction or a torn lenticule.

To achieve a smooth separation of the lenticule, identification and separation of the anterior lenticular surface with the dissector tool is very important. The right position of the dissector tool can be checked by the white ring sign located at the lenticule edge which results in a reflection of light from the lenticule side cut. If the white ring sign is interrupted by the dissector tool, the anterior plane is located and the lenticule can be separated. Multiple attempts to separate the different corneal layer and forceful extraction of the lenticule can cause damage to the stromal bed as described in our patient.

Instead of forcefully trying to perform the procedure in such a situation we advise to simply stop the procedure and wait for three months till most of the corneal healing process is finished and refractive stability is achieved. At this stage we would then advice to perform a femto-LASIK procedure in order not to have again the risk of not being able to separating the lenticule from the remaining corneal stroma.

A possible option during the initial SMILE procedure in the case presented here, and alternative for intraoperative complications during SMILE procedure is the CIRCLE cap-to-flap technique. The CIRCLE software of the Zeiss VisuMax platform is specifically developed for enhancement and conversion of the SMILE cap into a full flap for LASIK-like excimer laser treatment.<sup>7</sup> In the case of an uncomplicated procedure with postoperative regression, surface ablation or, in the case of a suitable cap thickness, thin-flap LASIK are an alternative.<sup>8,9</sup>

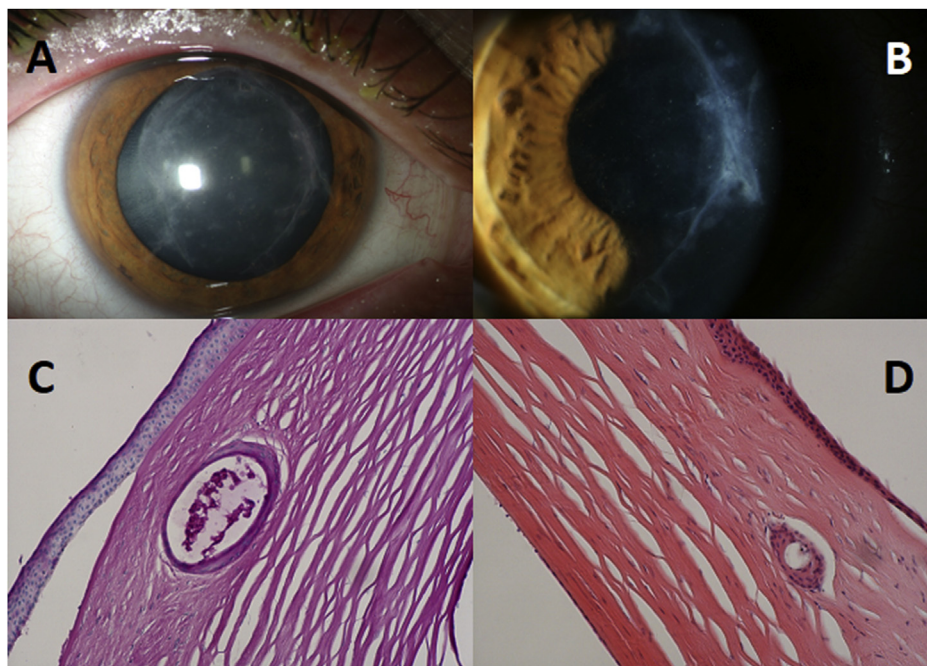


Fig. 2. A + B (Cornea photography at first presentation in our clinic): deep corneal scarring particularly along the lenticule edge; C + D Histological photography of the removed corneal tissue with intrastromal epithelial cysts and scarring.

Kim et al.<sup>10</sup> reported a similar case in which not lenticule extraction was the problem but incision failure. They found that conjunctivochalasis was the most likely cause for this failure but were successful with continuing the procedure by performing the incision manually, this was unfortunately not the case in our patient.

The challenges in SMILE, especially during the first 50 cases was already described by Titiyal et al.<sup>11</sup> They identified the lenticule dissection and extraction as being the most challenging parts of the procedure, which is in line with our case. In total they observed a difficult lenticule extraction in 9% of all cases. Similarly, Ramirez-Miranda et al. reported in a study that inexperience with the procedure is the most likely source for complications during SMILE and that after a learning period these kinds of complications would drop significantly.<sup>12</sup>

We believe that several surgeries should be performed in wet labs and an experienced surgeon should be observing the procedure for the first 50 cases in order to reduce the risk of complications during lenticule dissection and extraction. This approach would substantially

improve the results and prevent similar complications as described in this case.

**Funding**

No funding or grant support.

**Patient consent**

Written consent to publish this case has not been obtained. This report does not contain any personal identifying information.

**Authorship**

All authors attest that they meet the current ICMJE criteria for Authorship.

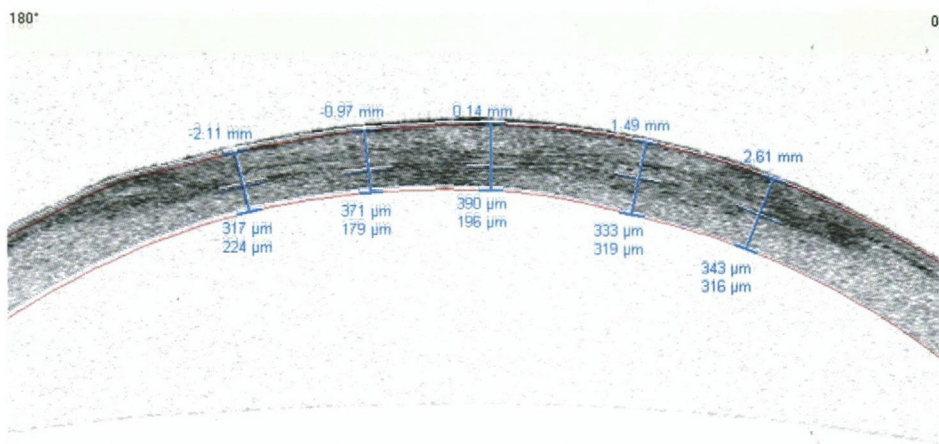


Fig. 3. Cornea OCT 8 weeks after SMILE procedure (scanned, performed externally): deep stromal to pre-descemet scar formation, especially central and along the edge area.

## Declaration of competing interest

All authors have no financial disclosures.

## Acknowledgements

None.

## References

1. Sekundo W, Kunert KS, Blum M. Small incision corneal refractive surgery using the small incision lenticule extraction (SMILE) procedure for the correction of myopia and myopic astigmatism: results of a 6 month prospective study. *Br J Ophthalmol*. 2011;95(3):335–339.
2. Kobashi H, Kamiya K, Shimizu K. Dry eye after small incision lenticule extraction and femtosecond laser-assisted LASIK: meta-analysis. *Cornea*. 2017;36(1):85–91.
3. Wu D, Wang Y, Zhang L, Wei S, Tang X. Corneal biomechanical effects: small-incision lenticule extraction versus femtosecond laser-assisted laser in situ keratomileusis. *J Cataract Refract Surg*. 2014;40(6):954–962.
4. Bansal AK, Murthy SI, Maaz SM, Sachdev MS. Shifting “ectasia”: interface fluid collection after small incision lenticule extraction (SMILE). *J Refract Surg*. 2016;32(11):773–775.
5. Kim TI, Alio Del Barrio JL, Wilkins M, Cochener B, Ang M. Refractive surgery. *Lancet*. 2019;393(10185):2085–2098.
6. Shetty R, Negalur N, Shroff R, Deshpande K, Jayadev C. Cap lenticular adhesion during small incision lenticular extraction surgery: causative factors and outcomes. *Asia Pac J Ophthalmol (Phila)*. 2017;6(3):233–237.
7. Siedlecki J, Luft N, Mayer WJ, et al. CIRCLE enhancement after myopic SMILE. *J Refract Surg*. 1995;34(5):304–309 Thorofare, NJ.
8. Beerthuis JJ, Siebelt E. Surface ablation after laser in situ keratomileusis: re-treatment on the flap. *J Cataract Refract Surg*. 2007;33(8):1376–1380.
9. Reinstein DZ, Carp GI, Archer TJ, Vida RS. Inferior pseudo-hinge fulcrum technique and intraoperative complications of laser in situ keratomileusis retreatment after small-incision lenticule extraction. *J Cataract Refract Surg*. 2018;44(11):1355–1362.
10. Kim BK, Mun SJ, Lee DG, Choi HT, Chung YT. Management of incision failure during small incision lenticule extraction because of conjunctivochalasis. *Am J Ophthalmol Case Rep*. 2017;7:134–137.
11. Titiyal JS, Kaur M, Rathi A, Falera R, Chaniyara M, Sharma N. Learning curve of small incision lenticule extraction: challenges and complications. *Cornea*. 2017;36(11):1377–1382.
12. Ramirez-Miranda A, Ramirez-Luquin T, Navas A, Graue-Hernandez EO. Refractive lenticule extraction complications. *Cornea*. 2015;34(Suppl 10):S65–S67.