

[ CASE REPORT ]

## Immunotherapy-responsive Non-paraneoplastic Encephalitis with Antibodies against GAD, LGI1, and GABA<sub>A</sub> Receptor

Takahiro Nakano<sup>1</sup>, Norio Chihara<sup>1</sup>, Kento Matoba<sup>1</sup>, Hisatsugu Tachibana<sup>1</sup>, Shiho Okuda<sup>2</sup>, Yoshihisa Otsuka<sup>1</sup>, Takehiro Ueda<sup>1</sup>, Kenji Sekiguchi<sup>1</sup>, Hisatomo Kowa<sup>3</sup>, Frank Leyboldt<sup>4</sup>, Klaus-Peter Wandinger<sup>4</sup> and Riki Matsumoto<sup>1</sup>

### Abstract:

A 62-year-old man showed abnormal behavior. Brain magnetic resonance imaging revealed multifocal lesions on T2-weighted images. Initial screening revealed that he was seropositive for antibodies against glutamate decarboxylase, which usually indicates treatment resistance to autoimmune encephalitis (AE). Intensive immunosuppressive therapies, however, improved the neurological symptoms. In line with this, we also detected seropositivity for antibodies against leucine-rich glioma-inactivated 1 and gamma-aminobutyric acid A receptor (GABA<sub>A</sub>R). Brain imaging and treatment responsiveness suggested that antibodies against GABA<sub>A</sub>R were the main cause of symptoms. Furthermore, the patient showed the presence of triple anti-neural antibodies in the absence of malignancy and had a favorable clinical course.

**Key words:** autoimmune encephalitis, plasma exchange, anti-GAD antibody, anti-LGI1 antibody, anti-GABA<sub>A</sub>R antibody

(Intern Med 61: 419-423, 2022)

(DOI: 10.2169/internalmedicine.7846-21)

### Introduction

Autoimmune encephalitis (AE) is a group of inflammatory diseases of the central nervous system that present with anti-neuronal auto-antibodies and exhibit a variety of neurological and psychiatric symptoms (1). Emerging anti-neuronal antibody discovery has promoted our understanding of the pathogenesis of this rare but important disease (2). AE associated with anti-glutamate decarboxylase (GAD) antibody has been reported as a treatment-resistant AE, characterized by cognitive impairment and epilepsy (3). In such circumstances, patients respond best to immunosuppressive treatment (4).

We herein report a patient who was seropositive for antibodies against GAD as well as against leucine-rich glioma-inactivated 1 (LGI1) and gamma-aminobutyric acid A receptor (GABA<sub>A</sub>R) in the absence of malignancy but had a fa-

vorable course following intensive immunotherapy.

### Case Report

A 62-year-old right-handed man was admitted to our hospital with behavioral alterations and seizures. The patient had been in his usual state of health until six months before admission, when his cognition began declining gradually. Ten days before admission to our hospital, he suffered from a convulsive seizure involving the left side of his body. He had no medical history of diabetes, and there was no mention of it in his family history. He also did not have any history of smoking and drinking.

On an examination, his body temperature was 35.7°C, while his other vitals were stable. On a neurological assessment, the patient showed Glasgow Coma Scale E4V4M6, motor aphasia, frontal lobe dysfunctions, and bilateral pyramidal tract signs. There were no facio-brachial dystonic

<sup>1</sup>Division of Neurology, Kobe University Graduate School of Medicine, Japan, <sup>2</sup>Department of Neurology, Hyogo Rehabilitation Center Hospital, Japan, <sup>3</sup>Department of Rehabilitation Science, Kobe University Graduate School of Health Sciences, Japan and <sup>4</sup>Institute of Clinical Chemistry, University Hospital Schleswig-Holstein, Germany

Received: April 29, 2021; Accepted: June 7, 2021; Advance Publication by J-STAGE: July 30, 2021

Correspondence to Dr. Norio Chihara, chiharan@med.kobe-u.ac.jp

seizures. On admission, blood tests did not show hyponatremia or thyroid dysfunction. Furthermore, his serum was positive for anti-GAD-antibody (anti-GAD Ab) with a high titer (155,000 U/mL, normal <5.0 U/mL). A viral antibody work-up was seropositive for both herpes simplex virus 1 (HSV1) IgM (1.16: enzyme immunoassay, normal <0.8) and HSV1 IgG antibodies (111.1: enzyme immunoassay, normal <2.0). His cerebrospinal fluid (CSF) showed normal cell numbers and total protein and glucose levels. The IgG index was 0.38 (normal), and no CSF-specific oligoclonal IgG bands were detected. HSV1 DNA was not detected by polymerase chain reaction. The anti-GAD Ab titer was 4,460 U/mL in the CSF. The index for the intrathecal synthesis of anti-GAD Ab was calculated using the following formula: [CSF anti-GAD Ab titer/serum anti-GAD Ab titer]/[CSF albumin level/serum albumin level] (5). An index value higher than 1 strongly indicates intrathecal synthesis; this patient showed an index value of 3.12.

Indirect immunohistochemistry using the CSF and serum revealed a pattern indicating the presence of anti-GAD65 and anti-LGI1 Ab and hinted at the presence of another synaptic auto-antibody (Figure A). Cell-based assays for anti-LGI1 (Euroimmun, Lübeck, Germany) and anti-GABA<sub>A</sub>R Ab (University Hospital Schleswig-Holstein, Kiel and Lübeck, Germany) confirmed the presence of both with a low positive titer in serum (1:32), but these values were not found in the CSF. Findings for other known anti-neuronal auto-antibodies, including antibodies against N-methyl-D-aspartate receptor (NMDAR),  $\alpha$ -amino-3-hydroxy-5-methyl-4-isoxazole-propionic acid receptor, contactin-associated protein 2, Delta/Notch-like epidermal growth factor-related receptor, dipeptidyl-peptidase-like protein 6, gamma-aminobutyric acid B receptor, group 1 metabotropic glutamate receptor, IgLON5, Homer-3 (University Hospital Schleswig-Holstein), Hu, Yo, Ri, Ma, CV2, and amphiphysin (BML, Tokyo, Japan), were negative.

Brain magnetic resonance imaging (MRI) showed multiple hyperintense cortical and subcortical lesions in the bilateral frontal lobe and right parietal lobe on T2-weighted imaging (T2WI) as well as on fluid-attenuated inversion-recovery (FLAIR) images (Figure B) without contrast enhancement. On the third day after admission, electroencephalography (EEG) showed an almost continuous rhythmic delta activity in the bilateral frontopolar regions, dominant on the left side, suggesting the presence of interictal continuum or non-convulsive status epilepticus. On the fifth day, <sup>123</sup>I-iodoamphetamine single-photon emission computed tomography (SPECT) showed hyperperfusion in the bilateral orbitofrontal region, left temporal lobe, right parietal lobe, and right limbic area (Figure C). On the 15th day, a brain biopsy of the right orbitofrontal region, where MRI and SPECT both showed findings, was obtained, and non-specific reactive astrocytes were detected by immunohistochemistry without any evidence of a tumor, including lymphoma. On the 45th day following admission, whole-body fluorodeoxyglucose-positron emission tomography showed

no evidence of malignancy.

Intravenous high-dose methylprednisolone was followed by plasma exchange seven times, and then oral prednisolone treatment was started. He showed significant improvement with respect to brain lesions on MRI; his Mini-Mental State Examination score increased from at least 15 to 24, and his Modified Rankin Scale score decreased from 3 to 1. EEG epileptic discharges disappeared with the administration of an anti-epileptic drug. We were able to obtain sequential anti-GAD Ab titers in both the serum and CSF. Both titers gradually decreased over the treatment course, except for temporary disease flare-up before the start of intensive immunotherapy (Figure D). The finding for HSV1 IgM antibody was negative (<0.80) after treatment.

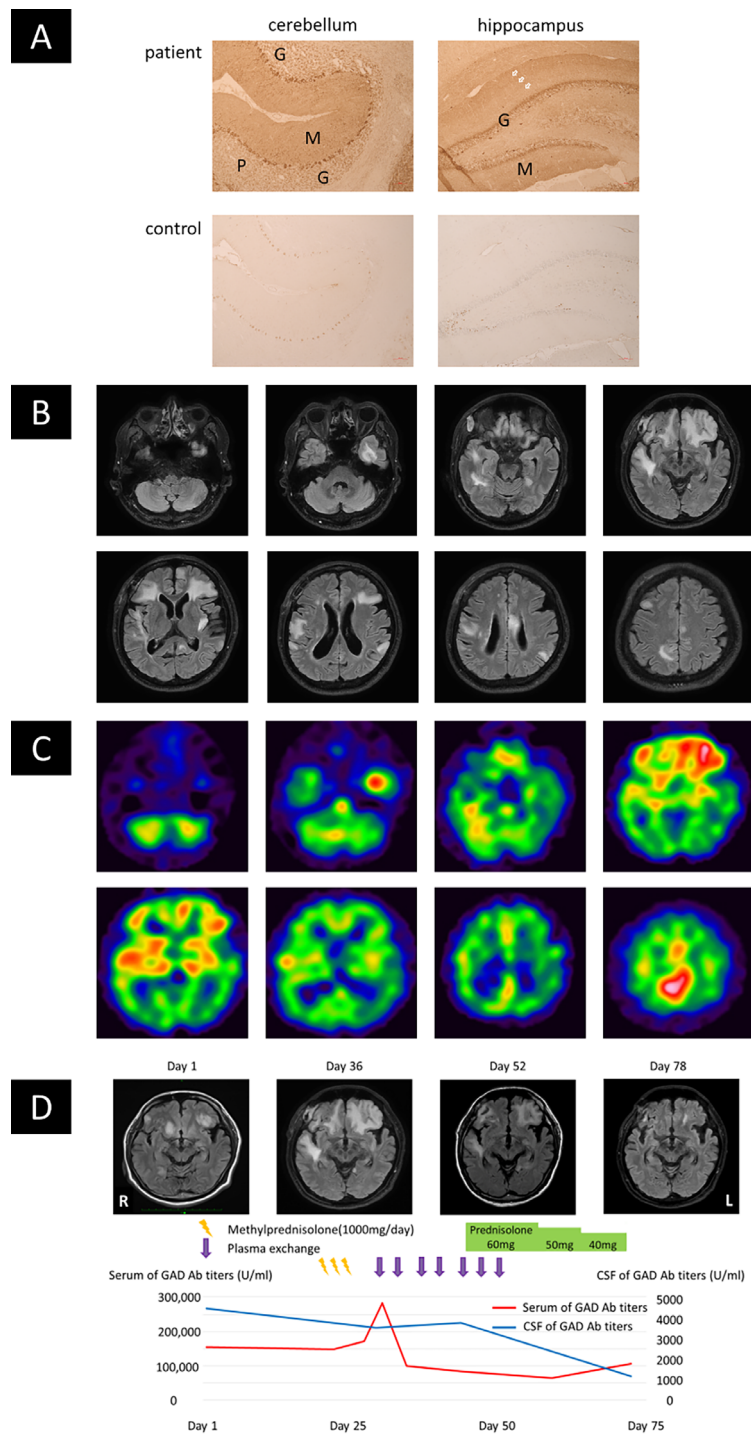
## Discussion

Although patients with AE associated with high titers of anti-GAD Ab frequently suffer from treatment-resistant seizures and cognitive impairment (3), some reports have documented a favorable response to immunotherapy for patients that presented with mainly extra-limbic signs and symptoms. This suggests the co-existence of other antibodies against cell-surface antigens or synaptic proteins. In the present study, the patient showed extra-limbic clinical as well as imaging manifestations, while rat brain immunohistochemistry and cell-based assays confirmed the co-presence of anti-GABA<sub>A</sub>R Ab and anti-LGI1 Ab.

Anti-GABA<sub>A</sub>R Ab is a recently identified anti-neural auto-antibody that has been associated with AE. The main symptoms are seizure, cognitive impairment, altered behavior, and a decreased level of consciousness. The CSF was normal in 42% of the patients. Typical brain MRI findings are extensive multifocal abnormalities on FLAIR and T2WI, which involve both the cortex and subcortical white matter, usually without contrast enhancement. These MRI findings are important not only because they are frequently observed in patients with anti-GABA<sub>A</sub>R Ab-associated encephalitis (77% of all cases) but also because they are rarely observed in patients with other forms of autoimmune encephalitis (6).

Anti-LGI1 Ab-associated encephalitis has the following clinical features: subtle focal and facio-brachial dystonic seizures mostly occurring before the onset of memory disturbance. Initial MRI findings show hippocampal T2 hyperintensity (7).

Table shows several case reports of AE with the occurrence of multiple antibodies, including anti-GABA<sub>A</sub>R Ab (2, 8-12); of these cases, three showed invasive thymoma. In the current study, immunotherapy was found to be effective, and brain MRI showed multifocal signal abnormalities. We therefore believe that anti-GABA<sub>A</sub>R Ab was the main cause of this patient's AE. The present patient was unique since he, in the absence of any malignancy, developed triple positivity for antibodies against GABA<sub>A</sub>R, LGI1, and GAD. It has been reported previously that HSV-encephalopathy triggers an immune response that leads to



**Figure.** Immunohistochemistry and imaging findings along with treatment course. (A) Indirect immunohistochemistry for human IgG on cerebellar (left) and hippocampal (right) regions of sagittal rat brain sections using patient (upper row) or control CSF (lower row) is shown. Staining pattern is reminiscent of a combination of GAD65, LGI1, and GABA<sub>A</sub>R-specific staining: typical staining of cerebellar and hippocampal granule cell layer (GAD65, labeled G), cerebellar and hippocampal molecular layer (labeled M), mostly dominant in the outer hippocampal molecular layer (LGI1, arrows), yet more blurred presumably by the coexisting GABA<sub>A</sub>R-antibodies. M: molecular layer and G: granule cell layer. 10× magnification. (B) Axial FLAIR images at peak of the disease show multiple hyperintense bilateral cortical and subcortical lesions on the 36th day after admission. (C) <sup>123</sup>I-IMP SPECT shows an increase in cerebral blood flow in the bilateral orbitofrontal region. Regions: left temporal lobe, right parietal lobe, and right limbic area. (D) GAD-Ab titer and MRI (FLAIR) findings along the treatment course. After a high dose of intravenous methyl-prednisolone therapy and plasma exchanges, the images show improvement of widespread inflammatory lesions. The anti-GAD-Ab titers also showed improvement.

**Table. Clinical Features of Patients with Encephalitis and Multiple Anti-neural Antibodies.**

Ref.	8	9	10	11	12	Present case
Age (years)	46	59	38	78	45	62
Sex (M/F)	M	F	F	F	F	M
anti-neural antibodies	GABAAR/LGI1	GABAAR/CASPR2	GABAAR/GAD	GABAAR/VGKC	GABAAR/LGI1	GABAAR/LGI1/GAD
Symptoms	Aphasia, visual hallucination, and generalized seizures with delirium	Amnesia and disorientation	Dysgeusia and dysosmia	Akinetic mutism	Memory loss, confabulation, and behavioral changes	Cognitive decline and convulsive seizure
Brain MRI (T2WI)	Multifocal lesions	Multifocal lesions (the medial temporal lobe, insular cortex, frontobasal cortex and cingulate gyrus)	Multifocal lesions (the right temporal lobe, both frontal lobes, and parasagittal area)	Multifocal lesions	Multifocal lesions (extensive mesial temporal lobe)	Multifocal lesions (the bilateral frontal lobes and right parietal lobe)
Tumor	Invasive thymoma	Invasive thymoma	No malignancy	No malignancy	Invasive thymoma	No malignancy
Treatment	Corticosteroids, IVIg, and AED	Chemotherapy for thymoma	Corticosteroids, IVIg, and AED	Corticosteroids, IVIg, and AED	Corticosteroids and plasma exchange	Corticosteroids, plasma exchange, and AED
Outcome	Epileptic seizures disappeared; Cognitive impairment and psychological symptoms remained	Mental state partially improved	Epileptic seizures disappeared; Consciousness gradually improved	Epileptic seizures disappeared; Cognitive impairment remained	Brain MRI showed resolution of all lesions; Neurologic function mostly recovered	Brain MRI lesions and epileptic seizures disappeared; Cognitive impairment remained

GABAAR: gamma-aminobutyric acid A receptor, LGI1: leucine-rich glioma-inactivated 1, CASPR2: contactin-associated protein-like 2, GAD: glutamic acid decarboxylase, VGKC: voltage-gated potassium channel, IVIg: intravenous immunoglobulin, AED: antiepileptic drug

AE associated with the presence of anti-NMDAR Ab (13). Based on the transient presence of HSV1 IgM antibodies in the serum, it is tempting to speculate that the present patient developed triple autoantibody seropositivity due to occult HSV infection. However, the cause of the triple antibody positivity is not precisely known. The accumulation of further cases and immunological investigations is warranted to elucidate the pathomechanism of this rare case. One limitation of this study was that we did not search for surface binding on unpermeabilized cultured hippocampal neurons, which may have provided further information on the pathology.

Appropriate and intense treatment is important for achieving a good prognosis for AE. A systematic review of studies on plasma exchange in pediatric encephalitis associated with anti-NMDAR Ab showed a trend towards a better outcome when plasma exchange was administered early and in combination with steroids (14). In the present patient, the clinical symptoms and brain MRI abnormalities largely disappeared with intensive immunotherapy. Initial screening using blood tests revealed seropositivity for antibodies against GAD. Even in the presence of high-titer anti-GAD Ab, intensive immunotherapy should be considered for treatment when MRI of the brain presents multifocal signal abnormalities. In cases of autoimmune encephalitis such as this, multiple autoantibodies may be present simultaneously, so it is necessary to screen patients for various autoantibodies to ensure an accurate diagnosis.

The authors state that they have no Conflict of Interest (COI).

## References

- Blaabjerg M, Seifert-Held T, Sellner J. Editorial: emerging challenges in the diagnosis and treatment of autoimmune encephalitis. *Front Neurol* **10**: 146-999, 2019.
- Ohkawa T, Satake S, Yokoi N, et al. Identification and characterization of GABA (A) receptor autoantibodies in autoimmune encephalitis. *J Neurosci: the official journal of the Society for Neuroscience* **34**: 8151-8163, 2014.
- Malter MP, Helmstaedter C, Urbach H, Vincent A, Bien CG. Antibodies to glutamic acid decarboxylase define a form of limbic encephalitis. *Ann Neurol* **67**: 470-478, 2010.
- Najjar S, Pearlman D, Najjar A, Ghiasian V, Zagzag D, Devinsky O. Extralimbic autoimmune encephalitis associated with glutamic acid decarboxylase antibodies: an underdiagnosed entity? *Epilepsy Behav* **21**: 306-313, 2011.
- Saiz A, Blanco Y, Sabater L, et al. Spectrum of neurological syndromes associated with glutamic acid decarboxylase antibodies: diagnostic clues for this association. *Brain* **131**: 2553-2563, 2008.
- Spatola M, Petit-Pedrol M, Simabukuro MM, et al. Investigations in GABA (A) receptor antibody-associated encephalitis. *Neurology* **88**: 1012-1020, 2017.
- van Sonderen A, Thijs RD, Coenders EC, et al. Anti-LGI1 encephalitis: clinical syndrome and long-term follow-up. *Neurology* **87**: 1449-1456, 2016.
- Miyazaki Y, Hirayama M, Watanabe H, et al. Paraneoplastic encephalitis associated with myasthenia gravis and malignant thymoma. *J Clin Neurosci* **19**: 336-338, 2012.
- Ohshita T, Kawakami H, Maruyama H, Kohriyama T, Arimura K, Matsumoto M. Voltage-gated potassium channel antibodies associated limbic encephalitis in a patient with invasive thymoma. *J Neurol Sci* **250**: 167-169, 2006.
- Gagnon MM, Savard M, Mourabit Amari K. Refractory status epilepticus and autoimmune encephalitis with GABAAR and GAD65 antibodies: A case report. *Seizure* **37**: 25-27, 2016.

11. Fukami Y, Okada H, Yoshida M, Yamaguchi K. [Successful combination immunotherapy of anti-gamma aminobutyric acid (GABA) (A) receptor antibody-positive encephalitis with extensive multifocal brain lesions]. *Rinsho Shinkeigaku* **57**: 436-440, 2017 (in Japanese).
12. Simabukuro MM, Petit-Pedrol M, Castro LH, et al. GABAA receptor and LGII antibody encephalitis in a patient with thymoma. *Neurol Neuroimmunol Neuroinflamm* **2**: e73, 2015.
13. Armangue T, Spatola M, Vlasea A, et al. Frequency, symptoms, risk factors, and outcomes of autoimmune encephalitis after herpes simplex encephalitis: a prospective observational study and retrospective analysis. *Lancet Neurol* **17**: 760-772, 2018.
14. Suppiej A, Nosadini M, Zuliani L, et al. Plasma exchange in pediatric anti-NMDAR encephalitis: a systematic review. *Brain & development* **38**: 613-622, 2016.

The Internal Medicine is an Open Access journal distributed under the Creative Commons Attribution-NonCommercial-NoDerivatives 4.0 International License. To view the details of this license, please visit (<https://creativecommons.org/licenses/by-nc-nd/4.0/>).

---

© 2022 The Japanese Society of Internal Medicine  
*Intern Med* 61: 419-423, 2022