

Technical Note

Long segment spinal epidural extramedullary hematopoiesis

Kanwaljeet Garg, Pankaj Kumar Singh, Manmohan Singh, P. Sarat Chandra, Bhawani Shankar Sharma

Department of Neurosurgery, All India Institute of Medical Sciences, New Delhi, India

E-mail: Kanwaljeet Garg - gargneuro@hotmail.com; *Pankaj Kumar Singh - drpankajsingh11@gmail.com; Manmohan Singh - manmohan1972@gmail.com; Sarat P. Chandra - saratchandra3@gmail.com; Bhawani Shankar Sharma - drsharmabs@yahoo.com

*Corresponding author

Received: 08 October 13 Accepted: 11 November 13 Published: 26 December 13

This article may be cited as:

Garg K, Singh PK, Singh M, Chandra PS. Long segment spinal epidural extramedullary hematopoiesis. *Surg Neurol Int* 2013;4:161.

Available FREE in open access from: <http://www.surgicalneurologyint.com/text.asp?2013/4/1/161/123657>

Copyright: © 2013 Garg K. This is an open-access article distributed under the terms of the Creative Commons Attribution License, which permits unrestricted use, distribution, and reproduction in any medium, provided the original author and source are credited.

Abstract

Background: Extramedullary hematopoiesis is defined as the formation of blood cells outside the bone marrow. It is a common manifestation of many chronic hemolytic anemias, and typically involves the liver, spleen, and lymph nodes. Only rarely is the spinal epidural space involved.

Methods: We describe a 25-year-old male, known to have thalassemia intermedia, who presented with a 1-month history of stiffness and weakness in both lower extremities. On physical examination, he had palpable splenomegaly accompanied by spinal tenderness at the D5 level, weakness in both lower extremities, hyperactive bilateral Patellar and Achilles reflexes with bilateral Babinski responses, and a graded sensory loss to pin appreciation below D5.

Results: The magnetic resonance (MR) study revealed a posterior, isointense and soft tissue epidural mass extending from D2 to D12 on both the T1- and T2-weighted images. These findings were consistent with the diagnosis of "red marrow," and long-segment spinal epidural extramedullary hematopoiesis.

Conclusions: Although extramedullary hematopoiesis is rarely encountered within the spinal canal, it should be considered among the differential diagnoses when a posterior compressive thoracic lesion contributes to myelopathy in a patient with a history of thalassemia intermedia and the accompanying chronic hemolytic anemia.

Key Words: Extramedullary hematopoiesis, epidural, thalassemia

Access this article online

Website:

www.surgicalneurologyint.com

DOI:

10.4103/2152-7806.123657

Quick Response Code:

INTRODUCTION

Although thalassemia, a form of chronic hemolytic anemia, is commonly associated with extramedullary hematopoiesis (EMH), it is only rarely encountered in the spinal epidural space. Here, we report a patient with spinal epidural EMH spanning 11 thoracic vertebral levels, D2 to D12.

CASE REPORT

Physical presentation and examination

A 25-year-old male with known thalassemia intermedia, who had never previously required a blood transfusion, presented with a 1-month history of stiffness and weakness in both lower extremities without accompanying sphincteric dysfunction. The general physical examination

revealed palpable splenomegaly, while the neurological assessment demonstrated localized tenderness over the D5 level, with attendant 4/5 weakness in both lower extremities, hyperactive bilateral Patellar and Achilles reflexes with bilateral Babinski responses, and a graded sensory loss to pin appreciation below D5.

Neurodiagnostic studies

The magnetic resonance imaging (MRI) of the thoracic spine revealed a posterior, isointense soft tissue epidural mass extending from D2 to D12 on both pulse sequences (T1, T2), suggestive of “red marrow” [Figures 1 and 2]. The cord appeared compressed anteriorly, thinned, and atrophic. The vertebral bodies displayed isointense to hypointense signals on both T1WI and T2WI images along with coarsening of the trabecular

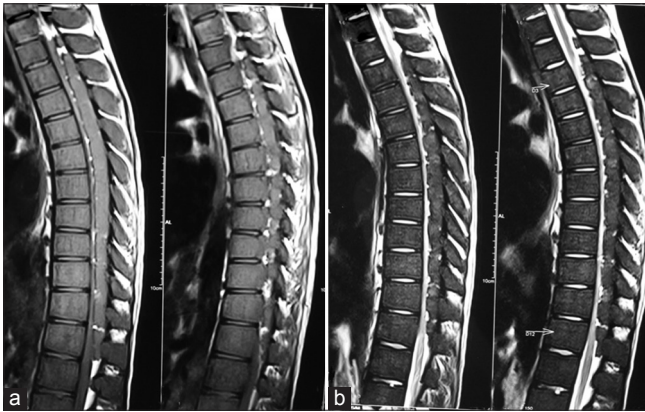

Figure 1: (a) MRI dorsal spine T1WI sagittal sections revealing an isointense epidural lesion posterior to the cord extending from D2 to D12, (b) MRI dorsal spine T2WI sagittal sections revealing an isointense to hyperintense epidural lesion posterior to the cord extending from D2 to D12. Note is also made of isointense to hypointense signal of vertebral bodies on both T1WI and T2WI along with coarsening of trabecular pattern, suggestive of hypercellular bone marrow

pattern; these findings suggested a hypercellular bone marrow consistent with EMH. Of interest, the cervical spine MR was normal.

Management

The patient was given multiple blood transfusions and it was decided to repeat a MRI after a period of 8 weeks and further treatment plan will be decided based on the MRI findings.

DISCUSSION

Review of the literature on EMH

EMH is a compensatory reaction, usually associated with chronic hemolytic anemias. It commonly involves the spleen, liver, lymph nodes, adrenal glands, and pleura.^[26,28] Although most patients with EMH are asymptomatic, rare involvement of the spinal epidural compartment may lead to spinal cord compression and myelopathy. Gatto^[8] first described this, while other cases studies cited the additional accompanying clinical and MR patterns of progressive lower thoracic spinal cord compression secondary to expansile epidural EMH.^[10,13,14,18,27,28] Salehi *et al.* reported EMH in a 34-year-old male patient with known beta thalassemia.^[26] They also reviewed 56 cases described in literature till 2001 and found that out of those 56, 42 cases were due to thalassemia. Only five patients had paraplegia in their study and none of them had thalassemia.

Issargisil *et al.*^[10] studied 12 patients with thalassemia who had spinal cord compression attributed to EMH; these cases involved the lower thoracic region (the commonest location of involvement). Mancuso *et al.* reported a 15-year-old thalassemia patient presenting with cauda equina syndrome as a result of cauda equina compression

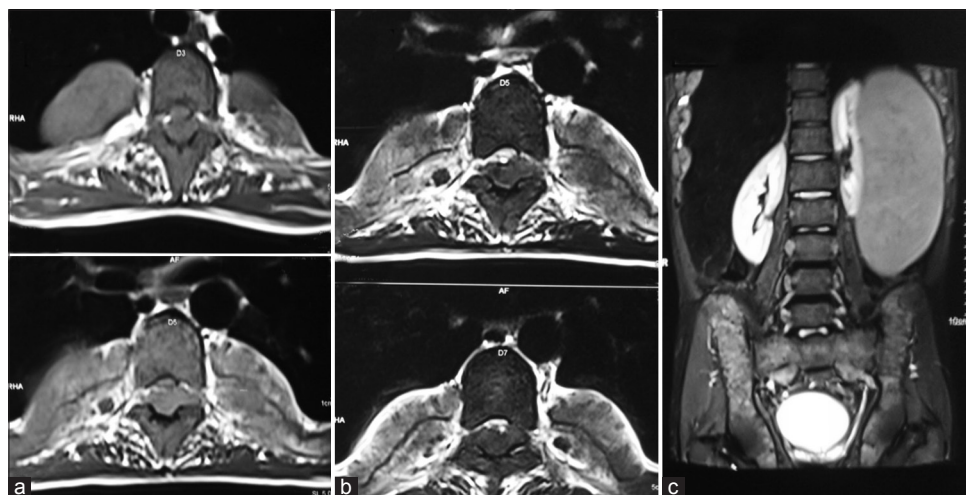


Figure 2: (a and b) MRI dorsal spine T1WI and T2WI axial sections revealing an isointense epidural lesion posterior to the cord causing severe cord compression, (c) MRI abdomen T2WI coronal section revealing splenomegaly

due to EMH.^[16] The incidence of EMH was reported to be 15% in patients with homozygous beta-thalassemia who received regular blood transfusions.^[4,6,17,23] In the literature review of Martina *et al.*,^[17] male to female ratio was 2.5:1 and most of the affected patients were within 15-45 years of age. The site of compression was the thoracic region in all cases in their series, as seen in our patient.

EMH is diagnosed on the basis of clinical and radiological findings. Symptoms and signs suggestive of compressive myelopathy in a patient with chronic hemolytic anemia should alert one regarding the possible spinal cord compression as a result of EMH.

EMH appears as a lobulated, well defined, and homogenous to heterogeneous soft-tissue mass on computed tomography (CT).^[20] Usually there is no evidence of calcification, and bony changes like widening of the medullary cavities of the ribs and coarsening of the trabecular pattern can be appreciated on CT. MRI has now replaced CT as the radiological investigation of choice due to its better soft tissue resolution. EMH appears as a lobular well circumscribed mass and active lesions have an intermediate intensity on both T1- and T2-weighted images and there is no or minimal enhancement following contrast administration.^[9] The important differential diagnoses include lymphoma, myeloma, and metastases. The lack of intense contrast enhancement differentiates EMH from other differentials.

Pathogenesis and management

Although the pathogenesis remains controversial and it is proposed that EMH might originate from the stimulation of embryonic rests in the epidural space or it may be a direct extension of the bone marrow.^[17,23] The treatment options include blood transfusion, surgical decompression, agents like hydroxyurea and radiotherapy.^[26] Various authors in literature have supported each of these modalities^[11,24,27] but there is no study comparing each of these modalities due to lack of enough number of cases.

Some authors have used blood transfusion as the sole therapy and have reported improvement of symptoms^[10,19,24] but improvement is usually incomplete.^[3] Blood transfusion acts by down regulating the erythropoietin production. However, it is to be kept in mind that blood transfusion is not completely free of risks and can result in transmission of infections. Patients with mild spinal cord compression can be managed by blood transfusions and more often it is used in combination with other modalities like surgery or radiotherapy.^[2,12,25] Few authors have also used cytostatic agents like hydroxyurea in combination with transfusion.^[7]

Surgical decompression provides immediate decompression of the cord but at the cost of massive bleeding and has been used by various authors.^[1,5,11,20,22] In patients presenting with paraplegia as a result of severe cord compression, surgical decompression may provide benefit to the patient.

Radiotherapy has also been advocated by many authors and has been proposed to halt the overproduction of the overgrown marrow.^[18] Malik *et al.* managed a patient of thalassemia intermedia with paraplegia with radiotherapy alone.^[15] There might be initial worsening with radiotherapy due to increased cord edema, and steroids can control the edema.^[29] Low doses of radiation usually do suffice due to radiosensitivity of the hematopoietic tissue. Good results with recurrence rates of about 19% have been reported with radiotherapy alone in the literature.^[21]

In the literature review by Salehi,^[26] 8 patients were managed by surgery alone, while 23 patients with radiotherapy alone. Nineteen patients were managed by a combination of therapies, including various surgery, radiotherapy, blood transfusion, phlebotomy, or steroids.

REFERENCES

1. Ahmed F, Tobin MS, Cohen DF, Gomez-Leon G. Beta thalassemia. Spinal cord compression. *NY State J Med* 1981;81:1505-8.
2. Chehal A, Aoun E, Koussa S, Skoury H, Koussa S, Taher A. Hypertransfusion: A successful method of treatment in thalassemia intermedia patients with spinal cord compression secondary to extramedullary hematopoiesis. *Spine* 2003;28:e245-9.
3. Coskun E, Keskin A, Suzer T, Sermez Y, Kildaci T, Tahta K. Spinal cord compression secondary to extramedullary hematopoiesis in thalassemia intermedia. *Eur Spine J* 1998;7:501-4.
4. Dore F, Pardini S, Gaviano E, Longinotti M, Bonfigli S, Rovasio S, *et al.* Recurrence of spinal cord compression from extramedullary hematopoiesis in thalassemia intermedia treated with low doses of radiotherapy. *Am J Hematol* 1993;44:148.
5. Dragean CA, Duquesne L, Theate I, Ghaye B, Coche EE. Extramedullary haemopoiesis and spinal cord compression. *Lancet* 2011;377:251.
6. Francesconi M, Vadala G, Franchini P, Cecchini A, Nappi G. Extramedullary hematopoiesis in homozygous thalassemia. A tomographic study of a case treated with radiotherapy. *Acta Neurol* 1981;3:602-5.
7. Gamberini MR, Fortini M, De Sanctis V. Paraplegia due to spinal cord compression by extramedullary erythropoietic tissue in a thalassaemia intermedia patient with gynecomastia secondary to cirrhosis: Successful treatment with hydroxyurea. *Pediatr Endocrinol Rev* 2004;2 Suppl 2:316-8.
8. Gatto I, Terrana V, Biondi L. Compression of the spinal cord due to proliferation of bone marrow in epidural space in a splenectomized person with Cooley's disease. *Haematologica* 1954;38:61-76.
9. Haidar R, Mhaidli H, Taher AT. Paraspinal extramedullary hematopoiesis in patients with thalassemia intermedia. *Eur Spine J* 2010;19:871-8.
10. Issaragrisil S, Piankigagum A, Wasi P. Spinal cord compression in thalassemia. Report of 12 cases and recommendations for treatment. *Arch Intern Med* 1981;141:1033-6.
11. Lau SK, Chan CK, Chow YY. Cord compression due to extramedullary hemopoiesis in a patient with thalassemia. *Spine* 1994;19:2467-70.
12. Lee AC, Chiu W, Tai KS, Wong V, Peh WC, Lau YL. Hypertransfusion for spinal cord compression secondary to extramedullary hematopoiesis. *Pediatr Hematol Oncol* 1996;13:89-94.
13. Luitjes WF, Braakman R, Abels J. Spinal cord compression in a new homozygous variant of beta-thalassemia. Case report. *J Neurosurg* 1982;57:846-8.
14. Luyendijk W, Went L, Schaad HD. Spinal cord compression due to extramedullary

- hematopoiesis in homozygous thalassemia. Case report. *J Neurosurg* 1975;42:212-6.
15. Malik M, Pillai LS, Gogia N, Puri T, Mahapatra M, Sharma DN, et al. Paraplegia due to extramedullary hematopoiesis in thalassemia treated successfully with radiation therapy. *Haematologica* 2007;92:e28-30.
 16. Mancuso P, Zingale A, Basile L, Chiamonte I, Tropea R. Cauda equina compression syndrome in a patient affected by thalassemia intermedia: Complete regression with blood transfusion therapy. *Childs Nerv Syst* 1993;9:440-1.
 17. Martina IS, van Doorn PA. Spinal cord compression due to extramedullary haematopoiesis in thalassaemia: A case report and review of the literature. *J Neurol* 1996;243:364-6.
 18. Mattei TA, Higgins M, Joseph F, Mendel E. Ectopic extramedullary hematopoiesis: Evaluation and treatment of a rare and benign paraspinal/epidural tumor. *J Neurosurg Spine* 2013;18:236-42.
 19. Moncef B, Hafedh J. Management of spinal cord compression caused by extramedullary hematopoiesis in beta-thalassemia. *Intern Med* 2008;47:1125-8.
 20. Monti L, Romano DG, Gozzetti A, Di Pietro G, Miracco C, Cerase A. Myelodysplasia presenting as thoracic spinal epidural extramedullary hematopoiesis: A rare treatable cause of spinal cord myelopathy. *Skeletal Radiol* 2012;41:611-4.
 21. Munn RK, Kramer CA, Arnold SM. Spinal cord compression due to extramedullary hematopoiesis in beta-thalassemia intermedia. *Int J Radiat Oncol Biol Phys* 1998;42:607-9.
 22. Oustwani MB, Kurtides ES, Christ M, Ciric I. Spinal cord compression with paraplegia in myelofibrosis. *Arch Neurol* 1980;37:389-90.
 23. Papavasiliou C, Gouliamos A, Andreou J. The marrow heterotopia in thalassemia. *Eur J Radiol* 1986;6:92-6.
 24. Parsa K, Oreizy A. Nonsurgical approach to paraparesis due to extramedullary hematopoiesis. Report of two cases. *J Neurosurg* 1995;82:657-60.
 25. Phupong V, Uerpaiojkij B, Limpongsanurak S. Spinal cord compression: A rareness in pregnant thalassemic woman. *J Obstet Gynaecol Res* 2000;26:117-20.
 26. Salehi SA, Koski T, Ondra SL. Spinal cord compression in beta-thalassemia: Case report and review of the literature. *Spinal Cord* 2004;42:117-23.
 27. Singhal S, Sharma S, Dixit S, De S, Chander S, Rath GK, et al. The role of radiation therapy in the management of spinal cord compression due to extramedullary haematopoiesis in thalassaemia. *J Neurol Neurosurg Psychiatry* 1992;55:310-2.
 28. Soman S, Rosenfeld DL, Roychowdhury S, Drachtman RA, Cohler A. Cord compression due to extramedullary hematopoiesis in an adolescent with known beta thalassemia major. *J Radiol Case Rep* 2009;3:17-22.
 29. Tan TC, Tsao J, Cheung FC. Extramedullary haemopoiesis in thalassemia intermedia presenting as paraplegia. *J Clin Neurosci* 2002;9:721-5.