



## Case report

## A leafy surprise: Case report of male breast malignant phyllodes

Ibtissam Bin Khalid<sup>\*</sup>, Muhammad Asad Parvaiz, Albash Sarwar, Omair Shahid Shaikh, Nida Javed, Arooj Fatima

Department of Surgical Oncology, Shaukat Khanum Memorial Cancer Hospital and Research Centre, 7A Block R-3, M.A. Johar Town, Lahore, Pakistan

## ARTICLE INFO

## Keywords:

Male  
Breast  
Malignant Phyllodes  
Case report

## ABSTRACT

**Introduction and importance:** Phyllodes tumor is a biphasic fibroepithelial tumor which accounts for less than 1% of all breast neoplasms. We aim to raise awareness among clinicians that a male breast lump may be indicative of underlying sinister pathology and therefore, should be investigated thoroughly.

**Case presentation:** A 62 year old male presented in clinic with right breast lump for the last 6 weeks. A preoperative diagnosis of spindle cell tumor was made on core needle biopsy. Neoadjuvant chemotherapy was administered in order to downsize the tumor as it was inseparable from underlying muscle. A post-operative diagnosis of malignant phyllodes was made following mastectomy. As the tumor was 1 mm from the deep margin, adjuvant radiotherapy was administered.

**Clinical discussion:** Differential diagnoses of malignant phyllodes include metaplastic carcinomas metastatic/primary sarcomas and fibroadenomas. Metaplastic carcinomas are morphologically heterogeneous and include adenosquamous carcinoma, squamous cell carcinoma and spindle cell carcinoma. In some malignant phyllodes, extensive stromal proliferation can make detection of epithelial component very difficult. This highlights the limitation of core biopsy in establishing an accurate preoperative diagnosis.

The standard treatment for phyllodes treatment is surgical resection with margins of 1 cm or more. Adjuvant radiotherapy is used in cases with threatened margins.

**Conclusion:** Malignant phyllodes tumor of breast can exist in men, and its accurate pre-operative diagnosis is difficult given the limitations of core biopsy. This case report draws attention to the challenges associated with the diagnosis of this rare condition and highlights the role of different treatment modalities in its management.

## 1. Introduction

The word phyllodes is derived from Greek word 'Phyllon', meaning 'leaf'. Phyllodes tumor is an uncommon biphasic fibroepithelial tumor. On account of its varying clinical and pathological characteristics, it is considered a spectrum of fibroepithelial neoplasms instead of a single disease [1]. Phyllodes tumors are classified into benign, borderline and malignant on the basis of their histological features. The latter type metastasizes hematogenously and can involve lungs, skeleton, heart and liver [2]. While Phyllodes tumors account for less than 1% of all breast neoplasms [1], occurrence of malignant Phyllodes in men is very rare and only a handful of such cases are reported in literature. Standard treatment for malignant Phyllodes is wide local excision with margins of 1 cm or more. A mastectomy may be necessary in large tumors. Recurrence is reported in less than 20% of cases with an earlier recurrence in malignant Phyllodes as compared to its benign counterpart [3]. We

report a very rare case of male breast malignant phyllodes involving the underlying pectoralis major muscle. The patient was managed by utilizing a variety of treatment modalities such as neoadjuvant chemotherapy, surgical resection and adjuvant radiotherapy. The case has been reported in accordance with SCARE 2020 criteria [4].

## 2. Case report

A 62 year old male school teacher presented at our institution with a complaint of painless right breast lump for the last 6 weeks. The patient had no comorbidities or family history of breast cancer. On examination, a 2.5 × 2.5 cm lump was palpable at 1 o'clock position in the right breast. It was not attached to overlying skin and axillary lymph nodes were not palpable. A heterogeneous lobulated lesion (Fig. 1), measuring 32 mm was detected in the upper inner quadrant of the right breast on ultrasound. On mammogram (Fig. 2), a partly circumscribed high

<sup>\*</sup> Corresponding author.

E-mail addresses: [ibtissambinkhalid@yahoo.com](mailto:ibtissambinkhalid@yahoo.com) (I.B. Khalid), [albashsarwar@skm.org.pk](mailto:albashsarwar@skm.org.pk) (A. Sarwar), [omairshahid@skm.org.pk](mailto:omairshahid@skm.org.pk) (O.S. Shaikh).

<https://doi.org/10.1016/j.ijscr.2021.106536>

Received 22 September 2021; Received in revised form 16 October 2021; Accepted 19 October 2021

Available online 23 October 2021

2210-2612/© 2021 The Authors. Published by Elsevier Ltd on behalf of IJS Publishing Group Ltd. This is an open access article under the CC BY-NC-ND license

(<http://creativecommons.org/licenses/by-nc-nd/4.0/>).

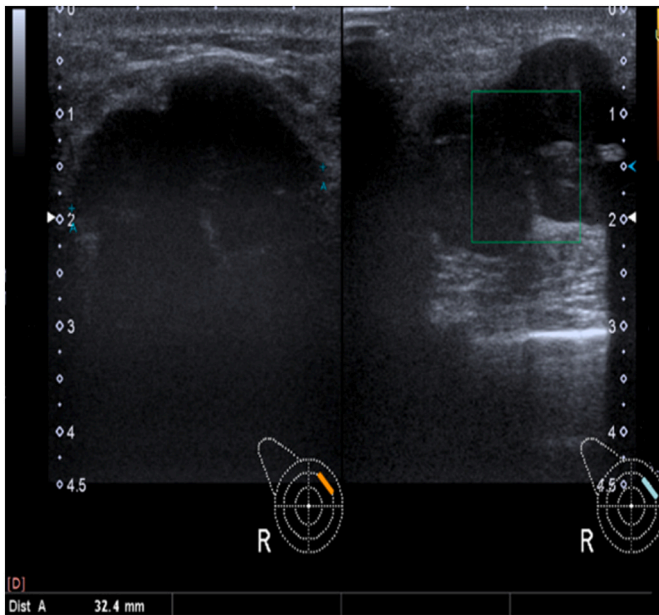


Fig. 1. A heterogeneous lobulated mass, measuring 32 mm.

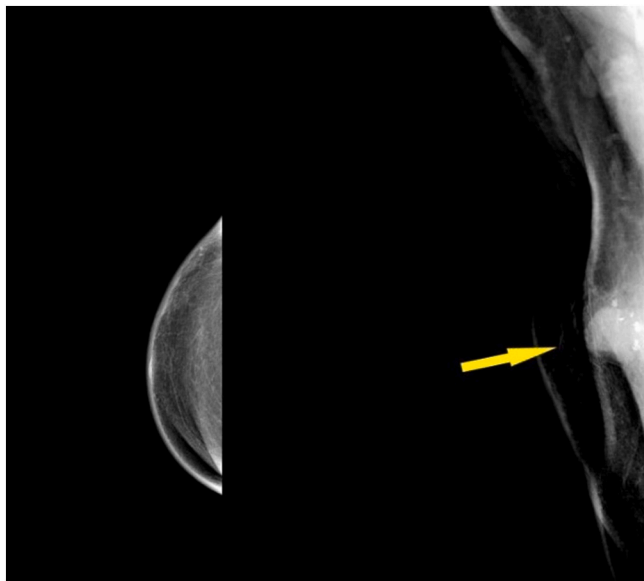


Fig. 2. Right breast mammogram.

density radio opaque lesion was observed along the superior aspect. It was visualized only on the mediolateral oblique view (MLO) and was associated with internal macrocalcifications. Core biopsy was performed which showed sheets and bundles of spindle cells with significant nuclear pleomorphism and increased mitotic activity. A preoperative diagnosis of spindle cell tumor was made. Computerized tomography (CT) scan (Fig. 3) showed a 33 mm lobulated mass in superior aspects of right chest wall. The mass was inseparable from underlying pectoralis major muscle and demonstrated internal coarse calcifications. There was no evidence of distant metastasis.

A multidisciplinary team recommended the use of neoadjuvant chemotherapy in order to downsize the tumor as the mass was inseparable from the underlying muscle and this was to be followed by surgical resection. Three cycles of doxorubicin plus ifosfamide were administered. Patient experienced grade 1 mucositis apart from which the regimen was well tolerated. Post neoadjuvant ultrasound Scan (Fig. 4)

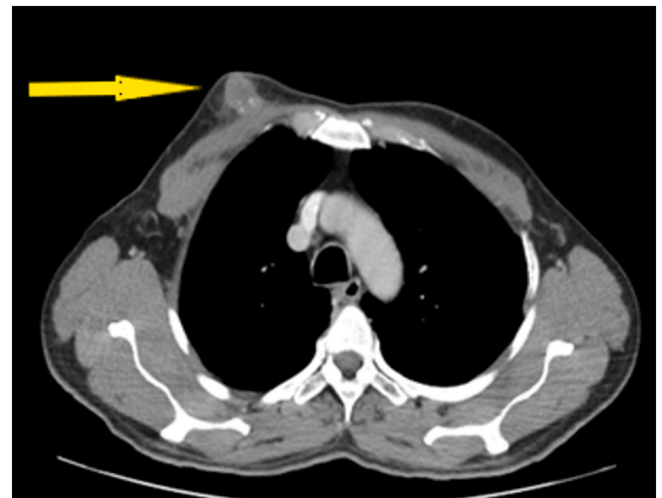


Fig. 3. Chest computerized tomography (CT) scan.

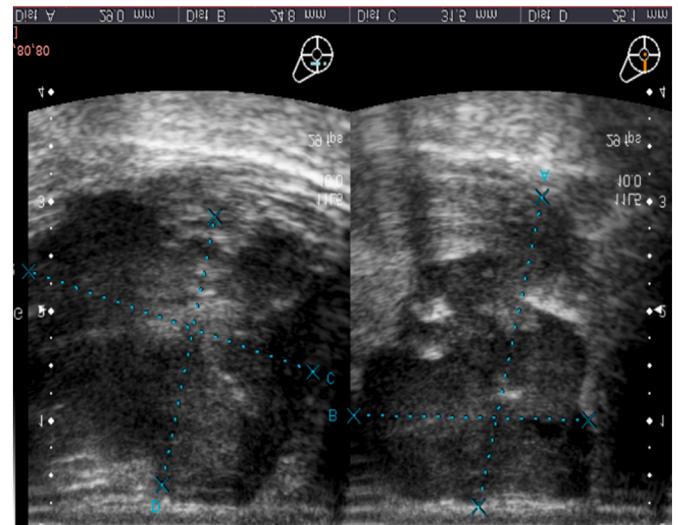


Fig. 4. Post chemotherapy scan, re-demonstrating a 32 mm stable lobulated mass in the right breast.

showed a stable mass as compared to the prior scan. On examination; however, the edema surrounding tumor had settled.

A right mastectomy was performed by a breast surgeon. The patient had an uneventful recovery and was discharged on second post-operative day. On gross examination of the specimen, a well circumscribed, firm and tan white colored tumor measuring 3.0 × 3.0 × 2.5 cm was seen. The tumor was 1 mm from the deep resected margin. On microscopic examination (Fig.5A and B), increased stromal cellularity was noted mainly in periductal region. Extensive hyperchromasia, markedly increased mitotic activity and foci of necrosis were also observed. On immunohistochemical examination, the cells were positive for Smooth Muscle Actin (SMA) and negative for Cytokeratin, High molecular weight cytokeratin (HMWCK), Desmin and S100. A diagnosis of malignant phyllodes was made. Given the proximity of deep margin, the patient received right chest wall and supraclavicular irradiation (267 centigray (cGY) × 15 Fractions).

In line with institutional policies, a six monthly follow up was advised with a yearly bilateral mammogram. None of the follow up mammograms showed any recurrence. Patient is doing well and has remained disease free during 4 years of follow up.

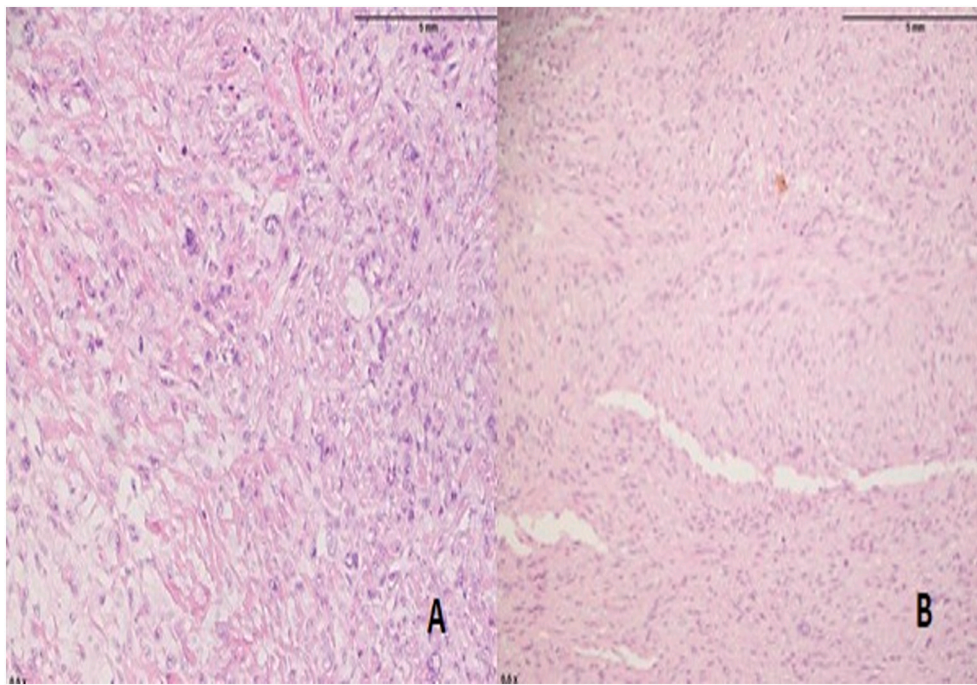


Fig. 5. Microscopic examination: Increased stromal cellularity composed of sheets and bundles of spindle cells and areas of necrosis.

### 3. Discussion

Phyllodes tumor is composed of connective tissue stroma and epithelial component. Based on histological features such as stromal atypia, stromal cellularity, stromal overgrowth, mitotic count and tumor border it is classified into benign, borderline and malignant. Differential diagnoses of malignant phyllodes include metaplastic carcinomas metastatic/primary sarcomas and fibroadenomas. Metaplastic carcinomas are morphologically heterogeneous and include low-grade adenosquamous carcinoma, fibromatosis like metaplastic carcinoma, squamous cell carcinoma and spindle cell carcinoma [5]. In some malignant phyllodes, extensive stromal proliferation can make detection of the epithelial component very difficult [5].

In case of our patient, a preoperative diagnosis of spindle cell carcinoma was made based on the findings of core needle biopsy. Limitations of core biopsy in establishing an accurate pre-operative diagnosis of phyllodes tumor are well documented [6]. The multidisciplinary team opted for neoadjuvant chemotherapy with the intent of downsizing the tumor so that free margins could be achieved during surgical resection. On account of rarity of spindle cell carcinomas, treatment is often extrapolated from sarcomas of different locations. It is also noteworthy that primary breast sarcomas and malignant phyllodes tumors have a similar 5 years disease free and overall survival; therefore, it can be treated with similar strategies [7]. In our patient, re-evaluation after neoadjuvant therapy showed a stable disease with minimal response to the treatment.

Radiologically, phyllodes tumor can be difficult to differentiate from fibroadenomas. Certain findings are more common with phyllodes tumor than a fibroadenoma, such as presence of a high-density mass as compared to surrounding fibroglandular breast tissue and a round or lobulated mass with posterior acoustic enhancement and intramural cystic areas on mammogram and ultrasound, respectively [8].

The standard treatment for phyllodes treatment is surgical resection with margins of 1 cm or more [9]. This can be achieved either with breast conservation surgery or mastectomy depending upon the size of the tumor relative to breast. Decision was made in favor of the mastectomy on account of small size of male breast. Axillary lymph node dissection is not routinely done as malignant phyllodes tumor spreads

hematogenously and rarely involves axillary lymph nodes. The role of adjuvant therapy is debatable in case of malignant phyllodes. No survival benefit has been proven with the use of adjuvant chemotherapy. Adjuvant radiotherapy is general reserved for cases with threatened margins [10,11].

### 4. Conclusion

In summary, a male breast lump can be indicative of underlying sinister pathology and therefore should be investigated thoroughly. However, accurate pre-operative diagnosis of phyllodes tumor is difficult on account of the limitations of core biopsy. Through this case report, we aim to draw attention to the challenges associated with the diagnosis of this rare condition and to highlight the role of different treatment modalities in its management.

### Provenance and peer review

Not commissioned, externally peer-reviewed.

### Sources of funding

None.

### Ethical approval

Not applicable.

### Consent

Written informed consent was obtained from the patient for publication of this case report and accompanying images. A copy of the written consent is available for review by the Editor-in-Chief of this journal on request.

### CRedit authorship contribution statement

Dr. Ibtissam Bin Khalid: Conceptualization, Data Curation, Formal

analysis, Methodology, Project administration, Writing-Original Draft, Writing-review & editing.

Dr. Muhammad Asad Parvaiz: The surgeon who performed the operation and follow up, Conceptualization, Data Curation, Supervision, Validation, Writing-review & editing.

Dr. Albash Sarwar: Conceptualization, Data Curation, Resources, Writing-review & editing.

Dr. Omair Shahid Shaikh: Conceptualization, Methodology, Writing-Original Draft, Writing-review & editing.

Dr. Nida Javed: Conceptualization, Methodology, Writing-Original Draft, Writing-review & editing.

Dr. Arooj Fatima: Conceptualization, Methodology, Resources, Data curation, Writing-review & editing.

#### Research registration

Not applicable.

#### Guarantor

Dr. Ibteham Bin Khalid.

#### Declaration of competing interest

The authors have no conflicts of interest to declare.

#### References

- [1] S.J. Parker, S.A. Harries, Phyllodes tumours, *Postgrad. Med. J.* 77 (909) (2001 Jul) 428–435, <https://doi.org/10.1136/pmj.77.909.428>.
- [2] N. Treves, A study of cystosarcoma phyllodes, *Ann. N. Y. Acad. Sci.* 144 (1964) 922–936, <https://doi.org/10.1111/j.1749-6632.1964.tb41013.x>.
- [3] E. Guillot, B. Couturaud, F. Reyat, A. Curnier, J. Ravinet, M. Laé, et al., Management of phyllodes breast tumors, *Breast J.* 17 (2) (2011) 129–137, <https://doi.org/10.1111/j.1524-4741.2010.01045.x>. Mar-Apr.
- [4] R.A. Agha, T. Franchi, C. Sohrabi, G. Mathew, for the SCARE Group, The SCARE 2020 guideline: updating consensus Surgical Case REport (SCARE) guidelines, *Int. J. Surg.* 84 (2020) 226–230.
- [5] S.R. Lakhani, I.O. Ellis, S.J. Schnitt, P.H. Tan, M.J. van de Vijver, in: *WHO Classification of Tumours of the Breast*, 4th ed., IARC, Lyon, 2012, pp. 48–52.
- [6] Z.R. Zhou, C.C. Wang, X.J. Sun, Z.Z. Yang, X.L. Yu, X.M. Guo, Diagnostic performance of core needle biopsy in identifying breast phyllodes tumors, *Nov. J. Thorac. Dis.* 8 (11) (2016) 3139–3151, <https://doi.org/10.21037/jtd.2016.10.109>.
- [7] F. Wang, Y. Jia, Z. Tong, Comparison of the clinical and prognostic features of primary breast sarcomas and malignant phyllodes tumor, *Feb. Jpn. J. Clin. Oncol.* 45 (2) (2015) 146–152, <https://doi.org/10.1093/jjco/hyu177>.
- [8] L. Duman, N.S. Gezer, P. Balci, C. Altay, I. Başara, M.G. Durak, et al., Differentiation between phyllodes tumors and fibroadenomas based on mammographic sonographic and MRI features, *Apr. Breast Care (Basel)* 11 (2) (2016) 123–127, <https://doi.org/10.1159/000444377>.
- [9] A.W. Chaney, A. Pollack, M.D. McNeese, G.K. Zagars, P.W.T. Pisters, R.E. Pollock, et al., Primary treatment of cystosarcoma phyllodes of the breast, *Cancer* 89 (7) (2000) 1502–1511, [https://doi.org/10.1002/1097-0142\(20001001\)89:7<1502::aid-cnrc13>3.0.co;2-p](https://doi.org/10.1002/1097-0142(20001001)89:7<1502::aid-cnrc13>3.0.co;2-p).
- [10] F. Morales-Vásquez, A.M. Gonzalez-Angulo, K. Broglio, H.N. Lopez-Basave, D. Gallardo, G.N. Hortobagyi, et al., Adjuvant chemotherapy with doxorubicin and dacarbazine has no effect in recurrence-free survival of malignant phyllodes tumors of the breast, *Breast J.* 13 (6) (2007) 551–556, <https://doi.org/10.1111/j.1524-4741.2007.00510.x>. Nov-Dec.
- [11] X. Chao, K. Chen, J. Zeng, Z. Bi, M. Guo, Y. Chen, et al., Adjuvant radiotherapy and chemotherapy for patients with breast phyllodes tumors: a systematic review and meta-analysis, *BMC Cancer* 19 (1) (2019) 372, <https://doi.org/10.1186/s12885-019-5585-5>. Apr 23.