



# Oncologic and obstetric outcomes of a novel nerve-sparing radical trachelectomy while preserving the uterine branches of the pelvic nerves

Kentaro Nakayama<sup>1</sup>, Sultana Razia<sup>2</sup>, Tomoka Ishibashi<sup>1</sup>, Hitomi Yamashita<sup>3</sup>, Kosuke Kanno<sup>3</sup>, Masako Ishikawa<sup>3</sup>, Seiya Sato<sup>3</sup>, Haruo Takeshita<sup>2</sup>, Satoru Kyo<sup>3</sup>

<sup>1</sup>Department of Obstetrics and Gynecology, Nagoya City University East Medical Center, Nagoya, Japan; <sup>2</sup>Department of Legal Medicine, Shimane University School of Medicine, Izumo, Japan; <sup>3</sup>Department of Obstetrics and Gynecology, Shimane University School of Medicine, Izumo, Japan

**Contributions:** (I) Conception and design: K Nakayama, S Kyo; (II) Administrative support: K Nakayama, H Takeshita, S Kyo; (III) Provision of study materials or patients: K Nakayama, S Razia, T Ishibashi, H Yamashita, K Kanno, M Ishikawa, S Sato; (IV) Collection and assembly of data: S Razia, T Ishibashi, H Yamashita, K Kanno, M Ishikawa, S Sato; (V) Data analysis and interpretation: S Razia, T Ishibashi, H Yamashita, K Kanno, M Ishikawa, S Sato; (VI) Manuscript writing: All authors; (VII) Final approval of manuscript: All authors.

**Correspondence to:** Kentaro Nakayama, MD, PhD. Department of Obstetrics and Gynecology, Nagoya City University East Medical Center, 1-2-23 Wakamizu, Chikusa-ku, Nagoya 4648547, Japan. Email: kn88@med.nagoya-cu.ac.jp or kent880626@gmail.com; Satoru Kyo, MD, PhD. Department of Obstetrics and Gynecology, Shimane University School of Medicine, Enya 89-1, Izumo 6938501, Japan. Email: satoruky@med.shimane-u.ac.jp.

**Background:** Cervical cancer is a prevalent malignancy among women of reproductive age. For early-stage cervical cancer, nerve-sparing radical trachelectomy offers a fertility-preserving treatment option. This procedure aims to remove the cancerous tissue while preserving pelvic nerves necessary for uterine function, thereby maintaining fertility while achieving favorable oncologic outcomes. This study evaluated the obstetric and oncologic outcomes of nerve-sparing radical trachelectomy in patients with early-stage cervical cancer.

**Methods:** Retrospective reviews were performed on eight patients who underwent nerve-sparing radical trachelectomy for stage IA2–IB1 cervical cancer, classified according to the International Federation of Gynecology and Obstetrics (FIGO). Six patients underwent nerve-sparing radical trachelectomy while preserving the uterine branches of the pelvic nerves, while two patients underwent conventional nerve-sparing radical trachelectomy. Two patients underwent abdominal surgery, and six patients underwent laparoscopic surgeries. The clinical stages included three patients with stage IA2 and five patients with stage IB1. The median follow-up period was 78 months (range, 15–114 months).

**Results:** In this study, 37.5% of the patients attempted conception. The pregnancy rate was 66.7%, with deliveries occurring at full term as well as at 34 gestational weeks. Cine magnetic resonance imaging revealed physiological endometrial movements in patients who underwent surgery. No patient developed recurrence, and none of the patients died.

**Conclusions:** Early-stage cervical cancer patients may be safe candidates for nerve-sparing radical laparoscopic trachelectomy with preservation of the uterine branches of the pelvic nerves. Maintaining the uterine branches of the pelvic nerves may be crucial for strengthening uterine immunity and maintaining uterine peristalsis, which may contribute to improved pregnancy outcomes.

**Keywords:** Cervical cancer; radical trachelectomy; outcomes; nerve-sparing; uterine branches

Submitted Oct 10, 2024. Accepted for publication Jan 22, 2025. Published online Mar 24, 2025.

doi: 10.21037/tcr-24-1929

**View this article at:** <https://dx.doi.org/10.21037/tcr-24-1929>

## Introduction

Cervical cancer is the fourth most common malignancy affecting women globally (1). In Japan, approximately 3,500 deaths occur annually from cervical cancer, with over 13,000 new cases identified each year (2). Cervical cancer predominantly affects women at an earlier age compared with other cancer types. It is most commonly diagnosed in young and middle-aged adults, particularly between the ages of 35 and 55 years (3). Surgery remains the primary treatment modality for early-stage cervical cancer, with radical hysterectomy being a widely performed procedure (4). This surgery can be performed through open surgery or minimally invasive techniques, depending on the patient's condition and the surgeon's expertise. Recently, a review paper evaluated the safety, efficacy, and oncologic outcomes of minimally invasive radical hysterectomy compared to open surgery in early-stage cervical cancer, focusing on evidence from key trials and retrospective studies (5). Prior to 2018, minimally invasive radical hysterectomy was widely regarded as safe and effective (6-9), with meta-analyses demonstrating comparable survival outcomes between laparoscopic and

open surgery (8). However, the lack of definitive evidence (level A) prompted the design of the Laparoscopic Approach to Cervical Cancer (LACC) trial to further compare these techniques (10). The LACC trial revealed significant shortcomings of minimally invasive surgery, including poorer disease-free survival and a higher risk of recurrence compared to open surgery, raising concerns about its safety (10,11). Following the trial, retrospective studies presented mixed findings. Some studies reported a 4-year mortality rate of 9.1% for minimally invasive surgery compared to 5.3% for open surgery, while others indicated a 71% higher pooled hazard ratio for adverse oncologic outcomes associated with minimally invasive surgery (12,13). These results underscore the ongoing debate regarding the safety and efficacy of minimally invasive radical hysterectomy, emphasizing the need for further investigation.

However, radical hysterectomy carries the potential to cause infertility (14). Recently, the prevalence of early-stage cervical cancer has increased among women who wish to preserve their fertility. Radical trachelectomy is currently considered the standard treatment for patients with early-stage cervical cancer who want to maintain their fertility (15). The radical trachelectomy involves the *en bloc* removal of the cervix, vaginal margins, and parametria while preserving the uterine body and fundus *in situ* (16). Traditionally, trachelectomy has been selectively offered to women meeting specific criteria, typically those diagnosed with up to stage IB1 cervical cancer and a tumor size not exceeding 2 cm, as per current guideline recommendations (17). In addition, patients who wish to retain their fertility may also have radical trachelectomy combined with pelvic lymphadenectomy; however, all surgical approaches (vaginal, abdominal, laparoscopic, and robotic) cause peritoneal damage leading to periadnexal adhesions (18). Several surgical approaches, such as abdominal, vaginal, laparoscopic, and robotic radical trachelectomies, are employed worldwide (19-21). Numerous studies have reported the oncologic and obstetric outcomes of radical trachelectomy (22-28). According to these reports, the oncologic outcomes of radical trachelectomies were comparable to radical hysterectomies (22-28). However, obstetric outcomes differed in each report, necessitating further improvements. To address this, we previously introduced the novel concept of preserving the uterine branches of the pelvic nerves in nerve-sparing radical trachelectomy (29). Using this method, the uterine branches of the pelvic nerves are safely translocated and preserved in the uterine body after resection of the cervix containing the tumor (29). Recently, we have succeeded in

### Highlight box

#### Key findings

- We identified a nerve-sparing surgical approach that preserves uterine branches of the pelvic nerves, improving pregnancy outcomes and maintaining uterine function in early-stage cervical cancer patients without compromising oncologic safety.

#### What is known and what is new?

- Nerve-sparing radical trachelectomy is a fertility-preserving surgery for early-stage cervical cancer, but the specific benefits of preserving the uterine branches of the pelvic nerves were not well established.
- This study highlights the importance of preserving uterine nerve branches during nerve-sparing radical trachelectomy, showing improved pregnancy outcomes and enhanced uterine function in early-stage cervical cancer patients without compromising oncologic outcomes.

#### What is the implication, and what should change now?

- The preservation of uterine nerve branches during nerve-sparing radical trachelectomy could be implemented in clinical practice to improve fertility outcomes and maintain uterine function in early-stage cervical cancer patients.
- Future surgical approaches should prioritize techniques that protect these nerve branches, and further research should focus on refining and validating this method to maximize both reproductive and oncologic outcomes.

introducing this concept in laparoscopic surgery. In this study, we present the oncologic and obstetric outcomes of patients with early-stage cervical cancer who underwent a novel nerve-sparing laparoscopic radical trachelectomy with preservation of the uterine branches of the pelvic nerves. We present this article in accordance with the SUPER reporting checklist (available at <https://tcr.amegroups.com/article/view/10.21037/tcr-24-1929/rc>).

## Methods

### Patients

This retrospective study analyzed eight patients with cervical cancer who underwent nerve-sparing type III radical trachelectomy and pelvic lymphadenectomy between December 2014 and February 2022 at Shimane University Hospital. All patients had stage IA2–IB1 cervical cancer, according to the International Federation of Gynecology and Obstetrics (FIGO). The inclusion criteria for this surgery were a tumor diameter of <20 mm, squamous cell carcinoma or adenocarcinoma, a free surgical margin of 10 mm, and a residual cervical length of >10 mm. During radical trachelectomy, in cases where positive tumor nodes were detected after pelvic lymphadenectomy or if frozen pathological sections revealed a positive surgical margin in the cervix, the surgical intervention was modified to radical hysterectomy. All patients provided written informed consent for surgery and separate consent for participation in this study was also obtained from all patients. The study was approved by the Institutional Review Board of Shimane University (IRB No. 20191120-1). Patients were informed of the option to withdraw from this study at any time using the opt-out option available on the hospital's website. This study was conducted in accordance with the Declaration of Helsinki (as revised in 2013).

### Surgical procedure

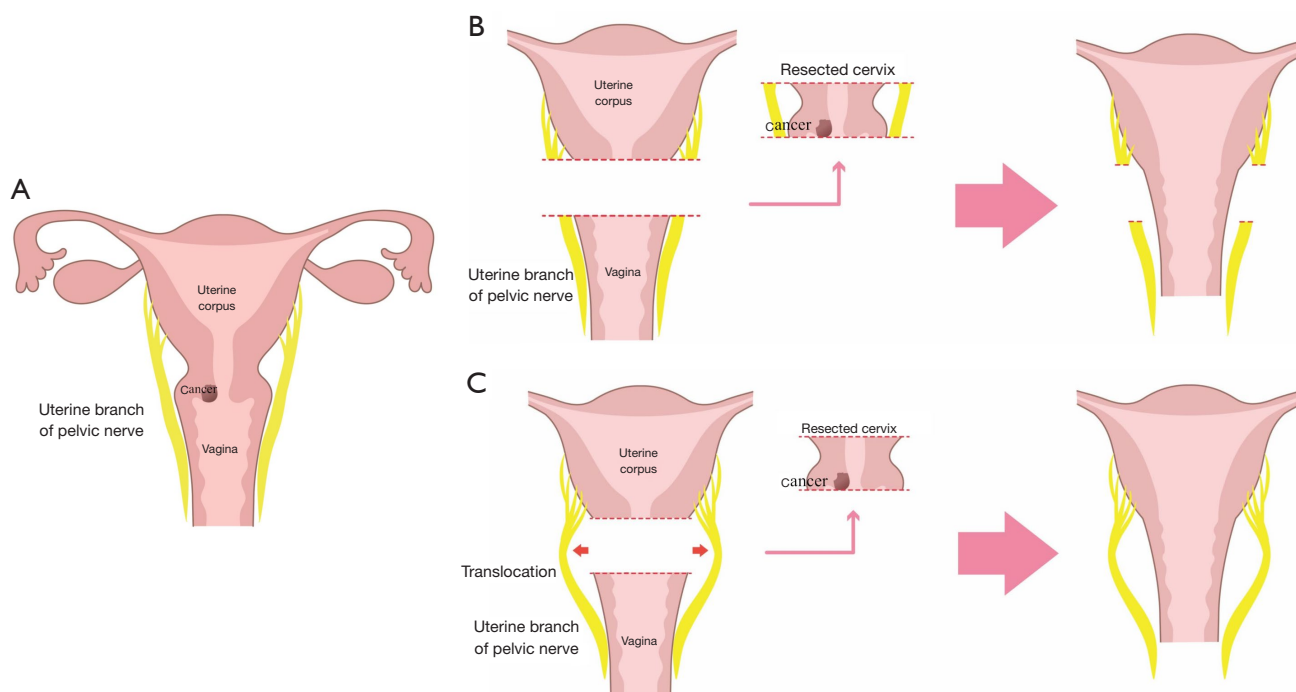
A detailed method for nerve-sparing radical trachelectomy with preservation of the uterine branches of the pelvic nerves was reported in our previous study (29). Briefly, this method involves the preservation of the uterine branch of the pelvic nerve, which is composed of the pelvic splanchnic and hypogastric nerves. The hypogastric nerve is usually identified by exploiting Okabayashi's pararectal space. Dissection of the surrounding connective tissue in the uterine cervix, including the continuation of the hypogastric

nerve, facilitates the isolation of the uterine branches. Further dissection of the surrounding connective tissue from the uterine corpus facilitates complete separation from the cervix. These techniques are similar to those used in abdominal and laparoscopic surgeries. The main concept for preserving the uterine branch of the pelvic nerve is shown in *Figure 1*. The bilateral ascending branches of the uterine arteries were also preserved. Treatments for the vesicouterine and cardinal ligaments followed those of the conventional nerve-sparing radical trachelectomy. Four of the six patients underwent laparoscopic radical trachelectomy without protective maneuvers.

After the colpotomy, the uterus was attached to the bilateral uterine arteries, bilateral uterine branches of the pelvic nerve, and bilateral infundibulopelvic ligaments. During laparoscopic surgery, a 5 cm lower abdominal longitudinal incision was made, and the uterine cervix was extracted from the pelvic cavity. The anatomical position of the internal ostium was identified using ultrasonography, and trachelectomy was performed 10 mm below the internal ostium, resulting in a residual cervical length of 10 mm. A permanent cerclage using #2-0 Ethibond (Johnson and Johnson, Norderstedt, Germany) was placed, and the anastomosis between the vagina and the residual cervix was performed laparoscopically.

## Results

A total of eight patients underwent a nerve-sparing radical trachelectomy. Among them, six patients underwent nerve-sparing radical trachelectomy to preserve the uterine branches of the pelvic nerves, and two patients underwent conventional nerve-sparing radical trachelectomy, prioritizing uterine preservation over conception. Two patients underwent abdominal surgery, and six patients underwent laparoscopic surgery. Seven of the eight patients underwent a radical trachelectomy, and one patient underwent a radical hysterectomy due to a positive surgical margin (*Table 1*). The follow-up duration ranged from 15 to 114 months (median: 78 months), with an age range of 31–37 years (median: 33.3 years). Three patients were classified as clinical stage IA2, and five as stage IB1 tumors. Histological examination revealed squamous cell carcinoma in six patients, while adenocarcinoma was observed in two patients. Lymphovascular space invasion was found in one case. The median operative time was 518 min (range, 385–630 min), median blood loss was 480 mL (range, 165–4,230 mL), and the median length of hospital stay



**Figure 1** Conceptual representation of novel nerve-sparing radical trachelectomy preserving the uterine branches of the pelvic nerves. (A) Schematic overview of the conventional technique. (B) Schematic overview of the current surgical technique. In the normal trachelectomy technique, the uterine branches of the pelvic nerve attach to the cervix and are simultaneously removed. (C) Schematic overview for radical trachelectomy from the standpoint of the uterine branches of the pelvic nerves. The procedure reduces the uterine branch of the pelvic nerve via translocation.

was 17.5 days (range, 7–47 days) (Table 1). There were no intraoperative and postoperative complications (0%). The average number of dissected lymph nodes was 38.1 (range, 22–61). The prevalence of residual disease in the surgical specimens was 12.5% (1/8). All patients remain alive without evidence of recurrence, resulting in a recurrence rate of 0%. One patient received adjuvant chemotherapy (taxane + carboplatin) owing to a high risk of recurrence according to the histological diagnosis.

Among the patients who underwent radical trachelectomy, three desired conception, and two achieved successful pregnancies through assisted reproductive technology. Both patients delivered via cesarean section; one patient had a full-term pregnancy, and the other had 34 gestational weeks due to labor onset. Therefore, the prevalence of pregnancy was 66.7% (2/3). To assess the physiological function of nerve-sparing radical trachelectomy while preserving the uterine branches of the pelvic nerves, we performed cine magnetic resonance imaging. The physiological endometrial movement was observed in the patients who underwent surgery (Figure 2).

## Discussion

Cervical cancer ranks the fourth most common malignancy globally in terms of incidence and mortality, following breast, colorectal, and lung cancers (30). The number of young patients with cervical cancer who wish to preserve fertility is rising, particularly in developed countries, due to the increase in average childbearing age. Currently, radical trachelectomy is carried out as a fertility-preserving surgery worldwide by vaginal, open, and minimally invasive techniques (22,30–34). In this study, we focused on the oncologic and obstetric outcomes of eight patients who underwent nerve-sparing laparoscopic radical trachelectomy while preserving the uterine branches of the pelvic nerves. At the time of writing this report, no patients had developed recurrence or died of the disease. Pareja *et al.* (26) examined the outcomes of abdominal radical trachelectomy and observed a disease recurrence rate of 3.8% and a mortality rate of 0.4%. Another study reported the overall recurrence rate to be about 7.2% after a median follow-up period of 58 months for 166 consecutive women who underwent

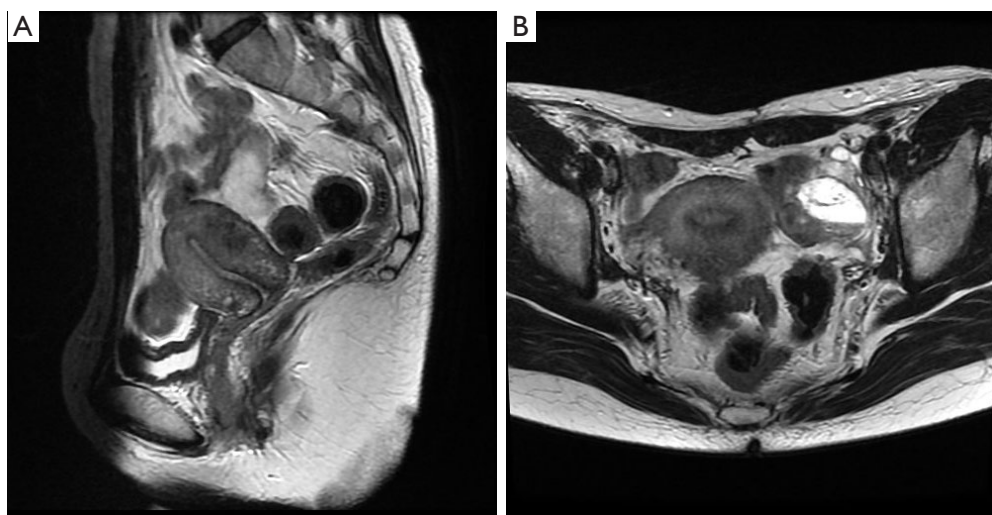
**Table 1** Summary of surgical, oncological, and obstetrical outcomes of patients who underwent nerve-sparing radical hysterectomy

Patient No.	Approach	Age, years	Marital history	GPAC	Histology	FIGO stage	Conization	Tumor diameter (cm)	Protective maneuvers	No. of dissected lymph node	Surgical time (min)	Conversion to RH	Estimated blood loss (mL)	Infertility treatment	Pregnancy	Delivery	Recurrence
1	ART	32	Married	G1P1	SCC	IA2	Yes	NA	NA	22	630	Yes	4,230	None	No	No	No
2	ART	34	Unmarried	G0	AD	IB1	Yes	NA	NA	36	518	No	2,950	None	No	No	No
3	LRT	31	Married	G0	AD	IA2	Yes	NA	No	36	519	No	860	None	No	No	No
4	LRT	34	Married	G1P1	SCC	IA2	Yes	NA	No	27	551	No	330	IVF-ET	No	No	No
5	LRT	32	Married	G0	SCC	IB1	No	1.75×1.75	No	61	621	No	480	IVF-ET	Yes	34 W C/S	No
6	LRT	32	Unmarried	G2P0	SCC	IB1	No	1.45×0.7	No	42	457	No	270	IVF-ET	Yes	37 W C/S	No
7	LRT	34	Married	G1P1	SCC	IB1	Yes	0.7×0.8	Yes	53	502	No	630	None	No	No	No
8	LRT	37	Married	G0P0	SCC	IB1	No	NA	Yes	28	385	No	165	None	No	No	No

GPAC, gravida-para-abortion-cesarean section; FIGO, International Federation of Gynecology and Obstetrics; RH, radical hysterectomy; ART, abdominal radical trachelectomy; LRT, laparoscopic radical trachelectomy; SCC, squamous cell carcinoma; AD, adenocarcinoma; NA, not applicable; IVF-ET, in vitro fertilization-embryo transfer; W, week; C/S, cesarean section.

fertility-sparing robot-assisted radical trachelectomy (35). Chiva *et al.* (36) reported that, compared with open surgery, cervical cancer minimally invasive surgery increased the risk of death (2.42 times higher) and recurrence (twice as high). The use of uterine manipulators and inadequate protective maneuvers to prevent tumor spread during colpotomy was associated with these poor outcomes in minimally invasive surgery. However, employing protective techniques and avoiding tumor spread during colpotomy resulted in outcomes similar to those of open surgery (36). Another prospective randomized study with similar findings revealed that robotic or laparoscopic radical hysterectomy was linked with a higher incidence of recurrence and poorer overall survival than the open method (36,37). The no-lock, no-touch method may be useful in lowering the risk of recurrence and enhancing obstetric outcomes during laparoscopic radical trachelectomy for early-stage cervical cancer (38). In a retrospective review spanning patients from four institutions, outcomes of oncologic and fertility assessments were compared between open and minimally invasive surgery (MIS) groups. Notably, no disparities were found in patient demographics, histology, or cancer stage. Intraoperative complications were minimal (3%), including one bladder and one fallopian tube injury in the MIS group, as well as one vascular injury in open surgery. Median lymph node count differed significantly (MIS: 17 *vs.* open surgery: 22,  $P=0.03$ ). Postoperative complications were comparable (30% MIS *vs.* 31% open surgery). Remarkably, there was only one recurrence in the laparotomy group, with none documented in the MIS group at the time of publication (39). Different surgical approaches to treating cervical cancer may have different oncological results. In our series, the relapse rate after laparoscopic radical trachelectomy during a median of 78 months was 0% with no mortality, even though four out of six patients underwent radical trachelectomy without protective maneuvers. This suggests that the oncological outcome is excellent and that patients with early-stage cervical cancer can safely undergo a nerve-sparing laparoscopic radical trachelectomy. Notably, all cases in this series had a tumor diameter <2.0 cm, which was consistent with the findings of a previous report (36).

In this study, three patients (37.5%) attempted conception following nerve-sparing laparoscopic radical trachelectomy. Two pregnancies were achieved in three women, resulting in deliveries at full term and 34 gestational weeks. The pregnancy rate following nerve-sparing laparoscopic radical trachelectomy with preservation of the uterine branches was 66.7%. Several gynecologic oncologists have reported



**Figure 2** This figure shows cine MRI of uterine peristalsis following nerve-sparing radical trachelectomy while preserving the uterine branches of the pelvic nerves. The images demonstrate physiological endometrial movements in the patient who underwent this surgery. (A) Cine MRI in the sagittal plane. (B) Cine MRI in the axial direction. MRI, magnetic resonance imaging.

a 50% pregnancy rate following simple trachelectomy (40), 24% after abdominal radical trachelectomy (26), and 52% after total laparoscopic radical trachelectomy (41), which are lower than the rate observed in the current report. Cervical factors such as mucus production, stenosis, and cervical length have been suggested as the main causes of infertility after trachelectomy (42,43). In our patients who went through radical trachelectomy, preservation of the uterine branches of the pelvic nerves may have maintained both endometrial immunity and uterine peristalsis. This might be confirmed by the fact that physiological endometrial movement can still be observed after nerve-sparing radical trachelectomy, with preservation of the uterine branches of the pelvic nerves on cine magnetic resonance imaging (Figure 2). Preservation of the pelvic nerves is thought to be crucial for boosting immunity in the uterus and maintaining uterine peristalsis, which may have contributed to the higher pregnancy rates. Recent concepts propose a precise regulation of successful pregnancy by the immune-neuro-endocrine network (44,45). The levels of uterine mast cells (MCs) and histamine release correlate with uterine immunity during pregnancy (46,47). Disruption of autonomic nerve innervation can elevate uterine MCs, resulting in increased histamine release. Histamine, in turn, can impact the balance between Th1 and Th2 immune responses. Excessive pre-implantation histamine levels may inhibit Th2, favoring Th1 dominance, potentially leading to immune rejection and implantation failure (48). Therefore,

uterine nerves likely play a pivotal role in facilitating successful implantation by regulating histamine levels and maintaining the Th1/Th2 balance.

This study on nerve-sparing surgery for early-stage cervical cancer establishes a strong foundation for future research and medical decision-making. Further research through continued follow-up studies is crucial to evaluate long-term outcomes and safety, especially regarding cancer recurrence, fertility outcomes, and nerve function. Comparative analyses with alternative surgical approaches and detailed assessments of functional outcomes will enhance evidence-based decision-making and improve patient care. Collaboration among medical institutions and international data-sharing initiatives may help gain a better understanding of nerve-sparing surgery outcomes across diverse populations, potentially leading to the development of standardized protocols and guidelines. Therefore, in the future, doctors may become more skilled at selecting the right patients for this surgery based on tumor type and patient preferences.

The strength of this study lies in its novel discussion of both oncologic and obstetric results of laparoscopic radical trachelectomy with preservation of the uterine branches of the pelvic nerves. However, a limitation of this study is its small sample size of patients who had nerve-sparing radical trachelectomy with preservation of the uterine branches of the pelvic nerve. Additionally, the relatively short median follow-up period of 78 months may not be sufficient to

capture potential long-term complications or recurrence rates. Larger, prospective studies with longer follow-up durations and comparative analyses are warranted to further validate the safety and efficacy of this surgical approach.

## Conclusions

In conclusion, nerve-sparing radical trachelectomy with laparoscopic preservation of the uterine branches of the pelvic nerves is a safe and effective approach for early-stage cervical cancer patients. This approach demonstrated no recurrence and a high pregnancy rate. This could lead to an increase in the pregnancy rate for this category of patients due to the maintenance of nerve and endometrial mobility. Therefore, patients with cervical cancer who wish to preserve their fertility may benefit from this technique. Clinicians can consider recommending this approach when counseling patients who prioritize fertility preservation. The study's practical relevance lies in providing a beneficial and viable choice for women with early cervical cancer seeking to preserve their ability to conceive, thereby influencing real clinical practice positively.

## Acknowledgments

None.

## Footnote

**Reporting Checklist:** The authors have completed the SUPER reporting checklist. Available at <https://tcr.amegroups.com/article/view/10.21037/tcr-24-1929/rc>

**Data Sharing Statement:** Available at <https://tcr.amegroups.com/article/view/10.21037/tcr-24-1929/dss>

**Peer Review File:** Available at <https://tcr.amegroups.com/article/view/10.21037/tcr-24-1929/prf>

**Funding:** None.

**Conflicts of Interest:** All authors have completed the ICMJE uniform disclosure form (available at <https://tcr.amegroups.com/article/view/10.21037/tcr-24-1929/coif>). The authors have no conflicts of interest to declare.

**Ethical Statement:** The authors are accountable for all aspects of the work in ensuring that questions related to the

accuracy or integrity of any part of the work are appropriately investigated and resolved. This study was conducted in accordance with the Declaration of Helsinki (as revised in 2013) and was approved by the Institutional Review Board of Shimane University (IRB No. 20191120-1). All patients provided written informed consent for surgery and separate consent for participation in this study was also obtained from all patients.

**Open Access Statement:** This is an Open Access article distributed in accordance with the Creative Commons Attribution-NonCommercial-NoDerivs 4.0 International License (CC BY-NC-ND 4.0), which permits the non-commercial replication and distribution of the article with the strict proviso that no changes or edits are made and the original work is properly cited (including links to both the formal publication through the relevant DOI and the license). See: <https://creativecommons.org/licenses/by-nc-nd/4.0/>.

## References

1. Sung H, Ferlay J, Siegel RL, et al. Global Cancer Statistics 2020: GLOBOCAN Estimates of Incidence and Mortality Worldwide for 36 Cancers in 185 Countries. *CA Cancer J Clin* 2021;71:209-49.
2. Hori M, Matsuda T, Shibata A, et al. Cancer incidence and incidence rates in Japan in 2009: a study of 32 population-based cancer registries for the Monitoring of Cancer Incidence in Japan (MCIJ) project. *Jpn J Clin Oncol* 2015;45:884-91.
3. Matsuura Y, Yoshioka M, Nakata A, et al. Trends in Uterine Cervical Cancer Screening at Physical Health Checkups for Company Employees in Japan. *J UOEH* 2019;41:327-33.
4. Landoni F, Colombo A, Milani R, et al. Randomized study between radical surgery and radiotherapy for the treatment of stage IB-IIA cervical cancer: 20-year update. *J Gynecol Oncol* 2017;28:e34.
5. Bogani G, Di Donato V, Scambia G, et al. Radical Hysterectomy for Early Stage Cervical Cancer. *Int J Environ Res Public Health* 2022;19:11641.
6. Shah CA, Beck T, Liao JB, et al. Surgical and oncologic outcomes after robotic radical hysterectomy as compared to open radical hysterectomy in the treatment of early cervical cancer. *J Gynecol Oncol* 2017;28:e82.
7. Ditto A, Martinelli F, Bogani G, et al. Implementation of laparoscopic approach for type B radical hysterectomy: a comparison with open surgical operations. *Eur J Surg*

- Oncol 2015;41:34-9.
8. Cao T, Feng Y, Huang Q, et al. Prognostic and Safety Roles in Laparoscopic Versus Abdominal Radical Hysterectomy in Cervical Cancer: A Meta-analysis. *J Laparoendosc Adv Surg Tech A* 2015;25:990-8.
9. Wang YZ, Deng L, Xu HC, et al. Laparoscopy versus laparotomy for the management of early stage cervical cancer. *BMC Cancer* 2015;15:928.
10. Ramirez PT, Frumovitz M, Pareja R, et al. Minimally Invasive versus Abdominal Radical Hysterectomy for Cervical Cancer. *N Engl J Med* 2018;379:1895-904.
11. Casarin J, Bogani G, Multinu F, et al. Paradigm shifts in gynecologic oncology. *Int J Gynecol Cancer* 2021;31:1617.
12. Melamed A, Margul DJ, Chen L, et al. Survival after Minimally Invasive Radical Hysterectomy for Early-Stage Cervical Cancer. *N Engl J Med* 2018;379:1905-14.
13. Nitecki R, Ramirez PT, Frumovitz M, et al. Survival After Minimally Invasive vs Open Radical Hysterectomy for Early-Stage Cervical Cancer: A Systematic Review and Meta-analysis. *JAMA Oncol* 2020;6:1019-27.
14. Lluca A, Ibañez MV, Torne A, et al. Fertility-Sparing Surgery versus Radical Hysterectomy in Early Cervical Cancer: A Propensity Score Matching Analysis and Noninferiority Study. *J Pers Med* 2022;12:1081.
15. Salvo G, Ramirez PT, Leitao MM, et al. Open vs minimally invasive radical trachelectomy in early-stage cervical cancer: International Radical Trachelectomy Assessment Study. *Am J Obstet Gynecol* 2022;226:97.e1-97.e16.
16. Li J, Wu X, Li X, et al. Abdominal radical trachelectomy: Is it safe for IB1 cervical cancer with tumors  $\geq 2$  cm? *Gynecol Oncol* 2013;131:87-92.
17. Matsuo K, Machida H, Mandelbaum RS, et al. Trachelectomy for stage IB1 cervical cancer with tumor size  $>2$  cm: trends and characteristics in the United States. *J Gynecol Oncol* 2018;29:e85.
18. Shimura K, Mabuchi S. Extraperitoneal radical trachelectomy with pelvic lymphadenectomy. *Int J Gynecol Cancer* 2019;29:842.
19. Lim YK, Lek SM, Yeo SH. Obstetric care after radical abdominal trachelectomy in a patient with stage IB1 cervical cancer: A case report and a review of medical literature. *Gynecol Oncol Rep* 2016;17:86-8.
20. Chen Y, Xu H, Zhang Q, et al. A fertility-preserving option in early cervical carcinoma: laparoscopy-assisted vaginal radical trachelectomy and pelvic lymphadenectomy. *Eur J Obstet Gynecol Reprod Biol* 2008;136:90-3.
21. Saadi JM, Perrotta M, Orti R, et al. Laparoscopic radical trachelectomy: technique, feasibility, and outcomes. *JSLs* 2015;19:e2013.00248.
22. Johansen G, Lönnerfors C, Falconer H, et al. Reproductive and oncologic outcome following robot-assisted laparoscopic radical trachelectomy for early stage cervical cancer. *Gynecol Oncol* 2016;141:160-5.
23. Ekdahl L, Crusensvärd M, Reynisson P, et al. Quality of life and long-term clinical outcome following robot-assisted radical trachelectomy. *Eur J Obstet Gynecol Reprod Biol* 2021;267:234-40.
24. Tamauchi S, Kajiyama H, Sakata J, et al. Oncologic and obstetric outcomes of early stage cervical cancer with abdominal radical trachelectomy: Single-institution experience. *J Obstet Gynaecol Res* 2016;42:1796-801.
25. Chen T, Li J, Zhu Y, et al. The oncological and obstetric results of radical trachelectomy as a fertility-sparing therapy in early-stage cervical cancer patients. *BMC Womens Health* 2022;22:424.
26. Pareja R, Rendón GJ, Sanz-Lomana CM, et al. Surgical, oncological, and obstetrical outcomes after abdominal radical trachelectomy - a systematic literature review. *Gynecol Oncol* 2013;131:77-82.
27. Yoshino AI, Kobayashi E, Kodama M, et al. Oncological and Reproductive Outcomes of Abdominal Radical Trachelectomy. *Anticancer Res* 2020;40:5939-47.
28. Nezhat C, Roman RA, Rambhatla A, et al. Reproductive and oncologic outcomes after fertility-sparing surgery for early stage cervical cancer: a systematic review. *Fertil Steril* 2020;113:685-703.
29. Kyo S, Mizumoto Y, Takakura M, et al. Nerve-sparing abdominal radical trachelectomy: a novel concept to preserve uterine branches of pelvic nerves. *Eur J Obstet Gynecol Reprod Biol* 2015;193:5-9.
30. Arbyn M, Weiderpass E, Bruni L, et al. Estimates of incidence and mortality of cervical cancer in 2018: a worldwide analysis. *Lancet Glob Health* 2020;8:e191-203.
31. Mangler M, Lanowska M, Köhler C, et al. Pattern of cancer recurrence in 320 patients after radical vaginal trachelectomy. *Int J Gynecol Cancer* 2014;24:130-4.
32. Li X, Li J, Jiang Z, et al. Oncological results and recurrent risk factors following abdominal radical trachelectomy: an updated series of 333 patients. *BJOG* 2019;126:1169-74.
33. Park JY, Joo WD, Chang SJ, et al. Long-term outcomes after fertility-sparing laparoscopic radical trachelectomy in young women with early-stage cervical cancer: an Asan Gynecologic Cancer Group (AGCG) study. *J Surg Oncol* 2014;110:252-7.
34. Salman L, Covens A. Fertility Preservation in Cervical

- Cancer-Treatment Strategies and Indications. *Curr Oncol* 2024;31:296-306.
35. Ekdahl L, Paraghamian S, Eoh KJ, et al. Long term oncologic and reproductive outcomes after robot-assisted radical trachelectomy for early-stage cervical cancer. An international multicenter study. *Gynecol Oncol* 2022;164:529-34.
  36. Chiva L, Zanagnolo V, Querleu D, et al. SUCCOR study: an international European cohort observational study comparing minimally invasive surgery versus open abdominal radical hysterectomy in patients with stage IB1 cervical cancer. *Int J Gynecol Cancer* 2020;30:1269-77.
  37. Chen X, Zhao N, Ye P, et al. Comparison of laparoscopic and open radical hysterectomy in cervical cancer patients with tumor size  $\leq 2$  cm. *Int J Gynecol Cancer* 2020;30:564-71.
  38. Kanao H, Aoki Y, Fusegi A, et al. Feasibility and Outcomes of "No-Look No-Touch" Laparoscopic Radical Trachelectomy for Early-Stage Cervical Cancer. *J Clin Med* 2021;10:4154.
  39. Vieira MA, Rendón GJ, Munsell M, et al. Radical trachelectomy in early-stage cervical cancer: A comparison of laparotomy and minimally invasive surgery. *Gynecol Oncol* 2015;138:585-9.
  40. Halaska M, Robova H, Pluta M, et al. The role of trachelectomy in cervical cancer. *Ecancermedalscience* 2015;9:506.
  41. Ebisawa K, Takano M, Fukuda M, et al. Obstetric outcomes of patients undergoing total laparoscopic radical trachelectomy for early stage cervical cancer. *Gynecol Oncol* 2013;131:83-6.
  42. Li J, Li Z, Wang H, et al. Radical abdominal trachelectomy for cervical malignancies: surgical, oncological and fertility outcomes in 62 patients. *Gynecol Oncol* 2011;121:565-70.
  43. Boss EA, van Golde RJ, Beerendonk CC, et al. Pregnancy after radical trachelectomy: a real option? *Gynecol Oncol* 2005;99:S152-6.
  44. Duclos AJ, Haddad EK, Baines MG. Presence of activated macrophages in a murine model of early embryo loss. *Am J Reprod Immunol* 1995;33:354-66.
  45. Piccinni MP, Scaletti C, Maggi E, et al. Role of hormone-controlled Th1- and Th2-type cytokines in successful pregnancy. *J Neuroimmunol* 2000;109:30-3.
  46. Shelesnyak MC. Inhibition of decidual cell formation in the pseudopregnant rat by histamine antagonists. *Am J Physiol* 1952;170:522-7.
  47. Padilla L, Reinicke K, Montesino H, et al. Histamine content and mast cells distribution in mouse uterus: the effect of sexual hormones, gestation and labor. *Cell Mol Biol* 1990;36:93-100.
  48. Kunzmann S, Mantel PY, Wohlfahrt JG, et al. Histamine enhances TGF-beta1-mediated suppression of Th2 responses. *FASEB J* 2003;17:1089-95.

**Cite this article as:** Nakayama K, Razia S, Ishibashi T, Yamashita H, Kanno K, Ishikawa M, Sato S, Takeshita H, Kyo S. Oncologic and obstetric outcomes of a novel nerve-sparing radical trachelectomy while preserving the uterine branches of the pelvic nerves. *Transl Cancer Res* 2025;14(3):1567-1575. doi: 10.21037/tcr-24-1929