



Open Access

LETTER TO THE EDITOR

Operational Andrology

A novel approach: successful management of vasectomy reversal with a three-dimensional digital image microscope system

Peng Li^{1,2,*}, Er-Lei Zhi^{1,*}, Chen-Cheng Yao¹, Shu-Jie Xia^{1,2}, Zheng Li¹

Asian Journal of Andrology (2021) 23, 118–119; doi: 10.4103/aja.aja_15_20; published online: 12 May 2020

Dear Editor,

Microsurgical vasovasostomy, most commonly performed for vasectomy reversal, remains the most successful procedure for restoring patency to the vas deferens with the return of sperm to the ejaculate. Although the excellent results depend on the surgeon's skill and technique, optimal vision and ergonomics are also crucial factors contributing to the achievement of good results during male infertility microsurgery. Recently, the use of a new revolutionary technology, called three-dimensional (3D) digital image microscope with a video-assisted telescope operating monitor, may fill the gap between the need for good surgical vision and maintenance of a comfortable posture during surgery and may improve surgeon comfort. We present the first case report of vasovasostomy performed using the 3D digital image microscope system and discuss advantages and disadvantages compared with the use of an operating microscope.

The 3D digital image microscope system, which consists of a scope located over the surgical field that is supported by a mobile mechanical arm and projects to a screen, can easily fit all kinds of observation angles and can produce high-quality 3D videos of a small surgical field, with a high magnification capacity ($\times 1.9$ to $\times 39.3$) and a long working distance from 350 to 1000 mm; this system allows surgeons to work in a setting similar to that of endoscopic surgeries, with possibilities of application similar to those of operating microscopes. The application of an ordinary video camera has been reported for microvascular anastomosis;¹ furthermore, the 3D video-assisted telescope operating system has been used in cranial surgery and spinal surgeries.^{2–4}

Barros *et al.*¹ performed cranial surgery using a video-assisted telescope operating monitor and demonstrated that this system might have many advantages regarding ergonomics, versatility, and field depth compared with an operating microscope.¹ We first performed vasovasostomy on rats to validate the feasibility and safety of this system. The mechanic patency rate was 100% (8/8) for 3D digital image microscope-assisted vasovasostomy in the rat model (unpublished data), which revealed that it may be possible

to perform a vasovasostomy with the 3D digital image microscope in humans.

In August 2018, a 44-year-old male with an 18-year-old son from his first marriage was admitted to our hospital for obstructive azoospermia with a history of bilateral vasectomy 18 years ago. He remarried 4 years ago, and his wife had no infertility factors. Physical examination showed bilateral palpable vasal defects, no sperm granuloma, and normal testes. Semen analysis indicated that no sperm was detected, and scrotal ultrasound evaluation demonstrated dilated vas deferens and epididymal tubules. The sex hormones were all in the normal range. We spoke with the patient and his wife regarding the alternative procedure of assisted reproductive technology that may be helpful for the treatment of his infertility as well as the feasibility and safety of microsurgical vasovasostomy; eventually, they agreed to receive this procedure using the 3D digital image microscope. The procedure was approved by the Ethics Committee of Shanghai General Hospital (Shanghai, China), and informed consent was obtained from the patient.

The procedure was performed under the 3D digital image microscope (Mitaka Kohki, Mitaka, Japan) with $\times 1.9$ – $\times 39.3$ magnification, and the procedure is described in detail in the following steps: (1) the 3D digital image microscope was placed over the surgical field, the working distance was 350–1000 mm, and two surgeons stood on each side of the operating table in a natural position and viewed opposite monitors on both sides (**Figure 1**); (2) under the microscope with $\times 2$ – $\times 4$ magnification, a 3-cm vertical middle scrotal incision was made, and the testes were delivered; (3) the vas deferens was exposed at the prior vasectomy site, and both ends of the vas deferens were subsequently transected; (4) the abdominal end of the vas deferens was cannulated with a 24-gauge angiocatheter sheath to confirm the patency by injecting diluted methylene blue into the distal part of the vas deferens; (5) the fluid from the testicular end of the vas deferens was examined under light microscopy intraoperatively, and a few motile sperm were found; (6) both vasal ends were fixed with the microspike approximator clamp (ASSI Corporation, Westbury, NY, USA), and six microdots were marked on each side⁵ (**Supplementary Figure 1a**); (7) under the microscope with $\times 30$ – $\times 39.3$ magnification, three interrupted sutures of 10-0 single-armed monofilament proline were placed through only the mucosal layer of the vas deferens, and then the mucosal sutures were tied with a microsurgical knot (**Supplementary Figure 1b and 1c**);

¹Department of Andrology, Center for Men's Health, Urologic Medical Center, Shanghai General Hospital, Shanghai Jiao Tong University, Shanghai 200080, China; ²Department of Urology, Shanghai General Hospital of Nanjing Medical University, Shanghai 200080, China.

*These authors contributed equally to this work.

Correspondence: Dr. Z Li (lizhengboshi@163.com)

Received: 25 August 2019; Accepted: 15 January 2020

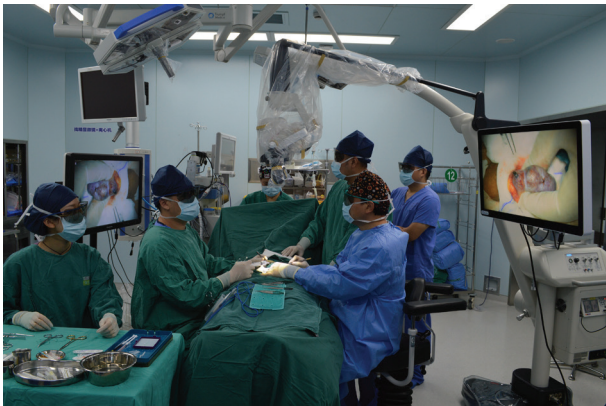

Figure 1: Operating room setup with the 3D digital image microscope system. The telescope, which is attached to its holding arm and comes from the assistant's right side, is held over the surgical field. The assistant sits on the opposite side of the surgeon. The surgeon controls the microscope with the use of a foot pedal. One video monitor is positioned on the surgeon's side, and another is positioned on the assistant's side. The entire surgical staff have the same view as the surgeon via the use of polarization glasses through the video monitor. 3D: three-dimensional.

(8) the placement of sutures in the muscularis and adventitial layer was located precisely in between the two previous mucosal sutures with a 9-0 monofilament proline single-armed needle; and (9) the approximator was turned over and folded in the opposite direction to expose the back wall of the anastomosis (**Supplementary Figure 1d**). The mucosal layer was approximated with six interrupted 10-0 monofilament sutures, and twelve interrupted 9-0 sutures were placed to close the muscularis and adventitial layer. The entire procedure lasted 245 min and was captured on a 3D digital high-definition video.

There were no complications after surgery. During the 6-week follow-up, the semen analysis showed that the sperm concentration was $63.0 \times 10^6 \text{ ml}^{-1}$, and the progressive sperm rate was 2.0%; however, during the 4-month follow-up, the sperm concentration was $131.0 \times 10^6 \text{ ml}^{-1}$, and the progressive sperm rate was 52.0%.

A previous study showed that the 2D digital exoscope system was comparable to an operative microscope but provided better visual quality and greater comfort for the surgeon, so it is a safe tool to perform common spinal and cranial surgeries.⁶ Currently, the 3D digital image system is gradually entering into surgical practice, although only a few cases have been treated using this tool.^{2,3} The data on the exoscope systems report comparable results with the conventional microscope with good image quality and illumination in spine and cranial surgeries.^{2,7} Barbagallo and Certo⁴ consider that exoscope-assisted surgery may become a safe and effective alternative to microscope-assisted surgery for anterior cervical discectomy and fusion. To the best of our knowledge, this is the first report describing the 3D digital image microscope system for vasectomy reversal. It is known that the operating microscope has some drawbacks: surgeons have to maintain positions that may cause back or neck pain and increase fatigue, and the depth of field is so narrow that refocusing must occur after each movement.

Based on our preliminary experience with microsurgical anastomosis, working in a natural position when watching a 3D video monitor placed in front of the surgeon can relieve stress on the neck and back to reduce fatigue, and the visual quality can equalize the stereopsis guaranteed by the 3D digital image microscope. Moreover, the surgeon can shift from microscopic to macroscopic views rapidly and easily without moving the scope. Other advantages were found

in our preliminary experience with the 3D digital image system, such as the bionic design for a natural view with a real sense for the depth of the field, the precise left- and right-eye image alignment for a natural review, and the ease of image sharing. Owing to the direct 3D intraoperative view on a wide screen, the assistant can better experience the surgical operation and the surgeon's actions. Therefore, the 3D digital image system may play a significant role in education and training.

However, the 2K 3D video monitor might limit the use of this system. The 4K 3D system will be better, but this system depends on the development of the technology of the microscope system. Hayden *et al.* reported that the 4K 3D video microscope may have a promising future in reconstructive macrovascular and microsurgery (available from: <http://epub.aunet.org/publication/?m=52864&i=587124&p=6>; last accessed on 30 March 2020).

To our knowledge, this is the first report of vasovasostomy performed using a revolutionary 3D digital image microscope with a video-assisted telescope operating monitor. The significant improvement in surgeon comfort and the improved field depth will promote the widespread use of the revolutionary 3D digital image microscope system in the field of male infertility in the future.

AUTHOR CONTRIBUTIONS

PL and ELZ performed the surgery. PL, ELZ, and CCY drafted the manuscript. SJX participated in its design and helped to draft the manuscript. ZL conceived of the study, participated in its design and coordination, and helped draft the manuscript. All authors read and approved the final manuscript.

COMPETING INTERESTS

All authors declared no competing interests.

ACKNOWLEDGMENTS

This work was supported by grants from the National Nature Science Foundation of China (No. 81701524/81871215) and the Strategic Priority Research Program of the Chinese Academy of Sciences (XDA16020701).

Supplementary Information is linked to the online version of the paper on the *Asian Journal of Andrology* website.

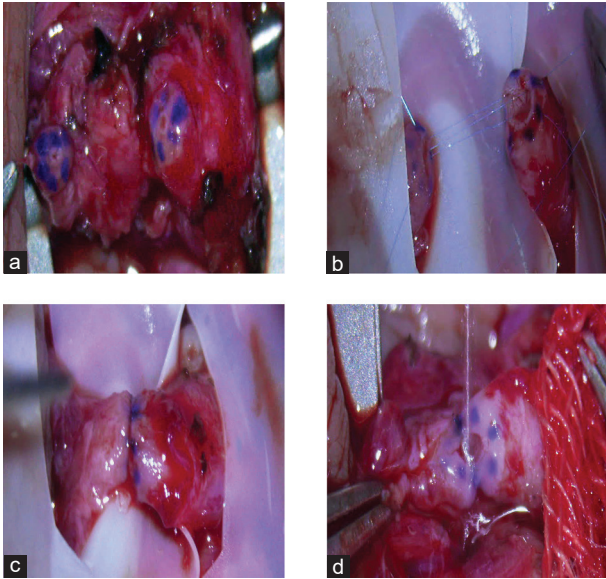
REFERENCES

- Barros RS, Brito MV, Moura GP, Moura MP, Freitas LM, *et al.* Is it possible to do a microvascular anastomosis with an ordinary video camera? Experimental study. *J Reconstr Microsurg* 2011; 27: 503–8.
- Rossini Z, Cardia A, Milani D, Lasio GB, Fornari M, *et al.* VITOM 3D: preliminary experience in cranial surgery. *World Neurosurg* 2017; 107: 663–8.
- Oertel JM, Burkhardt BW. Vitom-3D for exoscopic neurosurgery: initial experience in cranial and spinal procedures. *World Neurosurg* 2017; 105: 153–62.
- Barbagallo GM, Certo F. Three-dimensional, high-definition exoscopic anterior cervical discectomy and fusion: a valid alternative to microscope-assisted surgery. *World Neurosurg* 2019; 130: e244–50.
- Goldstein M, Li P, Matthews GJ. Microsurgical vasovasostomy: the microdot technique of precision suture placement. *J Urol* 1998; 159: 188–90.
- Muhammad S, Lehecka M, Niemelä M. Preliminary experience with a digital robotic exoscope in cranial and spinal surgery: a review of the Synaptive Modus V system. *Acta Neurochir (Wien)* 2019; 161: 2175–80.
- Takahashi S, Toda M, Nishimoto M, Ishihara E, Miwa T, *et al.* Pros and cons of using ORBEYE for microneurosurgery. *Clin Neurol Neurosurg* 2018; 174: 57–62.

This is an open access journal, and articles are distributed under the terms of the Creative Commons Attribution-NonCommercial-ShareAlike 4.0 License, which allows others to remix, tweak, and build upon the work non-commercially, as long as appropriate credit is given and the new creations are licensed under the identical terms.

©The Author(s)(2020)





Supplementary Figure 1: Surgical intervention performed with the 3D digital image microscope system. (a) Six microdots marked on each vasal end; (b) Three interrupted sutures of 10-0 single-armed monofilament proline placed through the mucosal layer of the anterior part of the vas deferens; (c) the mucosal sutures tied with a microsurgical knot; (d) the approximator turned over and folded in the opposite direction to expose the back wall of the anastomosis. 3D: three-dimensional.