



Contents lists available at ScienceDirect

## Journal of Ayurveda and Integrative Medicine

journal homepage: <http://elsevier.com/locate/jaim>

## Case Report

## Ayurveda co-interventions have supported complete recovery in severe COVID-19 infection with a chest severity score 18/25: A case report



Sanjeev Rastogi

Department of Kaya Chikitsa, State Ayurvedic College and Hospital, Lucknow University, Lucknow, 226003, India

## ARTICLE INFO

## Article history:

Received 22 December 2020

Received in revised form

13 February 2021

Accepted 27 February 2021

Available online 12 March 2021

## Keywords:

Chest severity score

Hypoxia

Integrative care

Severe COVID-19

## ABSTRACT

Severe COVID-19 infection requiring oxygen support is reported to have high mortality. Chest Severity Score evaluated through CT scan has a predictive value about future outcomes in such cases. Score value  $\sim 18$  is predicted to have poor outcomes. We are presenting here a case of severe COVID-19 with all predictors suggestive of a bad prognosis including IL-6, D-Dimer, Ferritin and CRP in addition to 18/25 Chest Severity Score. Initially treated under ICU care at a tertiary care COVID hospital for about 14 days, the patient was intervened with Ayurveda on his own insistence seeing the unsatisfactory improvements. Ayurveda intervention for 19 days along with standard ICU care resulted in complete clinical recovery of the patient besides the correction of biomarker levels. Rapid clinical and biochemical correction in this severe COVID-19 case against all odds is highly significant and warrants an urgent search for possibility of instituting the integrative management strategies for all those treated in an allopathic facility. This case also advocates an early institution of Ayurveda interventions in COVID-19 in order to prevent deterioration leading to complications.

© 2021 The Authors. Published by Elsevier B.V. on behalf of Institute of Transdisciplinary Health Sciences and Technology and World Ayurveda Foundation. This is an open access article under the CC BY-NC-ND license (<http://creativecommons.org/licenses/by-nc-nd/4.0/>).

## 1. Introduction

Ayurveda physicians often get the opportunities to intervene in cases where modern medicine had shown limitations owing to the bad prognosis or limited treatment options. If not all, at least some of these cases eventually benefit from such interventions. A very few among these successful interventions however are documented. This non documentation of meaningful interventions in intractable conditions is largely attributed to the unfamiliarity of Ayurveda physicians with scientific writing and meticulous record keeping. Such observations of benefits however have proven to be of immense value in the lives of the beneficiaries. From research perspectives, all these observations may have a potential to act as strong cues demanding further exploration for their possible generalisation.

COVID-19 pandemic has presented numerous such opportunities before Ayurveda physicians where novelty of the disease and absence of clear cure has come as a compulsion to many for the

search of other pragmatic alternatives [1]. Ayurveda physicians invariably treated many of such cases in their individual capacities and met with success in terms of reduced complications, improved recovery rate and reduced hospital stay. Such cases are treated either in an integrative model using Ayurveda in an 'add on' mode upon the insistence of the patients or as the stand alone therapy where Ayurveda has been instituted as the sole intervention modality. A few of such cases having variable stages of COVID-19 related pathology and treated through Ayurveda are reported in literature [2,3]. As a response to the pandemic, Ayurvedic classical literature has been critically revisited in the context and many novel propositions including rephrasing the COVID-19 pathophysiology in terms of Ayurveda has been attempted [4,5]. Many clinical trials on Ayurvedic formulations and their role in SARS-CoV-2 infection are underway and their results are eagerly awaited [6]. In this background, we present here a case of 52 year old male having severe breathlessness with COVID related Chest Severity Score (CSS) 18/25 and CT scan showing intermediate phase changes in lungs (CORADS-6) due to COVID-19 infection, diagnosed as a RT-PCR positive case of severe COVID-19 and was admitted to Intensive Care Unit of a tertiary care hospital. He constantly required oxygen support as without oxygen his SPO2 was reported

E-mail: [rastogisanjeev@rediffmail.com](mailto:rastogisanjeev@rediffmail.com).

Peer review under responsibility of Transdisciplinary University, Bangalore.

as low as 64%. On the basis of various biomarkers related to the prognosis of COVID-19 infection, he was identified as severe COVID-19 case with poor prognosis. In this condition, facing the state of hopelessness with on-going care, he sought Ayurveda opinion. Upon initiation of the Ayurveda therapy along with standard ICU care while the patient was still in ICU, in next three days, he was able to breath at his own without any supplemental oxygen need for as long as 45 min. On 6th day of initiation of Ayurveda medications, he was able to breathe without additional oxygen support. Subsequent blood and biochemical investigations have shown remarkable improvement on all parameters.

Although the case was on standard COVID care in a tertiary care hospital, the improvements were not satisfactory till 16th day of his admission in the ICU. The improvements were visible only after the initiation of Ayurveda therapy. After 26 days spending in the ICU, the patient was shifted to High Dependency Unit (HDU) and was finally discharged from the hospital on 33rd day of his admission.

Improvements seen in this case after the initiation of Ayurveda therapy were remarkable and worthy of getting noticed for two obvious reasons. One is that it highlights the potential of Ayurveda interventions in many intractable conditions even when the patients are receiving ICU care. This was argued earlier also that Ayurveda should be given an access to ICUs for active treatment at least in the conditions where standard care have not shown much to offer [7]. Second and even more important message is that such cases, for their novelty, unusualness and demonstrable clinical benefits should be taken as important cues of future research. Serious clinical trials therefor should be planned to establish the feasibility of such interventions in larger population. This inference has a high significance in current pandemic where the real cures proven through robust and generalizable evidence are still awaited. Our observations as a case report are placed on record in order to see the generalizability of such interventions proven through larger systematic studies. Till such cures are in sight, any proposition offering a reduction in the morbidity and improved survival in COVID-19 seems to have a great value.

## 2. Patient information

This case is about a 52 year old, resident of Delhi, average built, otherwise healthy (without any known co-morbidity relevant to COVID-19) and a non-smoker male who was infected with SARS-CoV-2 infection confirmed by RT-PCR test (11.11.2020).

## 3. Clinical Findings

Corresponding Coronavirus disease 2019 (COVID-19) Reporting and Data System (CO-RADS) score –6 on CT scan (18.11.2020). CO-RADS 6 is strongly suggestive of lung changes due to SARS-CoV-2 infection. Chest severity score (CSS) calculated on the basis of radiological findings was found to be 18/25 which was associated with a high risk of mortality (Table 1). Since the initial onset of fever and flu like symptoms (running nose, sore throat, cough, head ache 21.10.2020) till the diagnosis of SARS-CoV-2 infection by RT-PCR test, the patient was receiving home based care inclusive of hot water drinking and gargling, steam inhalation, analgesic, antipyretic and antihistamine. In addition to this, he has received *AYUSH quath* and *Chyawanprash* as per the recommendations of Ministry of Ayush. Additional antibiotic (Azithromycin), antiviral (Favipiravir) and antiplatelet (Low dose aspirin) was added upon the SARS-CoV-2 infection confirmation. Initially there was no breathlessness but the cough and breathless gradually set in requiring a shifting of patient to DRDO-COVID Hospital, New Delhi where he was admitted in ICU (18.11.2020). Since then he was continuously kept on Oxygen as he was not able to breathe on his own without

**Table 1**

CT scan lung findings and Chest Severity Score (18.11.2020).

Lobe score	(0–5)
Right upper lobe	3
Right middle lobe	3
Right lower lobe	4
Left upper lobe	4
Left lower lobe	4
CT chest severity score	18/25

There is evidence of extensive large ill-defined confluent areas of ground glass attenuation in bilateral lungs involving all the lobes with peri-broncho-vascular and peripheral sub-pleural distribution pattern and few superimposed linear fibro-atelectatic densities. Findings are suggestive of early/intermediate phase changes of Covid 19 infection (CORADS-6).

additional oxygen support. Without oxygen support, his SPO2 was reported to be as low as 64%. Blood investigations carried out on 18.11.2020 were suggestive of bad prognostic values for all the severity predictors including D-Dimer, CRP, IL-6 and Ferritin (Table 2). A high total count (17,280) was reported on 1.12.2020 indicated steroids used in the case. Despite being under standard ICU care till 2.12.2020, his condition did not improve much.

## 4. Ayurvedic Interventions

In the state of hopelessness, he sought Ayurveda intervention. After a tele-consultation he was recommended *Chausath Prahari Pippali* (CPP) 500 mg twice in a day, *Shringarabhra rasa* (SR) 125 mg twice in a day and *Amrit Bhallataka* (AB) 2.5 g twice in a day. CPP and SR were started from 3.12.2020 whereas AB was started only from 6.12.2020. He continued to be in standard ICU care as usual with oxygen support. The patient reported to feel positive from the very first day of start of Ayurveda intervention. His dependency upon oxygen started reducing on the following days. From 9.12.2020 he reported to sustain without oxygen support for ~45 min. He continued with Ayurvedic intervention along with ICU standard care. On 11.12.2020 his RT-PCR became negative. He still required oxygen support but his dependency on it continued to reduce as he was able to sustain for longer periods without additional oxygen support. On 12.12.2020 his blood investigations were carried out and most prognosis indicators of SARS-CoV-2 infection were found to be in normal range (Table 2). From 12.12.2020 he did not require any oxygen support. On 14.12.2020 he was shifted from ICU to HDU. He continued the standard care and also the Ayurveda medications. He continued to improve on following days and finally discharged from the hospital on 21.12.2020.

## 5. Followup and outcomes

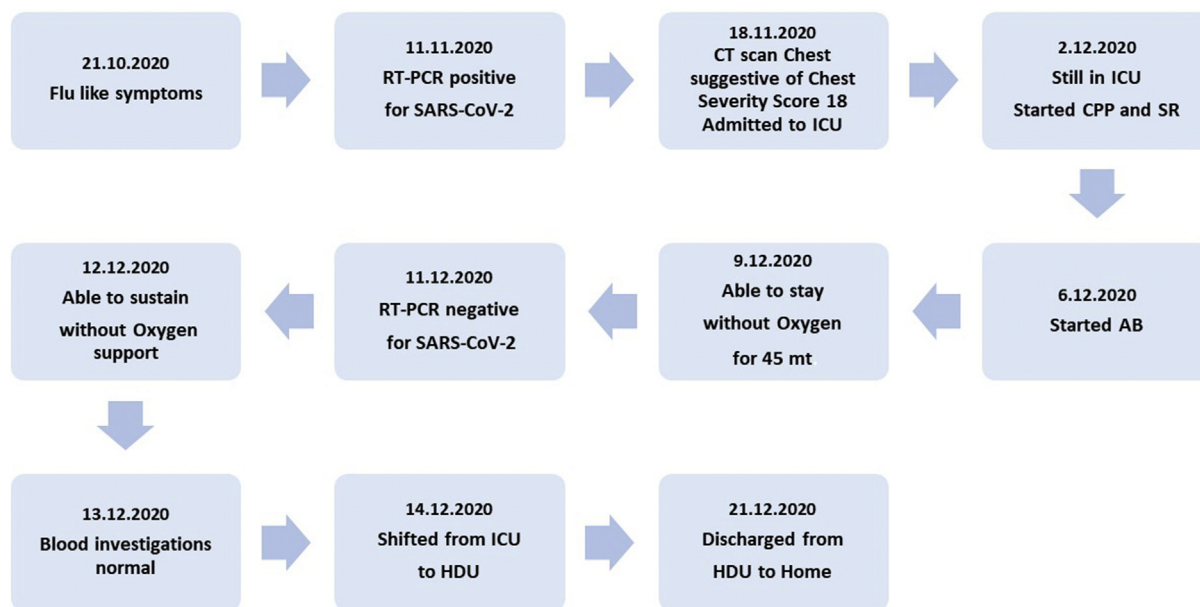
Although, the patient was on simultaneous standard ICU and HDU care for ~ 1 month, he largely attributed his improvements to Ayurveda interventions which were started from 2.12.2020 and continued till his discharge (19 days). A narrative of patient's perspective of the case is appended at the end of this case report. A time line of major events in the course of illness is appended as Fig. 1.

## 6. Discussion

There has been a recent report on outcomes of Ayurvedic care in a COVID-19 patient with severe hypoxia [2]. The case presented here although observes similar outcomes, is noteworthy for two important reasons. One is that the patient here was receiving the ICU care in a tertiary care hospital for over 2 weeks and decided to

**Table 2**  
Blood Investigations before and after Ayurveda intervention.

Parameters	Units	Values on 18.11.2020 (before Ayurvedic Intervention)	Values on 1.12.2020 (before Ayurvedic Intervention)	Values on 12.12.2020 (after Ayurvedic Intervention)	
Haemoglobin	g/dL	14.9	14.8	12.7	
Total Leucocyte Count	Cumm	5300	17,280	7700	
RBC	Million/cumm	6.82	—	—	
Platelets	Lacks/cumm	1.56	4.16	1.20	
Neutrophils	%	84	86	70	
Lymphocytes	%	07	11	28	
Monocytes	%	08		01	
Eosinophil	%	01		01	
Basophils	%	0		0	
PCV	%	47.5		39.8	
MCV	pl	69.6		70.4	
MCH	pg	21.8		22.5	
MCHC	%	31.4		31.9	
RDW	%	16.8		42.9	
D-Dimer	Ng/ml	973.90		225.0	76.88%↓
CRP	Mg/l	87.90		14.70	83.28%↓
IL-6	Pg/ml	149.40		6.53	95.63%↓
Ferritin	Ng/ml	339		353.4	4.1%↑
LDH	U/L	—		328.8	
Urea	Mg/dl	—	30.5	17	
Creatinine	Mg%	—	1.06	0.89	
BUN	Mg%	—		7.94	
S. Bilirubin	Mg/dL	—		1.15	
SGOT	IU/L	—		21.9	
SGPT	IU/L	—		31.7	
Alkaline Phosphatase	U/L	—		130.60	
S Sodium	Mmol/L	—	133	137	
S Potassium	Mmol/L	—	3.8	4.45	



**Fig. 1.** Major events and their time line.

add on Ayurveda interventions only when there was unsatisfactory improvement in the condition. He further had all biomarkers indicative of severity of the disease and bad prognosis. On the coronavirus disease 2019 (COVID-19) Reporting and Data System (CO-RADS) which is developed as a categorical system to assess suspicion of lung involvement by COVID-19 on chest CT scans he

was found CO-RADS 6, a condition with positive RT-PCR and bilateral Ground Glass Opacity (GGO) and halo sign [8]. Chest Severity Score (CSS) which is a rapid identifier of patients with severe forms of coronavirus disease 2019 was found 18/25 in this case. A CT score of  $\geq 18$  is reported to be associated with an increased mortality risk and is found to be predictive of death both

in univariate and multivariate analysis [9]. In this condition, a complete clinical recovery along with reversal of most biomarkers related to the disease severity within 19 days of initiation of Ayurveda intervention along with standard ICU and HDU care is remarkable and needs the utmost attention.

This case was treated through a *vyadhipratyanik* approach of Ayurveda where the disease complex is targeted *in toto* through specific interventions. Three medicines (CPP, SR and AB) which have been given to the case were mainly *vata-kapha shamak* in nature which is presumed to be the principal pathology in SARS-CoV-2 infection [4]. From Ayurveda perspectives, lungs are invariably the seat of *vata* and *kapha*. *Pippali* (*Piper longum*) as the sole ingredient in the CPP is recommended as *rasayana* to *pranavaha srotus* which is rooted in lungs [10]. SR is a highly praised drug in respiratory conditions dominated by *vata-kapha* pathology [11]. AB where *Bhallataka* (*Semicarpus anacardium*) is the principal component is a highly praised *kapha shamak* drug [12]. All these drugs recommended in the case are used in ayurvedic clinical practice since long and have not been reported with any adversity during their monitored use. Failure of standard recommendation of Ayurveda immune enhancive therapy in preventing the disease and its complications as is noted in the case is another important observation. This is observed that such recommendations in general reduce the intensity of the disease and hence promote its benign course but do not prevent the disease from occurrence in every individual [13]. Much research is still required to understand the preventive and disease modifying potential of standard Ayurveda recommendations in COVID-19.

Although *vyadhi bala*, *rogi bala* and *dosha avastha* should have been examined before prescribing a drug from Ayurvedic perspective, we see that in COVID-19 where consultations are largely offered in a tele-consultation mode [14] a knowledge about the *roga* and *rogi bala* is largely procured through telephonic enquiry. We adopted the similar method of disease assessment and in our case the *roga* and *rogi* both were found to be of *pravara bala*.

Ayurvedic physicians are often approached when the conventional health care fails to deliver what is actually desired. This is done often in the intractable cases with poor prognosis or in the conditions where the conventional approach is rejected by the patient. In many instances, such alternative interventions have resulted in improvements and cures which were not deliverable through conventional care despite of standard care approaches. Such observations have been noticed in variety of conditions including traumatic brain injury [15], Spinal cord injury [16], atonic bladder [17], Hepatic encephalopathy [7], metastatic liver disease [18] and achalasia [19].

A disease condition which was novel and was available in a pandemic proportion has given the health care systems an unprecedented opportunity to learn, to reinvent and to repurpose every bit of knowledge which could have been of help to mitigate the disease [20,21]. In the absence of a definitive cure anywhere in sight, this is natural for the people to look at alternative health care solutions. Although not utilised to the full of its potential, Ayurveda continued to show the evidence of its effectiveness in various stages of SARS-CoV-2 infection. Ayurveda responded to the pandemic initially by exploring its textual wisdom to find the clues for the disease management and subsequently it offered care to many cases who demanded individualised Ayurveda care. More clinical trials are underway and are expected to generate dependable evidences about possible role of Ayurveda in COVID-19. The observations made through such single case reports however are also significant for their possibility of getting converted into robust evidences following the systematic clinical trials. Ayurvedic case reports and clinical trials in the context of COVID-19 are also meaningful from an entirely different perspective. This is observed

that the cases are treated differently following different protocols based on the individual logics and judgments. This variability of protocols reaching to successful outcomes is a clear example of versatility of Ayurveda interventions and its treatment personalisation approach.

Although valuable, such case reports in Ayurveda are inherently deficient in precise details of the disease process and changes in response to the given interventions. Being retrospective in nature, such cases in Ayurveda are largely reported only when the outcome of interest has already arrived. This implies for two important limitations of such reporting. One is that the cases where the desired outcomes are not achieved are never reported and hence the limitations of Ayurvedic interventions in unsuccessful cases do not see the light of the day. Second limitation is that a clear reasoning of intervention and its effects is always difficult to interpret in the presence of other variables and confounding factors including any on-going therapy. This case report should essentially be viewed in light of these limitations related with retrospective case reporting in Ayurveda.

## 7. Conclusion

Severe COVID-19 associated with respiratory distress corresponding to the high chest severity score and raised specific biomarkers like IL-6, CRP, Ferritin and D-Dimer has invariably been associated with poor outcomes. Studies have revealed that the mortality rate for Covid-19 positive critically ill patients receiving ICU care can be very high [22,23] In India although the mortality among critically ill COVID-19 patients with respiratory failure is reported to be slightly lower [24], it is expected to be of much higher value if reported correctly [25].

In this background, improved outcome in such critically ill patients, reducing complications, reduced stay in hospitals, and recovery, should be the main points of focus. An integrative strategy for hospitalised patients which uses Ayurvedic management strategies is expected to improve the outcome and minimise risk. This case report highlights that despite prolonged hospitalisation in an ICU, Ayurvedic intervention can prevent deterioration leading to complications, and enable complete recovery.

## 8. Patient Perspectives

Patient's Perspectives (Excerpts from the whatsapp messages received from the patient).

I have been discharged and am finally home now after 33 days. Fresh air and evening sun reminded me that I am alive!! I have no words to express my deep gratitude to Ayurveda and to you for your kind concern, support, medical advice, motivation, wishes and prayers. I'm deeply indebted to you for this new lease of life.

I am still unable to believe that I have returned home alive. I was admitted on Nov 18, 2020 when my condition had gone worst. My SpO<sub>2</sub> level dipped to 64 that evening. Right from the morning I was unable to breathe. While I was in ICU- during the first five days, I prayed to God and to doctors to allow me go home only for a day ... excluding night, so that I can tell my wife about my bank account and give her legal authorisation to withdraw money from my salary account which is not a joint account. Just wanted to have last glimpse of my son and wife!! Because I started realising that my days were numbered. And on any day I would be off, especially after I was declared of having Pneumonia.

Facing death so close was rarest of experience. I virtually saw death in front of me but also felt the presence of super consciousness, or Supreme power which we call God ... who pulled me out of that. So today being at home, I have no words to express myself.



Inner strength genuinely came, once I became assured that the 3 Ayurvedic medicines you gave me would actually heal my lungs infection and strengthen it. Prior to that even after taking allopathic medicines I wasn't getting that confidence. My father in law proved it as he didn't take any allopathic medicine as he took only Ayurvedic medicines for 7 days. I am also indebted to you for boosting my morale and your kind support, to the extent of sending me medicines from Lucknow.

## 9. Informed Consent

Informed Consent has been obtained from the patient regarding the initiation of Ayurveda intervention in his case. Consent has also been obtained for publication of his case report for the purpose of dissemination of knowledge among medical fraternity.

## Source(s) of funding

None.

## Conflict of interest

None.

## References

- [1] Rastogi S, Pandey DN, Singh RH. COVID-19 pandemic: a pragmatic plan for ayurveda intervention. *J Ayurveda Integr Med* 2020;S0975–9476(20):30019. <https://doi.org/10.1016/j.jaim.2020.04.002> [published online ahead of print, 2020 Apr 23].
- [2] Joshi JA, Puthiyedath R. Outcomes of Ayurvedic care in a COVID-19 patient with hypoxia - a Case Report. *J Ayurveda Integr Med* 2020. <https://doi.org/10.1016/j.jaim.2020.10.006> [published online ahead of print, 2020 Oct 13].
- [3] Girija PLT, Sivan N. Ayurvedic treatment of COVID-19/SARS-CoV-2: a case report. *J Ayurveda Integr Med* 2020;S0975–9476(20):30042–5. <https://doi.org/10.1016/j.jaim.2020.06.001> [published online ahead of print, 2020 Jun 19].
- [4] Puthiyedath R, Kataria S, Payyappallimana U, Mangalath P, Nampoothiri V, Sharma P, et al. Ayurvedic clinical profile of COVID-19 - a preliminary report. *J Ayurveda Integr Med* 2020;S0975–9476(20):30039–45. <https://doi.org/10.1016/j.jaim.2020.05.011> [published online ahead of print, 2020 Jun 12].
- [5] Gautam S, Gautam A, Chhetri S, Bhattarai U. Immunity against COVID-19: potential role of Ayush Kwath. *J Ayurveda Integr Med* 2020. <https://doi.org/10.1016/j.jaim.2020.08.003> [published online ahead of print, 2020 Aug 17].
- [6] Bhapkar V, Sawant T, Bhalerao S. A Critical Analysis of CTIR registered AYUSH studies for COVID- 19. *J Ayurveda Integr Med* 2020. <https://doi.org/10.1016/j.jaim.2020.10.012> [published online ahead of print, 2020 Nov 26].
- [7] Rastogi S, Srivastav PS. Ayurveda in critical care: Illustrating Ayurvedic intervention in a case of hepatic encephalopathy. *Ayu* 2011;32(3):345–8. <https://doi.org/10.4103/0974-8520.93911>.
- [8] Prokop M, van Everdingen W, van Rees Vellinga T, Quarles van Ufford H, Stöger L, Beenen L, et al., COVID-19 Standardized Reporting Working Group of the Dutch Radiological Society. CO-RADS: a categorical CT assessment Scheme for patients suspected of having COVID-19-definition and evaluation. *Radiology* 2020;296(2):E97–104. <https://doi.org/10.1148/radiol.2020201473>.
- [9] Francone M, Iafate F, Masci GM, Coco S, Cilia F, Manganaro L, et al. Chest CT score in COVID-19 patients: correlation with disease severity and short-term prognosis. *Eur Radiol* 2020;30(12):6808–17. <https://doi.org/10.1007/s00330-020-07033-y>.
- [10] Gaur BL. Hindi translation of Charaka Samhita, Chikitsa sthan, Adhyaya 1 Pada 3 Verse 32-35. New Delhi: Rashtriya Ayurveda Vidyapeeth; 2014.
- [11] Sen Govind Das, Ratnavali Bhaishjya. Eng translation by Rao prabhakar G. Varanasi: Chaukhambha Orientalia; 2014. p. 604–5.
- [12] Ayurveda Sarsamgraha. Shri Baidyanath ayurveda bhavan limited. 2004. p. 528. Nagpur.
- [13] Rastogi S, Rastogi R, Kharbanda A. Time when a physician turned out to be a patient: A case study on how an ayurvedic physician cured himself from COVID-19. *J Ayurveda Integr Med* 2021 Feb 25. <https://doi.org/10.1016/j.jaim.2021.02.002>. Epub ahead of print.
- [14] Rastogi S, Singh N, Pandey P. On the brighter side of COVID-19 induced Lockdown: Devising the collateral methods to provide Ayurveda consultation during impasse. *J Ayurveda Integr Med* 2020 May 8. <https://doi.org/10.1016/j.jaim.2020.05.001>.
- [15] Rastogi S. Coma with Glasgow coma Scale score 3 at admission following Acute head injury: experiencing the complete recovery supported through ayurveda - a case report. *Complement Med Res* 2019;26(5):353–60. <https://doi.org/10.1159/000498912>. Epub 2019 Apr 9. PMID: 30965329.
- [16] Rastogi S. Rehabilitative potential of Ayurveda for neurological deficits caused by traumatic spinal cord injury. *J Ayurveda Integr Med* 2014 Jan;5(1): 56–9. <https://doi.org/10.4103/0975-9476.128868>. PMID: 24812477; PMCID: PMC4012364.
- [17] Rastogi S. Low-pressure, low-flow voiding dysfunction in an elderly male treated through ayurveda: a case report. *J Evid Based Complementary Altern Med* 2017 Oct;22(4):846–50. <https://doi.org/10.1177/2156587217712764>. Epub 2017 Jun 7. PMID: 28592135; PMCID: PMC5871289.
- [18] Rastogi S, Rastogi R. Ayurvedic intervention in metastatic liver disease. *J Alternative Compl Med* 2012 Jul;18(7):719–22. <https://doi.org/10.1089/acm.2011.0351>. PMID: 22830973.
- [19] Rastogi S, Chaudhari P. Ayurvedic management of achalasia. *J Ayurveda Integr Med* 2015 Jan-Mar;6(1):41–4. <https://doi.org/10.4103/0975-9476.146556>. PMID: 25878463; PMCID: PMC4395928.
- [20] Rastogi S, Singh RH. Taking lessons from the current pandemic to prepare for the future. *AAM* 2020;9(3):144–7. <https://doi.org/10.5455/AAM.1603468291>.
- [21] Rastogi S, Singh RH. In the context of COVID-19 and Ayurveda: few quick takeaways India may wish to have. *AAM* 2020;9(2):64–6. <https://doi.org/10.5455/AAM.110497>.
- [22] Chaddha U, Kaul V, Agrawal A. What is the True mortality in the critically ill patients with COVID-19? *Indian J Crit Care Med* 2020;24(6):383–4.
- [23] Fraser DD, Cepinskas G, Patterson EK, Slessarev M, Martin C, Daley M, et al. Novel outcome biomarkers identified with targeted proteomic Analyses of Plasma from critically ill coronavirus disease 2019 patients. *Crit Care Explor* 2020 Aug 24;2(9):e0189. <https://doi.org/10.1097/CCE.0000000000000189>. PMID: 32904064; PMCID: PMC7449255.
- [24] Shukla U, Chavali S, Mukta P, Mapari A, Vyas A. Initial experience of critically ill patients with COVID-19 in western India: a case series. *Indian J Crit Care Med* 2020 Jul;24(7):509–13. <https://doi.org/10.5005/jip-journals-10071-23477>. PMID: 32963432; PMCID: PMC7482330.
- [25] Chatterjee P. Is India missing COVID-19 deaths? *Lancet* 2020 Sep 5;396(10252):657. [https://doi.org/10.1016/S0140-6736\(20\)31857-2](https://doi.org/10.1016/S0140-6736(20)31857-2). PMID: 32891197; PMCID: PMC7470692.