

## Deep Brain Stimulation Case Files

## Deep Brain Stimulation Management of Essential Tremor with Dystonic Features

Amar Patel<sup>1\*</sup>, Wissam Deeb<sup>2†</sup> & Michael S. Okun<sup>2†</sup>

<sup>1</sup> Department of Neurology, Yale School of Medicine, Yale University, New Haven, CT, USA, <sup>2</sup> Fixel Center for Neurological Diseases, Program for Movement Disorders and Neurorestoration, Department of Neurology, University of Florida, Gainesville, FL, USA

### Abstract

**Clinical Vignette:** A 64-year-old female with essential tremor (ET) presents for evaluation of deep brain stimulation (DBS) candidacy. Examination revealed subtle dystonic features as well as a disabling postural-action tremor.

**Clinical Dilemma:** Can dystonia occur in the setting of the diagnosis of ET and can its presence alter DBS target selection?

**Clinical Solution:** Unilateral DBS implantation of the ventralis intermedius (Vim) led to improvement in both tremor and dystonic posturing.

**Gap in Knowledge:** Case reports of DBS in dystonic tremor suggest Vim, globus pallidus internus (GPi), and subthalamic targets may all be effective, to varying degrees, in improving both tremor and dystonia. More rigorous studies are needed to identify the optimal target(s).

**Expert Commentary:** This case underscores the limited evidence available to guide a clinician's choice of DBS targets in patients with ET and dystonia. The severity of the dystonia and the presence of more generalized dystonia may alter the thinking about optimal targeting. Vim, GPi, and subthalamic targets appear potentially acceptable options, though Vim is usually the first target attempted when postural-action tremor is the chief complaint. Occasionally, a second rescue DBS lead may be necessary.

**Keywords:** Essential tremor, dystonia, dystonic tremor, deep brain stimulation

**Citation:** Patel A, Deeb W, Okun MS. Deep brain stimulation management of essential tremor with dystonic features. *Tremor Other Hyperkinet Mov.* 2018; 8. doi: 10.7916/D8P85VBQ

<sup>†</sup>This author contributed to the expert commentary section and edited the manuscript for clarity.

\*To whom correspondence should be addressed. E-mail: amar.patel@yale.edu

**Editor:** Elan D. Louis, Yale University, USA

**Received:** March 12, 2018 **Accepted:** May 22, 2018 **Published:** June 20, 2018

**Copyright:** © 2018 Patel et al. This is an open-access article distributed under the terms of the Creative Commons Attribution–Noncommercial–No Derivatives License, which permits the user to copy, distribute, and transmit the work provided that the original authors and source are credited; that no commercial use is made of the work; and that the work is not altered or transformed.

**Funding:** None.

**Financial Disclosures:** None.

**Conflict of Interest:** The authors report no conflict of interest.

**Ethics Statement:** All patients that appear on video have provided written informed consent; authorization for the videotaping and for publication of the videotape was provided.

### Clinical vignette

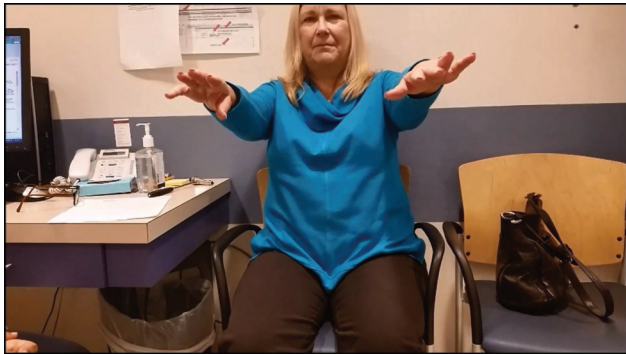A 64-year-old right-handed female presented for evaluation of deep brain stimulation (DBS) candidacy. She had medically refractory familial essential tremor (ET) of 40 years' duration. The tremor was present with action and improved transiently with alcohol. Propranolol, primidone, and topiramate provided either insufficient benefit or resulted in adverse effects. Her tremor progressed to significantly impact her ability to write, type, and cook. On examination there was a mild vocal tremor with sustained phonation of vowels. There was neither head tremor nor abnormal head posture. A postural and intention tremor was observed in both hands, the left greater than the right. With the hands outstretched there was slight dystonic posturing

of the digits and an occasional “jerky” tremor quality. There were no decrements in the cadence or amplitude of rapid movements, though the left hand and leg were slightly uncoordinated (Video 1). Neuropsychological testing was normal. A DaTscan<sup>TM</sup> revealed no evidence of dopaminergic deficiency.

### Clinical dilemma

This scenario illustrates two clinical problems that may confront providers trying to establish the optimal course of action for addressing refractory tremor with DBS therapy. First, it unearthed fundamental issues regarding phenomenology and diagnosis of the tremor. Can ET be diagnosed in the presence of dystonia or gait impairment?

Second, does the presence of dystonic features alter DBS target selection from the conventional ventralis intermedius (Vim) target in ET?



**Video 1. Pre-surgical Evaluation Showed a Postural, Kinetic, and Intention Tremor in Both Hands, Left Greater than Right.** With the hands outstretched there was mild dystonic posturing of the digits.



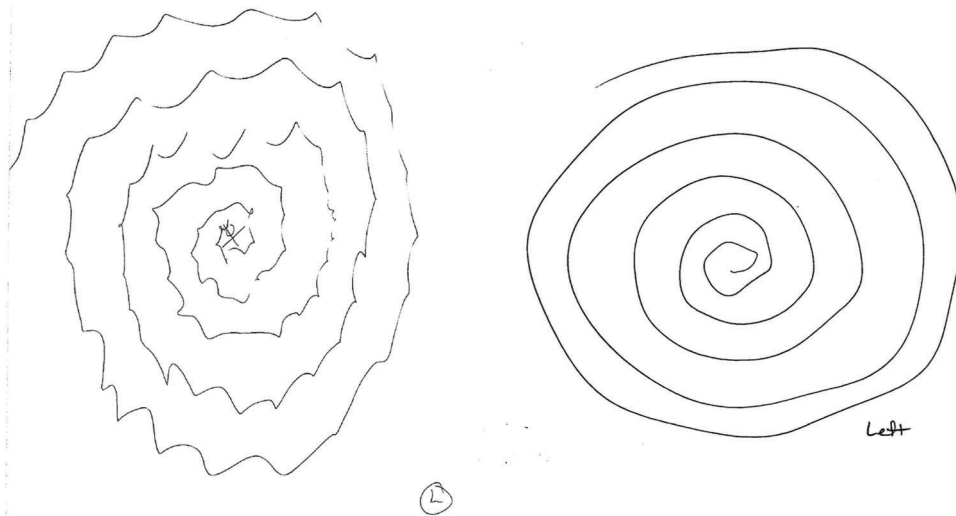
**Video 2. Six-month Post-surgical Evaluation, with Significant Improvement in the Left Hand Tremor and Dystonia.** Right ventralis intermedius targeting coordinates 14 mm lateral and 5.5 mm anterior from the posterior commissure (PC) with the z-axis at the anterior commissure-posterior commissure (ACPC) plane. Programming settings: contacts 9+, 10-, 11+; 3.7 V; 120 us; 180 Hz.

**Clinical solution**

Each member of the Yale DBS interdisciplinary team (comprising a movement disorders neurologist, a functional neurosurgeon, and a neuropsychologist) examined and discussed the patient. A unilateral right Vim target was selected to address the more severe left-hand postural and action tremor, despite the presence of mild dystonic hand posturing. The interdisciplinary team might have selected a different surgical target had the dystonia been more severe or more generalized. The globus pallidus internus (GPi) could be used as a future rescue target if Vim stimulation was unable to provide sufficient benefit to dystonia. Tremor and dystonic posturing in the left arm both improved with unilateral Vim DBS (Video 2, Figure 1). A second rescue DBS lead was not needed.

**Gaps in knowledge**

The first issue raised by this case is the challenge of properly diagnosing tremor syndromes. The overlap between ET and dystonic tremor (DT) has spawned confusion even for experienced movement disorder physicians. Historically, ET has likely been overdiagnosed while dystonia syndromes with prominent tremor may be under-recognized.<sup>1</sup> The Task Force on Tremor for the International Parkinson and Movement Disorder Society created a new consensus statement on the classification of tremors in 2017. The new classification scheme emphasized ET as an *isolated* tremor syndrome of bilateral upper limb action tremor, of at least 3 years’ duration with or without tremor in other locations, and in the absence of other neurological signs (dystonia, ataxia, or parkinsonism).<sup>2</sup> The tremor in ET is also typically characterized as a 4–12 Hz postural-action tremor affecting the limbs in a slightly asymmetric fashion.<sup>3</sup> The head and voice are affected less commonly and usually noticed after limb involvement.<sup>4</sup> However, there was insufficient evidence to support the inclusion of “onset of tremor in the upper limbs” as part of the new diagnostic classification for ET. The case presented satisfies much



**Figure 1. Spiral Drawing.** Left hand spiral drawing pre (left) and post (right) ventralis intermedius deep brain stimulation surgery.

of these criteria, and a prolonged history of progressive tremor with a family history of ET would favor an underlying diagnosis of ET. The presence of a single tremor axis on the patient's spiral drawing may further support an ET diagnosis.<sup>5</sup>

In contrast to ET, the diagnosis of DT rests on the idea that the tremor does not occur in isolation and recognizes that tremor can be a basic element of a dystonic contraction. The tremor of DT is most commonly an action tremor that affects the head, upper limbs, and voice, and is commonly induced by specific postures and actions or in a task-specific form. A geste antagoniste (sensory input) or alternatively a posture (null point) that reduces or eliminates the tremor is characteristic of DT and can help distinguish it from ET.<sup>6</sup>

When the features of ET and DT overlap, diagnostic uncertainty may exist. There is no consensus on what additional signs (e.g., impaired tandem gait, dystonic posturing, mild cognitive impairment) are acceptable within the definition of ET. "ET plus" is the new diagnostic criteria proposed to classify a tremor with the characteristics of ET in the presence of additional mild examination findings of uncertain significance. This entity has been further distinguished from "tremor associated with dystonia," in which tremor is present in a body part separate from the region with dystonia.<sup>2</sup> These distinctions between tremor syndromes are reliant on a clinician's subjective assessment of the significance of a patient's non-tremor-related examination features. There is also no consensus on the severity of additional signs necessary to classify a patient with DT rather than ET plus. Although the dystonic features in this case were very mild, a similar case with more prominent dystonia might be classified as DT rather than "ET plus." The classification is highly dependent on the interpretation of the clinician. Some clinicians may even label this phenotype as a mixed tremor syndrome. The lack of diagnostic consensus and the variability of diagnostic schema in the literature contribute to a second clinical dilemma: What evidence is available to guide the choice of DBS target selection when treating tremor with associated dystonic features?

The DBS target of choice for medically refractory postural-action tremor has traditionally been the Vim. There is robust evidence for its effectiveness in treating ET and postural-action tremor in general.<sup>7,8</sup> Stimulation of the thalamic ventralis oralis anterior and posterior (Voa/Vop), as a pallidal receiving area, has also been utilized in the treatment of postural-action tremors alone or as a rescue lead for refractory tremor.<sup>9</sup> There is equally convincing evidence supporting GPi stimulation for the treatment of dystonia.<sup>10,11</sup> Even the subthalamic nucleus (STN) has been occasionally reported as a possible target for the treatment of dystonia.<sup>12</sup> However, available evidence regarding DBS treatment for DT specifically has been limited to smaller retrospective reviews which often mix patients with variable forms of dystonia and tremor. These studies are naturally biased to include patients with more severe dystonia than our current case; however, they offer some of the only available insight into the variable effects of DBS target selection on the dystonic features associated with tremor (Table 1).

Studies of tremor patients treated with Vim or GPi DBS may offer the broadest available evidence to guide target selection in cases with both tremor and dystonia. Vercueil et al.<sup>13</sup> examined one of the largest series of patients with tremor (n = 19) in the setting of both primary and secondary dystonia. Twelve patients treated with Vim stimulation had no improvement in dystonia, and three of these patients underwent subsequent GPi DBS to address residual dystonia. However, six out of nine patients identified as having a "DT phenotype" achieved tremor suppression with Vim DBS (whether alone or in conjunction with GPi DBS).<sup>13</sup> Hedera et al.<sup>14</sup> reported a similar variable benefit for tremor and dystonia, which appeared to be highly dependent on target selection. These authors examined 10 patients with DT. Subjects with Vim DBS achieved the greatest tremor control (average improvement of the Washington Heights–Inwood Genetic Study of Essential Tremor Scale score was 84.7%). GPi DBS resulted in less improvement in the average tremor score (39.8%). GPi stimulation was, however, effective in treating severe dystonia, and subjects with Vim DBS required additional medical treatment for residual dystonic symptoms.<sup>14</sup> Morishita et al.<sup>15</sup> analyzed three cases of DT and found similar results. Of particular note was a case of bilateral GPi DBS that resulted in improvement in dystonic gait but persistent head and upper extremity tremor. This case required subsequent bilateral Vim DBS therapy, with improvement in the Fahn–Tolosa–Marin Tremor Rating Scale (FTM-TRS) from 40 to 22.<sup>15</sup> Vim and GPi DBS were effective in improving tremor and dystonia when both were utilized in combination in this single patient. Neither target alone was sufficient to control both sets of symptoms.

Although these case series collectively suggest a variable effectiveness for dystonia and tremor targets, there are isolated reports of adequate improvement in both symptoms via stimulation of a single target. Ramirez et al.<sup>16</sup> analyzed GPi DBS outcomes in two patients with focal limb DT in the absence of generalized dystonia. Treatment with GPi DBS led to an 82% and 79% improvement of the FTM-TRS in each case. In both cases, focal DT was significantly improved with GPi DBS and did not require additional thalamic stimulation to address the tremor.<sup>16</sup>

Evidence for the singular effectiveness of targets other than Vim or GPi has been more limited. Chou et al.<sup>17</sup> reported a case of a 52-year-old female with cervical dystonia and subsequent head and arm tremor treated with STN DBS. The patient's course suggested the modern classification of "tremor associated with dystonia." Bilateral STN DBS led to an improvement in her Toronto Western Spasmodic Torticollis Rating Scale from 14 to 3, with "full suppression" of her head and hand tremors.<sup>17</sup> While additional case reports of STN improvement in DT have been lacking, the posterior subthalamic area (PSA) may also be a reasonable target for DT. The PSA comprises the caudal zona incerta (cZi), including the pallidothalamic white matter and prelemniscal radiation. Stimulation in this region has been reported to be effective in reducing several tremor syndromes across multiple etiologies.<sup>18</sup> With regards to DT specifically, a few case reports have shown significant improvement in both tremor and dystonia from cZi

**Table 1. Summary of Studies Commenting Specifically on Tremor Improvement in Dystonia Treated with Deep Brain Stimulation**

Study	N	Diagnosis	DBS Target	Outcome
Kitagawa et al. <sup>19</sup>	1	ET/DT	cZi	“Remarkably reduced” tremor and also “reduced” dystonia
Vercueil et al. <sup>13</sup>	19	Primary and secondary limb tremor and dystonia	9 Vim 3 Vim and GPi 7 GPi	“Satisfactory” outcome (global functional score of 2 or 3) in Vim leads 6/12 (50%) GPi leads 7/10 (70%)
Chou et al. <sup>17</sup>	1	Segmental dystonia and ET	STN	TWSTRS OFF/ON stimulation (14/3) with “full tremor suppression”
Plaha et al. <sup>20</sup>	1	DT	cZi	65% improvement in BFMDRS and 70.5% in FTM-TRS
Blomstedt et al. <sup>21</sup>	2	DT	PSA	Patient 1 TRS subscores: Pre-surgical 9 Post-surgical OFF-stim 3 Post-surgical ON-stim 0 with “no dystonic posturing” Patient 2 TRS subscores: Pre-surgical 20 Post-surgical OFF-stim 0 (IPG subsequently removed)
Morishita et al. <sup>15</sup>	3	1. Generalized dystonia with head and hand tremor (prior GPi DBS) 2. Postural and intention hand tremor with dystonic posture 3. Cervical dystonia with head tremor and bilateral hand tremor	Vim	1. TRS OFF-stim 40, ON-stim 22 2. TRS OFF-stim 43, ON-stim 21 3. TRS OFF stim 24, ON-stim 17
Hedera et al. <sup>14</sup>	10	6 generalized dystonia 3 hemi-dystonia 1 segmental dystonia	3 Unilateral Vim 1 Bilateral Vim 4 Bilateral GPi 2 Bilateral GPi and unilateral Vim	Vim DBS – 84.7% improvement in WHIGET, no change in BFMDRS GPi DBS – 39.8% improvement in WHIGET, 63.5% improvement in BFMDRS
Ramirez et al. <sup>16</sup>	2	DT	Unilateral GPi Bilateral GPi	82% improvement in post-surgical FTM-TRS 79% improvement in FTM-TRS

Abbreviations: BFMDRS, Burke–Fahn–Marsden Dystonia Rating Scale; cZi, Caudal Zona Incerta; DT, Dystonic Tremor; ET, Essential Tremor; FTM-TRS, Fahn–Tolosa–Marin Tremor Rating Scale; GPi, Globus Pallidus Internus; IPG, Implanted Pulse Generator; PSA, Posterior Subthalamic Area; STN, Subthalamic Nucleus; TWSTRS, Toronto Western Spasmodic Torticollis Scale; Vim, Thalamic Ventralis Intermedius; WHIGET, Washington Heights–Inwood Genetic Study of Essential Tremor.

stimulation.<sup>19–21</sup> The varied surgical approaches and assessment techniques in these cases complicate interpretation of the results, making definitive conclusions regarding PSA targeting for DT difficult. Ultimately, the promise of a single target to reliably improve both tremor and dystonia in an individual case remains unclear and may be unrealistic, given the differences in phenomenology and pathogenesis in these varied case reports.

In conclusion, there are likely multiple DBS targets that may be effective in improving DT. The current limited evidence suggests that Vim DBS is likely the most effective target for reducing tremor, while GPi DBS is more likely to improve dystonia. However, isolated cases reports suggest this may not be an absolute rule. The severity of the relative components of tremor and dystonia and their contributions to patient disability should contribute to expert target selection. However,

when these components impact disability equally, the optimal target(s) remains debatable. Adherence to a more standardized tremor diagnostic classification may or may not help in target selection. Much of the cited literature relies on clinometric scales of tremor or dystonia as their primary measure, without detailed description of the tremor phenotype. As new diagnostic criteria are implemented, new scales must be adopted to reflect the areas in which tremor and dystonia overlap so that objective measures of DBS response can be tracked. The use of advanced DBS technology (e.g., directional current steering, closed loop systems) and surgical techniques (e.g., fiber-based targeting) may aid in identifying optimal targets and programming strategies for tremor phenotypes that do not rely on subjective criteria.

### Expert commentary

This case highlights the limited information available to guide the clinician in the choice of DBS target(s) for individual patients with ET and dystonic features regardless of the tremor classification system. ET can be observed either in isolation or can be associated with other neurologic symptoms such as dystonia (“ET plus”). The distinction between “ET plus” and DT relies on the evaluation of the examiner and thus is subjective. The FDA-approved DBS target for ET is the Vim and for dystonia it is usually the GPi. This current paper summarizes the available literature investigating the use of different DBS targets for management of both “ET plus” and DT. The classification of tremors into ET, “ET plus,” and DT has been a recent development in the field and has not yet been widely embraced (2017). Additionally, any best target conclusions based on the published literature should be interpreted cautiously. Vim, GPi, STN, and cZi have all been utilized as targets for tremor with associated features of dystonia and all have had varying degrees of success. Additionally, there is an unpublished experience in Voa/Vop thalamus. In our experience, Vim has been the initial target of choice when the tremor is postural-action and the tremor is the disabling feature of the presentation. In the current case, the dystonic features were mild and the choice for Vim over GPi was clear. Since there are so few “ET plus” and dystonia tremor cases implanted per year (even in expert centers) it will be important for groups to aggressively publish the results of cases and case series, preferably using the newly developed and standardized classification into ET, “ET plus,” and DT.

### Author statement

Writing – A.P., W.D., M.O.; Conceptualization: A.P.; Expert Commentary: W.D. and M.O.

### References

1. Lalli S, Albanese A. The diagnostic challenge of primary dystonia: evidence from misdiagnosis. *Mov Disord* 2010;25:1619–1626. doi: 10.1002/mds.23137
2. Kailash BP, Bain P, Bajaj N, Elble RJ, Hallett M, Louis ED, et al. and the Tremor Task Force of the International Parkinson and Movement Disorder

Society. Consensus Statement on the Classification of Tremors, from the Task Force on Tremor of the International Parkinson and Movement Disorder Society. *Mov Disord* 2018;33:75–87. doi: 10.1002/mds.27121

3. Elble RJ. What is essential tremor? *Curr Neurol Neurosci Rep* 2013;13:353. doi: 10.1007/s11910-013-0353-4
4. Louis ED, Ford B, Frucht S. Factors associated with increased risk of head tremor in essential tremor: a community-based study in northern Manhattan. *Mov Disord* 2003;18:432–436. doi: 10.1002/mds.10395
5. Michalec M, Hernandez N, Clark LN, Louis ED. The spiral axis as a clinical tool to distinguish essential tremor from dystonia cases. *Parkinsonism Relat Disord* 2014;20:541–544. doi: 10.1016/j.parkreldis.2014.01.021
6. Defazio G, Conte A, Gigante AF, Fabbrini G, Berardelli A. Is tremor in dystonia a phenotypic feature of dystonia? *Neurology* 2015;84:1053–1059. doi: 10.1212/WNL.0000000000001341
7. Schuurman PR, Bosch DA, Bossuyt PMM, Bonsel GJ, van Someren EJW, de Bie RMA, et al. A comparison of continuous thalamic stimulation and thalamotomy for suppression of severe tremor. *N Engl J Med* 2000;342:461–468. doi: 10.1056/NEJM200002173420703
8. Zhang K, Bhatia S, Oh MY, Cohen D, Angle C, Whiting D. Long-term results of thalamic deep brain stimulation for essential tremor. *J Neurosurg* 2010;112. doi: 10.3171/2009.10.JNS09371
9. Oliveria SF, Rodriguez RL, Bowers D, Kantor D, Hilliard JD, Monari EH, et al. Safety and efficacy of dual-lead thalamic deep brain stimulation for patients with treatment-refractory multiple sclerosis tremor: a single-centre, randomised, single-blind, pilot trial. *Lancet Neurol* 2017;16:691–700. doi: 10.1016/S1474-4422(17)30166-7
10. Vidailhet M, Vercueil L, Houeto JL, Krystkowiak P, Lagrange C, Yelnik J, et al. Bilateral, pallidal, deep-brain stimulation in primary generalised dystonia: a prospective 3 year follow-up study. *Lancet Neurol* 2007;6:223–229. doi: 10.1016/S1474-4422(07)70035-2
11. Kiss ZH, Doig-Beyaert K, Eliasziw M, Tsui J, Haffenden A, Suchowersky O, et al. The Canadian multicenter study of deep brain stimulation for cervical dystonia. *Brain* 2007;130:2879–2886. doi: 10.1093/brain/awm229
12. Kleiner-Fisman G, Liang GS, Moberg PJ, Ruocco AC, Hurtig HI, Baltuch GH, et al. Subthalamic nucleus deep brain stimulation for severe idiopathic dystonia: impact on severity, neuropsychological status, and quality of life. *J Neurosurg* 2007;107:29–36. doi: 10.3171/JNS-07/07/0029
13. Vercueil L, Pollak P, Fraix V, Caputo E, Moro E, Benazzouz A. Deep brain stimulation in the treatment of severe dystonia. *J Neurol* 2001;248:695–700. doi: 10.1007/s004150170116
14. Hedera P, Phibbs FT, Dolhun R, Charles PD, Konrad PE, Neimat JS. Surgical targets for dystonic tremor: considerations between the globus pallidus and ventral intermediate thalamic nucleus. *Parkinsonism Relat Disord* 2013;19:684–686. doi: 10.1016/j.parkreldis.2013.03.010
15. Morishita T, Foote KD, Haq IU, Zeilman P, Jacobson CE, Okun MS. Should we consider Vim thalamic deep brain stimulation for select cases of severe refractory dystonic tremor? *Stereotact Funct Neurosurg* 2010;88:98–104. doi: 10.1159/000289354
16. Ramirez-Zamora A, Kaszuba B, Gee L, Prusik J, Molho E, Willock M. Clinical outcome and intraoperative neurophysiology for focal limb dystonic

tremor without generalized dystonia treated with deep brain stimulation. *Clin Neurol Neurosurg* 2016;150:169–176. doi: 10.1016/j.clineuro.2016.06.006

17. Chou KL, Hurtig HI, Jaggi JL, Baltuch GH. Bilateral subthalamic nucleus deep brain stimulation in a patient with cervical dystonia and essential tremor. *Mov Disord* 2000;20:377–380. doi: 10.1002/mds.20341

18. Carrillo-Ruiz JD, Velasco F, Jimenez F, Castro G, Velasco AL, Hernandez JA. Bilateral electrical stimulation of prelemniscal radiations in the treatment of advanced Parkinson's disease. *Neurosurgery* 2008;62:347–359. doi: 10.1227/01.neu.0000316001.03765.e8

19. Kitagawa M, Murata J, Kikuchi S, Sawamura Y, Saito H, Sasaki H, et al. Deep brain stimulation of subthalamic area for severe proximal tremor. *Neurology* 2000;55:114–116. doi: 10.1212/WNL.55.1.114

20. Plaha P, Khan S, Gill SS. Bilateral stimulation of the caudal zona incerta nucleus for tremor control. *J Neurol Neurosurg Psychiatry* 2008;79:504–513. doi: 10.1136/jnnp.2006.112334

21. Blomstedt P, Fytagoridis A, Tisch S. Deep brain stimulation of the posterior subthalamic area in the treatment of tremor. *Acta Neurochir* 2009;151:31. doi: 10.1007/s00701-008-0163-7