

Treatment and Outcomes of Carcinoma of the External and Middle Ear: The Validity of En Bloc Resection for Advanced Tumor

Takuma MATOBA,^{1,2} Nobuhiro HANAI,² Hidenori SUZUKI,² Daisuke NISHIKAWA,² Eiji TACHIBANA,³ Takeshi OKADA,⁴ Shingo MURAKAMI,¹ and Yasuhisa HASEGAWA²

¹Department of Otorhinolaryngology and Head and Neck Surgery, Nagoya City University Hospital, Nagoya, Aichi, Japan;

²Department of Head and Neck Surgery, Aichi Cancer Center Hospital, Nagoya, Aichi, Japan;

³Department of Neurosurgery, Toyota Kousei Hospital, Toyota, Aichi, Japan;

⁴Department of Neurosurgery, Kainan Hospital, Yatomi, Aichi, Japan

Abstract

Carcinoma of the external and middle ear is a very rare disease. Despite the various treatment modalities available, its prognosis is still poor. We aimed to analyze the treatment modalities, outcomes, and validity of surgical approaches, especially in advanced tumors in the ear. Twenty-five patients with carcinoma of the external and middle ear were retrospectively analyzed. The modified Pittsburgh staging system was used for staging of the patients. Overall and disease-free survival was estimated using of Kaplan-Meier method. In our cohort of 25 patients, the majority (76%) had tumor located in external auditory meatus. The most common histologic subtype was squamous cell carcinoma (80%). More than half of patients (56%) had tumor stage IV. In the stage IV group, five patients underwent subtotal temporal bone resection and ipsilateral neck dissection. Seven patients underwent definitive radiotherapy. The remaining two patients underwent palliative chemotherapy. The 2-year overall and disease-free survival for patients with tumor stage IV was 67.7% and 57.8%, respectively. In patients with tumor stage IV, the 2-year overall survival for patients who underwent surgery was 80.0% versus 53.6% for those who underwent radiotherapy ($P = 0.16$). The 2-year disease-free survival for patients who underwent surgery was 80.0% versus 28.6% for those who underwent radiotherapy ($P = 0.15$). In the present study, the outcome of patients who received surgical treatment tended to be better than that of patients who received radiation therapy. Our results suggest that en bloc resection could be the first choice even in the advanced disease stage.

Key words: carcinoma, external and middle ear, en bloc resection, advanced stage

Introduction

Carcinoma of the temporal bone is extremely rare.^{1–3} The frequency of occurrence is only 1–6 cases per 1 million people yearly,^{1–3} and carcinoma of the external and middle ear is much rarer.^{1–3} Squamous cell carcinoma (SCC) is the most ordinary histology, although other types of histopathology have been reported, e.g. adenocarcinoma, adenoid cystic carcinoma, basal cell carcinoma, melanoma, and various types of sarcoma.³ Because of the rarity

of carcinoma of the external and middle ear, the literature on these tumor is limited.^{2,3} Decision-making about the treatment of carcinoma of the external and middle ear should be made taking into account their various clinical behavior and clinical courses.³ Furthermore, subtotal temporal resection can cause severe complications, such as deafness and abolition of the equilibrium function. Due to the difficulty of surgical procedures, radiotherapy is often performed as an alternative therapy for surgery.

In order to plan treatment of this rare tumor, a reliable staging system is very important. The Pittsburgh staging system has been the most widely used staging tool since 1990, and the most recent version of this system⁴ proposed from a surgical perspective has been proven to be trusted and

Received June 10, 2017; Accepted September 7, 2017

Copyright© 2018 by The Japan Neurosurgical Society
This work is licensed under a Creative Commons Attribution-NonCommercial-NoDerivatives International License.

reproducible. On the basis of this staging system, we retrospectively reviewed a series of 25 patients with carcinoma of the external and middle ear at a single institution and compared the outcomes of various treatment modalities.

Materials and Methods

A patient database at Aichi Cancer Center Hospital was used to identify patients who were treated for carcinoma of the external and middle ear between January 1999 and December 2014. A total of 25 patients were extracted, we reviewed their present symptoms, histopathology of the tumor, tumor stages (based on the Pittsburgh staging system), treatment modality, and clinical outcomes. We evaluated and staged all tumors according to the description of clinical findings, image findings, surgical records, and pathological examination results using the latest version (2000) of the Pittsburgh staging system.⁴⁾

All surgical procedures were en bloc resection, and no piecemeal removal was performed. The principles of skull base surgery were applied to the procedure when we performed subtotal temporal bone resection.^{5,6)} We performed subtotal temporal bone resection in the patients with T4 or aggressive T3 tumors (e.g. tumor invasion near the cochlea, petrous apex, or carotid canal) that could be removed en bloc and were without distant metastasis. We assessed the presence of distant metastasis by systemic enhanced computed tomography (CT) and positron emission tomography (PET), except for in the two patients who first visited in 1999 when PET was not common at that time. These two patients received systemic enhanced CT to assess the presence of distant metastasis. For lymph node metastasis in the neck, patients without invasion to the carotid artery were indicated for surgery, even if the nodal status was in the advanced stage. The contraindications of surgery for primary tumor were wide involvement of the dura mater or temporal lobe (cranial limit), invasion into the posterior fossa, and wide invasion into the sigmoid sinus (posterior limit). In patients with invasion into the sigmoid sinus, we evaluated the operability by angiography. We planned partial resection of the sigmoid sinus if we considered en bloc resection to be possible. We did not set an anterior limit, instead performing combined resection of the temporomandibular joint or total parotidectomy, if necessary. We also avoided subtotal temporal bone resection in patients with severe comorbidities.

We drew survival curves of the overall and disease-free survival using Kaplan-Meier method, and used log-rank test to assess the significance of

differences in the survival curves. To analyze the association between the parameters and survival, we used Pearson's chi-square test. If any parameters were fewer than 10, we used Fisher's exact test. We defined the overall survival as the time from the date of first visit associated with the disease until the last confirmation date or the date of death. We defined the disease-free survival as the time from the beginning of the treatment for the tumor until the first recurrence or the date of death. We used the JMP software program, version 8.0.2 (SAS Institute, Inc., Cary, NC, USA), to perform all statistical analyses. *P* values of < 0.05 were considered to indicate statistical significance.

Results

In our cohort of 25 patients, 15 (60%) were men, and 10 (40%) were women. The mean patient age was 66.6 years (range: 39–92 years). The distribution of location was auricle in 3 patients (12%), external auditory meatus in 19 patients (76%), and middle ear in 3 patients (12%). SCC was seen in 20 patients (80%), adenoid cystic carcinoma (ACC) in 2 patients (8%), and adenocarcinoma, basal cell carcinoma, and spindle cell carcinoma in 1 patient each (4%), respectively. The number of patients with tumor stage I was 6 (24%), stage II was 3 (12%), stage III was 2 (8%), and stage IV was 14 (56%). Twenty-one patients (84%) had a treatment-naive tumor, and 4 (16%) had a recurrent tumor (Table 1). The most common presenting symptoms were otorrhea and otalgia (Table 2).

In the stage I to III groups, all patients underwent surgery. Five patients underwent lateral temporal bone

Table 1 Patient characteristics

Age (years)	39–92 (mean 66.6)	
Gender	<i>Male</i>	15
	<i>Female</i>	10
Tumor location	<i>Auricle</i>	3
	<i>External auditory meatus</i>	19
	<i>Middle ear</i>	3
Histologic subtype	<i>SCC</i>	20
	<i>ACC</i>	2
	<i>Others</i>	3
Stage	<i>I</i>	6
	<i>II</i>	3
	<i>III</i>	2
	<i>IV</i>	14

ACC: adenoid cystic carcinoma, SCC: squamous cell carcinoma, Others: adenocarcinoma, basal cell carcinoma, and spindle cell carcinoma.

resection, and 6 patients underwent local resection. In the stage IV group, 5 patients (36%) underwent surgery—all subtotal temporal bone resection and ipsilateral neck dissection. Neck dissection was performed with curative intent in 4 patients, and elective neck dissection was performed in 1 patient. The excised ends were negative in all patients who underwent surgery. One of the patients who had stage IV disease and received surgery underwent postoperative radiotherapy. The dose of postoperative radiotherapy was 50 Gy. Seven patients (50%) underwent definitive radiotherapy, including carbon ion radiotherapy in 2 patients. Carbon ion radiotherapy was performed at an institution with ion beam equipment (Hyogo Ion Beam Medical Center). The median dose of definitive radiotherapy was 70.0 Gy (range: 35.0–70.4 Gy). The remaining 2 patients (14%) underwent palliative chemotherapy. Both patients had recurrent tumor after local resection and postoperative radiotherapy at the previous institute. One had multiple lung metastases and underwent 2 cycles of docetaxel 60 mg/m² intravenously every 3 weeks. Another patient had local recurrence involving the internal carotid artery and underwent 8 cycles of paclitaxel 100 mg/m² intravenously every week. The initial treatments performed at our institute are summarized in Table 3.

Seven patients experienced tumor recurrence after completion of primary treatment. Two patients had local recurrences, three had isolated regional recurrences, one had simultaneous local and regional

recurrences, and one had simultaneous local recurrence and lung metastasis. The salvage treatments performed are summarized in Table 4.

The 2-year overall survival for all patients and patients with tumor stage IV was 75.8% and 67.7%, respectively (Fig. 1). In patients with tumor stage IV, the 2-year overall survival for patients who underwent surgery was 80.0% versus 53.6% for those who underwent radiotherapy ($P = 0.16$; Fig. 2). The 2-year disease-free survival for all patients and patients with tumor stage IV was 57.8% and 42.9%, respectively (Fig. 3). In patients with tumor stage IV, the 2-year disease-free survival for patients who underwent surgery was 80.0% versus 28.6% for those who underwent radiotherapy ($P = 0.15$; Fig. 4).

The 2-year overall and disease-free survival for patients with SCC stage IV was 69.3% and 45.5%, respectively. In patients with SCC stage IV, the 2-year

Table 2 Presenting symptoms

Symptom	Number
Otorrhea	11
Bloody otorrhea	3
Otalgia	6
Feeling of fullness in the ear	3
Tumor of auricle	3
Itching	1
Ear canal mass	1
Facial nerve palsy	1

Table 3 Initial treatments at our institute

Stage	Number	Initial treatment				
		Local resection	LTBR	STBR+ND	RT	Palliative chemotherapy
I	6	5	1			
II	3	1	2			
III	2		2			
IV	14			5	7	2

LTBR: lateral temporal bone resection, ND: neck dissection, RT: radiation therapy, STBR: subtotal temporal bone resection.

Table 4 Salvage treatments for recurrences

Local	Regional	Distant	Salvage treatment	Outcome
○			STBR, ND, and PORT (60 Gy)	NED
○			Local resection and proton beam radiotherapy (70.2 GyE)	NED
	○		ND and adjuvant chemotherapy	DOD
	○		ND and PORT (60 Gy)	DOD
	○		ND and PORT (60 Gy)	DOD
○	○		Total parotidectomy, ND, and PORT (60 Gy)	NED
○		○	Total parotidectomy, and adjuvant chemotherapy	AWD

AWD: alive with disease, DOD: dead of disease, ND: neck dissection, NED: no evidence of disease, PORT: postoperative radiotherapy, STBR: subtotal temporal bone resection.

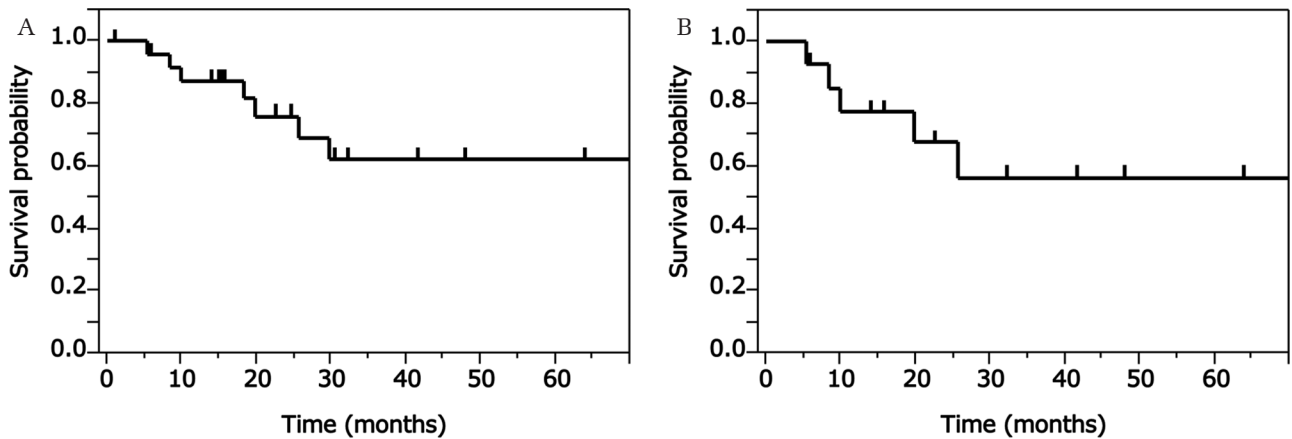


Fig. 1 (A) The overall survival for all patients. (B) The overall survival for patients with tumor stage IV.

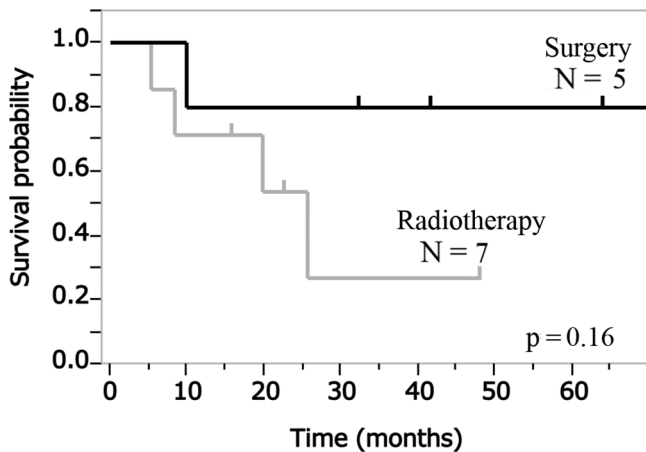


Fig. 2 The overall survival for patients with tumor stage IV by definitive treatment (surgery versus radiotherapy).

overall survival for patients who underwent surgery was 75.0% versus 62.5% for those who underwent radiotherapy ($P = 0.38$; Fig. 5A). In patients with SCC stage IV, the 2-year disease-free survival for patients who underwent surgery was 75.0% versus 33.3% for those who underwent radiotherapy ($P = 0.22$; Fig. 5B).

To assess the burden of surgery, we also examined the operation time and blood loss in six patients who underwent subtotal temporal bone resection. The mean operation time was 12.1 h, and the mean blood loss was 2070 mL (Table 5).

Discussion

We evaluated the overall and disease-free survival of patients with carcinoma of the external and middle ear and found that patients treated by radiotherapy tended to have worse overall and disease-free survival than those who underwent surgery.

In particular, in the present study, the patients with stage IV tumors who underwent surgical treatment tended to have a better prognosis than those who were treated with radiation therapy. The tendency for patients treated by radiotherapy to have a worse survival than those who underwent surgery was also observed in patients with SCC. However, the number of patients was relatively small in the present study. Further investigations in larger populations are thus expected to produce results showing significant differences.

We also examined the operation time and blood loss in six patients who underwent subtotal temporal bone resection. No previous study has reported the operation time and blood loss in subtotal temporal bone resection. Therefore, conclusively stating that our treatment choice and results are appropriate for the cases that underwent subtotal temporal bone resection is difficult. However, regarding oncological outcomes, it might be acceptable to perform subtotal temporal bone resection in patients with advanced tumors.

In a previous study, the 5-year overall and disease-free survival rates ranged from 37% to 68% and 45%–54%, respectively.^{1,3,7–13} Yin et al.⁷ analyzed a relatively large population (95 cases of SCC of the external and middle ear), and the 5-year overall survival rate in patients with tumor stage IV was 29.5%. Moody et al.⁴ analyzed 32 patients with primary SCC of the external auditory canal, and the 2-year overall survival rates were as follows: T1 lesions 100%, T2 80%, T3 50%, and T4 7%. Gandhi et al.² also described 2-year survival and 2-year progression-free survival rates of 50.7% and 30.4%, respectively. In our study in patients with tumor stage IV, the 2-year overall and 2-year disease-free survival rates were 67.7% and 42.9%, respectively. Compared to the findings from previous studies, our treatment policy appears feasible.

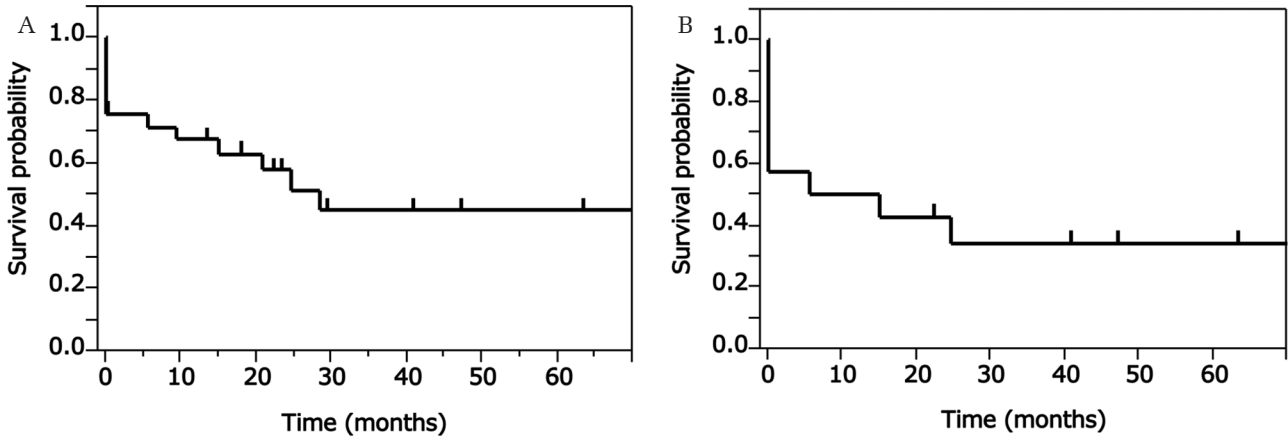


Fig. 3 (A) The disease-free survival for all patients. (B) The disease-free survival for patients with tumor stage IV.

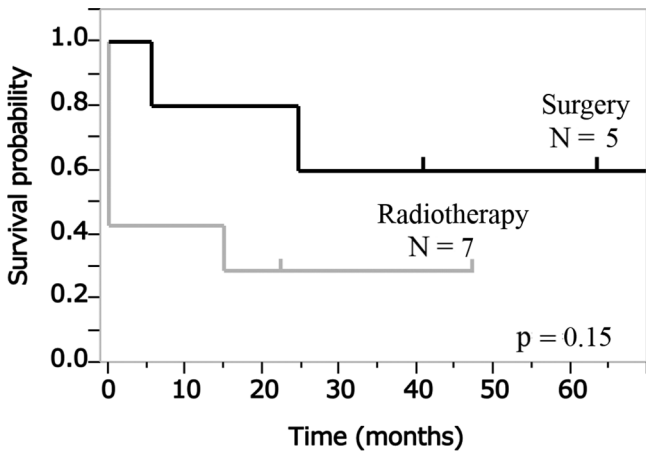


Fig. 4 The disease-free survival for patients with tumor stage IV by definitive treatment (surgery versus radiotherapy).

Table 5 Operation time and blood loss in patients who underwent subtotal temporal bone resection

T	N	M	Operation time (hours)	Blood loss (ml)
4	2b	0	12.6	680
4	0	0	11.5	1920
4	2b	0	9.8	850
3	2b	0	12.7	2770
4	0	0	13.0	2950
3	2b	0	12.8	3250
mean			12.1	2070

Five patients received subtotal temporal bone resection as the initial treatment at our institute, and the other patient received subtotal temporal bone resection for recurrence after partial resection.

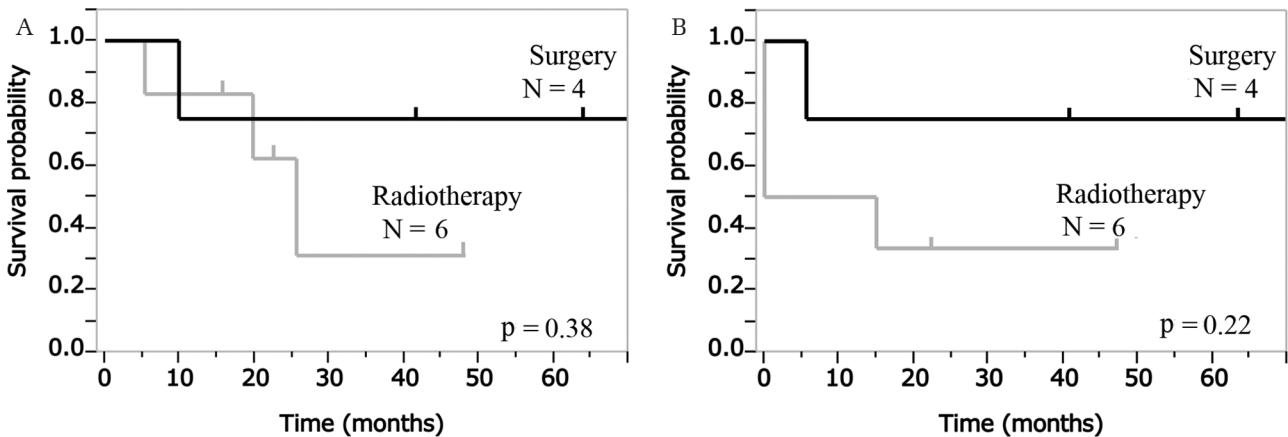


Fig. 5 (A) The overall and (B) disease-free survival for patients with SCC stage IV by definitive treatment (surgery versus radiotherapy).

In the present study, the surgical margins were all negative, which is an important factor for improving the prognosis.^{1,7)} Ogawa et al.¹⁾ indicated that the 5-year disease-free survival rate in patients with negative surgical margins was 83%, which was significantly higher than in those with positive margins (55%) or macroscopic residual disease (38%). Yin et al.⁷⁾ indicated that negative surgical margins yielded a 5-year survival rate of 76.5%, which was significantly higher than the 5-year survival rate of 20.8% for patients with positive margins. In these previous studies, the rate of negative margin for advanced stage tumor seemed to be lower than in the present study, where the rate of negative margins was 100% even in advanced stage cases (stage III; 2/2, stage IV; 5/5). In addition, the rate of tumor stage IV among negative margin cases was 31.3% (5/16). Yin et al.⁷⁾ showed a negative margin rate for tumor stage IV of 50% (10/20), and the rate of tumor stage IV among negative margin cases was 23.3% (10/43). Ogawa et al.¹⁾ did not describe the rate of advanced stage tumor in negative margin cases. However, based on the survival rates (5-year disease-free survival for patients with tumor stage T4: 27%), the rate of advanced stage tumor in negative margin cases does not appear to be very high. Therefore, it was impossible to directly compare the survival rates for negative surgical margins between previous studies and the present study. However, while it was also impossible to directly compare the survival rates for patients with positive and negative surgical margins in the present study, we reconfirmed the advantages of en bloc resection with negative margin based on the findings from previous studies.

While the combination of various treatment modalities helps improve the survival, the long-term survival remains unacceptably low, especially in patients with advanced tumor. Recently, carbon ion radiotherapy and arterial chemoradiotherapy have been reported to be effective and safe for locally advanced SCC of the external and middle ear.^{14,15)} However, those modalities may be insufficient if used alone; for example, the 3-year overall survival in patients who received carbon ion radiotherapy was 41.6%,¹⁴⁾ and the 2-year overall survival in patients who received arterial chemoradiotherapy was 58.7%.⁴⁾ Given the present and previous findings, we recommend that surgery-based combination therapy be conducted.

One limitation of this study is its retrospective nature, so there may be some bias in the treatment choice. The treatment modalities were decided according to not only the clinical stages but also comorbidities, the patient's wishes and doctor's

discretions. Therefore, in a few cases, surgical treatment might have been avoided when patients had severe comorbidities or extremely advanced tumors. However, in contrast, the patients who had shown a good response to induction chemotherapy were also included in the radiation therapy group. While there might be some selection bias, a portion of the patients did receive some benefit from the surgical treatment. We believe the results of this study are meaningful, as few studies have reported the efficacy of surgical treatment for carcinoma of the external and middle ear, especially in advanced tumor stages.

Conclusion

Our results suggest that en bloc resection may be suitable as the first choice for treatment in patients with carcinoma of the external or middle ear when they have no severe comorbidities, even in the advanced disease stage. However, this was a retrospective study comprising a relatively small number of patients, so further studies with a larger number of patients and longer follow-up are required to confirm that our treatment policy is appropriate. Furthermore, the treatment outcomes of patients with unresectable tumor are still quite poor and should be improved in future studies.

Conflicts of Interest Disclosure

The authors declare no conflicts of interest in association with this study.

References

- 1) Ogawa K, Nakamura K, Hatano K, et al.: Treatment and prognosis of squamous cell carcinoma of the external auditory canal and middle ear: a multi-institutional retrospective review of 87 patients. *Int J Radiat Oncol Biol Phys* 68: 1326–1334, 2007
- 2) Gandhi AK, Roy S, Biswas A, et al.: Treatment of squamous cell carcinoma of external auditory canal: a tertiary cancer centre experience. *Auris Nasus Larynx* 43: 45–49, 2016
- 3) Gidley PW, Roberts DB, Sturgis EM: Squamous cell carcinoma of the temporal bone. *Laryngoscope* 120: 1144–1151, 2010
- 4) Moody SA, Hirsch BE, Myers EN: Squamous cell carcinoma of the external auditory canal: an evaluation of a staging system. *Am J Otol* 21: 582–588, 2000
- 5) Mazzoni A, Danesi G, Zanoletti E: Primary squamous cell carcinoma of the external auditory canal: surgical treatment and long-term outcomes. *Acta Otorhinolaryngol Ital* 34: 129–137, 2014
- 6) Okada T, Saito K, Takahashi M, et al.: En bloc petrosectomy for malignant tumors involving the external

- auditory canal and middle ear: surgical methods and long-term outcome. *J Neurosurg* 108: 97–104, 2008
- 7) Yin M, Ishikawa K, Honda K, et al.: Analysis of 95 cases of squamous cell carcinoma of the external and middle ear. *Auris Nasus Larynx* 33: 251–257, 2006
 - 8) Ihler F, Koopmann M, Weiss BG, et al.: Surgical margins and oncologic results after carcinoma of the external auditory canal. *Laryngoscope* 125: 2107–2112, 2015
 - 9) Takenaka Y, Cho H, Nakahara S, Yamamoto Y, Yasui T, Inohara H: Chemoradiation therapy for squamous cell carcinoma of the external auditory canal: a meta-analysis. *Head Neck* 37: 1073–1080, 2015
 - 10) Madsen AR, Gundgaard MG, Hoff CM, et al.: Cancer of the external auditory canal and middle ear in Denmark from 1992 to 2001. *Head Neck* 30: 1332–1338, 2008
 - 11) Leong SC, Youssef A, Lesser TH: Squamous cell carcinoma of the temporal bone: outcomes of radical surgery and postoperative radiotherapy. *Laryngoscope* 123: 2442–2448, 2013
 - 12) Pemberton LS, Swindell R, Sykes AJ: Primary radical radiotherapy for squamous cell carcinoma of the middle ear and external auditory cana—an historical series. *Clin Oncol (R Coll Radiol)* 18: 390–394, 2006
 - 13) Bacciu A, Clemente IA, Piccirillo E, Ferrari S, Sanna M: Guidelines for treating temporal bone carcinoma based on long-term outcomes. *Otol Neurotol* 34: 898–907, 2013
 - 14) Koto M, Hasegawa A, Takagi R, et al.; Organizing Committee for the Working Group for Head and Neck Cancer: Carbon ion radiotherapy for locally advanced squamous cell carcinoma of the external auditory canal and middle ear. *Head Neck* 38: 512–516, 2016
 - 15) Fujiwara M, Yamamoto S, Doi H, et al.: Arterial chemoradiotherapy for carcinomas of the external auditory canal and middle ear. *Laryngoscope* 125: 685–689, 2015

Address reprint requests to: Nobuhiro Hanai, MD, PhD, Department of Head and Neck Surgery, Aichi Cancer Center Hospital, Kanokoden 1, Chikusa-ku, Nagoya, Aichi 464-8681, Japan.
e-mail: hanai@aichi-cc.jp