

Acute total hip arthroplasty in acetabular fractures using modern porous metal cup

Rajesh Malhotra and Deepak Gautam 

Abstract

Purpose: The aim of this study was to report the clinical and radiological outcome of using the modern porous metal cup in patients undergoing acute total hip arthroplasty (THA) for selected subset of acetabular fractures.

Patient and methods: Eighteen patients with acetabular fracture underwent acute THA with modern porous metal cup from a single manufacturer. Fifteen males and three females with a mean age of 46.4 years (range 21–57 years) were ambispectively followed up for a minimum period of 48 months. All patients were evaluated clinically with Harris Hip Scores (HHS) and radiographically with serial X-rays. **Results:** No patient was lost to follow-up. The HHS was excellent in nine patients, good in six patients, fair in two patients, and poor in one patient. All the fractures were united and the cups were well integrated. There was no lucent line seen in any acetabular zones on the X-rays. One patient had infection, which resolved with debridement. There was one dislocation following fall, which was reduced by closed means and remained stable. One of the two patients with heterotopic ossification had restricted movement of hip but not restricting the activities of daily living. No failures of acetabular component were seen in the study. **Conclusion:** The current study showed that the modern porous metal cup provides sufficient primary stability and appear suitable for primary THA in acute acetabular fractures at mid-term follow-up: (i) In selected fractures, acute THA can be extended to young adult patients as well. (ii) Modern porous metal cup may provide sufficient stability with or without additional fixation required.

Keywords

acetabular fracture, acetabular reconstruction, acute total hip arthroplasty, modern porous metal cup

Date received: 2 November 2018; Received revised 26 April 2019; accepted: 9 May 2019

Introduction

Open reduction and internal fixation, the mainstay of treatment for displaced acetabular fractures, remains as the treatment of choice.¹ Nevertheless, yet there is a recognized subset of patients, where the fracture is not amenable for fixation and/or unfavorable outcome is anticipated from osteosynthesis including the risk of post-traumatic osteoarthritis in the early follow-up.^{2,3} Acute total hip arthroplasty (THA) may be an appropriate treatment option in these cases,^{4–6} and this has been in practice recently with or without additional plate fixation.^{7–10} Apart from the fracture management, acute THA gives an advantage of early mobilization of the patient, which is the prime objective of any orthopedic technique.

Acute THA though seems straightforward is an extraordinary challenge in case of acetabular fractures because of the difficulty in obtaining acetabular component fixation.⁶ The bone bed may not be adequate enough to amalgamate the contemporary acetabular shell designs. An additional fixation may also be required to provide primary

Department of Orthopedics, All India Institute of Medical Sciences (AIIMS), New Delhi, India

Corresponding author:

Deepak Gautam, Department of Orthopedics, All India Institute of Medical Sciences (AIIMS), New Delhi 110029, India.

Email: cmcdeepak@yahoo.com



Table 1. Indications for acute THA in acetabular fractures.^{2,5,6,7,8}

Severely comminuted fracture
Articular impaction of the medial roof
Extensive abrasion of femoral head
Fracture of the femoral head
Significant destruction of the articular surface
Preexisting hip arthritis
Osteoporosis

THA: total hip arthroplasty.

stability. The newer porous metal cups, an innovation, has unequivocally demonstrated rapid and enhanced biologic fixation of the acetabular cups into the bone.^{2,11}

We hypothesize that the use of modern design porous metal cup provides good stability. Accordingly, the modern porous metal cup, RegenerexTM Ringloc[®] (initially from Biomet Inc. and now with Zimmer-Biomet, Warsaw, Indiana, USA), was used in acute THA in acetabular fractures, the evaluation of which was done based on clinical and radiological examination, and the succinct details are narrated in the following text.

Patient and methods

Particulars of all the patients with acetabular fractures, who underwent THA between 2012 and 2015, were retrieved from the service arthroplasty register of the department. The patients with established post-traumatic arthritis, following conservative or operative method of treatment prior to the surgery, were excluded from the study. Patients fulfilling the inclusion criteria (Table 1) and treated with acute THA were included in the study. The inclusion criteria are based mainly on the X-rays followed by computed tomogram (CT) scans if required. Although, it is our routine service protocol to get CT scans of all the patients with displaced acetabular fracture, exceptions were in those with preexisting hip arthritis and minimal displacement. Only those cases, which are not amenable for osteosynthesis and/or anticipated poor outcome with fixation alone, were considered for acute THA. Acute THA was defined as surgery within 3 weeks of the injury. Patients not completing a minimum of 2 years after surgery were excluded from the study. This yielded 26 patients suitable for the study. The clinical and operative details were obtained from the medical records. All the patients were called up for follow-up in the outpatient department. They were evaluated clinically with Harris Hip Score (HHS) and radiologically with the current and serial X-rays done in the regular follow-ups as per the service protocol. Eight patients who had modern porous acetabular shell designs other than RegenerexTM Ringloc[®] (Biomet, Warsaw, Indiana, USA) were again excluded from the study so as to give uniformity in the study. The remaining 18 patients (15 males and 3 females) were prospectively followed up for a minimum of 2 years so as to give an ambispective follow-up to a minimum of 4




Figure 1. Multi-hole RegenerexTM Ringloc[®] (Biomet, Warsaw, Indiana, USA) acetabular shell (a) inner view and (b) outer view showing the porous coating.

years. Their age group ranged from 21 years to 57 years with a mean age of 46.4 years at the time of surgery.

Operative technique

All patients were operated in lateral position via posterior approach. In six patients, the incision had to be extended proximally to a Kocher Langenbeck approach due to superior migration of the femoral head, resulting from fracture dislocation. These patients also needed additional posterior plate fixation for acetabular reconstruction. The femoral head was dislocated posteriorly, and neck cut made. The femoral broaching was done successively to a press fit size and the last broach left in situ. The anterior capsule, reflected head of rectus femoris and gluteus minimus were completely released in all cases to push the femur anteriorly for better exposure of the acetabulum. The acetabular fracture was first assessed for its requirement of any major reconstruction before acetabular preparation. Posterior plates were used for additional fixation in six cases. The femoral head was used as a graft in eight cases with major acetabular defects due to severe comminution. The acetabulum was then prepared with successive reamers to the minimum possible size fit to hold the acetabular shell. The modern porous coated, multi-hole RegenerexTM Ringloc[®] (Biomet, Warsaw, Indiana, USA; Figure 1) acetabular shell was fixed. All the acetabular shells were fixed with screws. A trial liner and head were inserted and the joint was reduced to check for its stability and soft tissue tension through the full range of movement. Uncemented femoral stems were used in all the cases. Short femoral stems were used in those patients who were physiologically young and active. Once the final head size was decided, the joint was re-dislocated to impact the definitive vitamin E polyethylene liner followed by the head, and the joint was re-reduced.

One patient had undergone simultaneous fixation for ipsilateral distal femur, one patient for ipsilateral tibial shaft, and one patient with polytrauma for contralateral distal femur.

As per our service protocol, low-molecular weight heparin was given to all patients and continued till the patient is mobilized. All the patients were started on

Indomethacin 75 mg daily for prophylaxis against heterotopic ossification (HO). All the patients in our study were made to sit by the bedside on the day after surgery. On the second day of surgery, all the patients were made to walk toe-touch weight-bearing on the operated limb and with the help of the walker except the one who had contralateral distal femur fixation, in whom the mobilization was considerably delayed. Partial weight-bearing as tolerated was allowed by 3 weeks, and full weight-bearing was started at 6 weeks of the surgery. Post-operative complications were recorded. None of the patients had any issue regarding the general condition in the immediate postoperative period. All the patients were advised to follow up regularly as per our protocol at 6 weeks, 3 months, 6 months, 1 year, and then yearly thereafter. They were evaluated both clinically and radiologically in each visit. Clinical evaluation was done using HHS and by assessing the walking ability of the patient.¹² Radiological evaluation was done by assessing the position of the cup, formation of bone on its acetabular bed, and healing of the fractures. The acetabular component was assessed for the presence of any radiolucency and loosening as per the DeLee and Charnley zones.¹³

Results

All the 18 patients were on regular follow-up and were available for detail re-evaluation at the latest follow-up. The average follow-up was 57.6 months (48–70 months).

Clinical evaluation

The mean HHS recorded at the minimum 24 months follow-up was 91 (range 78–97). At the latest follow-up, the mean HHS was 90 (range 80–96). There was no significant change in the HHS at 4 years as compared to that at 2 years ($p > 0.05$). They were walking independently. Sixteen patients were walking without any support while two patients were walking with cane on the opposite side. Two patients, who were diagnosed with trochanteric bursitis at 18 and 24 months follow-up, respectively, after the surgery, were managed with local steroid injection. No pain recurred then after. All except one patient with heterotopic ossification (HO) had pain-free hip movements. He had pain on walking and was walking with a limp. Overall, the score was excellent in nine patients, good in six patients, fair in two patients, and poor in one patient. All except one had satisfactory clinical relief with functional improvement.

Radiological evaluation

At the latest follow-up, all the cups were well integrated. There was no loosening in any cup as evidenced by the absence of lucent lines in any zones in the X-rays. There was neither osteolysis nor any evidence of migration or change in the inclination of the component as evidenced

by the serial X-rays done in the follow-ups (Figures 2 and 3). The fractures were united in all cases as evidenced by the healing of fracture lines previously seen in the initial X-rays. There was formation of bone medial to the cup without any break, where bone graft was used to fill the defects. There was no subsidence or loosening of the femoral component as well in the serial radiographs. HO was noted in two patients. Both of them had additional posterior plate fixation. One patient with Brooker Class 2 HO remained asymptomatic and static after 2 years while the other patient had progressive increase to Brooker class 4 at the latest follow-up of 66 months.¹⁴ The patient was explained regarding the prognosis. He was walking with a limp. However, he was managing his activities of daily living without any analgesic abuse.

Complications

One patient had infection at 3 weeks, which resolved with debridement and liner exchange. One patient had partial sciatic nerve palsy, which gradually recovered after 4 months. One patient who had sciatic nerve palsy during the time of injury did not recover even after exploration during the surgery. The nerve was found entrapped by a fragment of bone from the posterosuperior wall. The patient is managing with a foot drop splint. One patient had dislocation following a fall, which was reduced by closed means. He was given hip abduction brace for 4 weeks. The hip remained stable then after. Two patients with ipsilateral lower limb injury had limb length discrepancy (one with shortening of 1.5 cm and the other with 2 cm), both were corrected by compensatory shoe raise and were walking symptom free.

Discussion

The prevention of post-traumatic arthritis and disability is the prime objective of treatment in a displaced acetabular fracture. In young and medically fit patients, a general consensus exists regarding open reduction and internal fixation.⁴ However, there are certain fracture patterns and types, where the open reduction and internal fixation might not yield a favorable outcome both immediately as well as in long term, rendering the patient with painful hip.^{9,15–17} The movements of such patients are highly compromised predisposing them to other secondary complications, which may require a total hip replacement in the near future. O'Toole et al.³ in their study of 147 elderly patients reported a high 1-year mortality rate of 25% and conversion to arthroplasty in 28% cases, following open reduction and internal fixation for displaced acetabular fractures.³ Kreder et al. reported the requirement of early acute THA in 54% of the patients after internal fixation for comminuted posterior wall fracture and marginal impaction.¹⁶ These subsets of patients may eventually require a THA irrespective of the method of initial treatment.^{18–20} Thus, it is

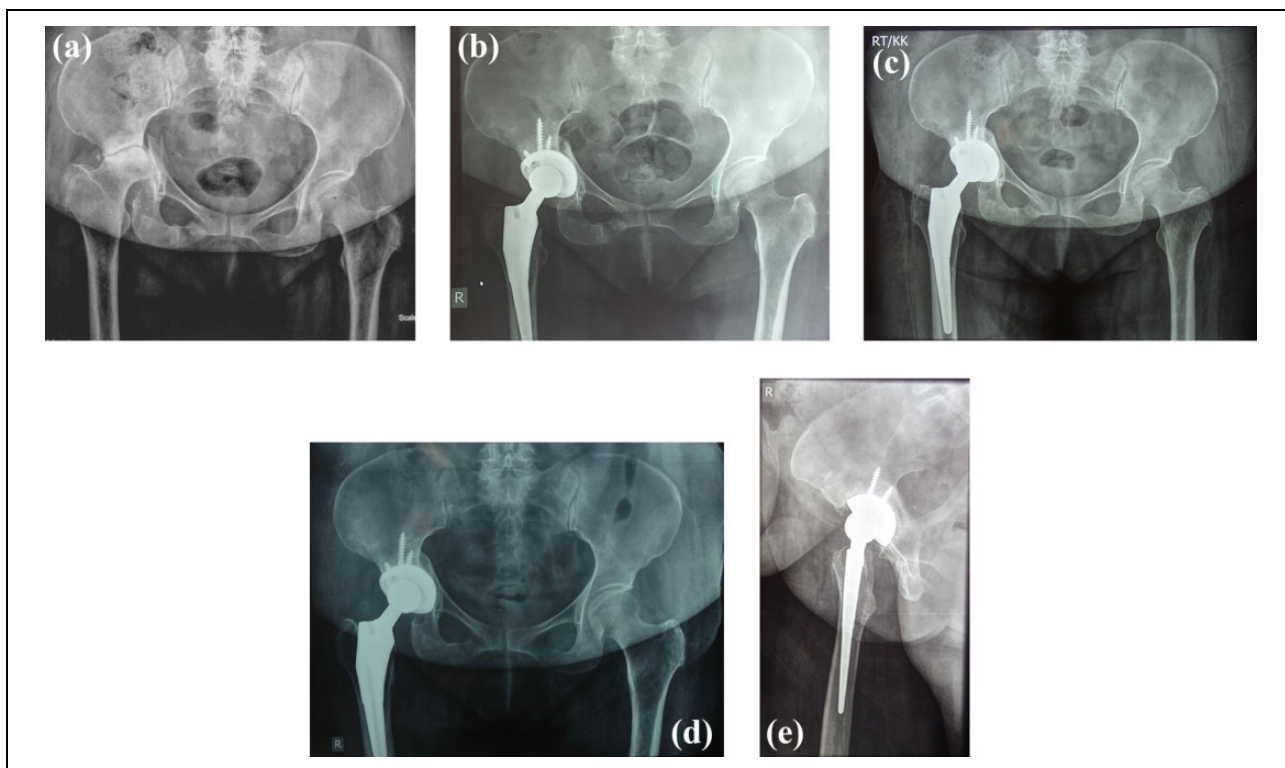


Figure 2. (a) Preoperative X-ray of both hips with pelvis of a 55-year-old female showing acetabular fracture in pre-existing hip arthritis of right side. (b) One year follow-up X-ray of both hips with pelvis in antero-posterior view showing total hip prosthesis in situ. Note the uniting fracture. (c) Two years follow-up X-ray showing healed fracture. Note the formation of bone with no break in the continuity medial to the cup. There is no change in cup position. (d) Sixty-six months' follow-up showing intact total hip prosthesis in situ. (e) Lateral view of right hip showing completely healed fracture.

worthwhile to perform an acute THA in these patients who have a likelihood of culminating in arthroplasty regardless of initial treatment. The main advantage of performing an acute THA is to minimize the delay between the acute fracture and the recovery from it. Acute THA reduces the period of immobilization and prevents secondary complications. Moreover, if an unacceptable deformity of the acetabulum is recognized soon after the injury, due to the inability to achieve an acceptable reduction or a delayed displacement, the problem can be adequately minimized or even fully corrected at the time of a promptly executed arthroplasty.⁸

The initial reports on acute THA in acetabular fractures were discouraging in the past, because of reported high rates of complications accounting to technical difficulties.^{2,12,21} Recent literature provides mixed results. Majority of them, of course, advocate acute THA in elderly patients.^{2,6-8,22} Very few have discussed acute THA for acetabular fractures in the young adults even though their likelihood to convert into an arthroplasty remains high as per certain fracture patterns. Mears and Velyvis had reported the results of acute THA in acetabular fractures in 57 patients, including the younger patients ranging 26–89 years age.⁷ With 83.33% (15 of 18) good to excellent results in the current study, the authors conclude that acute

THA can be a promising therapeutic alternative even for selected younger patients as well, should any unsatisfactory outcome is expected at the beginning of the fracture treatment.

The surgical challenge remains daunting due to the acetabular fracture itself, which creates difficulty in obtaining the acetabular component fixation. The newer porous metal cups allow rapid and enhanced biologic fixation of the acetabular cups into the bone even with <50% contact with the host bone as their coatings possess characteristics similar to cancellous bone. Their ability to aggregate thrombocytes around the coating is supposed to accelerate the osteointegration of shell into the acetabular bed.^{23,24} In our study, Regenerex™ Ringloc® multi-hole cup was used with an objective to achieve early osteointegration. Using the screws through the holes provided in the shell also stabilized the fractures. Although there is paucity of reports of use of this cup in primary THA, promising results have been reported in revision cases using the revision shell with same titanium coating.²⁵ Any defects seen were filled with the autogenous bone grafts taken from the femoral head. Care was taken to correctly position the center of rotation. Although, cages had been popularly used in the past to provide an initial stability, they are studded with certain shortcomings including, failure to achieve a rapid union

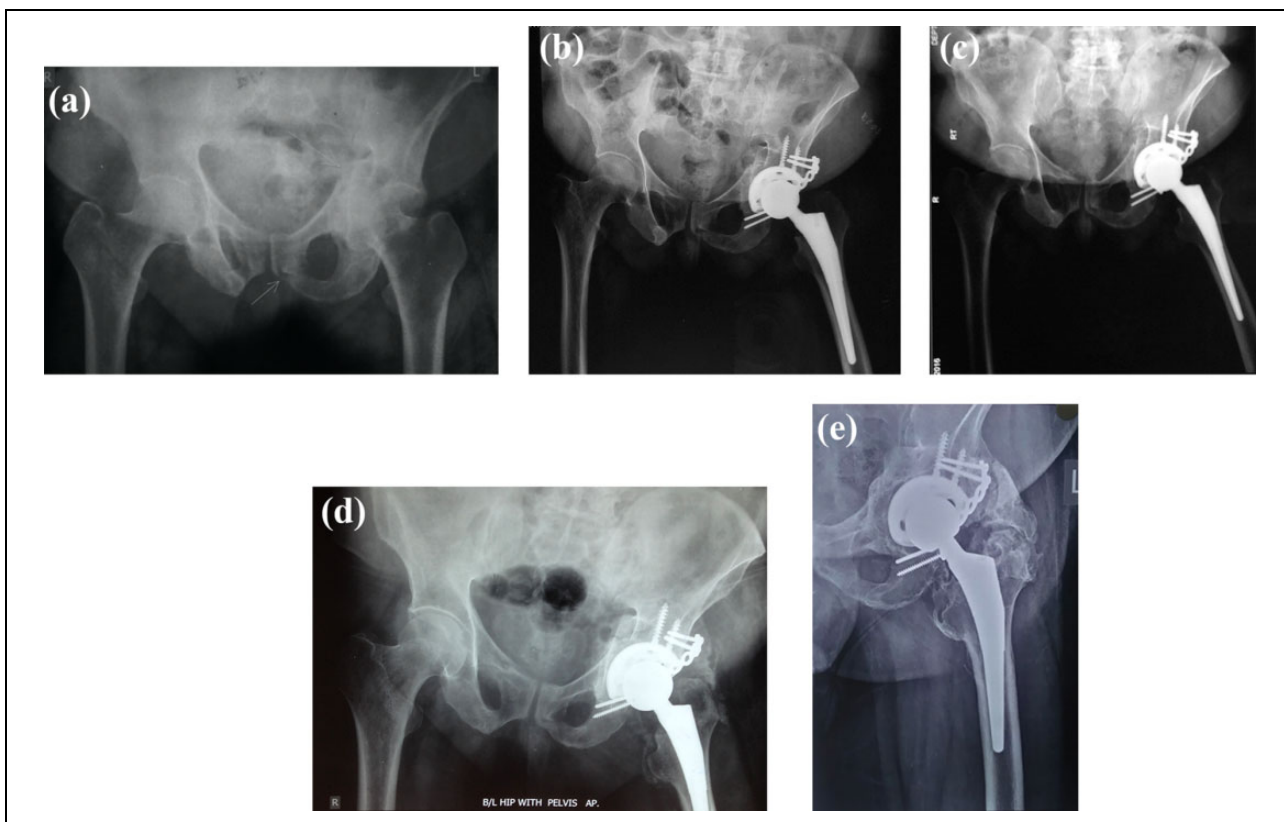


Figure 3. (a) Preoperative X-ray of both hips with pelvis of a 57-year-old male showing comminuted fracture of the left acetabulum. Intraoperatively, the head cartilage was also found to be damaged. As the fracture was unstable, he required posterior plate fixation and simultaneous acute total hip arthroplasty. (b) Immediate postoperative X-ray showing total hip prosthesis in situ. (c) One year follow-up showing total hip prosthesis in situ. (d) Two years follow-up showing healing fracture. Note the heterotopic ossification. There is no change in position of the acetabular component compared to the previous X-ray. (e) Sixty-six months' follow-up showing intact total hip prosthesis in situ. Note the progression of heterotopic ossification.

of the acetabulum leading to premature loosening of the cage, late deterioration of the bone cement interface with subsequent loss of fixation of the cup, and non-anatomical configuration where the cup does not fit properly in a highly deformed acetabulum.²⁶ The senior author (RM) has a vast experience of using special cages with osseointegration potential in the past, especially in severely comminuted displaced fractures where it is difficult to achieve a precise anatomical reduction.²⁷ However, the indications were limited to elderly patients only. The authors' choice of implant for acute THA in relatively younger patients has been a modern porous metal cup with or without additional plate fixation, while biological cages or cup cage construct are the choices in cases of elderly with osteoporotic bones or severe bone loss not amenable for fixation.

There is paucity of literature reporting the use of these modern porous cups for treatment of acute acetabular fractures. Initially used in revision surgeries only, these shells are being provided by the manufactures with a metal back, suitable for use in primary THA as well.¹¹ Kamath et al. reported the results of 12 patients (age ranging 24–88 years age) with acetabular fracture, who

underwent THA using porous metal cups.²⁸ At a mean period of 20 months, all the patients had favorable outcome except one. At average follow-up of 3 years, the porous metal components afforded improved clinical and radiographic outcomes in the majority of patients. The porous metal cups used in primary THA for conditions other than acetabular fractures have also been reported to have excellent results. In a study by Naziri et al. using highly porous titanium cups for 288 primary total hip replacements in 252 patients, no signs of progressive radiolucencies or changes in cup position were noticed at a mean follow-up of 36 months (range 24–56 months).²⁹ The mean HHS improved from 53 to 91. In another study by Noiseux et al. using a highly porous tantalum cup for 613 primary total hip arthroplasties in 558 patients followed up for 2–10 years, 98.9% survivorship of the acetabular component, free of revision for any reason, and 100% survivorship of the acetabular component, free of revision for aseptic loosening, were reported.³⁰ The outcome of our study supported the hypothesis that the use of modern design porous metal cup provides good stability; we could obtain early stability, durable fixation, and good to excellent results in this mid-term follow-up in our study

probably due to early osseointegration of the host bone with porous coated shell.

Conclusion

The results achieved in our study support the contention that primary total hip arthroplasty, using the modern porous metal cups, can be recommended for the successful management of selected types of acetabular fractures. The indication for acute total hip arthroplasty can be extended to young adult patients as well. However, longer follow-up may be required to vindicate our results further.

Limitations of study

There were certain limitations in our study. We had a small subset of patients. Nevertheless, excellent results in this subgroup of relatively young patients with mid-term follow-up using the modern porous metal cup can encourage its use in acetabular fractures. The other limitation in the study is that it is an ambispective case series; however, a prospective randomized study would hardly be possible on this topic. The main contributing factor for choosing this design in acute THA was senior author's experience using the contemporary designs in initial few cases and cases of post-traumatic osteoarthritis with less satisfactory results in early follow-up. Still, with limited evidence for acute THA in patients with acetabular fractures, the authors' strongly advocate that the surgeon's practice and expertise are still the most useful tools in clinical practice.


Declaration of conflicting interests

The author(s) declared no potential conflicts of interest with respect to the research, authorship, and/or publication of this article.

Funding

The author(s) received no financial support for the research, authorship, and/or publication of this article.

ORCID iD

Deepak Gautam  <https://orcid.org/0000-0002-8104-320X>

References

1. Kumar A, Shah NA, Kershaw SA, et al. Operative management of acetabular fractures. A review of 73 fractures. *Injury* 2005; 36(5): 605–612.
2. De Bellis UG, Legnani C, and Calori GM. Acute total hip replacement for acetabular fractures: a systematic review of the literature. *Injury* 2014; 45(2): 356–361.
3. O'Toole RV, Hui E, Chandra A, et al. How often does open reduction and internal fixation of geriatric acetabular fractures lead to hip arthroplasty? *J Orthop Trauma* 2014; 28(3): 148–153.
4. Editorial. *Injury. Int J Care Injur* 2010; 41: 777–779.
5. Guerado E, Cano JR, and Cruz E. Fractures of the acetabulum in elderly patients: an update. *Injury* 2012; 43(S2): S33–S41.
6. Sierra RJ, Mabry TM, Sems SA, et al. Acetabular fractures: the role of total hip replacement. *Bone Joint J* 2013; 95-B(Suppl A): 11–16.
7. Mears DC and Velyvis JH. Acute total hip arthroplasty for selected displaced acetabular fractures: 2–12-year results. *J Bone J Surg* 2002; 84A(1): 1–9.
8. Mears DC and Velyvis JH. Primary total hip arthroplasty after acetabular fracture. *Instr Course Lect* 2001; 50: 335–354.
9. Anglen JO, Burd TA, Hendricks KJ, et al. The “Gull Sign”: a harbinger of failure for internal fixation of geriatric acetabular fractures. *J Orthop Trauma* 2003; 17: 625–634.
10. Hamlin K, Lazaraviciute G, Koullouros M, et al. Should total hip arthroplasty be performed acutely in the treatment of acetabular fractures in elderly or used as a salvage procedure only? *Indian J Orthop* 2017; 51: 421–433.
11. Frank RM, Fabi D, and Levine BR. Modern porous coatings in orthopaedic applications. In: Nazarpour S (ed) *Thin Films and Coatings in Biology, Biological and Medical Physics, Biomedical Engineering*. Springer Science & Business Media Dordrecht, 2013, pp. 69–103. DOI: 10.1007/978-94-007-2592-8_3.
12. Harris WH. Traumatic arthritis of the hip after dislocation and acetabular fractures: treatment by mold arthroplasty. An end-result study using a new method of result evaluation. *J Bone Joint Surg Am* 1969; 51: 737–755.
13. De Lee JG and Charnley J. Radiological demarcation of cemented sockets in total hip replacement. *Clin Orthop Relat Res* 1976; 121: 20–32.
14. Hug KT, Alton TB, and Gee AO. Classifications in brief: Brooker classification of heterotopic ossification after total hip arthroplasty. *Clin Orthop Relat Res* 2015; 473(6): 2154–2157.
15. Bhandari M, Matta J, Ferguson T, et al. Predictors of clinical and radiological outcome in patients with fractures of the acetabulum and concomitant posterior dislocation of the hip. *J Bone Joint Surg [Br]* 2006; 88-B: 1618–1624.
16. Kreder HJ, Rozen N, Borkhoff CM, et al. Determinants of functional outcome after simple and complex acetabular fractures involving the posterior wall. *J Bone Joint Surg [Br]* 2006; 88B: 776–782.
17. Matta JM. Fractures of the acetabulum: accuracy of reduction and clinical results in patients managed operatively within three weeks after injury. *J Bone Joint Surg [Am]* 1996; 78A: 1632–1645.
18. Vail TP and McCollum DE. Complex primary acetabular replacement. In: Callaghan JJ, Rosenberg AG and Rubash HE (eds) *The Adult Hip*. Philadelphia: Lippincott-Raven, 1998, pp. 1183–1200.
19. Letournel E and Judet M. *Fractures of the Acetabulum*, 2nd ed. New York: Springer, 1993, pp. 359–386.
20. Tile M. *Fractures of the Pelvis and Acetabulum*, 2nd ed. Baltimore: Williams and Wilkins, 1995, pp. 176–184.
21. Kelly PJ and Lipscomb PR. Primary vitallium-mold arthroplasty for posterior dislocation of the hip with fracture of the femoral head. *J Bone Joint Surg Am* 1958; 40: 675–680.

22. Coventry MB. The treatment of fracture–dislocation of the hip by total hip arthroplasty. *J Bone Joint Surg Am* 1974; 56(6): 1128–1134.
23. Jauregui JJ, Clayton A, Kapadia BH, et al. Total hip arthroplasty for acute acetabular fractures: a review of the literature. *Exp Rev Med Devices* 2015; 12(3): 287–295.
24. Szypuła J and Kedziora J. The use of titanium sponge in hip revision replacement prosthesis-preliminary report. *Pol Merkur Lekarski* 2009; 27(160): 315–317.
25. Karageorgiou V and Kaplan D. Porosity of 3D biomaterial scaffolds and osteogenesis. *Biomaterials* 2005; 26(27): 5474–5491.
26. Bonicoli E, Piolanti N, Andreani L, et al. Preliminary report with the Regenerex™ revision shell: clinical, functional, and radiologic evaluations with a mean follow-up of 25 months. *Eur Orthop Trauma* 2013; 3(4): 9–14.
27. Malhotra R, Singh DP, Jain V, et al. Acute total hip arthroplasty in acetabular fractures in the elderly using the octopus system: mid term to long term follow-up. *J Arthrop* 2013; 28(6): 1005–1009.
28. Kamath AF, Evangelista PJ, and Nelson CL. Total hip arthroplasty with porous metal cups following acetabular fracture. *Hip Int* 2013; 23(5): 465–471.
29. Naziri NO, Issa K, Pivec R, et al. Excellent results of primary THA using a highly porous titanium cup. *Orthopedics* 2013; 36(4): e390–e394.
30. Noiseux NO, Long WJ, Mabry TM, et al. Uncemented porous tantalum acetabular components: early follow-up and failures in 613 primary total hip arthroplasties. 2014; 29(3): 617–620.