

Evaluation of the efficacy and safety of MRI-guided focused ultrasound (MRgFUS) for focal hand dystonia: study protocol for an open-label non-randomised clinical trial

Joel Maamary ,^{1,2} James Peters,^{1,2} Kain Kyle,³ Diane Ruge,⁴ Benjamin Jonker,⁵ Yael Barnett,⁶ Stephen Tisch¹

To cite: Maamary J, Peters J, Kyle K, *et al*. Evaluation of the efficacy and safety of MRI-guided focused ultrasound (MRgFUS) for focal hand dystonia: study protocol for an open-label non-randomised clinical trial. *BMJ Neurology Open* 2023;5:e000522. doi:10.1136/bmjno-2023-000522

Received 21 August 2023
Accepted 23 September 2023

ABSTRACT

Introduction MRI-guided focused ultrasound (MRgFUS) thalamotomy provides an exciting development in the field of minimally invasive stereotactic neurosurgery. Current treatment options for focal hand dystonia are limited, with potentially more effective invasive stereotactic interventions, such as deep brain stimulation or lesional therapies, rarely used. The advent of minimally invasive brain lesioning provides a potentially safe and effective treatment approach with a recent pilot study establishing MRgFUS Vo-complex thalamotomy as an effective treatment option for focal hand dystonia. In this study, we undertake an open-label clinical trial to further establish MRgFUS Vo-complex thalamotomy as an effective treatment for focal hand dystonia with greater attention paid to potential motor costs associated with this treatment. To elucidate pathophysiology of dystonia and treatment mechanisms, neurophysiological and MRI analysis will be performed longitudinally to explore the hypothesis that neuroplastic and structural changes that may underlie this treatment benefit.

Methods and analysis A total of 10 participants will be recruited into this open-label clinical trial. All participants will undergo clinical, kinematic, neurophysiological and radiological testing at baseline, followed by repeated measures at predesignated time points post MRgFUS Vo-complex thalamotomy. Further, to identify any underlying structural or neurophysiological abnormalities present in individuals with focal hand dystonia, 10 age and gender matched control participants will be recruited to undergo comparative investigation. These results will be compared with the intervention participants both at baseline and at 12 months to assess for normalisation of these abnormalities, if present.

Ethics and dissemination This trial was reviewed and approved by the St Vincent's Health Network Sydney Human Research Ethics Committee (2022/ETH00778). Study results will be published in peer-reviewed journals and presented at both national and international conferences.

Trial registration number CTRN12622000775718.

INTRODUCTION

Dystonias are a complex group of movement disorders that are characterised by sustained or intermittent muscle contractions resulting

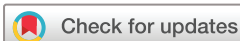WHAT IS ALREADY KNOWN ON THIS TOPIC

⇒ A recent pilot study established that unilateral MRI-guided focused ultrasound (MRgFUS) Vo-complex thalamotomy significantly improved the symptoms of focal hand dystonia, with treatment benefit persisting out to 12 months follow-up. While this trial established treatment efficacy and an acceptable side effect profile, there was no quantification of the potential motor cost associated with this procedure.

WHAT THIS STUDY ADDS

⇒ This trial further establishes the efficacy and safety profile of unilateral MRgFUS Vo-complex thalamotomy in focal hand dystonia. While the number of published cases of MRgFUS Vo thalamotomy for focal and dystonia remains small, this validation of the efficacy and safety is still required. Additionally, it provides a rigorous analysis of upper limb and hand function to quantify any motor cost associated with the procedure. Given the task specific nature of focal hand dystonia, and the potential effect on livelihood, this information is crucial in ensuring informed treatment decisions. Further, this trial includes neurophysiological and MRI imaging component to assess the neurophysiological and structural abnormalities that exist in individuals with focal hand dystonia in addition to observing changes in these measures post MRgFUS thalamotomy.

in abnormal movements, postures or both.¹ Focal dystonia refers to those dystonias where the abnormal movement is isolated to a single body part. Involvement of the upper limb is termed focal hand dystonia and can be classified as either a task-specific action dystonia, whereby the dystonia can be predictably triggered by performance of a specific motor task, or paroxysmal, with episodes of dystonia that occur without specific task performance or persistent.² For the purposes of this manuscript, focal hand dystonia refers to that



© Author(s) (or their employer(s)) 2023. Re-use permitted under CC BY-NC. No commercial re-use. See rights and permissions. Published by BMJ.

For numbered affiliations see end of article.

Correspondence to

Dr Joel Maamary;
joel.maamary@svha.org.au

HOW THIS STUDY MIGHT AFFECT RESEARCH, PRACTICE OR POLICY

⇒ The information obtained from this trial may further establish MRgFUS thalamotomy as an effective treatment option for individuals with focal hand dystonia. However, a significant portion of informed decision-making relates to the potential motor cost that may occur as a result of the thalamotomy. It may be that, while MRgFUS thalamotomy reduces the symptoms of focal hand dystonia, there is slowing and imprecision of movement postprocedure, and this information is crucial in informing both clinicians and patients regarding the best potential treatment option.

dystonia which is task-specific and isolated to the upper limb. The most common subtypes of focal task-specific hand dystonia are ‘musician’s dystonia’ and ‘writer’s cramp’.³ Musician’s dystonia presents as muscular incoordination, or loss of voluntary control, in extensively trained musicians.^{4 5} The specific pattern of abnormal muscle activation varies depending on the instrument being played; for example, pianist’s or violinist’s cramp may affect the control of finger, hand or arm movements, whereas an embouchure dystonia affects the lips, tongue, facial or cervical muscles in brass and wind players.⁶ Similarly, writer’s cramp is characterised by involuntary movements and posturing that typically affects the fingers, hand and forearm and occurs during writing.⁶

Estimates of the prevalence of dystonia vary depending on the subtype and the population studied. General estimates suggest that approximately 16–30 per 100 000 individuals are affected,^{7 8} however, the incidence of idiopathic dystonia is significantly higher in those aged 50 years or older (732 per 100 000).² While dystonia may be more common among an ageing population, there is marked variability in prevalence due to a lack of clear clinical criteria and a wide range of symptom severity. Focal hand dystonia, specifically, affects approximately 7–70 individuals per million in the general population, with a higher prevalence reported in at-risk populations, such as professional musicians where dystonia has been noted in up to 14% of musician-related health clinic presentations.⁹

Individuals with focal dystonia are often disabled and unable to perform the task related to their dystonia with subsequent implications on their profession, livelihood and quality of life.⁶ The aetiology of focal hand dystonia is unknown, however, both genetic and environmental factors have been implicated. Individuals with focal dystonia have demonstrated abnormalities in sensory processing, sensorimotor organisation, motor excitability and increased cortical plasticity.^{10 11} It is proposed that, while it may speed motor learning, this increased cortical plasticity may predispose to the formation of unwanted motor associations, hence task specific involuntary movements.¹⁰ Recent investigation suggests that focal dystonia is likely a manifestation of abnormalities of the entire

sensorimotor network¹² that is amenable to targeted neurosurgical approaches.¹³

Current treatment options for focal dystonia are limited to short term symptom relief with low efficacy oral medications or local treatment with botulinum toxin. Physical therapies and rehabilitation have been reported to provide some improvement, but this evidence is not definitive.¹⁴ Unlike generalised or segmental dystonia syndromes, where the GPi (globus pallidus internus) is preferred, small non-randomised trials suggest that focal hand dystonia responds well to targeted intervention of the thalamus; specifically, the Vo complex.¹⁵ Thalamic deep brain stimulation (DBS) is an effective treatment option for individuals with writer’s cramp^{16 17}; however, there are inherent risks associated with DBS, including perioperative anaesthetic complications, intraparenchymal haemorrhage, electrode/lead breakage or infection. The use of stereotactic thalamotomy, which involves an open surgical or radiofrequency incision of the thalamus, has demonstrated significant improvement in focal hand dystonia but is similarly an invasive treatment modality.¹³ Gamma-knife ablation of the Vo-complex has reported positive outcomes in musician’s dystonia, however, this carries the risk of radiation exposure and neoplasia.^{18 19} MRI-guided focused ultrasound (MRgFUS) is a minimally invasive functional neurosurgical technique that aims to avoid the risk associated with more invasive stereotactic surgical modalities. This technique involves the administration of targeted beams of ultrasound energy through the skull, without requiring a surgical incision, to ablate specific neural pathways without damaging the surrounding brain tissue. MRgFUS thalamotomy is a safe and effective treatment option for multiple tremor syndromes²⁰ and has both Therapeutic Goods Administration (TGA) and US Food and Drug Administration approval for the treatment of essential tremor. The use of MRgFUS Vo thalamotomy for focal hand dystonia, without tremor, was proposed as an alternative to more invasive stereotactic surgery in 2018,²¹ with the first case report appearing soon after.²² Since this time, a recent pilot study has provided evidence that MRgFUS thalamotomy provides relief of the symptoms of focal hand dystonia with clinical benefit extending out to 12 months post-treatment.²³ While the thalamus has an important role in motor planning and execution, it also has a complex role in the integration and processing of non-motor information, including sensory perception, arousal modulation, limbic regulation of mood and motivation, and associative inputs connoting cognition.²⁴ Thalamic anatomy can be parcellated based on neuropathological and functional neuroimaging to allow the targeted intervention of motor pathways with preservation of non-motor thalamic function, however, there is little data reporting the loss of fine motor control, learning or task imprecision following MRgFUS. It may be that,

while MRgFUS thalamotomy reduces the symptoms of focal dystonia, there is slowing of movement with imprecision, or deautomation, of sequential learnt movements post-thalamotomy. Given the precision, accuracy and tempo required for high level musical performance, either inadequate treatment efficacy or potential motor costs may be significant for professional musicians. The balance of symptomatic benefit and motor cost is crucial in informing joint clinician–patient treatment decisions. Further, the effect of MRgFUS thalamotomy on neuroplasticity and motor learning is yet to be understood.

Study rationale

The advent of MRgFUS thalamotomy in the treatment of focal hand dystonia provides an exciting development in the field of minimally invasive stereotactic neurosurgery. The ventro-oral complex, or Vo-complex, of the motor thalamus acts as the main input structure for pallidal fibres and is an important node in the pallidothalamic network. Pallidal afferents to the Vo-complex assist in the programmed control of movement patterns and are modified with repeated trials of a motor task, indicating the important role of these pathways in motor learning.²⁵ Stereotactic thalamotomy of the Vo-complex is an established method of treatment in focal hand dystonia that provides long-term relief of symptoms.^{17 26–28} A recent retrospective analysis of 171 patients who underwent surgical Vo-complex thalamotomy for focal hand dystonia demonstrated sustained symptom relief at 12-month follow-up, with recurrence in only 10% of patients.²⁹ MRgFUS thalamotomy provides a minimally invasive incisionless alternative to open surgical thalamotomy and recent case reports have demonstrated safety and feasibility of this approach in focal hand dystonia.^{22 30 31}

Horisawa *et al*²³ published the first open-label trial of MRgFUS thalamotomy in writer’s cramp and musician’s dystonia with sustained improvement in symptoms reported at 12 months. Symptoms of dystonia recurred in 3 patients (30%). This trial established the feasibility of minimally invasive approaches for thalamic lesioning in focal hand dystonia. However, given that task specific focal hand dystonia occurs in the context of performing a highly practised, repeated skill, a pure reduction in the severity of the dystonia, following thalamotomy, may not necessarily equate to a desirable treatment outcome. Further, the procedure may be associated with quantifiable slowing of movement, with imprecision or even deautomation of sequenced learnt movements, post-thalamotomy. This information is crucial in informing treatment decisions prior to consideration of thalamotomy. It is our hypothesis that, while MRgFUS Vo-complex thalamotomy may improve the symptoms of dystonia, as measured by validated questionnaires and task performance, it may result in quantifiable losses in

hand strength, velocity and function. To this end, we plan to use validated task specific dystonia questionnaires in addition to objective measures of finger and grip strength, as well as functional upper limb task measurement, both pre-treatment and post-treatment with between group comparisons.

A secondary aim of this study is to assess the effect of MRgFUS Vo-complex thalamotomy on the abnormal synaptic plasticity, cortical inhibition and basal ganglia/cerebellar network changes that are thought to underlie the pathophysiology of focal hand dystonia. Given that Vo-complex thalamotomy has been shown to reduce the symptoms of focal hand dystonia, we hypothesise that disruption of the pallidothalamic tract, via thalamotomy, will lead to changes in neurophysiological measures with a shift brain plasticity and cortical inhibition, towards normal levels comparable to healthy control participants.¹¹ As basal ganglia hyperactivation has been implicated in focal hand dystonia, using functional MRI (fMRI) techniques,¹² motor, premotor, supplementary motor and basal ganglia activity will be analysed using resting state fMRI pretreatment and post-treatment, in addition to comparison of these findings with asymptomatic controls with a proposed shift to normalisation. Advanced imaging methods, using diffusion tensor imaging (DTI), have demonstrated abnormalities in fibre tracts connecting the primary sensorimotor regions to subcortical structures in focal hand dystonia³² and we aim to assess the effect of Vo-complex thalamotomy on these both these pathways in addition to microstructural changes in the pallidothalamic tract. Similarly, these changes will be compared with healthy control participants at baseline with proposed normalisation of fractional anisotropy.

Objectives

Primary objective

The primary objective of this trial is to establish the efficacy of MRgFUS Vo-complex thalamotomy for the treatment of focal hand dystonia using the Arm Dystonia Disability Scale (ADDS)³³ and Writer’s Cramp Rating Scale (WCRS)³⁴ or Tubiana Musicians Dystonia Scale (TMDS),³⁵ as appropriate.

Secondary objectives

1. To establish the adverse event profile of MRgFUS Vo-complex thalamotomy for the treatment of focal hand dystonia.
2. To establish the motor cost associated with MRgFUS Vo-complex thalamotomy by comparing standardised measures of upper limb function preprocedure and postprocedure.
3. To compare baseline measures of neuroplasticity and cortical inhibition in individuals with focal hand dystonia and healthy controls, in addition to comparing

the changes in neuroplasticity and cortical inhibition prethalamotomy and post-thalamotomy.

- To compare baseline radiological measures using DTI and fMRI in individuals with focal hand dystonia and healthy controls, in addition to comparing the changes in these radiological measures prethalamotomy and post-thalamotomy.

METHODS AND ANALYSIS

Study design

This trial is an open-label clinical trial. Recruitment commenced in November 2022 and is expected to finish in December 2023.

MRgFUS Vo-complex thalamotomy

The MRgFUS intervention will be performed according to the following protocol: on the day of treatment, participants will undergo a head shave and the administration of local anaesthetic blocks prior to application of a stereotactic head frame. An elastic diaphragm is then placed over the scalp and affixed to the ultrasound transducer prior to being filled with cooled, degassed water. Participants are then placed into the 3-Tesla MRI scanner (SIGNA Architect, General Electric) and 3D T1-weighted imaging performed for localisation of the ventro-oral anterior and ventro-oral posterior nuclei. Lesions are created using an Exablate Neuro (InSightec) 650 Hz, 1024-element, phased array ultrasound transducer. Initial operative planning is performed with a series of low power sonications producing mean temperatures of 40°C–45°C to confirm accurate focusing in three orthogonal planes with MR thermography. MR thermometry is used to measure the maximum temperature at target's central voxel, centring on the target. Following confirmation of accurate targeting, therapeutic sonications are performed by gradually increasing the ultrasound energy and monitoring both the maximal and average temperatures at the target for each sonication. Clinical examinations are performed between each sonication to assess for focal hand dystonia and for the presence of side effects. This protocol is in keeping with the current TGA approved protocol for the use of MRgFUS in tremor treatment.

Eligibility criteria

Inclusion criteria

Participants will be included based on a formal diagnosis of focal task-specific action hand dystonia according to the MDS 2013 classification of dystonia consensus paper.² Individuals may be included if there is mild paroxysmal or persistent dystonia only if the dystonia was noted to be task-specific at onset. Participants must be at least 18 years of age and be willing to provide written consent to participate in the study. Participants must have tried and failed at least one first line therapy for focal hand dystonia, including hand therapy, oral medications and/or botulinum toxin injections. All participants must be ambulant at the time of the procedure.

Exclusion criteria

- ▶ History of ischaemic stroke or transient ischaemic event.
- ▶ History of stereotactic cerebral surgery.
- ▶ Diagnosis of unstable cardiac disease.
- ▶ Diagnosis of psychiatric disease.
- ▶ Cognitive impairment as indicated by a Mini-Mental State Examination (MMSE) score of <24.
- ▶ Coagulopathy or on anticoagulation that cannot be withheld for the intervention.
- ▶ Skull density ratio of <0.3.
- ▶ Absolute contraindication to MRI (eg, non-MR compatible pacemaker/defibrillator or other non-MR compatible device in situ).
- ▶ Relative contraindication to MRI (such as severe claustrophobia) will be assessed on a case-by-case basis.
- ▶ Unwilling to provide written informed consent.

Rationale for study design

This trial is an open-label clinical trial study design with baseline comparison to age and gender matched controls. This design allows for comparison of differences in kinematic, neurophysiological and imaging based parameters that exist individuals with focal hand dystonia compared with 'healthy' controls. Further, prospective follow-up and data analysis provide insights into treatment efficacy, safety and examines the network changes underpinning improvement in focal hand dystonia.

Treatment groups

This study will be performed on a single cohort of patients with the aim of recruiting ten participants to the open-label trial. All patients have been, or will be, included in the trial based on a formal diagnosis of focal hand dystonia made by a consultant neurologist with specialist expertise in movement disorders. The clinical syndromes of focal hand dystonia will include, but not be limited to, writer's cramp and musician dystonia, with other forms of task specific focal hand dystonia eligible for screening towards study inclusion.

Following enrolment, all intervention participants undergo baseline assessment followed by MRgFUS Vo-complex thalamotomy the following day. A group of 10 age-matched control subjects will be recruited to undergo baseline MRI, neurophysiological and clinical/kinematic testing to establish whether differences exist at baseline. These individuals will not undergo the remaining assessments or follow-up. The control participants will sign a consent form and be made aware that they will not undergo any procedure or follow-up thereafter.

Data collection methods

Data collection will occur at baseline and at 1, 3, 6 and 12 months postprocedure (figure 1). Baseline demographic data (age, gender, hand dominance) will be recorded as standard. Cognitive screening, using the MMSE and mood disturbance, using the Beck Depression Inventory,

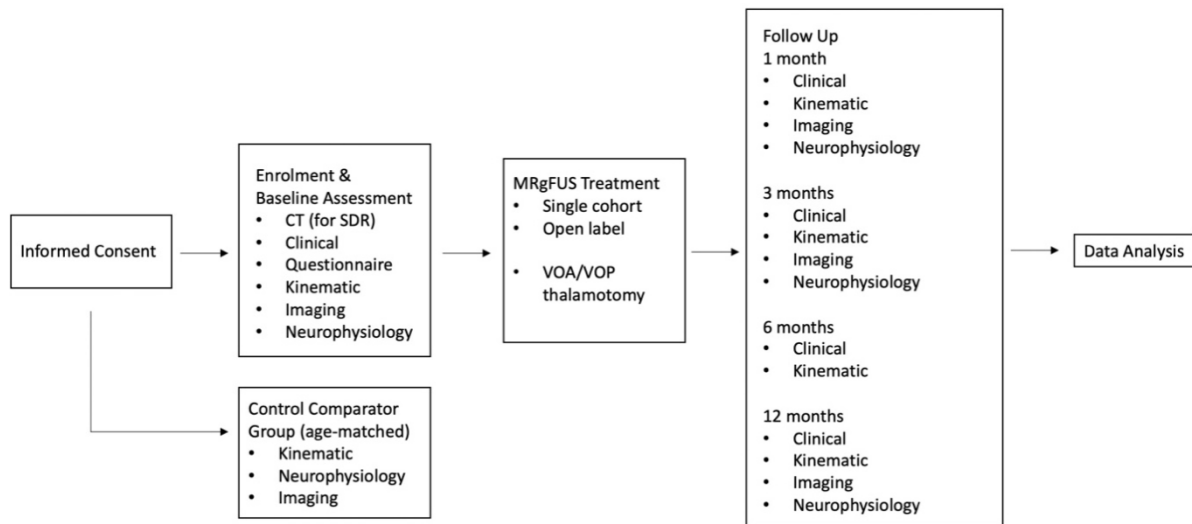


Figure 1 Trial design flow chart. MRgFUS, MRI-guided focused ultrasound. (SDR - skull density ratio, VOA - ventralis oralis anterior, VOP - ventralis oralis posterior)

will be obtained in all participants. The remaining data will be collected as outlined in [table 1](#).

Primary outcome

For the primary outcome, treatment efficacy will be based on administration of the ADDS, either the TMDS or WCRS depending on the syndromic diagnosis, in addition to the Michigan Hand Outcomes Questionnaire³⁶ and Short Form-36 scores of quality of life, at 1, 3, 6 and 12 months post-treatment. All testing and scoring will be undertaken by study authors JM and ST.

Secondary outcomes

The adverse event profile of MRgFUS Vo-complex thalamotomy will be assessed using standardised recording sheets applied on days 0 and 1 postprocedure, in addition to all study timepoints. To assess the motor cost associated with Vo-complex thalamotomy, measures of grip and pincer strength (measured in kg force) will be

undertaken at baseline and all time points in addition to validated measures of upper limb function using the box-and-block test, Purdue 9-hole peg and grooved peg tests.

Measures of neuroplasticity will be derived using transcranial magnetic stimulation and paired associative stimuli to obtain pretreatment and post-treatment measures of long-term potentiation-like plasticity with short-latency afferent facilitation, spatial specificity, short-latency intracortical inhibition and stimulus-response curves. These measures will be compared with control participants, at baseline, to assess for any differences in individuals with focal hand dystonia prior to intervention. Repeated measures will be obtained at regular intervals post-treatment as outlined above to identify the effect of MRgFUS Vo-complex thalamotomy on these measures of plasticity.

Radiological outcomes will be assessed by DTI of the pallidothalamic and surrounding tracts to assess for

Table 1 Data collection and time points

List	Enrolment/baseline	Day 0	Day 1	1 month	3 months	6 months	12 months
Informed consent	✓						
Inclusion/exclusion criteria	✓						
Physical examination	✓	✓	✓	✓	✓	✓	✓
Video assessment	✓	✓	✓	✓	✓	✓	✓
CT brain scan	✓						
Questionnaires (ADDS, MHOQ, TMDS/WCRS, SF-36, MMSE, BDI)	✓			✓	✓	✓	✓
MRI	✓	✓		✓	✓		✓
Kinematic assessment	✓			✓	✓	✓	✓
Neurophysiology	✓			✓	✓		✓
Adverse event and serious adverse event assessment		✓	✓	✓	✓	✓	✓

ADDS, Arm Dystonia Disability Scale; BDI, Beck Depression Inventory; MHOQ, Michigan Hand Outcomes Questionnaire; MMSE, Mini-Mental State Examination; SF-36, Short Form-36; TMDS, Tubiana Musicians Dystonia Scale; WCRS, Writer's Cramp Rating Scale.

microstructural, both at baseline in comparison to individuals without focal hand dystonia, and repeated to identify alterations post Vo-complex thalamotomy. Resting state fMRI will be implemented to identify changes in premotor, motor and supplementary motor cortical activity in individuals with focal dystonia in addition to the basal ganglia. All radiological outcomes will be repeated at 1, 3 and 12 months post-treatment.

Sample size and statistical analysis

A preliminary sample-size calculation indicates that we will require eight patients to detect a 50% improvement in focal hand dystonia (based on standardised rating scales and a predicted similar outcome to a recent pilot study) at $p < 0.05$ with 0.9 power and an SD of 0.30. Ideally, we aim to recruit at least 10 patients to the trial and possibly more pending patients fulfilling inclusion criteria. The data will be analysed using analysis of variance (ANOVA) with main effect of time at 1, 3, 6 and 12 months follow-up intervals. Post hoc paired t-tests (or Shapiro-Wilk if the data is non-normative) will be used where effects of time are identified by ANOVA. Non-parametric variables will be compared pre and post using Wilcoxon signed-rank test.

Patient and public involvement

Patients and the public were not involved in the design of this trial due to its early clinical phase model. Patients were involved in the trial at the time of recruitment and were consulted for their opinion on methods of assessment of fine motor tasks and task performance. Participants in this trial will be primarily recruited from the neurology and movement disorders clinics of the Department of Neurology at St Vincent's Hospital Sydney. The study treatment costs are fully funded and no financial cost will be borne by participating patients. Additionally, the trial has been advertised through the Brain Foundation, with specific reference made to the trial during a presentation on dystonia given by author JM for Brain Awareness week 2023. The trial details have been disseminated by both the Dystonia Network of Australia and the Australia Dystonia Support Group to all active members. Further, this trial was featured on the Australian Broadcasting Corporation's nationally televised programme '7:30' on the 26 June 2023. Once the trial results have been published, participants will be informed by the study authors by a dedicated study newsletter.

DISSEMINATION

All adverse events, both non-serious and serious, are recorded and reported to the HREC by the study investigators. All data will be stored securely for five years, in accordance with the National Statement on Ethics Conduct,³⁷ as well as NSW (New South Wales) health data storage requirements under the Health Records and Information Privacy Act, and will be destroyed thereafter. Paper records will be disposed of in confidential recycling bins and electronic files permanently deleted.

Given its clinical importance, the study will be presented for publication in high-quality neurology journals with a movement disorder subinterest. The strength of this study is in its relative novelty (only the second group worldwide to commence MRgFUS Vo-complex thalamotomy for focal hand dystonia) and the depth of analysis of motor outcomes to fully assess positive and negative impacts of treatment, as well as the corresponding structural and neurophysiological changes underlying those outcomes. Further, all results will be published with the ANZCTR at anzctr.org.au.

Author affiliations

¹Department of Neurology, St Vincent's Health Australia Ltd, Sydney, New South Wales, Australia

²School of Clinical Medicine, University of New South Wales, Sydney, New South Wales, Australia

³Brain and Mind Centre, The University of Sydney, Sydney, New South Wales, Australia

⁴Laboratoire de Recherche en Neurosciences Cliniques, Montpellier, France

⁵Department of Neurosurgery, St Vincent's Health Australia Ltd, Sydney, New South Wales, Australia

⁶Department of Radiology, St Vincent's Health Australia Ltd, Sydney, New South Wales, Australia

Twitter Joel Maamary @JoelMaamary

Contributors JM and ST drafted the first version of this paper, which was subsequently revised and approved by all authors. All authors have contributed to the design of the study and will be involved in conducting the trial.

Funding This work was supported by philanthropic donation from the John and Margaret Cunningham foundation, via the St Vincent's Curran Foundation, in addition to a research grant received from the Brain Foundation. JM has received a personal PhD top up grant from the Dystonia Network of Australia to contribute to the completion of this work.

Competing interests None declared.

Patient consent for publication Not applicable.

Ethics approval This study involves human participants and this trial was reviewed and approved by the St Vincent's Health Network Sydney Human Research Ethics Committee (2022/ETH00778). Participants gave informed consent to participate in the study before taking part.

Provenance and peer review Not commissioned; externally peer reviewed.

Open access This is an open access article distributed in accordance with the Creative Commons Attribution Non Commercial (CC BY-NC 4.0) license, which permits others to distribute, remix, adapt, build upon this work non-commercially, and license their derivative works on different terms, provided the original work is properly cited, appropriate credit is given, any changes made indicated, and the use is non-commercial. See: <http://creativecommons.org/licenses/by-nc/4.0/>.

ORCID iD

Joel Maamary <http://orcid.org/0000-0002-4547-9866>

REFERENCES

- Nutt JG, Muenter MD, Aronson A, *et al*. Epidemiology of focal and generalized dystonia in Rochester, Minnesota. *Mov Disord* 1988;3:188–94.
- Albanese A, Bhatia K, Bressman SB, *et al*. Phenomenology and classification of dystonia: a consensus update. *Mov Disord* 2013;28:863–73.
- Sadnicka A, Kassavetis P, Pareés I, *et al*. Task-specific dystonia: pathophysiology and management. *J Neurol Neurosurg Psychiatry* 2016;87:968–74.
- Altenmüller E, Jabusch H-C. Focal hand dystonia in musicians: phenomenology, etiology, and psychological trigger factors. *J Hand Ther* 2009;22:144–54.
- Pullman SL, Hristova AH. Musician's dystonia. *Neurology* 2005;64:186–7.

- 6 Stahl CM, Frucht SJ. Focal task specific dystonia: a review and update. *J Neurol* 2017;264:1536–41.
- 7 Brandfonbrener AG. Musicians with focal dystonia: a report of 58 cases seen during a ten-year period at a performing arts medicine clinic. *Med Probl Perform Art* 1995;10:121–7.
- 8 Medina A, Nilles C, Martino D, et al. The prevalence of idiopathic or inherited isolated dystonia: a systematic review and meta-analysis. *Mov Disord Clin Pract* 2022;9:860–8.
- 9 Rosenkranz K, Williamon A, Butler K, et al. Pathophysiological differences between musician's dystonia and writer's cramp. *Brain* 2005;128:918–31.
- 10 Quartarone A, Siebner HR, Rothwell JC. Task-specific hand dystonia: can too much plasticity be bad for you? *Trends Neurosci* 2006;29:192–9.
- 11 Quartarone A, Bagnato S, Rizzo V, et al. Abnormal associative plasticity of the human motor cortex in writer's cramp. *Brain* 2003;126:2586–96.
- 12 Blood AJ, Flaherty AW, Choi J-K, et al. Basal ganglia activity remains elevated after movement in focal hand dystonia. *Ann Neurol* 2004;55:744–8.
- 13 Taira T, Hori T. Stereotactic ventrooralis thalamotomy for task-specific focal hand dystonia (writer's cramp). *Stereotact Funct Neurosurg* 2003;80:88–91.
- 14 Hautekiet A, Raes K, Geers S, et al. Evidence of rehabilitation therapy in task-specific focal dystonia: a systematic review. *Eur J Phys Rehabil Med* 2021;57:710–9.
- 15 Fukaya C, Katayama Y, Kano T, et al. Thalamic deep brain stimulation for writer's cramp. *J Neurosurg* 2007;107:977–82.
- 16 Cho CB, Park HK, Lee KJ, et al. Thalamic deep brain stimulation for writer's cramp. *J Korean Neurosurg Soc* 2009;46:52–5.
- 17 Asahi T, Koh M, Kashiwazaki D, et al. Stereotactic neurosurgery for writer's cramp: report of two cases with an overview of the literature. *Stereotact Funct Neurosurg* 2014;92:405–11.
- 18 Nonaka T, Horisawa S, Taira T, et al. Long term effect of gamma knife ventro-oral thalamotomy for musician's dystonia: a case report. *Jpn J Neurosurg* 2018;27:222–6.
- 19 Horisawa S, Tamura N, Hayashi M, et al. Gamma knife ventro-oral thalamotomy for musician's dystonia. *Mov Disord* 2017;32:89–90.
- 20 Elias WJ, Lipsman N, Ondo WG, et al. A randomized trial of focused ultrasound thalamotomy for essential tremor. *N Engl J Med* 2016;375:2202–3.
- 21 Tisch S. Recent advances in understanding and managing dystonia. *F1000Res* 2018;7:F1000 Faculty Rev-1124.
- 22 Horisawa S, Yamaguchi T, Abe K, et al. A single case of MRI-guided focused ultrasound Ventro-oral thalamotomy for musician's dystonia. *J Neurosurg* 2019;131:384–6.
- 23 Horisawa S, Yamaguchi T, Abe K, et al. Magnetic resonance-guided focused ultrasound thalamotomy for focal hand dystonia: a pilot study. *Mov Disord* 2021;36:1955–9.
- 24 Schmahmann JD. Vascular syndromes of the thalamus. *Stroke* 2003;34:2264–78.
- 25 Schroll H, Hamker FH. Computational models of basal-ganglia pathway functions: focus on functional neuroanatomy. *Front Syst Neurosci* 2013;7:122.
- 26 Horisawa S, Taira T, Goto S, et al. Long-term improvement of musician's dystonia after stereotactic ventro-oral thalamotomy. *Ann Neurol* 2013;74:648–54.
- 27 Shibata T, Hirashima Y, Ikeda H, et al. Stereotactic VOA-Vop complex thalamotomy for writer's cramp. *Eur Neurol* 2005;53:38–9.
- 28 Doshi PK, Ramdasi RV, Karkera B, et al. Surgical interventions for task-specific dystonia (writer's dystonia). *Ann Indian Acad Neurol* 2017;20:324–7.
- 29 Horisawa S, Ochiai T, Goto S, et al. Safety and long-term efficacy of ventro-oral thalamotomy for focal hand dystonia. *Neurology* 2019;92:e371–7.
- 30 Fasano A, Llinas M, Munhoz RP, et al. MRI-guided focused ultrasound thalamotomy in non-ET tremor syndromes. *Neurology* 2017;89:771–5.
- 31 Meng Y, Suppiah S, Scantlebury N, et al. Treatment of a patient with task-specific writing tremor using magnetic resonance-guided focused ultrasound. *Can J Neurol Sci* 2018;45:474–7.
- 32 Delmaire C, Vidailhet M, Wassermann D, et al. Diffusion abnormalities in the primary sensorimotor pathways in writer's cramp. *Arch Neurol* 2009;66:502–8.
- 33 Fahn S. Assessment of the primary dystonias. In: Munsat T, ed. *Quantification of neurologic deficit*. Butterworths, 1989: 241–70.
- 34 Wissel J, Kabus C, Wenzel R, et al. Botulinum toxin in writer's cramp: objective response evaluation in 31 patients. *J Neurol Neurosurg Psychiatry* 1996;61:172–5.
- 35 Tubiana R. Musician's focal dystonia. *Hand Clin* 2003;19:303–8.
- 36 Chung KC, Pillsbury MS, Walters MR, et al. Reliability and validity testing of the michigan hand outcomes questionnaire. *J Hand Surg Am* 1998;23:575–87.
- 37 National statement on ethical conduct in human research 2007 (updated 2018). The national health and medical research council, the Australian research council and Universities Australia. Canberra Commonwealth of Australia;